
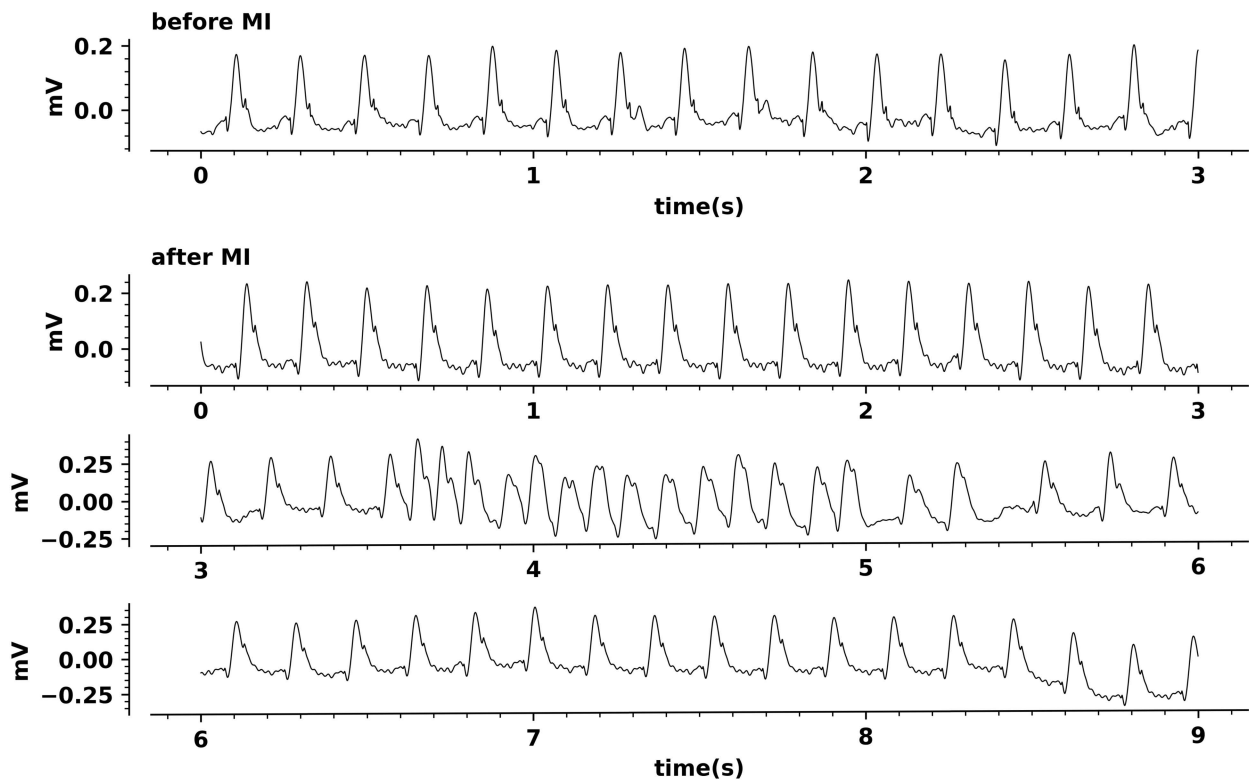


Supplementary video. *Experimental myocardial infarction preparation*



Aortic transit-time flow probe, left ventricular (LV) pressure-volume (PV) and pulmonary artery (PA) catheters are signaled. Both the position of left anterior descending artery ligation by a 6/0 polypropylene suture and the pale dyskinetic area in the anterior LV wall are marked by arrows.

Supplementary figure. *Electrocardiographic changes upon acute myocardial infarction (MI)*



ST-segment elevation is conspicuous after MI. Periods of ventricular arrhythmia were common.