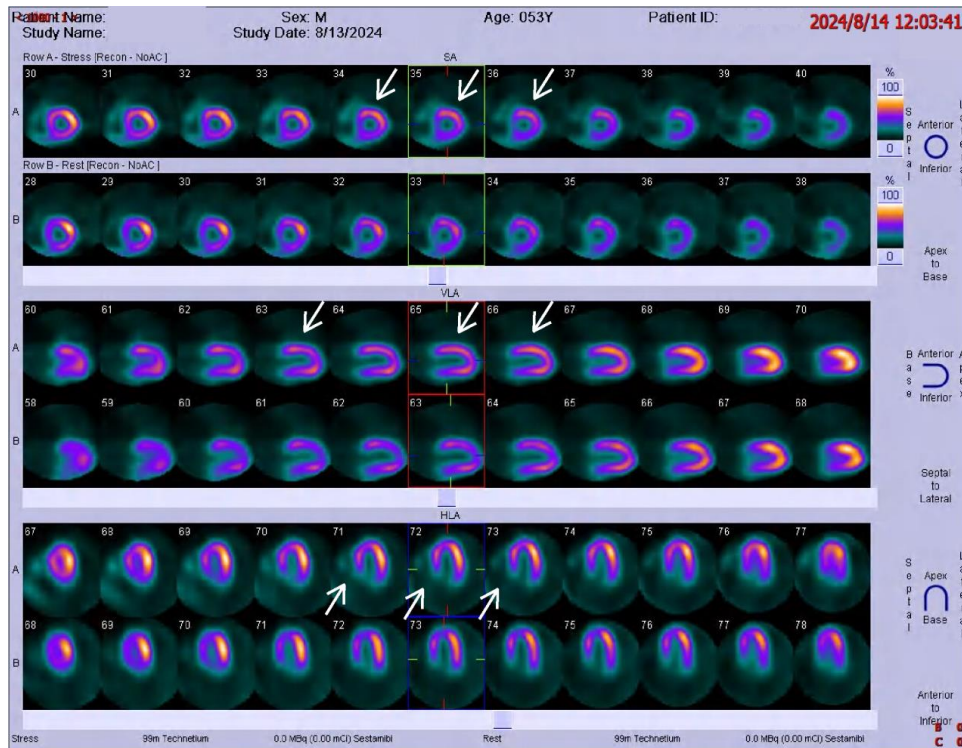
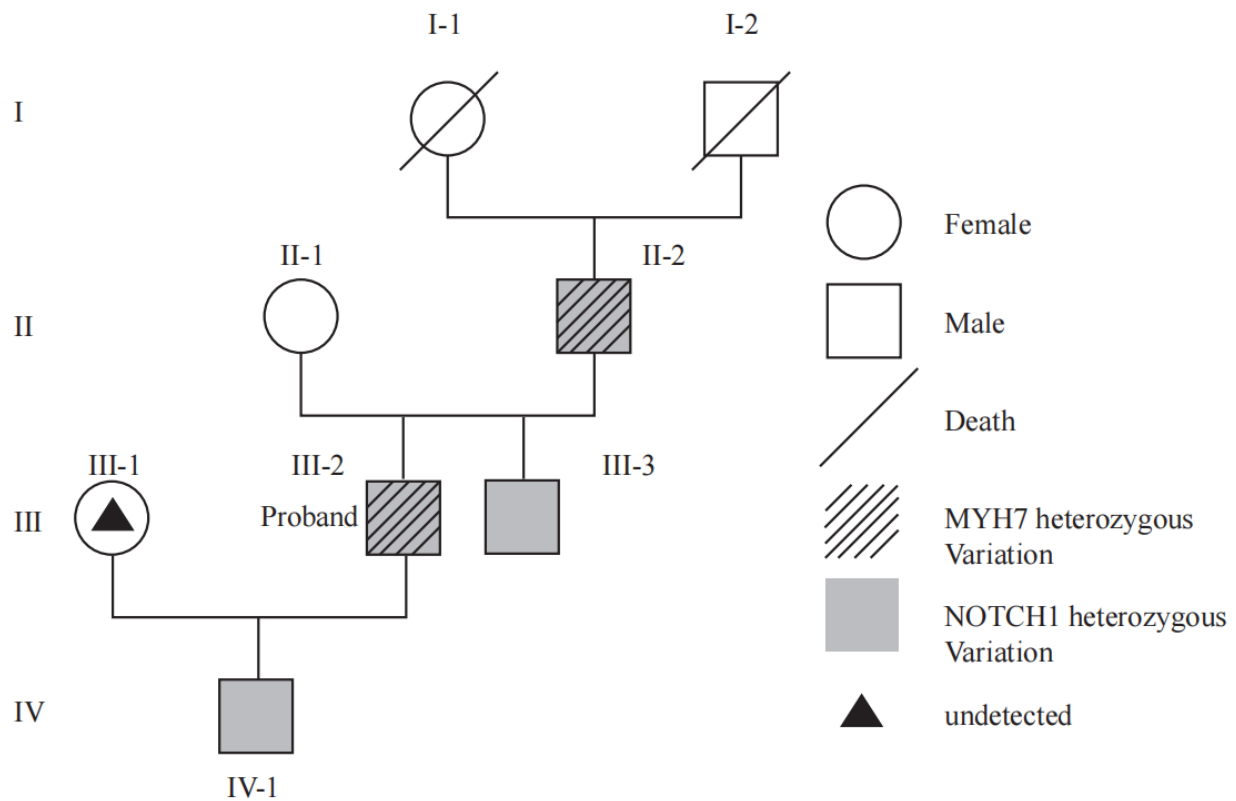


# Supplementary Material

## 1 Supplementary Figures



**Supplementary Figure 1.** Radionuclide myocardial perfusion imaging after six months of treatment.



**Supplementary Figure 2.** Investigation of the proband and family members. The proband (III-2) and his father (II-2) carry heterozygous variants in the NOTCH1 and MYH7 genes, while III-3 and IV-1 only carry a heterozygous variant in the NOTCH1 gene.