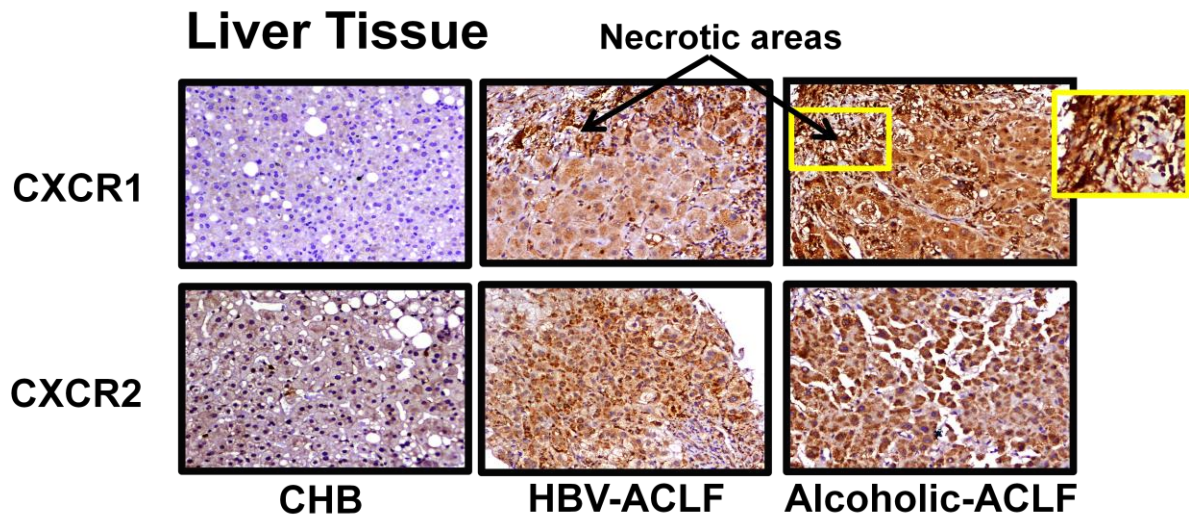


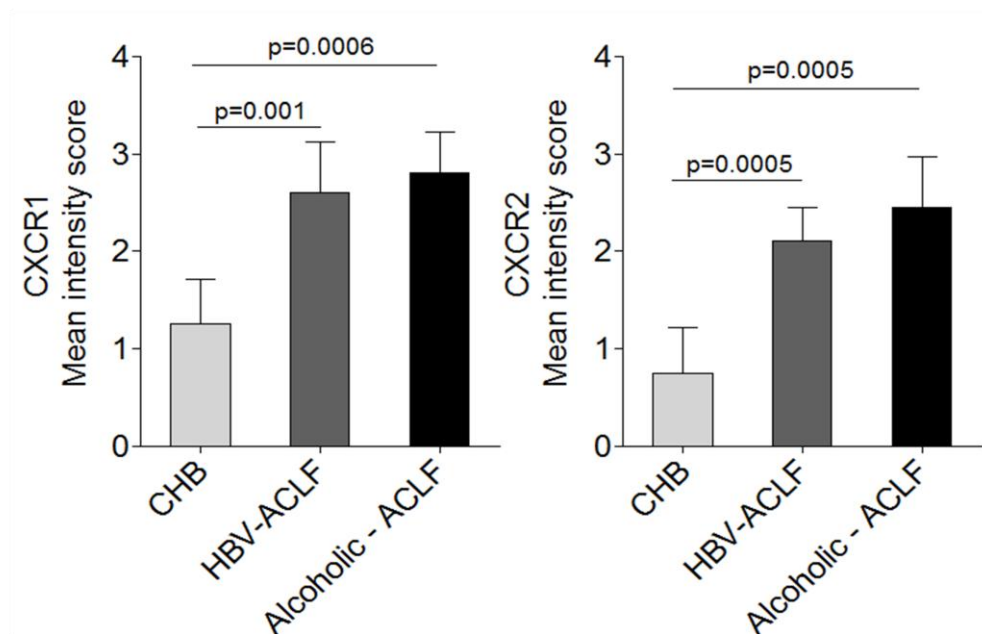
SUPPLEMENTARY FIGURE 2

A



Liver

B



Supplementary Figure 2 Increased CXCR1 and CXCR2 expression in the liver tissue of ACLF. (A)Immunohistochemistry (IHC) data illustrates high CXCR1 and CXCR2 staining in ACLF, more intense near necrotic areas of liver (magnification: 20X). (B)IHC data scoring

was done by giving a numerical value on a scale of 0, 1, 2 and 3 for none, light, medium and dark respectively. Higher CXCR1 and CXCR2 mean intensity score was found in ACLF groups than CHB.