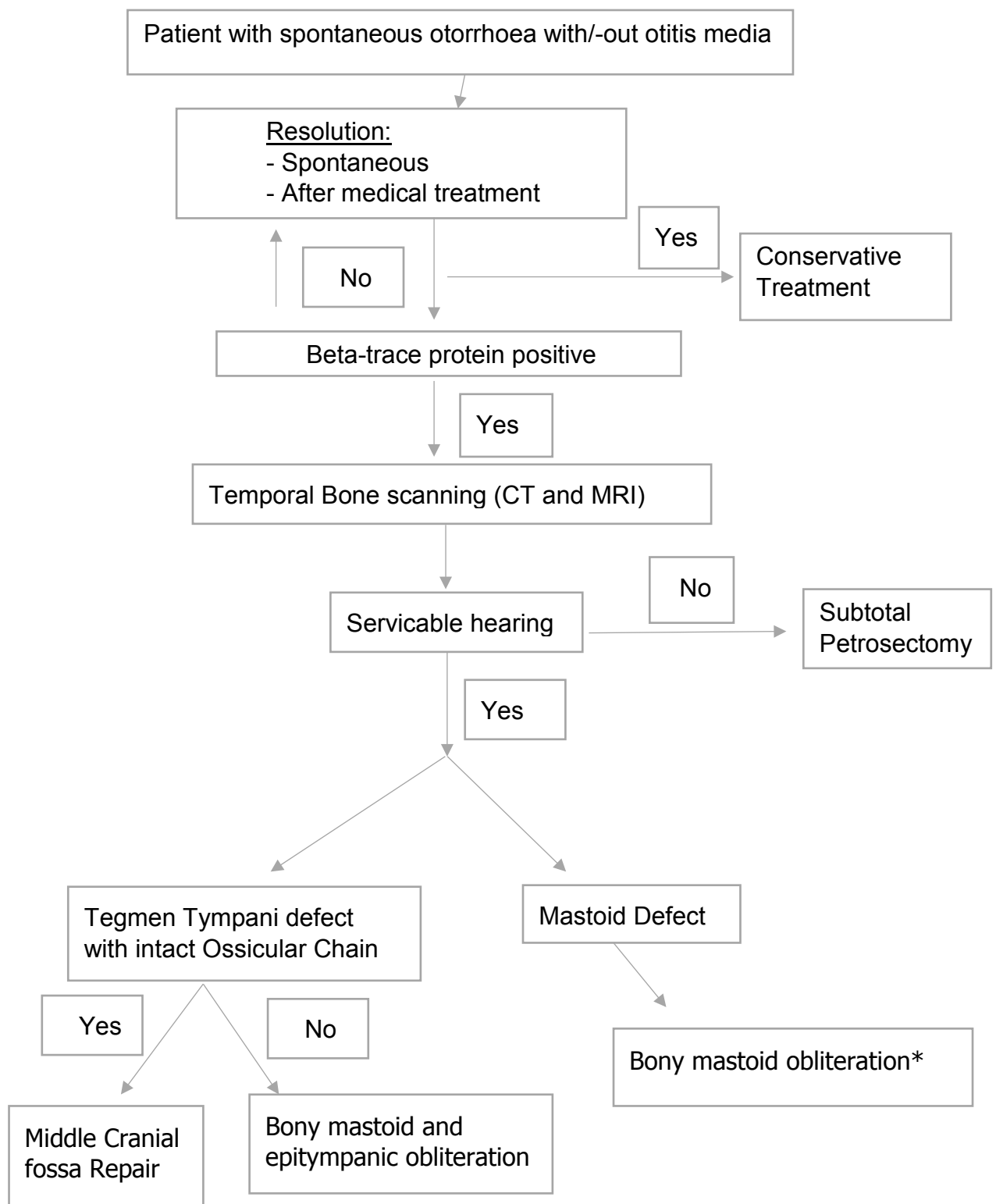


## Flow Chart Treatment CSF Otorrhoea



\* In cases where space (>0.8mm) between intact ossicular chain and tegmen tympani defect: then only underlay reconstruction tegmen defect with bony mastoid obliteration, without ossicular chain sacrifice

