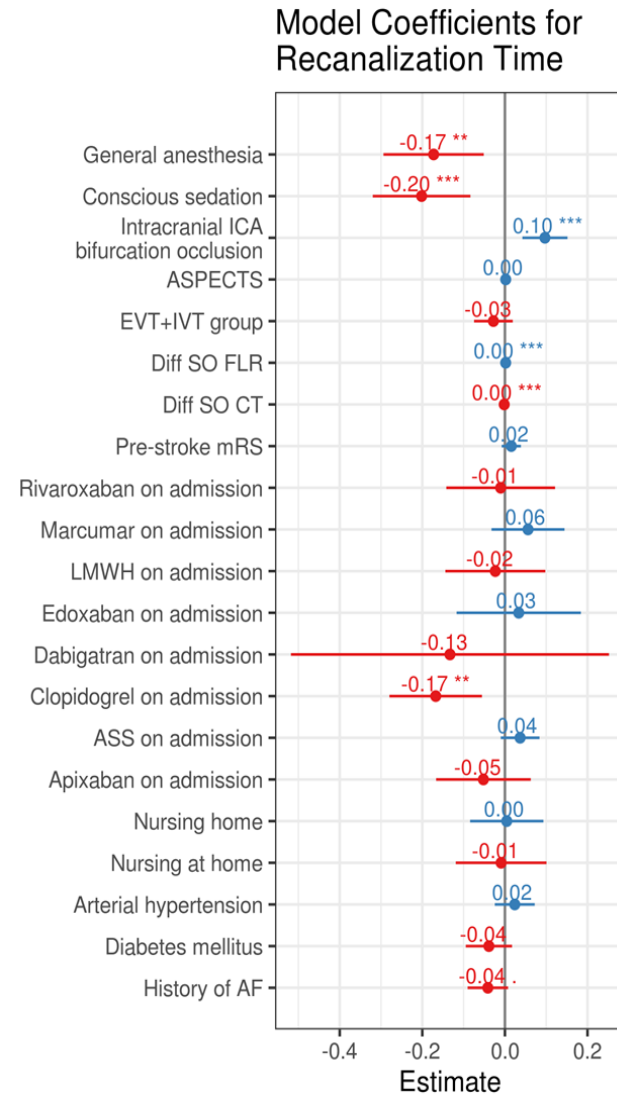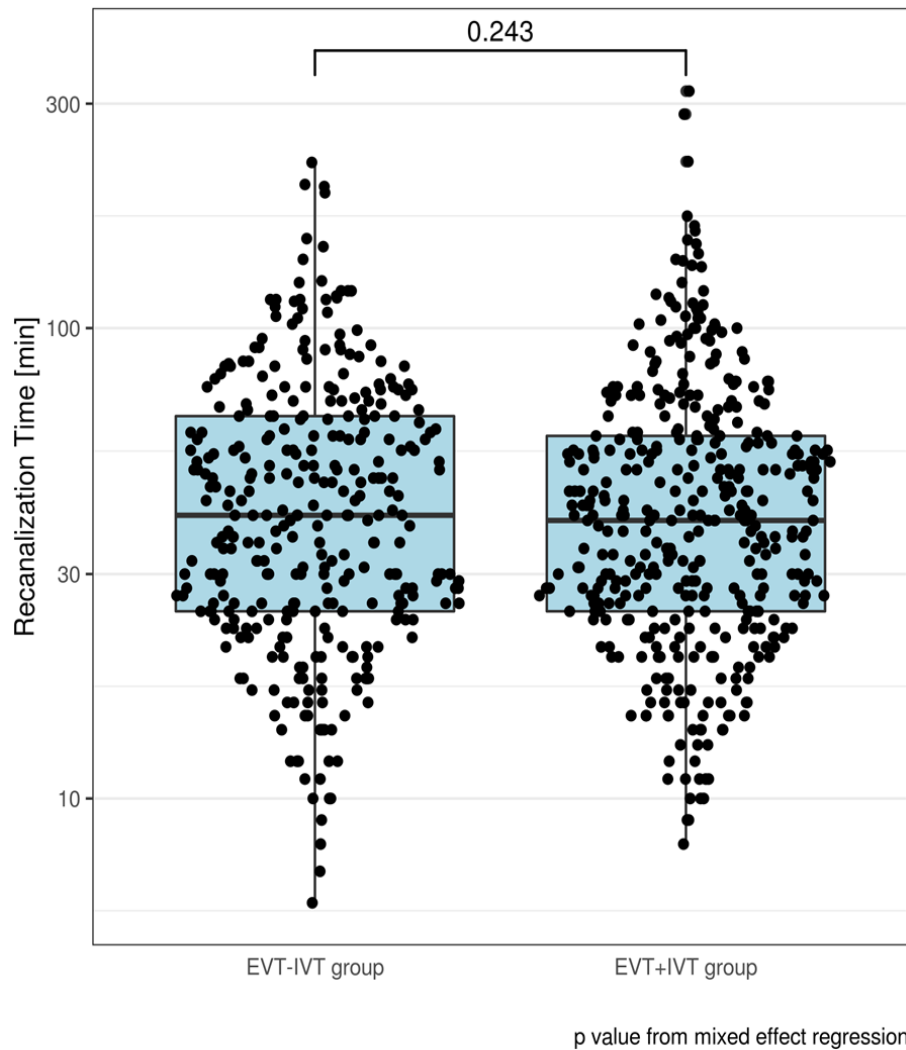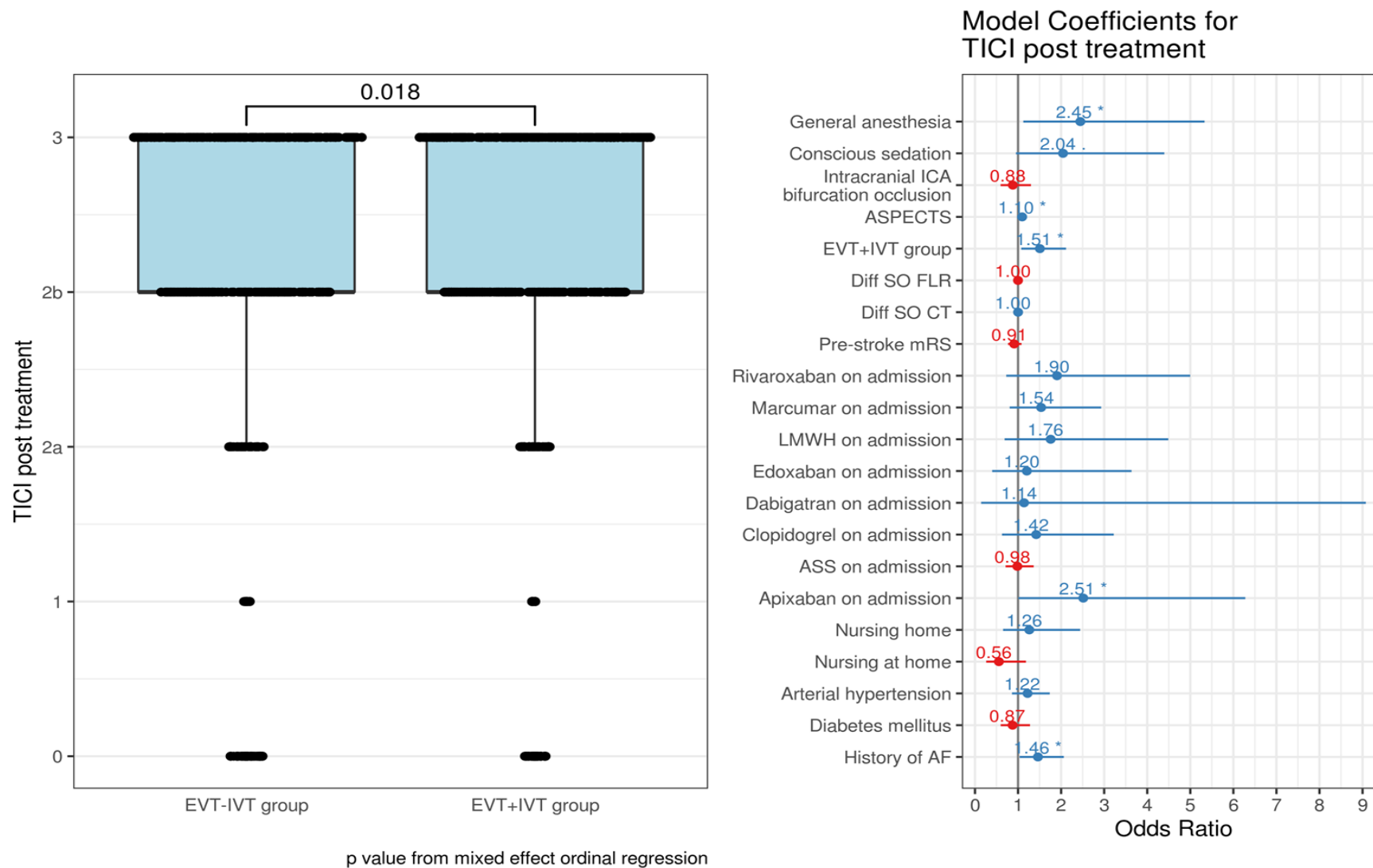
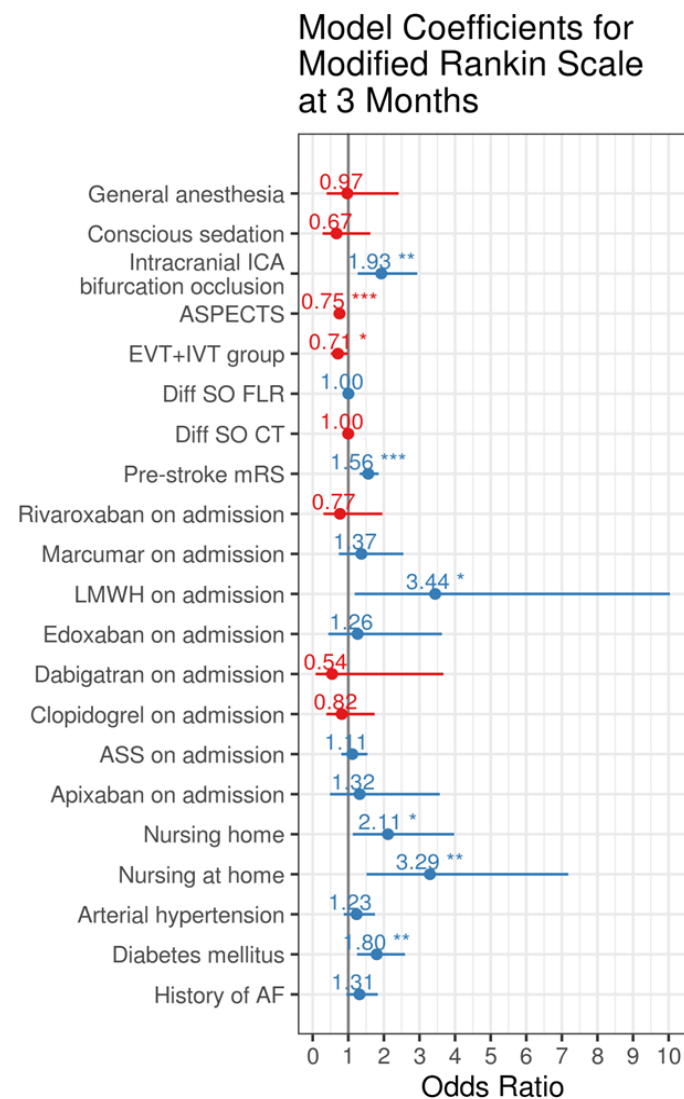
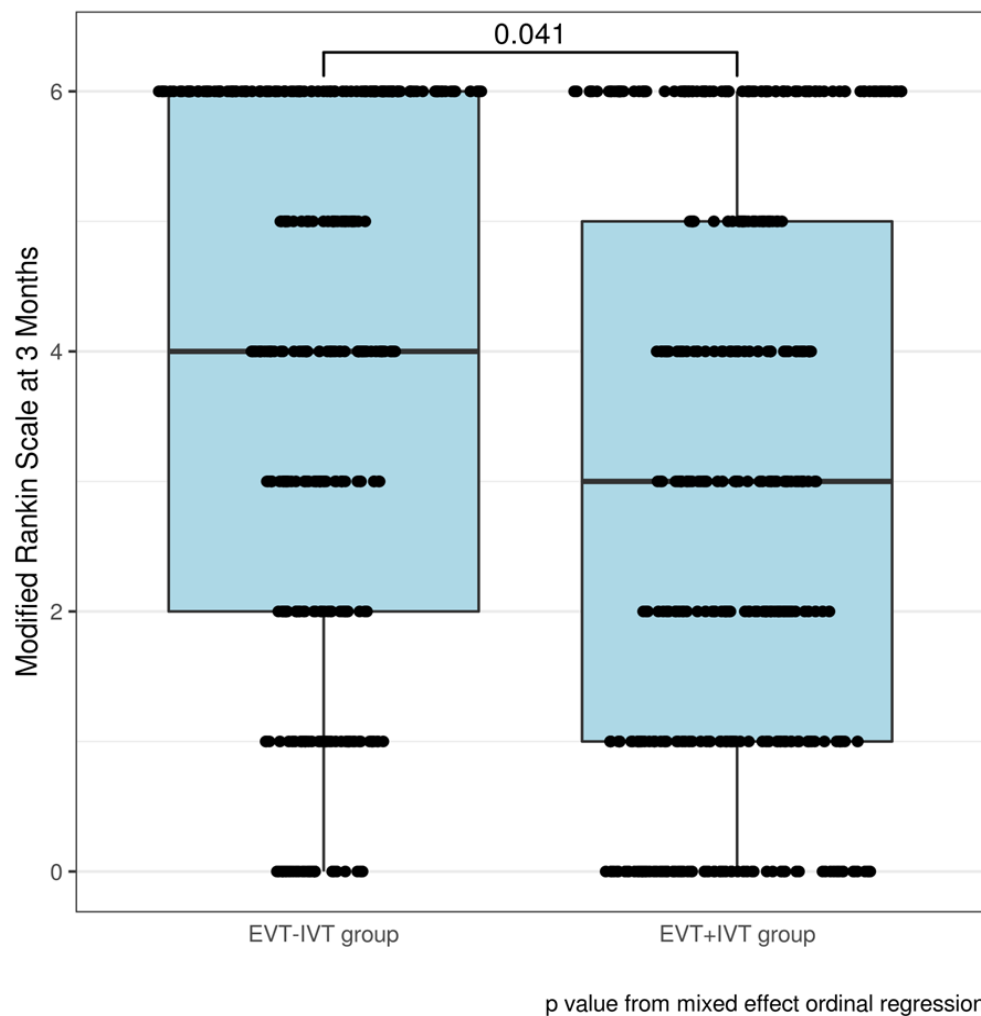


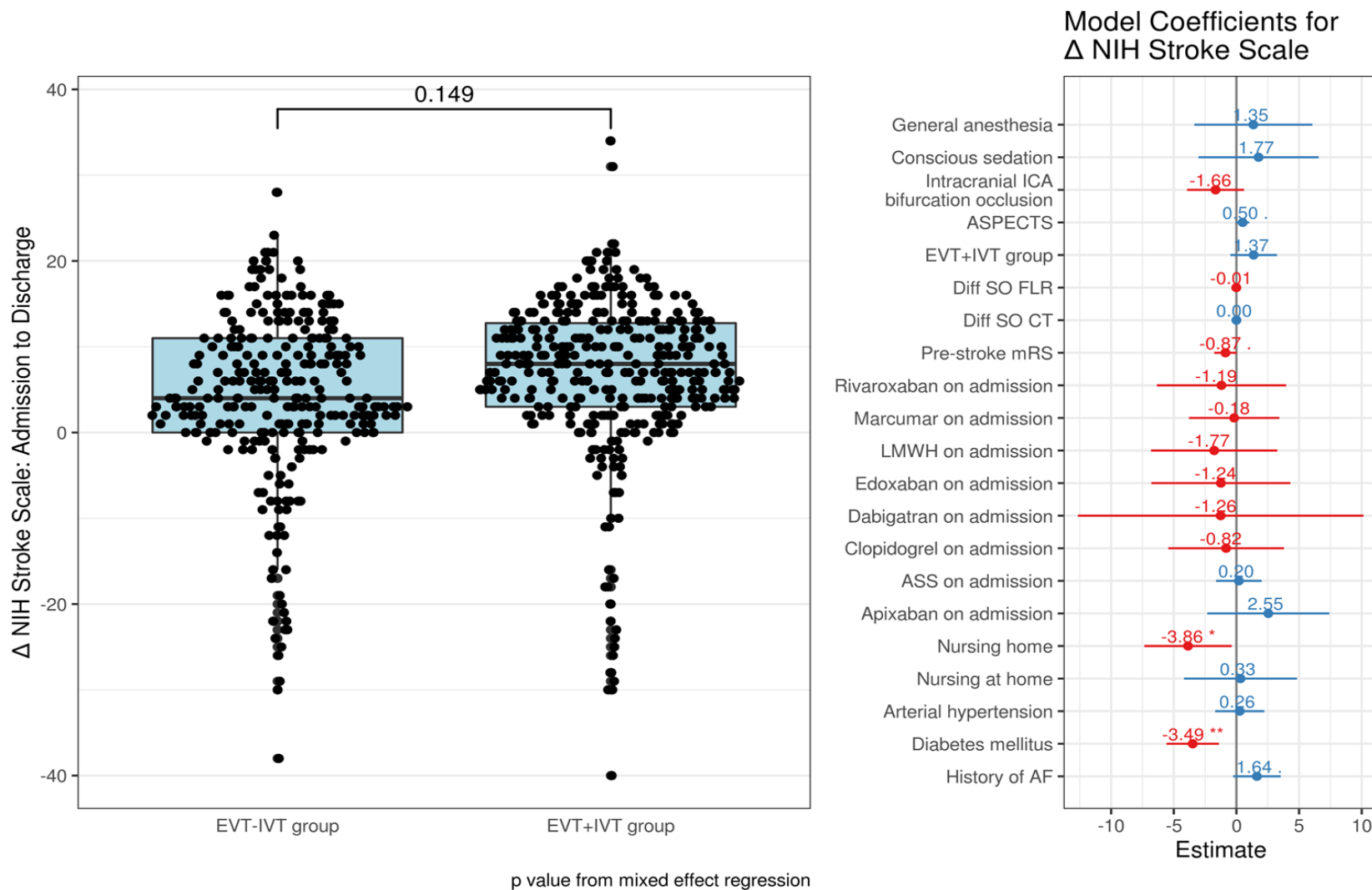
Supplementary Figure 2a: Adjusted analysis of the groin to recanalization times in patients with- (EVT+IVT) and without (EVT-IVT) bridging intravenous thrombolysis (EVT: endovascular treatment, IVT: intravenous thrombolysis, AF: atrial fibrillation, ASPECTS: Alberta stroke program early CT score, ASS: acetylsalicylic acid, LMWH: low molecular weight heparin, mRS: modified Rankin scale, ICA: internal carotid artery).



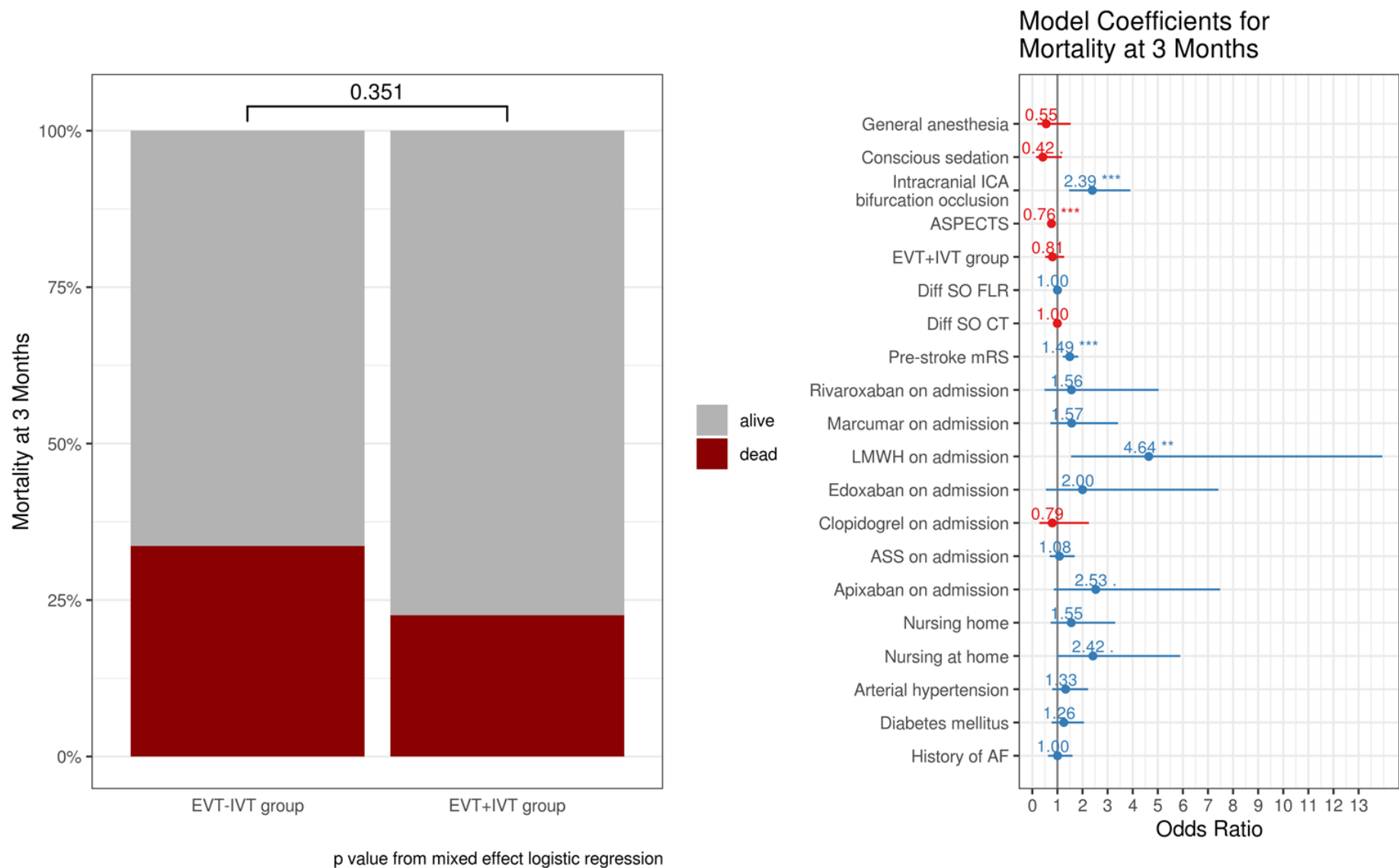
Supplementary Figure 2b: Adjusted analysis of the reperfusion status (quantified by the Thrombolysis in Cerebral Infarction (TICI) scale) in patients with- (EVT+IVT) and without (EVT-IVT) bridging intravenous thrombolysis (EVT: endovascular treatment, IVT: intravenous thrombolysis, AF: atrial fibrillation, ASPECTS: Alberta stroke program early CT score, ASS: acetylsalicylic acid, LMWH: low molecular weight heparin, mRS: modified Rankin scale, ICA: internal carotid artery).



Supplementary Figure 2c: Adjusted analysis of the modified Rankin Scale (mRS) at 90 days in with- (EVT+IVT) and without (EVT-IVT) bridging intravenous thrombolysis (EVT: endovascular treatment, IVT: intravenous thrombolysis, AF: atrial fibrillation, ASPECTS: Alberta stroke program early CT score, ASS: acetylsalicylic acid, LMWH: low molecular weight heparin, ICA: internal carotid artery).



Supplementary Figure 2d: Adjusted analysis of the change in National Institute of Health Stroke Scale (NIHSS) (admission NIHSS minus discharge NIHSS) in patients with- (EVT+IVT) and without (EVT-IVT) bridging intravenous thrombolysis (EVT: endovascular treatment, IVT: intravenous thrombolysis, AF: atrial fibrillation, ASPECTS: Alberta stroke program early CT score, ASS: acetylsalicylic acid, LMWH: low molecular weight heparin, mRS: modified Rankin scale, ICA: internal carotid artery).



Supplementary Figure 2e: Adjusted mortality analysis at 90 days in patients with- (EVT+IVT) and without (EVT-IVT) bridging intravenous thrombolysis (EVT: endovascular treatment, IVT: intravenous thrombolysis, AF: atrial fibrillation, ASPECTS: Alberta stroke program early CT score, ASS: acetylsalicylic acid, LMWH: low molecular weight heparin, mRS: modified Rankin scale, ICA: internal carotid artery).