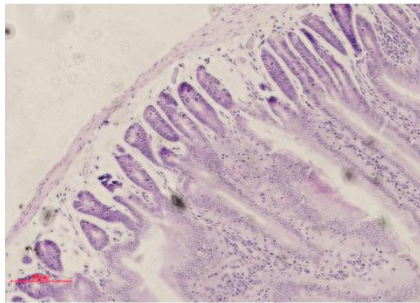
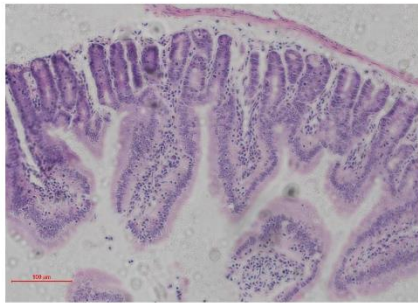


1 Supplementary material:

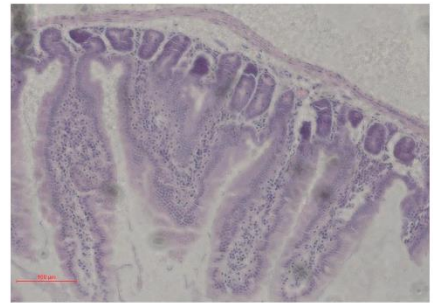**Vaccination**



**Vehicle**



**Mock**



2  
3 **Fig.S1.** Histopathological observations of mice intestine injected with the indicated viral strain or  
4 DMEM. (hematoxylin and eosin staining, 200×magnification)