



OPEN ACCESS

EDITED BY

Antonino Maniaci,
Kore University of Enna, Italy

REVIEWED BY

Salvatore Cocuzza,
University of Catania, Italy
Salvatore Lavallo,
San Raffaele Hospital (IRCCS), Italy

*CORRESPONDENCE

Yahya M. Naguib
✉ yahyamn@agu.edu.bh

RECEIVED 04 December 2023

ACCEPTED 20 February 2024

PUBLISHED 05 March 2024

CITATION

Al Shenawi H, Yaghan R, Al Saad S,
Binayfan ZM, Mohamed YY, Alnasser MM,
Al Shenawi F, Yaghan L, Almarabbeh A,
Alshammari A, Al Shenawi N and Naguib YM
(2024) The association between interdigital
pilonidal sinus and animal groomers is a
historical narrative correlation and not a true
occupational hazard.
Front. Environ. Health 3:1349268.
doi: 10.3389/fenvh.2024.1349268

COPYRIGHT

© 2024 Al Shenawi, Yaghan, Al Saad, Binayfan,
Mohamed, Alnasser, Al Shenawi, Yaghan,
Almarabbeh, Alshammari, Al Shenawi and
Naguib. This is an open-access article
distributed under the terms of the [Creative
Commons Attribution License \(CC BY\)](#). The
use, distribution or reproduction in other
forums is permitted, provided the original
author(s) and the copyright owner(s) are
credited and that the original publication in
this journal is cited, in accordance with
accepted academic practice. No use,
distribution or reproduction is permitted
which does not comply with these terms.

The association between interdigital pilonidal sinus and animal groomers is a historical narrative correlation and not a true occupational hazard

Hamdi Al Shenawi¹, Rami Yaghan^{1,2}, Suhair Al Saad¹,
Ziyad M. Binayfan³, Yaqoob Y. Mohamed³, Mansour M. Alnasser³,
Fatima Al Shenawi³, Lamees Yaghan⁴, Amer Almarabbeh⁵,
Abdulrahman Alshammari³, Noor Al Shenawi³ and Yahya M. Naguib^{6,7*}

¹Department of Surgery, College of Medicine and Medical Sciences, Arabian Gulf University, Manama, Bahrain, ²Department of Surgery, Jordan University of Science and Technology, Irbid, Jordan, ³Medical Student, College of Medicine and Medical Sciences, Arabian Gulf University, Manama, Bahrain, ⁴Medical Skills and Simulation Center, College of Medicine and Medical Sciences, Arabian Gulf University, Manama, Bahrain, ⁵Department of Family and Community Medicine, College of Medicine and Medical Sciences, Arabian Gulf University, Manama, Bahrain, ⁶Physiology Department, College of Medicine and Medical Sciences, Arabian Gulf University, Manama, Bahrain, ⁷Clinical Physiology Department, Faculty of Medicine, Menoufia University, Menoufia, Egypt

Introduction: Pilonidal sinus (PNS) is a small hole or “tunnel” in the skin that frequently occurs in the sacrococcygeal region. Nevertheless, PNS has been reported to occur between the fingers (interdigital) in barbers, hairdressers, and animal groomers. The aim of this study was to estimate the prevalence of interdigital PNS among animal handlers in Bahrain and to treat any patients encountered.

Methods: This is a cross-sectional study with convenience sampling from November 2020 to October 2021. The study participants were animal handlers from stables, veterinary, and pet shops in Bahrain. There were 43 males and 7 females with direct animal contact. 86% of the study population were handling horses, and 15% were handling different types of animals.

Results: No positive cases of interdigital PNS among participants were found, this might reflect the positive impact of good personal hygiene among our study population. Our study shows that groomers in Bahrain frequently wash their hands after handling animals, and 98% have a daily habit of bathing after work. It was also estimated that 60% of the participants use gloves to handle animals themselves or their waste.

Discussion: This could be the first study looking at the prevalence of interdigital PNS in animal groomers worldwide. The absence of any case report of interdigital PNS among animal groomers in the recent literature strengthens our assumption that the association between interdigital PNS and hair grooming could be a narrative coincidence rather than a true occupational hazard. The present work may help in better understanding of occupation-disease association, and highlights the importance of mass screening of animal handlers for occupation-dependent health problems.

KEYWORDS

pilonidal sinus, interdigital, animal groomers, hair dressers, domestic animals, Bahrain

Abbreviations

PNS, pilonidal sinus.

Background

A pilonidal sinus (PNS) is a small hole or “tunnel” in the skin that frequently occurs in the sacrococcygeal region. The word “pilonidal” is derived from the Latin words’ pilus (meaning hair) and nidus (meaning nest) (1). Pilonidal sinuses affect about 26 in 100,000 people, with at least 3 times male preponderance (2, 3). Less frequently, PNS was reported in other areas like breast, scalp, and face (2).

Exceptionally, PNS was reported in the interdigital area, with an anecdotal relation to working as a barber, hairdresser, or animal groomer (3–5). Interdigital PNS was first described in 1942 by Templeton and was histologically defined as a foreign body granuloma in a hairdresser (6). Long-standing interdigital PNS induces epidermal down growth, putatively in an attempt to wall off and expel the foreign material, progressing to cyst and sinus formation and predisposing to secondary infection (7).

Eryilmaz et al. proposed a mechanism by which the disease occurs by penetration of hair into the skin. This results in foreign body reactions and the development of a sinus lined by granulation tissue. In contrast to the other types of PNS, interdigital PNS was historically considered an occupational disease among barbers and animal groomers exposed to hair pieces (4).

PNS has been known to manifest as an acute abscess or a chronic sinus with discharge accompanied by recurrent episodes of inflammation (8). Abdulwahid et al. have demonstrated similar presentations of interdigital PNS, with chronic, painful discharging sinus being the most common manifestation (9). Other less common presentations include cystic-like lesions and nodules (4).

The first reported case of an interdigital PNS in animal groomers was in 1951 by Matheson (10). Since then, few reports have appeared in the literature. This condition was identified as an occupational hazard in male hairdressers, sheep shearers, dog groomers, and cow milkers (8). Many reports have demonstrated that interdigital PNS occurred mainly in the third, fourth, and second web spaces (4).

The association between interdigital PNS and hair grooming might be anecdotal, and the recent literature lacks such case reports. Given the improved hygiene over time, this study aimed to estimate the prevalence of interdigital PNS among animal handlers in Bahrain, if any, and treat any encountered patients. We also provided a review of the related literature.

Materials and methods

Ethical considerations

Ethical approval was obtained from the Research and Ethics committee at the Arabian Gulf University (approval number: E031-PI-4/19). Written informed consent was sought from all participants before enrolment.

Study design

An analytical cross-sectional study was conducted to estimate the prevalence of interdigital pilonidal sinus among animal handlers in the Kingdom of Bahrain. Data were collected during the period of November 2020 and October 2021 by face-to-face structured interviews using a questionnaire. The structured questionnaire was used to measure the socio-demographic characteristics, type of animal handled, use of gloves, washing hands, bathing after work, and Interdigital pilonidal sinus present.

Study participants, setting and data collection

The target study population included animal handlers from stables, veterinary, and pet shops in the kingdom of Bahrain, who are in direct contact with animals. The research team contacted all the 81 registered animal handlers in Bahrain using Sijilat governmental e-service to assess their willingness to enroll in this study. A representative sample (50 participants) was selected using a convenience sampling technique out of (81) participants (Response rate 62% approximately).

The following variables were collected from the participants: age, gender, hygiene habits, nationality, marital status, ethnicity, cigarette smoking, alcohol ingestion, medical comorbidities (diabetes, hypertension, previous skin diseases), place of work, duration of working with animals (experience), type of work (veterinary, groomer, cleaner, farmer, others), work-related data (dominant hand, types of animals handled). PNS data if they are present (when first noticed, for how long was it there, and if treated before or not). Participants were examined for the presence of interdigital PNS, both by history and physical examination, using a magnifying lens. If any interdigital PNS is encountered, data regarding duration, symptoms, and previous treatment were to be collected.

Inclusion criteria

Age ≥ 20 years, with history of direct contact and handling of animals.

Exclusion criteria

The participants whose ages were less than 20 years, who had contact with only pet animals at home, did not provide informed consent, or refused to participate (31 participants) were excluded.

Statistical analysis

Data from the survey was loaded into excel sheets (MS Excel) were checked, coded, and then exported to the Statistical Package

for Social Sciences (SPSS), version 29 (Chicago, IL, USA) to analyzed. Descriptive statistics analysis was applied to calculate frequencies and percentages and graphically for the categorical variables.

Literature review

The literature review was performed by searching electronic databases (PubMed and ScienceDirect) and using the following search words: pilonidal sinus, interdigital, groomers, and domestic animals.

Results

No single case of interdigital PNS was encountered among our study group. Fifty participants (43 males and 7 females) with direct contact with animals were obtained from stables and veterinary and pet shops in the Kingdom of Bahrain. Thirty-one animal groomers refused to participate. Half of the participants were Bahraini. The majority of participants were non-smokers (58%), as well as non-alcohol drinkers (86%), and all participants were right-handed (Table 1).

Regarding the types of animals that groomers handled in this research, 86% were handling horses as the primary animal of care. The second most common animals were cats (Figure 1).

Our study showed that 90% of groomers in Bahrain frequently washed their hands after handling animals, 98% bathed daily after work, and 60% used gloves while handling animals or their wastes (Figure 2).

Discussion

Twelve isolated cases of interdigital PNS were previously reported among animal groomers (Table 2). The last reports were published in 2020 (7, 11). These twelve cases formed the base of the anecdotal relation between working in animal

grooming and developing interdigital PNS as a very rare occupational hazard (6, 12). It is postulated that trauma, likely from the repetitive use of the hand as a comb-like device, causes coarse hairs to penetrate the skin of the interdigital crease, subsequently leading to a foreign body reaction, chronic inflammation, and sinus tract formation (4). Studies show that cigarette smoking and alcohol consumption can significantly increase the risk of inflammation and infection (22). Mohanna et al. described a dog groomer who developed a subungual pilonidal sinus complicated by osteomyelitis of the distal phalanx (13).

We did not encounter any cases of interdigital PNS among our study group. This could result from the small number of participants, but it also might reflect that the assumed historical causal relationship between animal grooming and the risk of developing interdigital PNS was exaggerated in the literature. The improved hygiene practices over the decade might have helped in reducing this hazard. It is worth mentioning here, however, that we do not have any firm evidence from the literature that PNS occurrence in other sites of the body is related to the level of hygiene practice.

In our study, 98% of participants bathed after work, 90% washed their hands regularly, and 60% used gloves. These measures may be a contributing factor in reducing the amount of recent literature on the association between interdigital PNS and animal grooming. Dupuis et al. showed that poor hygiene might cause multiple health issues and different types of infections (14). To the best of our knowledge, there is no data regarding the input of using gloves on the reduction or abolishment of the occurrence of interdigital PNS.

Our literature review showed that conservative approaches such as removal of hairs from the sinus, drainage of abscesses, and antibiotic administration are inadequate treatments for interdigital PNS. Most authors agree that radical surgical excision of the involved tissue allowing for secondary healing, is curative (5, 23) (Table 2).

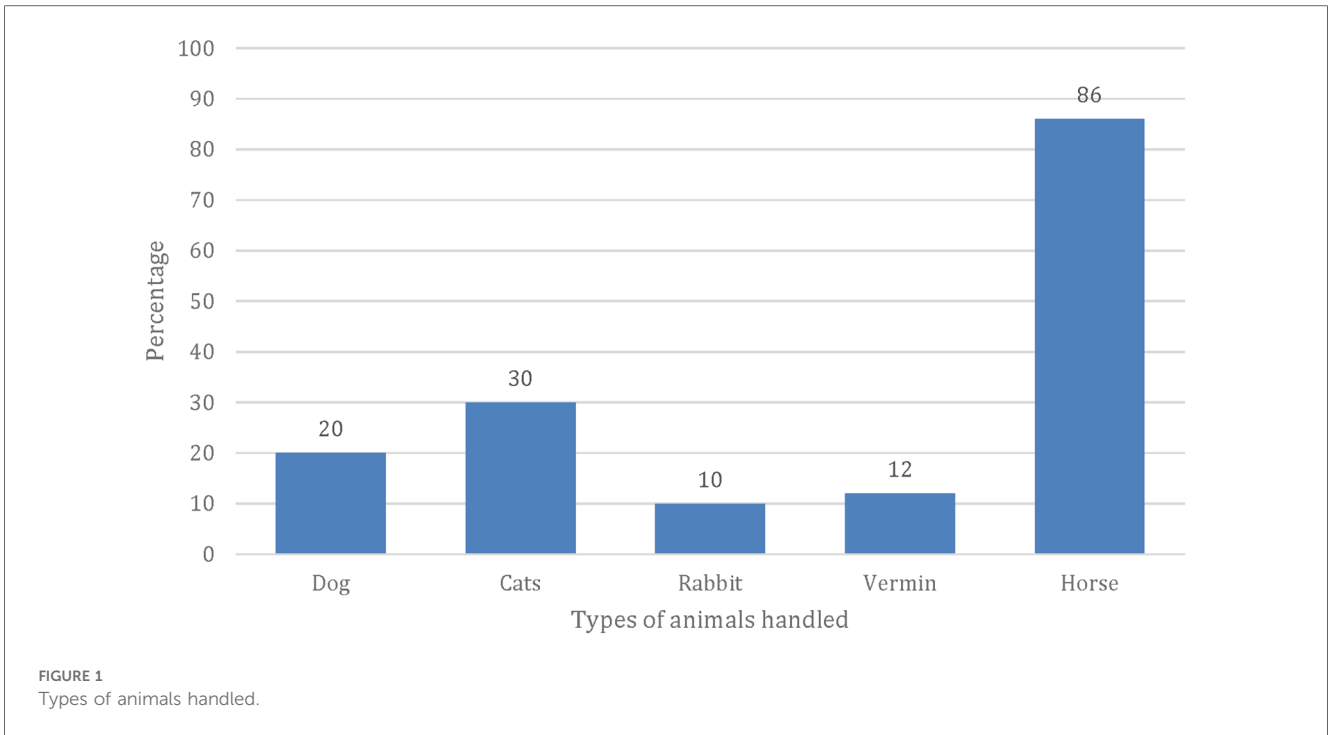
Treatment considerations include cost, healing period, scar tissue formation, and recurrence, with the latter being the most significant (8). Flap repairs can reduce the duration of recovery and, therefore, the away from work time (4). The recurrence was higher among patients treated with incision and drainage compared to those treated with radical excision (4).

In the Arabian Gulf region, horse stables are popular; thus, the number of animal groomers dealing with horses was the highest in our study.

Further research should be done to explore the relationship between good personal hygiene practices and the occurrence of interdigital PNS in groomers. Our study was conducted during the COVID-19 pandemic when Bahrain had strict regulations about hygiene practices and sanitization. In addition, the government of Bahrain has strict supervision and monitoring over stables and animal shops to prevent the spread of diseases. These factors support the findings of our studies that the high levels of hygiene practices might have led to abolished interdigital PNS cases among hair groomers in Bahrain.

TABLE 1 Demographic data regarding the participants.

Variables		Number	Percentage (%)
Gender	Male	43	86
	Female	7	14
Nationality	Bahraini	25	50
	Non-Bahraini	25	50
Age group	20–40 years	36	72
	>40 years	14	28
Cigarette smoking	Yes	21	42
	No	29	58
Alcohol ingestion	Yes	7	14
	No	43	86
Experience	<5 years	15	30
	5–10 years	22	44
	>10 years	13	26
Dominant hand	Right	50	100
	Left	0	0



Limitations

Although statistically sound, the number of animal groomers in the Kingdom of Bahrain remains low due to the limited number of pet and veterinary shops and horse stables. The number of participants was further affected by the fear of

the animal groomers that participating in the study might jeopardize their jobs. Future work could extend to involve house-based animal grooming and compare whether the compliance of animal groomers to hygiene protocols is fundamental in the protection against PNS in house or work settings.

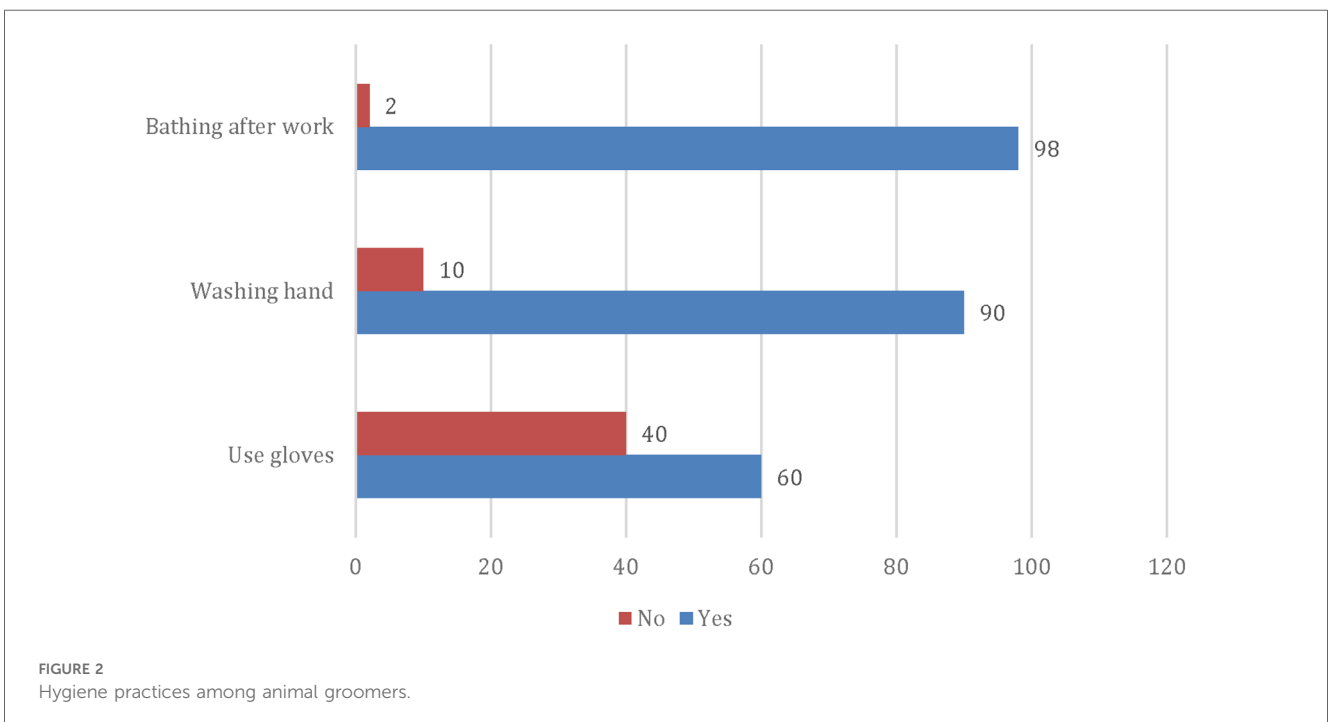


TABLE 2 Literature review.

Authors, year & type of paper	History and examination	Investigations	Treatment & prognosis
Olabi et al. (7), case report	41-year-old, right-handed male pet groomer Presented with 2 small sinuses, over the dorsal aspect and the free margin of the webspace of his right fourth finger.	Dermoscopic and histologic examination of the excised tissue	Antibiotics course and removed under general anesthesia, with reconstruction of the defect with a local flap. No recurrence after 2 months postoperatively.
Phillips et al. (11), case report	Male Shearer	Not accessible	
Matheson et al. (12), case report	34-year-old, male shearer Recurrent painful swelling in interdigital space between left middle and ring fingers Previous incident at same sight in the right hand	Block dissection of affected area in third recurrence. Sinus cavity containing wool with serrated margin lined superficially by squamous epithelium and deeply has connective tissue.	Incision and drainage Personal treatment first time by hot foment and spontaneous discharge of pus. Second treatment by hot water and removing wool using tweezers.
Mohanna et al. (13), case report	37-year-old, male dog groomer Presented with recurrent PNS in right thumb, oblique split in the distal pulp tissue, discharging purulent fluid	Radiographs showed a destructive lesion involving the tip of the terminal phalanx, consistent with osteomyelitis Collection of hair shafts surrounded by keratin and benign squamous epithelium containing acute and chronic inflammatory cells	Surgical excision of the distal half of the terminal phalanx No recurrence for 8 months
Vaiude et al. (14), case report	31-year-old, right-handed male shearer Painful, inflamed middle finger and nodule in the 3rd web space the left hand	Histology: The dermis contains an inflamed pilonidal sinus with evidence of ulceration. The sinus revealed sheep hair.	Erythromycin followed by Surgical excision with primary closure with a local skin flap. One recurrence in 2 months
Ramilo et al. (15), case report	24-year-old, left-handed male dog groomer Third interdigital space of his dominant hand	Histopathologic examination: An acanthotic, hyperplastic epidermis with scale crust, and nodular dermal infiltrates composed of epithelioid histiocytes, plasma cells, lymphocytes, and eosinophils. Transepidermal extrusion of polarizable hair cortical material	Sinusotomy and debridement with healing by secondary intention followed by proper wound care. No evidence of recurrence 3 years after resection
Meneghini et al. (16), case report	Milker	Not accessible	
Sloan et al. (17), case report	55-year-old, male abattoir worker Pain and swollen third web space of left hand.	Ultrasound showed a hypochoic area consistent with chronic inflammation and a linear hyperechoic structure measuring 4.25 mm	The lesion was explored under local anaesthesia and excised completely. No recurrence after 6 weeks.
Shikowitz-Behr et al. (18), case report	24-year-old, male dog groomer Second web space of his right hand revealed a 0.8 cm abscesses	Histological examination: A cystic follicle with surrounding fibrosis and focal hemosiderin	Incision and drainage and complete antibiotic course 4 weeks later, with recurrent abscess at the same location.
Papa et al. (19), case report	47-year-old, female dog groomer Tender erythematous 1.5 cm nodule in fourth web space of left hand with central pustule	Elliptical biopsy sent for histopathologic examination: purulent drainage cultured for microorganisms. Subcorneal cystic space containing neutrophils surrounding fragment of hair and portion of epidermis absent. Gram stain showed gram positive cocci.	Hairs were removed from cavity. Prescribed cephalixin. Patient returned after 1 month with tenderness and drainage; remaining sinus and tissue containing hair excised and prescribed cephalixin again. Healed and no recurrence.
Ito et al. (20), case report	24-year-old, female dog groomer Fourth web space of the right hand showed a red nodule, 8 mm in diameter, near the fistula, multiple hairs of different colors were seen in the fistula	Culture and histopathological examination: multiple hair shafts surrounded by infiltration of inflammatory cells with keratin and squamous epithelium with some foreign body giant cells	Treated with cefcapene Pivoxil of 300 mg/day for 7 days and surgical excision was performed. No recurrence occurred
Stern et al. (21), case report	39-year-old, female animal groomer Web between the middle and ring fingers of one hand small sinus tract with visible hair and an area of chronic inflammation. An area of chronic inflammatory tissue with a sinus tract and multiple visible hairs	Pathological examination: Sinus tract with abundant keratin, epidermal thickening, dermal fibrosis with chronic inflammation, and multiple embedded hairs	History of treatment with antibiotics therapy, drainage, and surgical excision of the sinus No recurrence

Conclusion

This could be the first study which looks at the prevalence of interdigital PNS in animal groomers worldwide. Our study did not document the presence of any interdigital PNS among animal hair groomers in Bahrain. This might reflect the positive impact of good personal hygiene in the prevention of interdigital PNS. However, together with the absence of any case reports of interdigital PNS among hair groomers in the recent literature, our findings might suggest that the association between interdigital

PNS and animal hair grooming could be a narrative coincidence rather than a true occupational hazard. This study could improve our knowledge about occupation-disease association.

Data availability statement

The original contributions presented in the study are included in the article/Supplementary Material, further inquiries can be directed to the corresponding author.

Ethics statement

The studies involving humans were approved by Research and Ethics Committee at Arabian Gulf University (E031-PI-4/19). The studies were conducted in accordance with the local legislation and institutional requirements. The participants provided their written informed consent to participate in this study.

Author contributions

HA: Conceptualization, Investigation, Methodology, Project administration, Supervision, Validation, Writing – original draft, Writing – review & editing. RY: Conceptualization, Data curation, Supervision, Validation, Writing – review & editing. SA: Conceptualization, Validation, Writing – review & editing. ZB: Data curation, Writing – review & editing. YM: Data curation, Writing – review & editing. MA: Data curation, Writing – review & editing. FA: Data curation, Writing – review & editing. LY: Data curation, Formal Analysis, Writing – review & editing. AA: Data curation, Formal Analysis, Methodology, Software, Validation, Writing – review & editing. AA: Data curation, Writing – review & editing. NA: Conceptualization, Data curation, Formal Analysis, Methodology, Writing – review & editing. YN: Conceptualization, Project administration, Supervision, Writing – review & editing.

References

- Nixon AT, Garza RF. Pilonidal Cyst and Sinus. [Updated 2023 Aug 8]. In: StatPearls [Internet]. Treasure Island, FL: StatPearls (2024). <https://www.ncbi.nlm.nih.gov/books/NBK557770/>
- Borges G, Maciel JA Jr, Carelli E, Alvarenga M, Castro RD, Bonilha L. Pilonidal cyst on the vault: case report. *Arq Neuropsiquiatr.* (1999) 57:273–6. doi: 10.1590/S0004-282X1999000200017
- Khanna A, Rombeau JL. Pilonidal disease. *Clin Colon Rectal Surg.* (2011) 24(1):46–53. doi: 10.1055/s-0031-1272823
- Eryilmaz R, Okan I, Ozkan OV, Somay A, Ensari CÖ, Sahin M. Interdigital pilonidal sinus: a case report and literature review. *Dermatol Surg.* (2012) 38(8):1400–3. doi: 10.1111/j.1524-4725.2012.02412.x
- Uysal AC, Orbay H, Uraloglu M, Sensoz O, Hyakusoku H. A rare occupational disease of hair dressers: interdigital pilonidal sinus. *J Nippon Med Sch.* (2007) 74(5):364–6. doi: 10.1272/jnms.74.364
- Templeton HJ. Foreign body granuloma or interdigital cysts with hair formation. *Arch Dermatol Syph.* (1942) 46:157–8.
- Olabi B, Biswas A, Tidman MJ. Interdigital lesions: it's a dog's life. *Clin Exp Dermatol.* (2020) 45(8):1077–9. doi: 10.1111/ced.14372
- Al-Khamis A, McCallum I, King PM, Bruce J. Healing by primary versus secondary intention after surgical treatment for pilonidal sinus. *Cochrane Database Syst Rev.* (2010) 2010(1):CD006213. doi: 10.1002/14651858.CD006213.pub3
- Shareef SH, Hawrami TA, Salih AM, Kakamad FH, Rahim HM, Hassan HA, et al. Interdigital pilonidal sinus: the first case series. *Int J Surg Case Rep.* (2017) 41:265–8. doi: 10.1016/j.ijscr.2017.10.021
- Waisman M, Olivetti RG. Pilonidal sinus of the hand. *AMA Arch Derm Syphilol.* (1952) 66(4):466–9. doi: 10.1001/archderm.1952.01530290042005
- Phillips PJ. Web space sinus in a shearer. *Med J Aust.* (1966) 2(24):1152–3. doi: 10.5694/j.1326-5377.1966.tb91893.x

Funding

The author(s) declare that no financial support was received for the research, authorship, and/or publication of this article.

Acknowledgment

Special thanks to College of Medicine and Medical Sciences at Arabian Gulf University.

Conflict of interest

The authors declare that the research was conducted in the absence of any commercial or financial relationships that could be construed as a potential conflict of interest.

Publisher's note

All claims expressed in this article are solely those of the authors and do not necessarily represent those of their affiliated organizations, or those of the publisher, the editors and the reviewers. Any product that may be evaluated in this article, or claim that may be made by its manufacturer, is not guaranteed or endorsed by the publisher.

- Matheson AD. Interdigital pilonidal sinus caused by wool. *Aust N Z J Surg.* (1951) 21(1):76–7. doi: 10.1111/j.1445-2197.1951.tb03774.x
- Mohanna PN, Flemming AS, Al-Sam SZ. Subungual pilonidal sinus of the hand in a dog groomer. *Br J Plast Surg.* (2001) 54(2):176–8. doi: 10.1054/bjps.2000.3457
- Vaiude P, Dhital M, Hancock K. A true pilonidal sinus in the hand of a sheep shearer. *J Surg Case Rep.* (2011) 2011(12):6. doi: 10.1093/jscr/2011.12.6
- Dupuis A, Christou N, Teterycz D, Balaphas A, Robert-Yap J, Zufferey G, et al. Sacro-coxxygial hygiene, a key factor in the outcome of pilonidal sinus surgical treatment? *BMC Surg.* (2021) 21(1):197. doi: 10.1186/s12893-021-01204-4
- Meneghini CL, Gianotti F. Granulomatosis fistulosa interdigitalis of milkers' hands. *J Occup Environ Med.* (1964) 6(6):276.
- Sloan JP, Brenchley J. An unusual cause of pilonidal sinus. *Emerg Med J.* (2000) 17(3):232. doi: 10.1136/emj.17.3.232
- Shikowitz-Behr L, Freedman AM. Recurrent interdigital pilonidal sinus in a dog groomer. *J Hand Microsurg.* (2016) 8(02):113–4. doi: 10.1055/s-0036-1585469
- Papa CA, Ramsey ML, Tyler WB. Interdigital pilonidal sinus in a dog groomer. *J Am Acad Dermatol.* (2002) 47(5):S281–2. doi: 10.1067/mjd.2002.109256
- Ito A, Yoshida Y, Yamamoto O. Case of interdigital pilonidal sinus in a dog groomer. *J Dermatol.* (2013) 40(12):1051–2. doi: 10.1111/1346-8138.12343
- Shikowitz-Behr L, Freedman AM. Recurrent interdigital pilonidal sinus in a dog groomer. *J Hand Microsurg.* (2016) 8(2):113–4. doi: 10.1055/s-0036-1585469
- Rosoff DB, Yoo J, Lohoff FW. Smoking is significantly associated with increased risk of COVID-19 and other respiratory infections. *Commun Biol.* (2021) 4(1):1230. doi: 10.1038/s42003-021-02685-y
- Vogel P, Lenz J. Treatment of pilonidal sinus with excision and primary suture using a local, resorbable antibiotic carrier. Results of a prospective randomized study. *Chirurg.* (1992) 63(9):748–53. doi: 10.1111/1346-8138.12343