



## OPEN ACCESS

APPROVED BY  
Frontiers Editorial Office,  
Frontiers Media SA, Switzerland

\*CORRESPONDENCE  
Ming Zhang  
✉ zhangming01@xjtu.edu.cn  
Junya Mu  
✉ junyamu@xjtu.edu.cn

<sup>†</sup>These authors share first authorship

RECEIVED 16 July 2025  
ACCEPTED 17 July 2025  
PUBLISHED 29 July 2025

CITATION  
Wen X, Zeng W, Li C, Qin Y, Qiao Y, Lu T,  
Dun W, Zhang M and Mu J (2025) Correction:  
Early corticospinal tract sub-pathway lesion  
load and integrity predict post-stroke motor  
outcomes. *Front. Hum. Neurosci.* 19:1667293.  
doi: 10.3389/fnhum.2025.1667293

COPYRIGHT  
© 2025 Wen, Zeng, Li, Qin, Qiao, Lu, Dun,  
Zhang and Mu. This is an open-access article  
distributed under the terms of the [Creative  
Commons Attribution License \(CC BY\)](#). The  
use, distribution or reproduction in other  
forums is permitted, provided the original  
author(s) and the copyright owner(s) are  
credited and that the original publication in  
this journal is cited, in accordance with  
accepted academic practice. No use,  
distribution or reproduction is permitted  
which does not comply with these terms.

# Correction: Early corticospinal tract sub-pathway lesion load and integrity predict post-stroke motor outcomes

Xin Wen<sup>1†</sup>, Wentao Zeng<sup>1†</sup>, Chiyin Li<sup>2</sup>, Yue Qin<sup>3</sup>, Yanqiang Qiao<sup>3</sup>,  
Tao Lu<sup>1</sup>, Wanghuan Dun<sup>4</sup>, Ming Zhang<sup>1\*</sup> and Junya Mu<sup>1\*</sup>

<sup>1</sup>Department of Medical Imaging, The First Affiliated Hospital of Xi'an Jiaotong University, Xi'an, Shaanxi, China, <sup>2</sup>Xi'an Academy of Fine Arts, Xi'an, Shaanxi, China, <sup>3</sup>Department of Radiology, Xi'an Daxing Hospital, Xi'an, Shaanxi, China, <sup>4</sup>Department of Rehabilitation Medicine, The First Affiliated Hospital of Xi'an Jiaotong University, Xi'an, Shaanxi, China

## KEYWORDS

stroke, motor recovery, corticospinal tract, diffusion spectrum imaging, lesion load

## A Correction on

### Early corticospinal tract sub-pathway lesion load and integrity predict post-stroke motor outcomes

by Wen, X., Zeng, W., Li, C., Qin, Y., Qiao, Y., Lu, T., Dun, W., Zhang, M., and Mu, J. (2025). *Front. Hum. Neurosci.* 19:1598598. doi: 10.3389/fnhum.2025.1598598

In the published article, there was an error in the legend for Table 1 as published. The legend incorrectly included the abbreviations “MMSE, Mini-Mental State Examination; NIHSS, National Institute of Health Stroke Scale,” which should have been removed because the table does not contain these variables.

The corrected legend appears below.

IQR, interquartile range; FMA-UE, Fugl-Meyer assessment of the upper extremity; Values are expressed as the mean  $\pm$  standard deviation, unless otherwise indicated.

In the published article, there was an error in the figure and caption for **Figure 1** as published. Due to a revision based on the reviewers' suggestion to remove the NIHSS assessment, the NIHSS label was inadvertently retained in the flowchart and should have been deleted. In addition, to ensure consistency in terminology, the label “FMA-UE” was also replaced with “clinical assessments” in the flowchart. The corrected figure appears below.

The original article has been updated.

## Publisher's note

All claims expressed in this article are solely those of the authors and do not necessarily represent those of their affiliated organizations, or those of the publisher, the editors and the reviewers. Any product that may be evaluated in this article, or claim that may be made by its manufacturer, is not guaranteed or endorsed by the publisher.

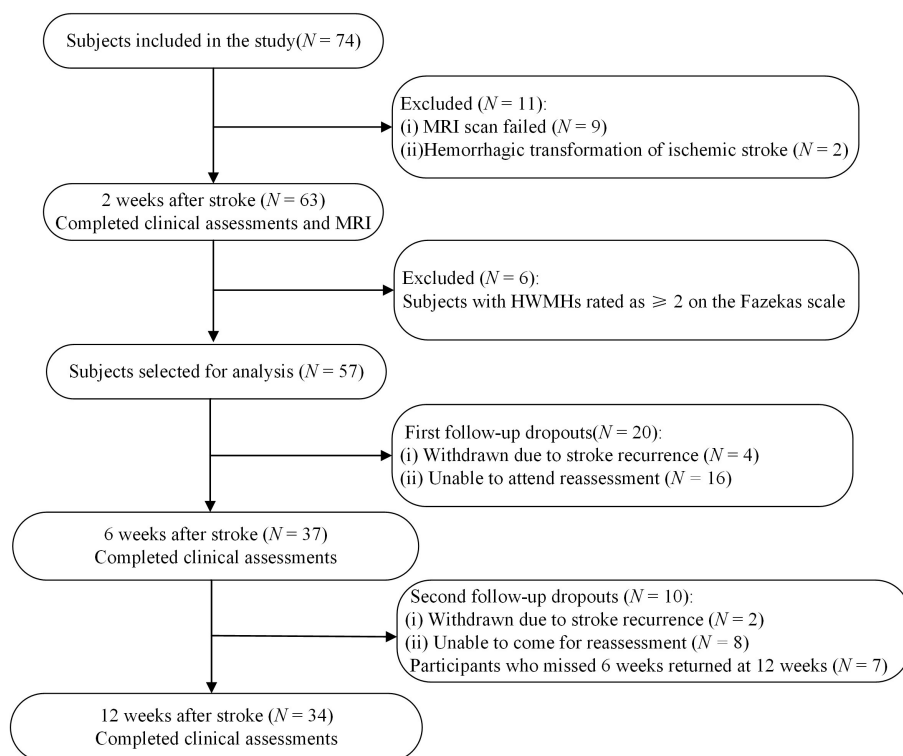


FIGURE 1

Flowchart of recruitment for the study. MRI, magnetic resonance imaging; HWMHs, high-grade white matter hyperintensities.