



OPEN ACCESS

EDITED BY

Yi Du,
The First Affiliated Hospital of Guangxi
Medical University, China

REVIEWED BY

Francesco Maria D'Alterio,
Royal Liverpool University Hospital,
United Kingdom
Jian-Feng He,
The First Affiliated Hospital of Guangxi
Medical University, China

*CORRESPONDENCE

Yuanzhen Su
✉ yuazhenhaoren@126.com

RECEIVED 14 November 2024

ACCEPTED 05 March 2025

PUBLISHED 24 March 2025

CITATION

Zhai G, Sun C, Zhang X and Su Y (2025)
Efficacy and safety of intravitreal injection of
aflibercept biosimilar for treating diabetic
macular edema.
Front. Med. 12:1528104.
doi: 10.3389/fmed.2025.1528104

COPYRIGHT

© 2025 Zhai, Sun, Zhang and Su. This is an
open-access article distributed under the
terms of the [Creative Commons Attribution
License \(CC BY\)](https://creativecommons.org/licenses/by/4.0/). The use, distribution or
reproduction in other forums is permitted,
provided the original author(s) and the
copyright owner(s) are credited and that the
original publication in this journal is cited, in
accordance with accepted academic
practice. No use, distribution or reproduction
is permitted which does not comply with
these terms.

Efficacy and safety of intravitreal injection of aflibercept biosimilar for treating diabetic macular edema

Gaixia Zhai, Chao Sun, Xia Zhang and Yuanzhen Su*

Zibo Central Hospital, Zibo, China

Purpose: This study aimed to evaluate the efficacy and safety of intravitreal injection of aflibercept biosimilar in the treatment of diabetic macular edema (DME).

Methods: Clinical data were collected from 33 patients (40 eyes) newly diagnosed with DME in the ophthalmology department of our hospital between February and April 2024, all of whom were treated with the aflibercept biosimilar. Patients were managed according to the 3+ Pro re nata (PRN) regimen and completed a minimum follow-up period of 6 months. The best-corrected visual acuity (BCVA) testing, optical coherence tomography, optical coherence tomography angiography, and multifocal electroretinography were performed before and after treatment. BCVA and central retinal thickness (CRT) were compared at baseline and 1-, 3-, and 6-months post-treatment. Additionally, the changes in the foveal avascular zone area, vascular density (VD) of superficial and deep retinal capillaries in the macular region, and the first positive peak amplitude density in ring 1 were analyzed 6 months post-treatment.

Results: BCVA improved significantly from 0.53 ± 0.12 logMAR at baseline to 0.31 ± 0.12 , 0.26 ± 0.10 , and 0.26 ± 0.08 logMAR at 1-, 3-, and 6-months post-treatment, respectively, ($p < 0.05$). CRT decreased significantly from 422.4 ± 63.04 μ m at baseline to 294.7 ± 47.89 , 272.1 ± 47.43 , and 281.0 ± 40.72 μ m at 1-, 3-, and 6-months post-treatment, respectively, ($p < 0.05$). The foveal avascular zone area significantly reduced from 0.40 ± 0.08 mm² at baseline to 0.35 ± 0.07 mm² at 6 months post-treatment. Superficial VD increased significantly from $38.90 \pm 7.88\%$ at baseline to $41.21 \pm 7.98\%$ at 6 months post-treatment, while deep VD significantly increased from $35.67 \pm 7.50\%$ at baseline to $38.72 \pm 6.90\%$ ($p < 0.05$). The first positive peak amplitude improved significantly from 55.30 ± 9.45 to 72.90 ± 7.44 nv/deg² at 6 months post-treatment ($p < 0.05$).

Conclusion: Intravitreal injections of aflibercept biosimilar can significantly reduce DME, improve BCVA, enhance macular perfusion, and restore macular function.

KEYWORDS

aflibercept biosimilar, diabetic macular edema, foveal avascular zone, vascular density, multifocal electroretinography

1 Introduction

Diabetic macular edema (DME) is the leading cause of vision loss among patients with diabetes, affecting approximately 21 million individuals worldwide (1). The primary pathological mechanisms driving DME include increased vascular permeability and leakage, with vascular endothelial growth factor (VEGF) playing a pivotal role in its onset and progression (2). Given the profound socio-economic impact of DME, its prevention and timely, effective treatment have emerged as critical priorities in public health.

In recent years, intravitreal anti-VEGF therapy (3, 4) and dexamethasone implants have become the cornerstone of DME management (5–7). Conbercept, aflibercept, and ranibizumab are commonly used anti-VEGF agents for the treatment of DME. Compared to conbercept (Chengdu Kang Hong Biotechnology Co., Ltd.) and ranibizumab (Lucentis; Genentech, Inc., South San Francisco, CA, USA), aflibercept (Eylea; Regeneron, Inc., Tarrytown, NJ, USA) stands out due to its broader target range, stronger binding affinity, and longer duration of action. Despite its superior therapeutic efficacy, the high cost of aflibercept may limit its widespread adoption. The aflibercept biosimilar QL1207 developed by Qilu Pharmaceutical Co., Ltd., received certification from the National Medical Products Administration on 18 December 2023. This biosimilar is indicated for the treatment of neovascular age-related macular degeneration and DME. Its primary advantage over the originator drug lies in its cost-effectiveness, which can significantly alleviate the financial burden on patients and improve treatment adherence.

Currently, only a limited number of clinical studies have investigated the therapeutic effect of aflibercept biosimilars in the treatment of DME. Some studies suggest that frequent anti-VEGF therapy can delay the progression of retinal capillary occlusion, while others hold a contrasting view (8). The potential for anti-VEGF therapy to exacerbate retinal ischemia remains a subject of ongoing debate. In recent years, optical coherence tomography (OCT) angiography (OCTA) has emerged as a non-invasive diagnostic tool, enabling precise measurement of the foveal avascular zone (FAZ) and vascular density (VD) in both the superficial and deep retinal capillary networks of the macular region (9).

Multifocal electroretinography (mfERG) has gained recognition as an objective technique in the field of visual electrophysiology. This method provides a direct assessment of various retinal functions, with its central response offering valuable insights into macular functionality (10). Clinically, mfERG is widely utilized to evaluate the severity of retinal lesions and to monitor improvements following pharmacological interventions (11–13). The primary objective of this study was to evaluate the efficacy and safety of aflibercept biosimilars in the treatment of DME, utilizing OCTA and mfERG as key diagnostic modalities.

2 Methods

2.1 Study protocol

This study was conducted in accordance with the principles of the Helsinki Declaration and received approval from the Medical Ethics Committee of Zibo Central Hospital. The study was retrospective. However, all patients were thoroughly informed of the potential risks and clinical necessity of the intravitreal injection prior to the

procedure. Written informed consent was obtained from each patient before the administration of the treatment.

2.2 Patients

Clinical data were collected from patients diagnosed with DME for the first time in the ophthalmology department of our hospital and subsequently treated with aflibercept biosimilars. The inclusion criteria were as follows: (a) a first-time diagnosis of DME with no prior ocular treatments administered, (b) age over 18 years, and (c) availability of complete clinical data. The exclusion criteria included: (a) a history of ocular trauma, surgery, and corneal diseases; (b) refractive media opacity that could interfere with fundus examination; (c) current use of contact lenses; (d) a history of ocular conditions such as glaucoma and optic neuritis; and (e) poorly controlled blood glucose or blood pressure levels.

2.3 Examination and treatment

All patients underwent intravitreal injections of aflibercept biosimilars (2 mg/0.05 mL). Treatment followed the 3+ Pro re nata (PRN) regimen, wherein the first three injections were delivered at 4-week intervals. Subsequent injections were determined based on clinical indicators. The criteria for reinjection were as follows: (1) a decline in BCVA of more than one line on the Snellen chart; (2) a CRT exceeding 280 μ m; and (3) the presence of new, recurrent, or persistent subretinal or intraretinal fluid, as identified on any OCT scan. All patients completed a minimum follow-up period of 6 months. Comprehensive ophthalmic evaluations were conducted before and after treatment, including slit lamp biomicroscopy, tonometry, best-corrected visual acuity (BCVA) testing, OCT, OCTA (Optovue RTVue xR Avanti, Optovue Inc. USA), fundus fluorescein angiography (Spectralis, Heidelberg, Germany), and fundus examination. MfERG was performed at baseline and 6 months post-treatment. Central retinal thickness (CRT) was measured using OCT (Optovue, Inc., Fremont, CA, USA), while the FAZ area and VD of the superficial and deep retinal capillaries were assessed using OCTA. The first positive peak (P1) amplitude density (Amp-P1) in ring 1 was quantified using mfERG.

To rule out any surgical contraindications, all patients underwent preoperative assessments, including lacrimal irrigation, electrocardiogram, complete blood count, coagulation profile, biochemical tests, and pre-transfusion screening. To prevent intraocular infection, patients were instructed to administer levofloxacin eye drops (Santen, Japan) four times daily for 3 days prior to the procedure. All surgeries were performed under strict aseptic conditions. The surgical protocol included preoperative mydriasis using compound tropicamide eye drops and surface anesthesia with three applications of procaine hydrochloride eye drops. Patients were positioned supine on the operating table, and standard disinfection and draping procedures were followed. The conjunctival sac was disinfected with 50 g L-1 povidone-iodine and then rinsed with normal saline. Using a 30-G needle, aflibercept biosimilars (2 mg/0.05 mL) were injected into the vitreous cavity through the pars plana, 3.5–4 mm posterior to the temporal limbus. Following the injection, gentle pressure was applied to the puncture site using a

sterile cotton swab. Postoperatively, an eye ointment containing tobramycin and dexamethasone was applied, and the affected eyes were covered with sterile gauze. Patients were prescribed tobramycin and dexamethasone eye drops to be used four times daily for 1 week after the surgery.

2.4 Observation parameters

The BCVA (logMAR) and CRT were evaluated at baseline and at 1-, 3-, and 6-months post-injection. The FAZ areas, VD of the retinal capillaries, and Amp-P1 values were assessed at baseline and 6 months following the injection.

2.5 Statistical analysis

In this study, GraphPad Prism 9 software was used for the statistical analysis, and the BCVA was converted to the logarithm of the minimum angle of resolution (logMAR). Quantitative data were expressed as mean \pm standard deviation (SD). Repeated measures one-way analysis of variance was used to evaluate BCVA and CRT at baseline and at 1-, 3-, and 6-months post-treatment. The Anderson–Darling test was used to assess the normality of the data distribution. When the standard normal distribution was satisfied, the paired sample *t*-test was used to compare the VD and FAZ areas of retinal capillaries and Amp-P1 at baseline and 6 months post-treatment, but when the standard normal distribution was not satisfied, the Wilcoxon signed-rank test was used for comparative analysis.

3 Results

3.1 Baseline characteristics

This study analyzed the clinical data of 33 patients (40 eyes), including 16 men and 17 women. The mean age of the participants was 51.06 ± 11.00 years (range, 32–70 years), and the average duration

of diabetes was 12.61 ± 3.91 years. All 40 eyes included in the study were diagnosed with non-proliferative diabetic retinopathy.

3.2 BCVA and CRT

The BCVA and CRT measurements are summarized in [Tables 1, 2](#), as well as illustrated in [Figure 1](#).

3.3 FAZ area, VD of retinal capillaries, and Amp-P1

The FAZ area, VD of retinal capillaries, and Amp-P1 are presented in [Table 3](#) and illustrated in [Figure 2](#).

3.4 Complications

Subconjunctival hemorrhage was observed in five eyes, corneal epithelial injury occurred in two eyes, and intraocular pressure increased transiently in two eyes. No severe complications such as endophthalmitis, glaucoma, cataracts, or vitreous hemorrhage occurred in 40 eyes. Furthermore, no cardiovascular or cerebrovascular events were reported in any of the patients during the follow-up period.

3.5 Number of injections

The average number of injections administered to 40 eyes was 3.20 ± 0.46 over the 6-month follow-up period post-treatment.

4 Discussion

The prevalence of type 2 diabetes is increasing due to the acceleration of the aging process of the population and changes in

TABLE 1 Comparison of BCVA and CRT at 1-, 3-, and 6-months post-treatment and baseline values.

Indices (mean \pm SD)	Preoperation	1 month	3 months	6 months
BCVA (LogMAR)	0.53 ± 0.12	$0.31 \pm 0.12^*$	$0.26 \pm 0.10^*$	$0.26 \pm 0.08^*$
<i>p</i> -value	—	<0.0001	<0.0001	<0.0001
CRT (μ m)	422.4 ± 63.04	$294.7 \pm 47.89^*$	$272.1 \pm 47.43^*$	$281.0 \pm 40.72^*$
<i>p</i> -value	—	<0.0001	<0.0001	<0.0001

BCVA, best-corrected visual acuity; logMAR, logarithm of minimal angle of resolution; CRT, central retinal thickness. **P* < 0.05 statistically significant difference compared with baseline values.

TABLE 2 Comparison of BCVA and CRT at 1-, 3-, and 6-months post-treatment.

	BCVA (LogMAR) <i>p</i> -value	CRT <i>p</i> -value
1 vs. 3 months	0.0615	0.1939
1 vs. 6 months	0.0090	0.5621
3 vs. 6 months	0.9984	0.6013

BCVA, best-corrected visual acuity; logMAR, logarithm of minimal angle of resolution; CRT, central retinal thickness.

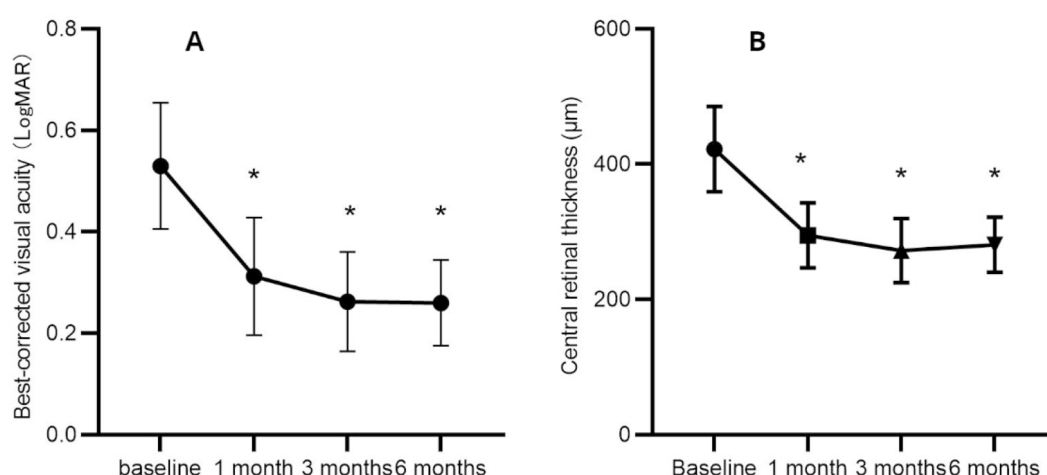


FIGURE 1

Mean changes in best-corrected visual acuity (A) and central retinal thickness (B) during the 6-month follow-up period. * $p < 0.05$ statistically significant difference compared with baseline values.

TABLE 3 Comparative analysis of FAZ area, VD of retinal capillaries, and Amp-P1 before and 6 months post-treatment.

Indices (mean \pm SD)	Preoperative	6 months	<i>P</i>
FAZ (mm ²)	0.40 \pm 0.08	0.35 \pm 0.07	<0.0001
Superficial VD (%)	38.90 \pm 7.88	41.21 \pm 7.98	<0.0001
Deep VD (%)	35.67 \pm 7.50	38.72 \pm 6.90	<0.0001
Amp-P1 (nv/deg ²)	55.30 \pm 9.45	72.90 \pm 7.44	<0.0001

FAZ, foveal avascular zone; VD, vascular density; Amp-P1, first positive peak amplitude density.

lifestyle and other factors (14). Chronic hyperglycemia poses a threat to many organs of the body, especially the eyes, nervous system, kidneys, heart, and blood vessels (15). Diabetic retinopathy (DR), one of the most frequent microvascular complications of diabetes, is categorized into proliferative and non-proliferative forms. Among these, DME has the most profound impact on vision acuity in patients with non-proliferative diabetic retinopathy (16).

The treatment of DME includes retinal photocoagulation, hormones, and anti-VEGF agents. The primary treatment for DME in the past was macular laser photocoagulation, which effectively reduces macular edema, but it has a limited effect on vision acuity improvement. In recent years, anti-VEGF therapy has emerged as the preferred treatment for DME due to its demonstrated efficacy (17, 18). Within the VEGF family, VEGF-A and placental growth factor (PGF) play central roles in the pathogenesis of DME. VEGF-A promotes the proliferation and migration of endothelial cells, enhances vascular permeability, and is directly implicated in the development of macular edema. PGF exacerbates vascular leakage by mediating inflammatory responses. Aflibercept exhibits a high binding affinity for both VEGF and PGF. A meta-analysis of 43 randomized controlled trials involving 8,234 patients demonstrated that aflibercept outperformed conbercept and ranibizumab in treating DME (19). Approved by the US FDA in 2014 for DME treatment, aflibercept effectively blocks VEGF at a low concentration and has a prolonged duration of action, allowing for extended

injection intervals and reducing treatment burden. These properties may explain its superior efficacy in DME management.

Despite its therapeutic advantages, the high cost of aflibercept imposes a significant economic burden on patients. The emergence of biosimilar drugs offers a promising solution to this challenge. Biosimilars are highly similar to their reference products in terms of quality, safety, and efficacy but are more cost-effective, potentially improving patient access and treatment adherence. However, the therapeutic efficacy of aflibercept biosimilars in DME is worthy of further study.

Although intravitreal anti-VEGF injections are generally considered safe, it is crucial to remain vigilant about potential ocular and systemic complications associated with the procedure. Ocular complications primarily include uveitis, endophthalmitis, retinal detachment, vitreous hemorrhage, sustained elevation of intraocular pressure, cataract progression, pain, and floaters.

Some scholars propose that the increase in VEGF concentration within the vitreous serves as a compensatory mechanism to restore macular blood perfusion. While anti-VEGF treatment effectively improves macular edema, it may also accelerate retinal capillary occlusion in patients with DME, potentially exacerbating visual impairment (20, 21). Currently, fundus fluorescein angiography remains the most effective tool for assessing the FAZ; however, it lacks the ability to differentiate between superficial and deep retinal capillary layers. In contrast, OCTA provides detailed visualization of the FAZ morphology in both the superficial and deep retinal vascular plexus. Theoretically, anti-VEGF drugs may induce the contraction of retinal arterioles, which could lead to the expansion of the FAZ, particularly in patients with pre-existing macular ischemia (22). In recent years, mfERG has emerged as a non-invasive, objective method for assessing visual function, proving valuable in evaluating retinal vascular diseases such as diabetes retinopathy and guiding treatment strategies (23, 24).

In this study, we evaluated changes in BCVA, CRT, FAZ area, VD of retinal capillaries, and Amp-P1 before and after treating DME with an aflibercept biosimilar. We also assessed the efficacy and safety of the aflibercept biosimilar in managing DME. The results demonstrated

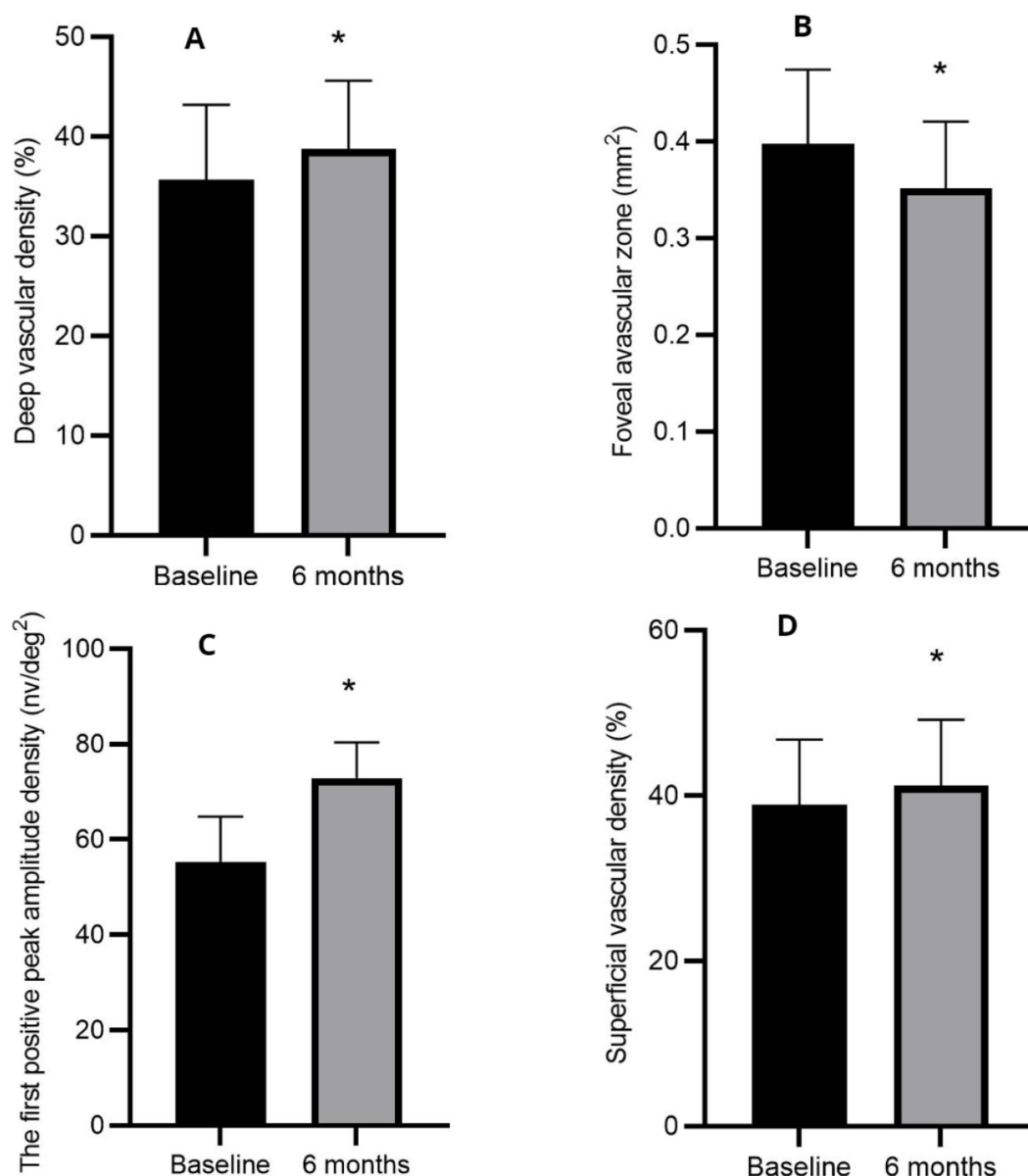


FIGURE 2

Mean changes in deep vascular density (A), foveal avascular zone (B), the first positive peak amplitude density (C), and superficial vascular density (D) before and at 6 months post-treatment. * $p < 0.05$ statistically significant difference compared with baseline measurements.

a significant improvement in BCVA at 1-, 3-, and 6-months post-treatment compared to baseline, alongside a significant reduction in CRT and macular edema. These findings align with previous studies, which reported comparable efficacy between the aflibercept biosimilar (QL1207) and the reference aflibercept in treating neovascular age-related macular degeneration (25). However, unlike previous research, this study uniquely explores the effects of the aflibercept biosimilar (QL1207) on macular perfusion and functional outcomes in DME patients before and after treatment.

The Amp-P1 was significantly higher at 6 months post-treatment compared to baseline ($p < 0.05$), suggesting improved macular function following treatment. Additionally, the study revealed a reduction in the FAZ area and an increase in VD after treatment, indicating enhanced macular perfusion after anti-VEGF therapy.

These findings are consistent with previous research on the effects of conbercept on macular perfusion in patients with DME (26). Notably, no severe complications such as endophthalmitis, glaucoma, cataract progression, or vitreous hemorrhage were observed in any of the 40 treated eyes. Furthermore, none of the patients experienced cardiovascular or cerebrovascular events during the treatment period.

Intravitreal injections of the aflibercept biosimilar significantly reduce macular edema in patients with DME, improving their BCVA, macular perfusion status, and macular function. However, this study has several limitations, including its retrospective design, small sample size, and relatively short follow-up period. The long-term efficacy of the aflibercept biosimilar in treating DME remains to be confirmed through large-scale, prospective studies with extended follow-up. Additionally, future research should compare the therapeutic effects

of the aflibercept biosimilar (QL1207) with other anti-VEGF agents to further elucidate its relative efficacy and safety.

Data availability statement

The original contributions presented in the study are included in the article/supplementary material, further inquiries can be directed to the corresponding author.

Ethics statement

The studies involving humans were approved by Medical Ethics Committee of Zibo Central Hospital. The studies were conducted in accordance with the local legislation and institutional requirements. The participants provided their written informed consent to participate in this study.

Author contributions

GZ: Software, Writing – original draft, Writing – review & editing. CS: Investigation, Resources, Writing – review & editing. XZ: Supervision, Writing – review & editing. YS: Software, Supervision, Validation, Writing – review & editing, Writing – original draft.

References

- Joanne WY, Rogers SL, Kawasaki R, Lamoureux EL, Kowalski JW, Bek T, et al. Global prevalence and major risk factors of diabetic retinopathy. *Diabetes Care*. (2012) 35:556–64. doi: 10.2337/dc11-1909
- Simó R, Hernandez C. Intravitreal anti-VEGF for diabetic retinopathy: hopes and fears for a new therapeutic strategy. *Diabetologia*. (2008) 51:1574–80. doi: 10.1007/s00125-008-0989-9
- Nguyen QD, Brown DM, Marcus DM, Boyer DS, Patel S, Feiner L, et al. Ranibizumab for diabetic macular edema: results from 2 phase III randomized trials: RISE and RIDE. *Ophthalmology*. (2012) 119:789–801. doi: 10.1016/j.ophtha.2011.12.039
- Maris D, Dastiridou A, Kotoula M, Karathanou A, Tsironi EE, Bargiota A, et al. Macular ischemia changes in patients with diabetic macular edema treated with Aflibercept and Ranibizumab. *Diagnostics*. (2024) 14:1306. doi: 10.3390/diagnostics14121306
- Berhuni M, Yilmaz IE, Gizem GS, Özcan ZÖ, Dögan L. Efficacy and safety of intravitreal dexamethasone implant in treatment-resistant diabetic macular edema: six-month results. *Cesk Slov Oftalmol*. (2025) 81:1–6. doi: 10.31348/2025/4
- Tranos P, Koukoulas S, de Politis PB, Tranou M, Giamouridou O, Stavrakas P, et al. Effects of dexamethasone intravitreal implant on multifocal electroretinography in diabetic macular Oedema. *Drug Des Devel Ther*. (2024) 18:5367–75. doi: 10.2147/DDDT.S477677
- Chakraborty S, Sheth JU. Comparative analysis of intravitreal dexamethasone implant (Ozurdex) and Brolucizumab injection in the treatment of diabetic macular edema with Hyperreflective Intraretinal dots: a retrospective study. *Clin Ophthalmol*. (2024) 18:2897–905. doi: 10.2147/OPHT.S484731
- Terui T, Kondo M, Sugita T, Ito Y, Kondo N, Ota I, et al. Changes in areas of capillary nonperfusion after intravitreal injection of bevacizumab in eyes with branch retinal vein occlusion. *Retina*. (2011) 31:1068–74. doi: 10.1097/IAE.0b013e31820c83c2
- Samara WA, Shahlaee A, Sridhar J, Khan MA, Ho AC, Hsu J, et al. Quantitative optical coherence tomography angiography features and visual function in eyes with branch retinal vein occlusion. *Am J Ophthalmol*. (2016) 166:76–83. doi: 10.1016/j.ajo.2016.03.033
- Luu CD, Lau AMI, Lee SY. Multifocal electroretinogram in adults and children with myopia. *Arch Ophthalmol*. (2006) 124:328–34. doi: 10.1001/archophth.124.3.328
- Lu H, Yue T, Liu N, Wang ZF, Zhai GX, Mi DM, et al. Efficacy of Conbercept in the treatment of choroidal neovascularization secondary to pathologic myopia. *Front Med*. (2021) 8:720804. doi: 10.3389/fmed.2021.720804

Funding

The author(s) declare that no financial support was received for the research and/or publication of this article.

Conflict of interest

The authors declare that the research was conducted in the absence of any commercial or financial relationships that could be construed as a potential conflict of interest.

Generative AI statement

The authors declare that no Gen AI was used in the creation of this manuscript.

Publisher's note

All claims expressed in this article are solely those of the authors and do not necessarily represent those of their affiliated organizations, or those of the publisher, the editors and the reviewers. Any product that may be evaluated in this article, or claim that may be made by its manufacturer, is not guaranteed or endorsed by the publisher.

- Macha N, Yu M, Sapieha P, Klier S, Ghosh A, White L, et al. Multifocal electroretinography changes after UBX1325 (Foselutoclax) treatment in Neovascular age-related macular degeneration. *J Clin Med*. (2024) 13:5540. doi: 10.3390/jcm13185540
- Shuyu Z, Xianjun L, Jinglin Z. Effectiveness of dexamethasone implants in treating diabetic macular edema with hard exudates: a clinical observation. *Int Ophthalmol*. (2024) 44:377. doi: 10.1007/s10792-024-03278-4
- Jinchi X, Maoqing W, Zhiping L, Hua N, Jingkuo L, Yukun C, et al. Global burden of type 2 diabetes in adolescents and young adults, 1990–2019: systematic analysis of the global burden of disease study 2019. *BMJ*. (2023) 379:e072385. doi: 10.1136/bmj-2022-072385
- Sana E, Sarah L, Mahrukh A, Ariba Y, Sadia S, Asma B. Prevalence of complications associated with diabetes among Pakistani patients: a questionnaire-based survey. *Curr Diabetes Rev*. (2022) 18:629. doi: 10.2174/1573399818666220119100629
- Bressler NM, Glassman AR, Hutton DW. Controversies in using off-label Intravitreal bevacizumab for patients with diabetic macular edema—reply. *JAMA Ophthalmol*. (2017) 135:291–2. doi: 10.1001/jamaophthol.2016.5686
- Sorour OA, Sabrosa AS, Yasin Alibhai A, Arya M, Ishibazawa A, Witkin AJ. Optical coherence tomography angiography analysis of macular vessel density before and after anti-VEGF therapy in eyes with diabetic retinopathy. *Int Ophthalmol*. (2019) 39:2361–71. doi: 10.1007/s10792-019-01076-x
- Villegas VM, Schwartz SG. Current and future pharmacologic therapies for diabetic retinopathy. *Curr Pharm Des*. (2019) 24:4903–10. doi: 10.2174/1381612825666190130140717
- Wang X, He X, Qi F, Liu J, Wu J. Different anti-vascular endothelial growth factor for patients with diabetic macular edema: a network Meta-analysis. *Front Pharmacol*. (2022) 13:876386. doi: 10.3389/fphar.2022.876386
- Masahiko S, Kanako Y. Macular ischaemia after intravitreal bevacizumab injection in patients with central retinal vein occlusion and a history of diabetes and vascular disease. *Br J Ophthalmol*. (2010) 94:381–3. doi: 10.1136/bjo.2009.160986
- Leung LS, Silva RA, Blumenkranz MS, Flynn HW Jr, Sanislo SR, et al. Macular infarction following intravitreal bevacizumab for treatment of central retinal vein occlusion. *Ophthalmic Surg Lasers Imaging*. (2012) 43:e73–9. doi: 10.3928/15428877-20120712-05
- Callizo J, Atili A, Striebe NA, Bemme S, Feltgen N, Hoerauf H, et al. Bevacizumab versus bevacizumab and macular grid photocoagulation for macular edema in eyes with non-ischemic branch retinal vein occlusion: results from a prospective randomized study. *Graefes Arch Clin Exp Ophthalmol*. (2019) 257:913–20. doi: 10.1007/s00417-018-04223-9

23. Yigit K, Inan Ü, Inan S, Dogan M, Yavas GF, Cetinkaya E. Long-term full-field and multifocal electroretinographic changes after treatment with ranibizumab in patients with diabetic macular edema. *Int Ophthalmol.* (2021) 41:1487–501. doi: 10.1007/s10792-021-01712-5
24. Bian HX, Bian MT, Liu WH, Liu RY, Guo M. Efficiency analysis by mfERG and OCT of intravitreal injection with ranibizumab on diabetic macular edema. *Int. J Ophthalmol.* (2020) 13:1092–6. doi: 10.18240/ijo.2020.07.12
25. Li B, Fan K, Zhang T, Wu Z, Zeng S, Zhao M, et al. Efficacy and safety of biosimilar QL1207 vs. the reference Aflibercept for patients with Neovascular age-related macular degeneration: a randomized phase 3 trial. *Ophthalmol Ther.* (2023) 13:353–66. doi: 10.1007/s40123-023-00836-4
26. Zhu Z, Liang Y, Yan B, Meng Z, Long K, Zhang Y, et al. Clinical effect of conbercept on improving diabetic macular ischemia by OCT angiography. *BMC Ophthalmol.* (2020) 20:1648. doi: 10.1186/s12886-020-01648-x