

HYDRONEPHROSIS ASSOCIATED WITH URETEROPELVIC JUNCTION ANOMALIES: AN ONGOING CHALLENGE

EDITED BY: Abdurrahman Onen, Ali Avanoglu, Luis Henrique Braga and
Venkata R. Jayanthi

PUBLISHED IN: *Frontiers in Pediatrics* and *Frontiers in Surgery*



frontiers

Frontiers eBook Copyright Statement

The copyright in the text of individual articles in this eBook is the property of their respective authors or their respective institutions or funders. The copyright in graphics and images within each article may be subject to copyright of other parties. In both cases this is subject to a license granted to Frontiers.

The compilation of articles constituting this eBook is the property of Frontiers.

Each article within this eBook, and the eBook itself, are published under the most recent version of the Creative Commons CC-BY licence.

The version current at the date of publication of this eBook is CC-BY 4.0. If the CC-BY licence is updated, the licence granted by Frontiers is automatically updated to the new version.

When exercising any right under the CC-BY licence, Frontiers must be attributed as the original publisher of the article or eBook, as applicable.

Authors have the responsibility of ensuring that any graphics or other materials which are the property of others may be included in the CC-BY licence, but this should be checked before relying on the CC-BY licence to reproduce those materials. Any copyright notices relating to those materials must be complied with.

Copyright and source acknowledgement notices may not be removed and must be displayed in any copy, derivative work or partial copy which includes the elements in question.

All copyright, and all rights therein, are protected by national and international copyright laws. The above represents a summary only. For further information please read Frontiers' Conditions for Website Use and Copyright Statement, and the applicable CC-BY licence.

ISSN 1664-8714

ISBN 978-2-88976-184-5

DOI 10.3389/978-2-88976-184-5

About Frontiers

Frontiers is more than just an open-access publisher of scholarly articles: it is a pioneering approach to the world of academia, radically improving the way scholarly research is managed. The grand vision of Frontiers is a world where all people have an equal opportunity to seek, share and generate knowledge. Frontiers provides immediate and permanent online open access to all its publications, but this alone is not enough to realize our grand goals.

Frontiers Journal Series

The Frontiers Journal Series is a multi-tier and interdisciplinary set of open-access, online journals, promising a paradigm shift from the current review, selection and dissemination processes in academic publishing. All Frontiers journals are driven by researchers for researchers; therefore, they constitute a service to the scholarly community. At the same time, the Frontiers Journal Series operates on a revolutionary invention, the tiered publishing system, initially addressing specific communities of scholars, and gradually climbing up to broader public understanding, thus serving the interests of the lay society, too.

Dedication to Quality

Each Frontiers article is a landmark of the highest quality, thanks to genuinely collaborative interactions between authors and review editors, who include some of the world's best academicians. Research must be certified by peers before entering a stream of knowledge that may eventually reach the public - and shape society; therefore, Frontiers only applies the most rigorous and unbiased reviews.

Frontiers revolutionizes research publishing by freely delivering the most outstanding research, evaluated with no bias from both the academic and social point of view. By applying the most advanced information technologies, Frontiers is catapulting scholarly publishing into a new generation.

What are Frontiers Research Topics?

Frontiers Research Topics are very popular trademarks of the Frontiers Journals Series: they are collections of at least ten articles, all centered on a particular subject. With their unique mix of varied contributions from Original Research to Review Articles, Frontiers Research Topics unify the most influential researchers, the latest key findings and historical advances in a hot research area! Find out more on how to host your own Frontiers Research Topic or contribute to one as an author by contacting the Frontiers Editorial Office: frontiersin.org/about/contact

HYDRONEPHROSIS ASSOCIATED WITH URETEROPELVIC JUNCTION ANOMALIES: AN ONGOING CHALLENGE

Topic Editors:

Abdurrahman Onen, Onen Pediatric Urology Center, Turkey

Ali Avanoglu, Ege University, Turkey

Luis Henrique Braga, McMaster University, Canada

Venkata R. Jayanthi, Nationwide Children's Hospital, United States

Citation: Onen, A., Avanoglu, A., Braga, L. H., Jayanthi, V. R., eds. (2022).

Hydronephrosis Associated With Ureteropelvic Junction Anomalies: An Ongoing Challenge. Lausanne: Frontiers Media SA. doi: 10.3389/978-2-88976-184-5

Table of Contents

- 05 *Using Deep Learning Algorithms to Grade Hydronephrosis Severity: Toward a Clinical Adjunct***
Lauren C. Smail, Kiret Dhindsa, Luis H. Braga, Suzanna Becker and Ranil R. Sonnadara
- 13 *Embryology and Morphological (Mal)Development of UPJ***
Ali Avanoglu and Sibel Tiriyaki
- 16 *Managing Ureteropelvic Junction Obstruction in the Young Infant***
Niccolo Maria Passoni and Craig Andrew Peters
- 28 *Searching for the Least Invasive Management of Pelvi-Ureteric Junction Obstruction in Children: A Critical Literature Review of Comparative Outcomes***
Marco Castagnetti, Massimo Iafrate, Ciro Esposito and Ramnath Subramaniam
- 34 *Ultrasound-Based Scoring System for Indication of Pyeloplasty in Patients With UPJO-Like Hydronephrosis***
Bruce Li, Melissa McGrath, Forough Farrokhyar and Luis H. Braga
- 42 *Commentary: Ultrasound-Based Scoring System for Indication of Pyeloplasty in Patients With UPJO-Like Hydronephrosis***
Abdurrahman Onen
- 45 *Grading of Hydronephrosis: An Ongoing Challenge***
Abdurrahman Onen
- 58 *Prenatal Diagnosis and Findings in Ureteropelvic Junction Type Hydronephrosis***
Recep Has and Tugba Sarac Sivriköz
- 68 *Urinary Ultrasound and Other Imaging for Ureteropelvic Junction Type Hydronephrosis (UPJHN)***
Ayse Kalyoncu Ucar and Sebuhan Kurugoglu
- 84 *Symptomatology and Clinic of Hydronephrosis Associated With Uretero Pelvic Junction Anomalies***
Ilmay Bilge
- 92 *Redo Laparoscopic Pyeloplasty in Infants and Children: Feasible and Effective***
Hamdan Al-Hazmi, Matthieu Peycelon, Elisabeth Carricaburu, Gianantonio Manzoni, Khalid Fouda Neel, Liza Ali, Christine Grapin, Annabel Paye-Jaouen and Alaa El-Ghoneimi
- 98 *Early Robotic-Assisted Laparoscopic Pyeloplasty for Infants Under 3 Months With Severe Ureteropelvic Junction Obstruction***
Pin Li, Huixia Zhou, Hualin Cao, Tao Guo, Weiwei Zhu, Yang Zhao, Tian Tao, Xiaoguang Zhou, Lifei Ma, Yunjie Yang and Zhichun Feng
- 104 *Hydronephrosis Classifications: Has UTD Overtaken APD and SFU? A Worldwide Survey***
Santiago Vallasciani, Anna Bujons Tur, John Gatti, Marcos Machado, Christopher S. Cooper, Marie Klaire Farrugia, Huixia Zhou, Mohammed El Anbari and Pedro-José Lopez

- 111** *Comparing Robot-Assisted Laparoscopic Pyeloplasty vs. Laparoscopic Pyeloplasty in Infants Aged 12 Months or Less*
Yuenshan Sammi Wong, Kristine Kit Yi Pang and Yuk Him Tam
- 117** *Variations in the Density and Distribution of Cajal Like Cells Associated With the Pathogenesis of Ureteropelvic Junction Obstruction: A Systematic Review and Meta-Analysis*
U. M. J. E. Samaranayake, Y. Mathangasinghe, U. A. Liyanage, M. V. C. de Silva, M. C. Samarasinghe, S. Abeygunasekera, A. K. Lamahewage and A. P. Malalasekera
- 129** *Meta-Analysis of the Efficacy of Laparoscopic Pyeloplasty for Ureteropelvic Junction Obstruction via Retroperitoneal and Transperitoneal Approaches*
Fengming Ji, Li Chen, Chengchuang Wu, Jinrong Li, Yu Hang and Bing Yan
- 137** *Comparison of Drainage Methods After Pyeloplasty in Children: A 14-Year Study*
Xiangpan Kong, Zhenpeng Li, Mujie Li, Xing Liu and Dawei He



Using Deep Learning Algorithms to Grade Hydronephrosis Severity: Toward a Clinical Adjunct

Lauren C. Smail^{1,2}, Kiret Dhindsa^{3,4,5}, Luis H. Braga^{6,7,8*}, Suzanna Becker^{1,5,9} and Ranil R. Sonnadara^{1,2,3,4,5,9}

¹ Department of Psychology, Neuroscience & Behaviour, McMaster University, Hamilton, ON, Canada, ² Office of Education Science, McMaster University, Hamilton, ON, Canada, ³ Department of Surgery, McMaster University, Hamilton, ON, Canada, ⁴ Research and High Performance Computing, McMaster University, Hamilton, ON, Canada, ⁵ Vector Institute for Artificial Intelligence, Toronto, ON, Canada, ⁶ Division of Urology, Department of Surgery, McMaster University, Hamilton, ON, Canada, ⁷ Division of Urology, Department of Surgery, McMaster Children's Hospital, Hamilton, ON, Canada, ⁸ McMaster Pediatric Surgery Research Collaborative, McMaster University, Hamilton, ON, Canada, ⁹ Centre for Advanced Research in Experimental and Applied Linguistics, McMaster University, Hamilton, ON, Canada

OPEN ACCESS

Edited by:

Alberto Parente,
Consultant, Córdoba, Spain

Reviewed by:

Sherry Ross,
University of North Carolina at Chapel
Hill, United States
Osama Mahmoud Sarhan,
Mansoura University, Egypt

*Correspondence:

Luis H. Braga
braga@mcmaster.ca

Specialty section:

This article was submitted to
Pediatric Urology,
a section of the journal
Frontiers in Pediatrics

Received: 26 August 2019

Accepted: 06 January 2020

Published: 29 January 2020

Citation:

Smail LC, Dhindsa K, Braga LH,
Becker S and Sonnadara RR (2020)
Using Deep Learning Algorithms to
Grade Hydronephrosis Severity:
Toward a Clinical Adjunct.
Front. Pediatr. 8:1.
doi: 10.3389/fped.2020.00001

Grading hydronephrosis severity relies on subjective interpretation of renal ultrasound images. Deep learning is a data-driven algorithmic approach to classifying data, including images, presenting a promising option for grading hydronephrosis. The current study explored the potential of deep convolutional neural networks (CNN), a type of deep learning algorithm, to grade hydronephrosis ultrasound images according to the 5-point Society for Fetal Urology (SFU) classification system, and discusses its potential applications in developing decision and teaching aids for clinical practice. We developed a five-layer CNN to grade 2,420 sagittal hydronephrosis ultrasound images [191 SFU 0 (8%), 407 SFU I (17%), 666 SFU II (28%), 833 SFU III (34%), and 323 SFU IV (13%)], from 673 patients ranging from 0 to 116.29 months old ($M_{\text{age}} = 16.53$, $SD = 17.80$). Five-way (all grades) and two-way classification problems [i.e., II vs. III, and low (0–II) vs. high (III–IV)] were explored. The CNN classified 94% (95% CI, 93–95%) of the images correctly or within one grade of the provided label in the five-way classification problem. Fifty-one percent of these images (95% CI, 49–53%) were correctly predicted, with an average weighted F1 score of 0.49 (95% CI, 0.47–0.51). The CNN achieved an average accuracy of 78% (95% CI, 75–82%) with an average weighted F1 of 0.78 (95% CI, 0.74–0.82) when classifying low vs. high grades, and an average accuracy of 71% (95% CI, 68–74%) with an average weighted F1 score of 0.71 (95% CI, 0.68–0.75) when discriminating between grades II vs. III. Our model performs well above chance level, and classifies almost all images either correctly or within one grade of the provided label. We have demonstrated the applicability of a CNN approach to hydronephrosis ultrasound image classification. Further investigation into a deep learning-based clinical adjunct for hydronephrosis is warranted.

Keywords: hydronephrosis, machine learning, deep learning, ultrasound, diagnostic imaging, grading, diagnostic aid, teaching aid

INTRODUCTION

Machine learning is a field of research with far reaching applications that is generating considerable interest in medicine (1, 2). Deep learning, a subset of machine learning, is a general term for an algorithm that trains a many layered network to learn hierarchical feature representations from raw data. Due to the hierarchical nature of deep learning models, complex functions can be learned to solve difficult classification problems that were previously unsolvable by classic machine learning algorithms (3). Deep convolutional neural networks (CNNs) are a type of deep learning algorithm that are well-suited to computer vision tasks (3) due to their ability to take advantage of the multi-scale spatial structure of images (4). This makes CNN models an attractive candidate architecture for tackling medical imaging problems. In particular, they offer a promising avenue for creating clinical adjuncts to help train physicians, and flag/grade challenging diagnostic cases.

Prenatal hydronephrosis (HN) is a condition that involves accumulation of urine with consequent dilatation of the collecting system in fetuses. It is the most frequent neonatal urinary tract abnormality, occurring in 1–5% of all newborn babies (5). HN is detected by prenatal ultrasound (US) imaging and can be caused by several underlying conditions, such as uteropelvic junction obstruction or vesico-ureteral reflux (6). Although many cases eventually resolve on their own, in severe forms, afflicted infants may require surgical intervention (7, 8), and failure to intervene can result in loss of renal function (9, 10).

All patients with prenatal HN are normally evaluated after birth by postnatal renal ultrasonography to determine HN severity and the best course of treatment. Appropriate HN grading is important, as misclassification of any patient into the inappropriate HN category can lead to incorrect management and unnecessary testing since treatment is directly dependent on HN severity. Given the need for accurate and unambiguous classification of HN, numerous HN grading systems have been developed (11). However, poor inter-rater reliability (12, 13), particularly for intermediate HN grades, suggests that grading still relies on subjective interpretation of ultrasound images, as clear and objective criteria have not been fully established.

Owing to the ability of deep learning algorithms to classify images into diagnostic categories based solely on data-driven pattern recognition, the main purpose of this study was to extend on our previous work (14) to investigate whether deep learning algorithms can effectively grade the severity of HN using a prospectively collected HN database and separate them into 5 main classes. Secondary investigations were also conducted to assess whether the same model can effectively discriminate between low and high HN grades (SFU 0, I, II vs. III, IV), and between moderate (SFU II vs. III) cases. The results of this study may provide important insights into whether deep learning is a promising avenue of future study for discriminating different grades of HN, and developing clinical adjuncts. Given that our models were trained on images with human expert-generated training labels, we hypothesized that our deep learning model would perform at or very close to that of a human expert at HN grading. This would validate our method as a potential

training tool for medical students and as an adjunctive tool for clinical experts.

MATERIALS AND METHODS

Study Population and Exclusion Criteria

Our database consists of 2-dimensional renal B-mode US images from an ongoing large prospective cohort study involving all patients diagnosed with prenatal HN who were referred to a tertiary care pediatric hospital. The database contains one sagittal US image per patient visit, spanning 687 patients. Each image was assigned a grade according to the Society for Fetal Urology (SFU) system, one of the most widely adopted HN classification systems (15), ranging from 0 (normal kidney) to IV (severe HN with parenchymal thinning). Grades were provided by three separate physicians (2 fellowship trained pediatric urologists and 1 fellowship trained pediatric radiologist—agreement $K = 90\%$) with discrepancies resolved by consensus. From these 687 patients, 2,492 sagittal renal US images were collected. Seventy-two images from 14 patients were excluded due to poor image quality (e.g., blurry, large annotation overlaid, no visible kidney), leaving 2,420 sagittal US images from 673 patients ($N_{\text{female}} = 159$, $N_{\text{male}} = 514$) ranging from 0 to 116.29 months old ($M_{\text{age}} = 16.53$, $SD = 17.80$) to be included in the analysis. Of these, 191 were labeled as SFU 0, 407 as SFU I, 666 as SFU II, 833 as SFU III, and 323 as SFU IV. Ethics clearance for this study was obtained through the Research Ethics Board.

Preprocessing

Preprocessing is a crucial step in machine learning, as standardizing images and taking simple steps to reduce noise and non-discriminative variability improves the ability of models to learn relevant information. In this study, all images were cropped to remove any annotations and blank space in the margins. The images were then despeckled using the bi-directional FIR-median hybrid despeckling filter to remove speckle noise from the images (16). Despeckling is a standard preprocessing technique for US images since speckle noise is caused by interference between the US probe and reflecting US waves. Finally, the image pixel values were normalized between 0 and 1, and all images resized to 256×256 pixels to provide a consistent image input size into our network. The final image size was chosen based on the smallest dimension of the cropped images to ensure that images were not stretched.

Data augmentation is a common approach to reducing overfitting and improving classification performance for small datasets (3, 17). It works by introducing variations on each image during training so as to build robustness into the model. In this study, we augment the data by rotating each image up to 45° , performing horizontal and vertical flips with a 50% probability, and shifting the image vertically and horizontally up to 20%.

Model Architecture

A CNN is a type of neural network that has been particularly successful in computer vision applications. CNNs are constructed from alternating convolutional layers and pooling layers. The structure of a CNN is inspired by that of the mammalian visual

system, where earlier cortical areas receive input from small regions of the retina and learn simple local features such as edges, while regions at progressively higher levels in the visual system have correspondingly broader receptive fields, and learn complex features such as shape detectors. In a CNN, convolutional layers learn multiple local features of an image by processing it across many overlapping patches, while pooling layers summate the filter responses from the previous layer, thereby compressing the representations learned by the preceding convolutional layer to force the model to filter out unimportant visual information. As in the visual system, successive convolutional layers have progressively larger receptive fields, permitting more complex, and abstract image features to be learned in higher layers of the network. In classification models a standard multilayer perceptron, made up of a few fully connected layers of neurons (called dense layers) receives the learned image representation from the convolutional layers and attempts to classify the image. The entire network is trained using backpropagation, a neural network learning procedure which iteratively updates the strengths of the connections between layers of neurons in order to minimize classification error on the training data. For a detailed explanation of how CNNs work and are designed, see Le Cun et al. (18).

The CNN model used in the current study was developed using the Keras neural network API with Tensorflow (19, 20). The final architecture contained five convolutional layers, a fully connected layer of 400 units, and a final output layer where the number of units was equal to the number of classes for the given task (i.e., five or two) (Figure 1). The architecture was determined by experimenting with five-way SFU HN classification. The output unit/class with the highest overall final activation was used as the model's prediction and was compared against the provided label to assess performance. See **Supplementary Materials** for a description of all technical details.

Model Training and Evaluation

Five-way (all SFU grades) and binary classification tests were conducted using 5-fold cross validation. See **Supplementary Materials** for a description of this process. The binary classification tests were selected due to their clinical relevance and included distinguishing between mild (0, I, and II) and severe (III and IV) HN grades, and between moderate grades (II vs. III). Layer-wise relevant propagation (21) was used to visualize model output.

RESULTS

Our model achieved an average five-way classification accuracy of 51% (95% CI, 49–53%), and an average weighted F1 score of 0.49 (95% CI, 0.47–0.51). Furthermore, 94% (95% CI, 93–95%) of images were either correctly classified or within one grade of the provided label (Figure 2).

Our model classified mild vs. severe HN with an average accuracy of 78% (95% CI, 75–82%), and an average weighted F1 of 0.78 (95% CI, 0.74–0.82). When differentiating between moderate grades (SFU II and III), our model achieved an average accuracy of 71% (95% CI, 68–74%) and an average weighted F1 score of 0.71 (95% CI, 0.68–0.75). See **Table 1** for a comprehensive overview of model performance.

		Predicted				
		0	I	II	III	IV
Actual	0	20 (0.83%)	114 (4.71%)	50 (2.10%)	7 (0.29%)	0 (0%)
	I	20 (0.83%)	159 (6.57%)	190 (7.85%)	34 (1.40%)	4 (0.17%)
	II	8 (0.33%)	121 (5.00%)	357 (14.75%)	179 (7.40%)	1 (0.04%)
	III	0 (0%)	21 (0.87%)	198 (8.18%)	540 (22.31%)	74 (3.06%)
	IV	2 (0.08%)	6 (0.25%)	7 (0.29%)	160 (6.61%)	148 (6.12%)

FIGURE 2 | The confusion matrix of the CNN model. Boxes along the diagonal in gray represent the number (percentage) of cases where the CNN made the correct classification decision. Light gray boxes represent the cases where the CNN was incorrect by one grade, and white boxes indicate cases where the CNN was incorrect by two or more grades.

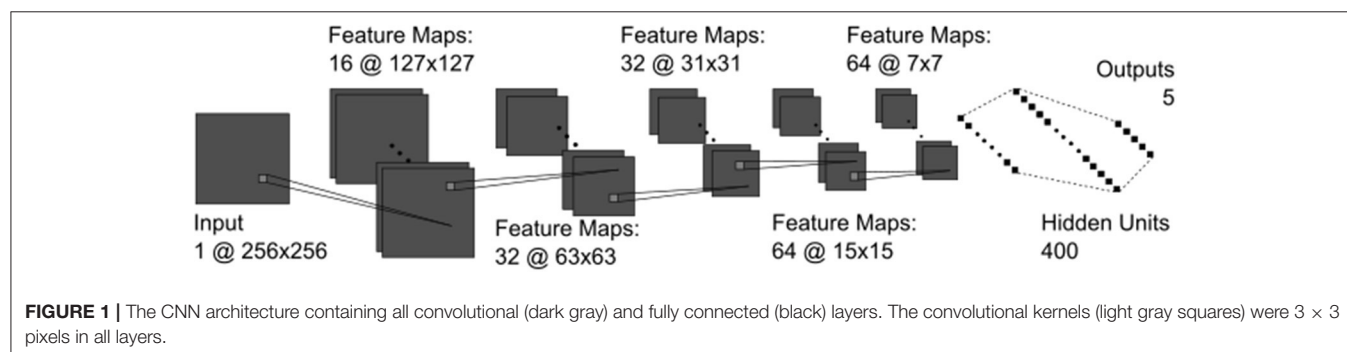


TABLE 1 | CNN model classification results averaged across the 5-folds.

Classification problem	Accuracy (%)	Sensitivity	Specificity	PPV	F1
Five-way (0 to IV)	51 (49–53)				0.49 (0.47–0.51) ^a
SFU 0		0.11 (0–0.21)	0.99 (0.97–1.00)	0.26 (0.05–0.47)	0.15 (0.01–0.29)
SFU 1		0.39 (0.35–0.43)	0.87 (0.84–0.90)	0.39 (0.34–0.44)	0.38 (0.35–0.42)
SFU II		0.54 (0.43–0.65)	0.75 (0.72–0.79)	0.45 (0.42–0.49)	0.48 (0.43–0.53)
SFU III		0.65 (0.60–0.70)	0.76 (0.74–0.78)	0.59 (0.53–0.65)	0.61 (0.56–0.66)
SFU IV		0.46 (0.29–0.62)	0.96 (0.94–0.98)	0.65 (0.54–0.75)	0.52 (0.38–0.66)
Mild (0, I, II) vs. Severe (III, IV)	78 (75–82)				0.78 (0.74–0.82) ^a
Mild		0.89 (0.82–0.96)	0.66 (0.51–0.81)	0.75 (0.69–0.81)	0.81 (0.78–0.84)
Severe		0.66 (0.51–0.81)	0.89 (0.82–0.96)	0.87 (0.80–0.94)	0.73 (0.64–0.82)
SFU II vs. SFU III	71 (68–74)				0.71 (0.68–0.75) ^a
SFU II		0.76 (0.60–0.92)	0.67 (0.52–0.82)	0.67 (0.59–0.75)	0.69 (0.63–0.75)
SFU III		0.67 (0.52–0.82)	0.76 (0.60–0.92)	0.80 (0.73–0.87)	0.71 (0.65–0.77)

The 95% confidence intervals are given in parentheses.

^aWeighted average.

DISCUSSION

We investigated the potential of deep CNN to create clinical adjuncts for HN. This was achieved by testing our model's ability to classify HN US images. We tested our model's performance on three different classification tasks that are relevant to clinical practice. These results, along with their potential clinical implications, are discussed below.

Five-Way Classification Performance

Our model achieved an average five-way classification accuracy that was well above chance level (51%). In practice, physicians usually have access to multiple different US images at different angles, as well as patient histories, and are therefore able to grade the US image by combining information from multiple views and timepoints. Although we are unable to compare our model's performance directly to a physician, achieving this level of accuracy with a single US image is very promising.

The model classified 94% (95% CI, 93–95%) of images either correctly or within one grade of the correct/provided label. Further investigation into the output of our model reveals that there are many borderline images where there is not an obvious choice for which class the image belongs to (e.g., **Figures 3A,C**). In cases such as these where two grades possible are, it must choose a single HN grade according to the SFU system, much like a physician (12, 13).

Considering that HN grading can be challenging, and that subjective assessments are used to differentiate between borderline cases (12, 13), we would argue that solely relying on whether the model's predictions matched the provided SFU labels is an incomplete assessment of our model's performance. Instead, the percentage of cases that are either "correct" or within one grade of the provided label (94%) is a more representative metric of our model's true performance. The nearly block-diagonal structure of the confusion matrix supports this (**Figure 2**) and indicates that the model is learning useful information for HN classification.

Binary Classification Performance

Discriminating between moderate HN grades is known to be challenging (12, 13), and therefore we wanted to investigate our model's performance on this same task. When comparing mild (0, I, II) and severe (III, IV) HN images, our model achieved an average accuracy of 78%, which is well above chance level. When the model discriminated between moderate grades (II and III), which is less reliable for physicians (12, 13), performance only dropped to 71%. There is no direct comparison to be made against physician accuracy, however, considering the known difficulties in distinguishing between moderate HN grades (12, 13), these results are encouraging.

Interpretability

We visualized regions of the HN US images that the CNN found important for five-way classification in a sample of images using layer-wise relevance propagation (21) from the DeepExplain toolbox (22). Layer-wise relevance propagation allows us to determine which features in the image contribute most strongly to the CNNs output (**Figure 3B**). Cyan pixels indicate that the model heavily relied on those features to classify the image. Visualizing can be used to validate whether our model is learning appropriate features that correspond with the SFU grading system and interpret its inner workings. Interpretability is crucial as we develop deep learning based clinical adjuncts since physicians will need to be able to understand why a model made a decision, rather than just blindly following the algorithm.

Of the examples we tested, we can see that our model is learning features that correspond appropriately with the SFU system (e.g., renal parenchyma, calyces), however, in some cases it is also relying on regions outside of the kidney. This can likely be attributed to image noise, and therefore removing the noise with segmentation (i.e., finding regions of interest in the image) would ensure that the model is only relying on appropriate regions for classification. However,

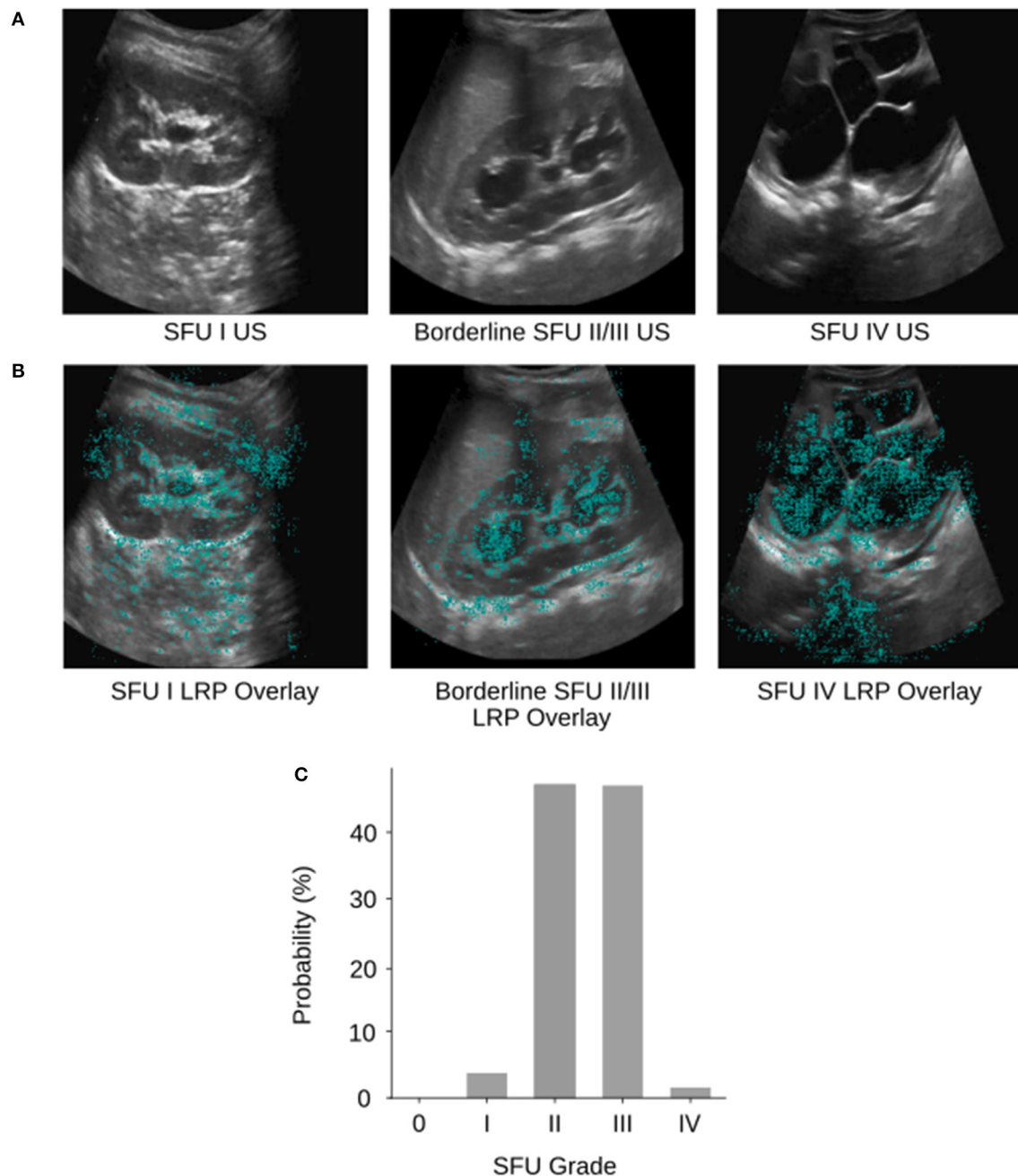


FIGURE 3 | (A) Example SFU I, borderline SFU II/III, and SFU IV US images from the database. **(B)** The corresponding layerwise relevance propagations of each of the example images. Layer-wise relevance propagations give a sparse representation of pixel importance. Propagations were visualized as heat maps and overlaid on top of the gray-scale input US images. The cyan colored pixels indicate regions that the CNN heavily relied upon for classification. **(C)** The corresponding softmax output probability distribution of the borderline SFU II/III US image. The image was labeled as SFU grade III by physicians; however, the CNN predicted SFU grade II which was incorrect. We can see based on the probability distribution that the model “thought” SFU grade II and III were almost equally likely but had to select one grade as its prediction. This behavior is analogous to that of physicians and can be partially explained by the poor inter-rater reliability and subjectivity of the SFU system (i.e., intrinsic limitations of that classification).

the model may be finding relevant features outside of those from the SFU classification system that are clinically relevant but not normally considered, and so this finding warrants further investigation.

Implications for Clinical Practice

Machine learning and deep learning models have been successfully applied in the context of HN to predict the need for surgical intervention (1), and the necessity of diuretic nuclear

renography (2). More broadly, machine learning and deep learning have been used in the field of pediatric urology to classify between different kidney diseases (23), and between diseased and normal kidneys (24). In addition, deep learning has recently been used to perform automatic kidney segmentation in ultrasound imaging (25). Due to the different problems being evaluated in each of the studies, a direct comparison in performance cannot be made. It is important to highlight that along with investigating different questions, and therefore having differing levels of chance performance (i.e., 50 vs. 20% in the current study), these studies also differ from the current study in that many of these papers are asking objective questions (e.g., Was surgery required?) and are therefore able to utilize objective labels in their models. As discussed previously, the lack of objective ground truth in the current study presents challenges in interpreting the true performance of our model, and likely contributes to our model's lower accuracy metric as compared to other papers.

Considering the issue of subjectivity, our model's current level of performance in classifying HN is promising and in line with previous research from our group (14). Our findings suggest that applying these algorithms into clinical practice through decision aids and teaching aids has potential. It is important to clarify that we anticipate that deep learning models like the one presented here will 1 day be used to support physicians rather than replace them, as human-level reliability and generalizability remains a major challenge for medical applications (26). We outline below two new ways that we expect deep learning models can be applied to benefit clinical practice in the future.

Decision Aids

In clinical practice, decision aids are used to assess the structure of interest, and then provide its estimate of disease probability. Physicians are then free to use this estimate as they wish. To our knowledge, patient management is always left up to the physician, and the aids act more like a second opinion. Studies have shown that the combined synergistic effects of the decision aid and physician knowledge greatly improved the diagnostic accuracy (27). In the context of HN, we expect that the second opinion from the decision aid would be particularly useful for borderline cases, since currently consensus decisions are required to resolve these cases.

Teaching Aids

Deep learning models can also be used to develop teaching aids for trainees to teach and provide them with feedback on how to grade HN US images. These teaching features can be created by exploiting the rich information that these algorithms contain. For example, a deep learning-based teaching aid could provide trainees with informative feedback based on the inner workings of the algorithm to tell trainees whether their diagnosis was correct. Furthermore, the teaching aid could highlight parts of the image with a heat-map using visualization methods, such as layer-wise relevance propagation, to indicate which regions were of clinical importance, and to what degree. A teaching aid would alleviate at least some

of the need for direct physician feedback and would allow trainees to work through examples at their own pace to maximize learning.

Limitations and Future Work

Considering that the current dataset was small by deep learning standards, slightly imbalanced, and only contained one image per patient visit, our model still achieved moderate to good accuracy across the different classification problems. This suggests that a richer and larger dataset could lead to even better performance and an eventual deep learning based clinical adjunct for HN. Future work should also investigate HN classification at the patient level and consider the time series in the data. HN patients are followed across time, and the trends in their HN severity provide physicians with important information that is incorporated into their clinical decision making. We would expect that providing a deep learning model with time series data would benefit model performance as well. Additionally, a model could convey its level of uncertainty in its diagnosis, flagging to the physician that this image merited a closer examination or additional measurements.

We applied relatively little preprocessing to our images, therefore future studies should investigate whether segmentation, a commonly recommended preprocessing technique, reduces model noise and improves performance (25). Within the current classification model, layer-wise relevance propagation revealed that regions outside of the kidney were contributing to model output. Further investigation on the impact of segmentation whereby the model is constrained to extract features from the kidney that correspond with the SFU grading system should elucidate whether these findings are attributable to image noise or useful features.

CONCLUSIONS

The purpose of the current study was to explore whether deep learning can effectively classify HN US images and separate them into 5 main categories. Overall, our model performs well above chance level across all classifications, categorizing images either correctly, or within one grade of the provided label. The model was also capable of discriminating well between mild and severe grades of HN, which has important clinical implications. The results of the current study suggest that CNNs can be applied to grade HN US images effectively, and that further investigation into using deep learning to grade HN US images is warranted. With further model refinement, and by addressing the limitations of our current data set, we expect that our model can be used to develop effective clinical adjuncts to improve clinical practice.

DATA AVAILABILITY STATEMENT

The datasets generated for this study are available on request to the corresponding author.

ETHICS STATEMENT

The studies involving human participants were reviewed and approved by Hamilton Integrated Research Ethics Board. Written informed consent to participate in this study was provided by the participants' legal guardian/next of kin.

AUTHOR CONTRIBUTIONS

LS was responsible for data analysis and writing the first draft of the manuscript. LB provided clinical oversight for the project, and was responsible for acquisition and curation of the dataset used for model training. All authors were responsible for the design of the study, interpretation of the data, and writing the final manuscript.

FUNDING

This research was supported by the Department of Surgery of McMaster University, the MacDATA Institute Graduate Fellowship Program of McMaster University, the Michael DeGroote Fellowship for Clinical Research, and the National Sciences and Engineering Research Council of Canada (RGPIN-2019-07276).

SUPPLEMENTARY MATERIAL

The Supplementary Material for this article can be found online at: <https://www.frontiersin.org/articles/10.3389/fped.2020.00001/full#supplementary-material>

REFERENCES

- Lorenzo AJ, Rickard M, Braga LH, Guo Y, Oliveria JP. Predictive analytics and modeling employing machine learning technology: the next step in data sharing, analysis and individualized counseling explored with a large, prospective prenatal hydronephrosis database. *Urology*. (2018) 123:204–9. doi: 10.1016/j.urol.2018.05.041
- Cerrolaza JJ, Peters CA, Martin AD, Myers E, Safdar N, Linguraru MG. Quantitative ultrasound for measuring obstructive severity in children with hydronephrosis. *J Urol*. (2016) 195:1093–9. doi: 10.1016/j.juro.2015.10.173
- Krizhevsky A, Sutskever I, Hinton GE. ImageNet classification with deep convolutional neural networks. In: Pereira F, Burges CJC, Bottou L, Weinberger KQ, editors. *Advances in Neural Information Processing Systems* 25. Lake Tahoe, NV: Curran Associates Inc. (2012). p. 1097–105.
- Le Cun Y, Bottou L, Bengio Y, Haffner P. Gradient-based learning applied to document recognition. *Proc IEEE*. (1998) 86:2278–324. doi: 10.1109/5.726791
- Woodward M, Frank D. Postnatal management of antenatal hydronephrosis. *BJU Int*. (2002) 89:149–56. doi: 10.1046/j.1464-4096.2001.woodward.2578.x
- Montini G, Tullus K, Hewitt I. Febrile urinary tract infections in children. *N Engl J Med*. (2011) 365:239–50. doi: 10.1056/NEJMr1007755
- Yang Y, Hou Y, Niu ZB, Wang CL. Long-term follow-up and management of prenatally detected, isolated hydronephrosis. *J Pediatr Surg*. (2010) 45:1701–6. doi: 10.1016/j.jpedsurg.2010.03.030
- Braga LH, McGrath M, Farrokhkar F, Jegatheeswaran K, Lorenzo AJ. Associations of initial society for fetal urology grades and urinary tract dilatation risk groups with clinical outcomes in patients with isolated prenatal hydronephrosis. *J Urol*. (2017) 197:831–7. doi: 10.1016/j.juro.2016.08.099
- González R, Schimke CM. The prenatal diagnosis of hydronephrosis, when and why to operate? *Arch Esp Urol*. (1998) 51:575–9.
- Hanna MK. Antenatal hydronephrosis and ureteropelvic junction obstruction: the case for early intervention. *Urology*. (2000) 55:612–5. doi: 10.1016/S0090-4295(00)00460-X
- Nguyen HT, Benson CB, Bromley B, Campbell JB, Chow J, Coleman B, et al. Multidisciplinary consensus on the classification of prenatal and postnatal urinary tract dilation (UTD classification system). *J Pediatr Urol*. (2014) 10:982–98. doi: 10.1016/j.jpuro.2014.10.002
- Rickard M, Easterbrook B, Kim S, Farrokhkar F, Stein N, Arora S, et al. Six of one, half a dozen of the other: a measure of multidisciplinary inter/intra-rater reliability of the society for fetal urology and urinary tract dilation grading systems for hydronephrosis. *J Pediatr Urol*. (2017) 13:80.e1–5. doi: 10.1016/j.jpuro.2016.09.005
- Keays MA, Guerra LA, Mihill J, Raju G, Al-Asheeri N, Geier P, et al. Reliability assessment of society for fetal urology ultrasound grading system for hydronephrosis. *J Urol*. (2008) 180:1680–3. doi: 10.1016/j.juro.2008.03.107
- Dhindsa K, Smail LC, McGrath M, Braga LH, Becker S, Sonnadara RR. Grading prenatal hydronephrosis from ultrasound imaging using deep convolutional neural networks. In: *15th Conference on Computer and Robot Vision*. Toronto, ON: IEEEExplore (2018). p. 80–7. Available online at: <https://bibbase.org/network/publication/dhindsa-smail-mcgrath-braga-becker-sonnadara-gradingprenatalhydronephrosisfromultrasoundimagingusingdeepconvolutionalneuralnetworks-2018> (accessed July 12, 2018).
- Nguyen HT, Herndon CDA, Cooper C, Gatti J, Kirsch A, Kokorowski P, et al. The society for fetal urology consensus statement on the evaluation and management of antenatal hydronephrosis. *J Pediatr Urol*. (2010) 6:212–31. doi: 10.1016/j.jpuro.2010.02.205
- Nieminen A, Heinonen P, Neuvo Y. A new class of detail-preserving filters for image processing. *IEEE Trans Pattern Anal Mach Intell*. (1987) 9:74–90. doi: 10.1109/TPAMI.1987.4767873
- Simard PY, Steinkraus D, Platt JC. Best practices in convolutional neural networks applied to visual document analysis. In: *Seventh International Conference on Document Analysis and Recognition, 2003* (Edinburgh) (2003). p. 958–62. doi: 10.1109/ICDAR.2003.1227801
- Le Cun Y, Bengio Y, Hinton G. Deep learning. *Nature*. (2015) 521:436–44. doi: 10.1038/nature14539
- Chollet F. *Keras* (2015). Available online at: <http://keras.io> (accessed September 20, 2018).
- Abadi M, Agarwal A, Barham P, Brevdo E, Chen Z, Citro C, et al. *TensorFlow: Large-Scale Machine Learning on Heterogeneous Distributed Systems* (2016). Available online at: <http://arxiv.org/abs/1603.04467> (accessed March 14, 2019).
- Bach S, Binder A, Montavon G, Klauschen F, Müller KR, Samek W. On pixel-wise explanations for non-linear classifier decisions by layer-wise relevance propagation. *PLoS ONE*. (2015) 10:e0130140. doi: 10.1371/journal.pone.0130140
- Ancona M, Ceolini E, Öztireli C, Gross M. *Towards Better Understanding of Gradient-Based Attribution Methods for Deep Neural Networks* (2017). Available online at: <http://arxiv.org/abs/1711.06104> (accessed September 20, 2018).
- Yin S, Peng Q, Li H, Zhang Z, You X, Liu H, et al. Multi-instance deep learning with graph convolutional neural networks for diagnosis of kidney diseases using ultrasound imaging. In: Greenspan H, Tanno R, Erdt M, Arbel T, Baumgartner C, Dalca A, et al., editors. *Uncertainty for Safe Utilization of Machine Learning in Medical Imaging and Clinical Image-Based Procedures*. Cham: Springer International Publishing (2019). p. 146–54.
- Zheng Q, Furth SL, Tasian GE, Fan Y. Computer-aided diagnosis of congenital abnormalities of the kidney and urinary tract in children based on ultrasound imaging data by integrating texture image features and deep transfer learning image features. *J Pediatr Urol*. (2019) 15:75.e1–7. doi: 10.1016/j.jpuro.2018.10.020

25. Sivanesan U, Braga LH, Sonnadara RR, Dhindsa K. *Unsupervised Medical Image Segmentation with Adversarial Networks: From Edge Diagrams to Segmentation Maps* (2019). Available online at: <http://arxiv.org/abs/1911.05140> (accessed December 03, 2019).
26. Dhindsa K, Bhandari M, Sonnadara RR. What's holding up the big data revolution in healthcare? *BMJ*. (2018) 363:k5357. doi: 10.1136/bmj.k5357
27. Doi K. Computer-aided diagnosis in medical imaging: historical review, current status and future potential. *Comput Med Imaging Graph*. (2007) 31:198–211. doi: 10.1016/j.compmedimag.2007.02.002

Conflict of Interest: The authors declare that the research was conducted in the absence of any commercial or financial relationships that could be construed as a potential conflict of interest.

Copyright © 2020 Smail, Dhindsa, Braga, Becker and Sonnadara. This is an open-access article distributed under the terms of the Creative Commons Attribution License (CC BY). The use, distribution or reproduction in other forums is permitted, provided the original author(s) and the copyright owner(s) are credited and that the original publication in this journal is cited, in accordance with accepted academic practice. No use, distribution or reproduction is permitted which does not comply with these terms.



Embryology and Morphological (Mal)Development of UPJ

Ali Avanoglu^{1*} and Sibel Tiryaki²

¹ Division of Pediatric Urology, Department of Pediatric Surgery, Ege University, Izmir, Turkey, ² Gaziantep Maternity and Children's Hospital, Pediatric Urology, Gaziantep, Turkey

Kidney parenchyma and collecting system arise from two different embryologic units as a result of a close interaction between them. Therefore, their congenital abnormalities are classified together under the same heading named CAKUT (congenital abnormalities of the kidney and urinary tract). The pathogenesis of CAKUT is thought to be multifactorial. Ureteropelvic junction obstruction (UPJO) is the most common and most investigated form of CAKUT. Despite years of experimental and clinical research, and the information gained on the embryogenesis of the kidney; its etiopathogenesis is still unclear. It involves both genetic and environmental factors. Failure in development of the renal pelvis, failure in the recanalization of ureteropelvic junction, abnormal pyeloureteral innervation, and impaired smooth muscle differentiation are the main proposed mechanisms for the occurrence of UPJO. There are also single gene mutations like AGTR2, BMP4, Id2 proposed in the etiopathogenesis of UPJO.

OPEN ACCESS

Edited by:

Alberto Parente,
Consultant, Córdoba, Spain

Reviewed by:

Huixia Zhou,
Bayi Children's Hospital, China
Andres Gomez Fraile,
University Hospital October 12, Spain

*Correspondence:

Ali Avanoglu
ali.avanoglu@gmail.com

Specialty section:

This article was submitted to
Pediatric Urology,
a section of the journal
Frontiers in Pediatrics

Received: 27 January 2020

Accepted: 11 March 2020

Published: 07 April 2020

Citation:

Avanoglu A and Tiryaki S (2020)
Embryology and Morphological
(Mal)Development of UPJ.
Front. Pediatr. 8:137.
doi: 10.3389/fped.2020.00137

Keywords: ureteropelvic junction obstruction, embryology, genetics, congenital anomalies of the kidney and urinary tract, BMP4

INTRODUCTION

The role of embryology in medical education is often underrated. Even clinicians dealing with congenital abnormalities consider in-depth knowledge on embryology unnecessary. Studies about urinary tract obstruction date back to forties (1), but there is still scarce information on how ureteropelvic junction obstruction (UPJO) develops. We believe, clinicians and embryologists shall work together to obtain further progress. The aim of this review is to demystify the current knowledge on the embryo-pathogenesis of UPJO to clinicians to promote future research.

THE CONCEPT OF CAKUT

Congenital anomalies of the kidney and urinary tract (CAKUT) refer to all the developmental abnormalities of kidney and ureter (2). The concept of CAKUT is based on the close interaction of the ureteric bud and metanephric mesenchyme in the development of kidney and ureter.

The main steps in the formation of the metanephric kidney and ureter are; formation of the ureteric bud from the Wolffian duct, its dorsal growth into the caudal portion of the nephric cord and branching of the ureter when it invades the mesenchyme. This appositional growth continues until the formation of the terminal nephrons in 32nd week in human embryo (3).

Experimental studies with knock-out mice support this interactive development delivering the renal parenchymal and ureteric abnormalities together. In fact, most popular theory about this close interaction by Mackie and Stephens was even earlier than these. They hypothesized that the association of renal parenchymal abnormalities with vesicoureteral reflux and other ureteric

abnormalities were the result of initial ectopic budding of the ureter (4).

CAKUT accounts for one of the most frequent congenital abnormalities detected by routine fetal sonography (5), but the spectrum is wide. Ureteropelvic junction obstruction is the most common form of CAKUT with an estimated incidence of 1/1,000–1,500 (6).

THEORIES ON UPJO PATHOGENESIS

The first theory was obliteration-recanalization by Ruano-Gil and Tejedo-Mateu which they raised on their findings on 45 normal human embryos of 5–55 mm (7). They said the ureter becomes obstructed beginning when the fetus is 14 mm, this process starts in the middle zone and progresses to the entire lumen, and then recanalization occurs after the fetus is 22 mm (7). Later, Alcaraz et al. also supported the existence of an obstructive phenomena of the ureter with their study on human and rat embryos (8); however, showed that this obstruction site didn't reach the ureteropelvic junction. After that, obstruction-recanalization theory to explain UPJO was abandoned by the majority. Also others think this obstruction phenomenon can only be the collapse of the ureter before the passage of the urine (2).

Other early studies about the subject were pathological analyses of the specimens with UPJO. They all noted the changes in the ureteropelvic junction (UPJ) without attribution to the etiology (9). Zhang et al. were also researchers who analyzed UPJO specimens. They showed that UPJs were thicker with enlarged muscularis propria, increased perifascicular fibrosis and inflammation in cases with intrinsic UPJO (10). They also couldn't make a statement whether these changes were causative but showed that they were not apparent in the extrinsic cases.

Miyazaki et al. showed angiotension type 1 lacking mice failed to develop a renal pelvis (11). They also showed hypoplastic smooth muscle and lacking peristalsis in the ureters of mutant mice. Reminding the results of Miyazaki's experimental study, Kajbafzadeh et al. showed increased smooth muscle cell apoptosis and collagen fibers while a decreased number of nerve terminals in the UPJO specimens compared to normal ureteropelvic junctions from autopsies (12). These studies strongly suggest defective muscle and nerve structure in the site of obstruction, but it is still unknown if these are the causative changes or the results of the obstruction. Later, Yiee et al. compared intrinsic, and extrinsic cases focusing on the muscle distribution. Their findings support a causative role by revealing a different muscle density between them (13).

Chang et al. generated an animal model of UPJO with a mutation in a calcineurin protein subunit (14). The mutant mice had abnormal renal mesenchyme and lack of a funnel-shaped ureteropelvic junction. They showed no abnormality in the nerve distribution. They correlated abnormal

shape of the pelvis and faulty mesenchyme with abnormal pyeloureteral peristalsis which they concluded as the cause of UPJO.

Based on the studies about peristalsis, Lye et al. speculated that peristalsis in the urinary tract becomes more important in late gestation when the fetus stays upside down and urine travels against gravity. They concluded that failure of peristalsis results in a functional obstruction manifested by hydronephrosis (15).

In fact, none of the above studies describe the macroscopic findings of the surgeon which are as follows: mostly there is narrow but patent lumen, ureter inserts the pelvis in a level higher than ureter and pelvis first meet, they are attached to each other between these two levels and there is fibrotic tissue around. Stephen Koff has an interesting idea about this that he never published. He believes UPJO is a consequence of temporary vesicoureteral reflux during the fetal life. He says reflux disrupts the position of the ureter and UPJ, and then pelvic drainage. When this lasts long enough, it results in inflammation and the fibrotic attachments around and UPJO becomes permanent (Koff, personal communication).

Despite the above theories and two very interesting speculations, further studies are still required to reveal etiopathogenesis of UPJO.

THE GENETICS

CAKUT is thought to be multifactorial. There are familial cases with different occurrence, so genetic penetrance is regarded to be incomplete or variable. Also, there are several single gene mutations like *Id2*, *PAX2*, *EYA*, *AGTR2*, *BMP4*, *SOX17*, *CHD1L*, *DSTYK* proposed by the experimental and clinical studies about the etiopathogenesis of UPJO (16–19). However, mutations in these mostly results in more than one form of CAKUT. For example, mutant mice has a 3% chance of developing CAKUT when *AGTR2* is inactivated, but it can be any type and happens randomly within the same pedigree (2).

Among these, *Adams1* and *Id2* are reported to lead to a more restricted phenotype resembling human UPJO (17). Interestingly, the macroscopic morphology of the kidney of the *Id2* knock-out mice even shows the high-insertion of the ureter into the pelvis (17).

BMP4 also has noteworthy features. It has an essential role in embryonic development shown by the fatality of the homozygous null mutations. Heterozygous mutation results, on the other hand, in multiple abnormalities including all types of CAKUT. It is also shown to cause ectopic budding of the ureter (like Mackie and Stephens described) (20). *BMP4*'s role may seem too wide to explain UPJO alone; however, two screening studies showed its association with UPJO (21, 22). The study from China revealed *BMP4* mutation in three cases with UPJO which were not apparent in the controls (21). Same study failed to show any specific mutation in *Id2* gene. The other one from Brazil showed

the association of BMP4 mutation with UPJO and multicystic dysplastic kidney (22).

Despite promising results of these papers, data to acknowledge a causative role of any gene is still lacking.

CONCLUSION

The etiopathogenesis and impacts of ureteropelvic junction obstruction has long been an interesting area for researchers.

REFERENCES

- Peters CA. Obstruction of the fetal urinary tract. *J Am Soc Nephrol.* (1997) 8:653–63.
- Ichikawa I, Kuwayama F, Pope JC, Stephens FD, Miyazaki Y. Paradigm shift from classic anatomic theories to contemporary cell biological views of CAKUT. *Kidney Int.* (2002) 61:889–98. doi: 10.1046/j.1523-1755.2002.00188.x
- Saxen L. Ontogenesis of the vertebrate excretory system. In: Barlow P, Green P, Wylie C, editors. *Ontogenesis of the Kidney*. Cambridge: Cambridge University Press (1987). p. 13–8.
- Mackie GG, Stephens FD. Duplex kidneys: a correlation of renal dysplasia with position of the ureteral orifice. *J Urol.* (1975) 114:274–80. doi: 10.1016/S0022-5347(17)67007-1
- Caiulo VA, Caiulo S, Gargasole C, Chiriaco G, Latini G, Cataldi L, et al. Ultrasound mass screening for congenital anomalies of the kidney and urinary tract. *Pediatr Nephrol.* (2012) 27:949–53. doi: 10.1007/s00467-011-2098-0
- Klein J, Gonzalez J, Miravete M, Caubet C, Chaaya R, Decramer S, et al. Congenital ureteropelvic junction obstruction: human disease and animal models. *Int J Exp Pathol.* (2011) 92:168–92. doi: 10.1111/j.1365-2613.2010.00727.x
- Ruano Gil D, Coca Payeras A, Tejedo Mateu A. Obstruction and normal recanalization of the ureter in the human embryo. its relation to congenital ureteric obstruction. *Eur Urol.* (1975) 1:287–93.
- Alcaraz A, Vinaixa F, Tejedo-Mateu A, Fores M, Gotzens V, Mestres C, et al. Obstruction and recanalization of the Ureter during embryonic development. *J Urol.* (1991) 145:410–6. doi: 10.1016/S0022-5347(17)38354-4
- Starr NT, Maizels M, Chou P, Brannigan R, Shapiro E. Microanatomy and morphometry of the hydronephrotic obstructed renal pelvis in asymptomatic infants. *J Urol.* (1992) 148:519–24. doi: 10.1016/S0022-5347(17)36643-0
- Zhang PL, Peters CA, Rosen S. Ureteropelvic junction obstruction: morphological and clinical studies. *Pediatr Nephrol.* (2000) 14:820–6. doi: 10.1007/s004679900240
- Miyazaki Y, Tsuchida S, Nishimura H, Pope JC IV, Harris RC, McKanna JM, et al. Angiotensin induces the urinary peristaltic machinery during the perinatal period. *J Clin Invest.* (1998) 102:1489–97. doi: 10.1172/JCI4401
- Kajbafzadeh AM, Payabvash S, Salmasi AH, Monajemzadeh M, Tavangar SM. Smooth muscle cell apoptosis and defective neural development in congenital ureteropelvic junction obstruction. *J Urol.* (2006) 176:718–23. doi: 10.1016/j.juro.2006.03.041
- Yiee JH, Johnson-Welch S, Baker LA, Wilcox DT. Histologic differences between extrinsic and intrinsic ureteropelvic junction obstruction. *Urology.* (2010) 76:181–4. doi: 10.1016/j.urol.2010.02.007
- Chang CP, McDill BW, Neilson JR, Joist HE, Epstein JA, Crabtree GR, et al. Calcineurin is required in urinary tract mesenchyme for the development of the pyeloureteral peristaltic machinery. *J Clin Invest.* (2004) 113:1051–8. doi: 10.1172/JCI20049
- Lye CM, Fasano L, Woolf AS. Ureter myogenesis: putting teashirt into context. *J Am Soc Nephrol.* (2010) 21:24–30. doi: 10.1681/ASN.2008111206
- dos Santos Junior ACS, de Miranda DM, Simões e Silva AC. Congenital anomalies of the kidney and urinary tract: an embryogenetic review. *Birth Defects Res C Embryo Today Rev.* (2014) 102:374–81. doi: 10.1002/bdrc.21084
- Aoki Y, Mori S, Kitajima K, Yokoyama O, Kanamura H, Okada K, et al. Id2 haploinsufficiency in mice leads to congenital hydronephrosis resembling that in humans. *Genes Cells.* (2004) 9:1287–96. doi: 10.1111/j.1365-2443.2004.00805.x
- Yerkes E, Nishimura H, Miyazaki Y, Tsuchida S, Brock JW, Ichikawa I. Role of angiotensin in the congenital anomalies of the kidney and urinary tract in the mouse and the human. *Kidney Int Suppl.* (1998) 54:75–7. doi: 10.1046/j.1523-1755.1998.06715.x
- Vivante A, Kohl S, Hwang DY, Dworschak GC, Hildebrandt F. Single-gene causes of congenital anomalies of the kidney and urinary tract (CAKUT) in humans. *Pediatr Nephrol.* (2014) 29:695–704. doi: 10.1007/s00467-013-2684-4
- Miyazaki Y, Ichikawa I. Ontogeny of congenital anomalies of the kidney and urinary tract, CAKUT. *Pediatr Int.* (2003) 45:598–604. doi: 10.1046/j.1442-200X.2003.01777.x
- He JL, Liu JH, Liu F, Tan P, Lin T, Le XL. Mutation screening of BMP4 and Id2 genes in Chinese patients with congenital ureteropelvic junction obstruction. *Eur J Pediatr.* (2012) 171:451–456. doi: 10.1007/s00431-011-1561-z
- Reis GS Dos, Simões E Silva AC, Freitas IS, Heilbuth TR, Marco LA De, Oliveira EA, et al. Study of the association between the BMP4 gene and congenital anomalies of the kidney and urinary tract. *J Pediatr.* (2014) 90:58–64. doi: 10.1016/j.jpeds.2013.06.004

Conflict of Interest: The authors declare that the research was conducted in the absence of any commercial or financial relationships that could be construed as a potential conflict of interest.

Copyright © 2020 Avanoglu and Tiryaki. This is an open-access article distributed under the terms of the Creative Commons Attribution License (CC BY). The use, distribution or reproduction in other forums is permitted, provided the original author(s) and the copyright owner(s) are credited and that the original publication in this journal is cited, in accordance with accepted academic practice. No use, distribution or reproduction is permitted which does not comply with these terms.



Managing Ureteropelvic Junction Obstruction in the Young Infant

Niccolo Maria Passoni and Craig Andrew Peters*

University of Texas Southwestern Medical Center, Dallas, TX, United States

OPEN ACCESS

Edited by:

Luis Henrique Braga,
McMaster University, Canada

Reviewed by:

Juan Manuel Moldes,
Italian Hospital of Buenos
Aires, Argentina
Paulo R. M. Moscardi,
University of São Paulo, Brazil
Mohan S. Gundeti,
University of Chicago, United States

*Correspondence:

Craig Andrew Peters
craig.peters@utsouthwestern.edu

Specialty section:

This article was submitted to
Pediatric Urology,
a section of the journal
Frontiers in Pediatrics

Received: 03 March 2020

Accepted: 20 April 2020

Published: 27 May 2020

Citation:

Passoni NM and Peters CA (2020)
Managing Ureteropelvic Junction
Obstruction in the Young Infant.
Front. Pediatr. 8:242.
doi: 10.3389/fped.2020.00242

In the last decade, management of congenital UPJ obstruction has become progressively observational despite the lack of precise predictors of outcome. While it is clear that many children will have resolution of their hydronephrosis and healthy kidneys, it is equally clear that there are those in whom renal functional development is at risk. Surgical intervention for the young infant, under 6 months, has become relatively infrequent, yet can be necessary and poses unique challenges. This review will address the clinical evaluation of UPJO in the very young infant and approaches to determining in whom surgical intervention may be preferable, as well as surgical considerations for the small infant. There are some clinical scenarios where the need for intervention is readily apparent, such as the solitary kidney or in child with infection. In others, a careful evaluation and discussion with the family must be undertaken to identify the most appropriate course of care. Further, while minimally invasive pyeloplasty has become commonly performed, it is often withheld from those under 6 months. This review will discuss the key elements of that practice and offer a perspective of where minimally invasive pyeloplasty is of value in the small infant. The modern pediatric urologist must be aware of the various possible clinical situations that may be present with UPJO and feel comfortable in their decision-making and surgical care. Simply delaying an intervention until a child is bigger may not always be the best approach.

Keywords: robotic assisted pyeloplasty, infant-age, prenatal hydronephrosis, diuretic nephrogram, ureteropelvic junction (UPJ) obstruction

INTRODUCTION

Hydronephrosis is the most commonly diagnosed genito-urinary abnormality on prenatal ultrasounds (1). In the past, corrective surgery was offered to every child who presented with uretero-pelvic junction obstruction (UPJO). Indeed, prior to diffusion of fetal ultrasound, patients with this condition were identified due to their signs and symptoms (2). Children were commonly diagnosed between the ages of 6 and 15 years, with only 14% of them being younger than 1 year of age (3).

However, prenatal imaging has increased the rate of diagnosis of asymptomatic cases that may not have otherwise not been detected until later in life. A multitude of studies has questioned the earlier operative paradigm by demonstrating a high rate of spontaneous resolution. Unfortunately, this culminated in a conundrum which today still has no clear solution: which asymptomatic infant with hydronephrosis will lose precious renal function if left untreated?

Finally, diagnosis of a UPJO that warrants surgical correction in an infant poses technical challenges in the modern era of minimally invasive surgery.

In this chapter the threats posed by chronic obstruction to the kidney as well as the natural history of prenatally diagnosed UPJO will be discussed. Surveillance algorithms aimed at identifying early candidates for surgery will be described prior to introducing novel markers and imaging methodologies to improve risk stratification. In the end, traditional and minimally invasive approaches will be compared with a particular attention to tips and tricks for the infant patient.

THE EFFECTS OF OBSTRUCTION ON THE KIDNEY

Hydronephrosis is an abnormal dilation of the collecting system. However, not all hydronephrosis is associated with clinically significant obstruction that will lead to renal function deterioration (4). Unfortunately, long-term complications of renal damage may not be evident until the patient reaches adulthood. Even if a child has normal renal function, these patients are four times more likely to develop ESRD (5) and can require renal replacement therapy in young adulthood (6). Nephrogenesis terminates at 36 weeks of gestation, without any more nephrons formed after birth. Premature babies will have a lower number of nephrons compared to children born at term (7). Therefore, any insult that leads to renal injury will not be followed by replacement of damaged nephrons but by adaptive changes of the remaining nephrons (8). While this mechanism maintains glomerular filtration rate at first, in the long term it appears to lead to renal damage in both the obstructed and the contralateral kidney, as shown in murine models (9).

Furthermore, obstruction that originates *in utero* can lead to more deleterious effects by altering the pathways of renal development (10, 11).

Initial series of biopsies obtained at time of surgical repair showed that up to 21% of children with a differential renal uptake (DRU) on diuretic renography >40% at time of surgery had histological changes, while only 34% of patients with a DRU <40% had normal findings (12). Interestingly, when grouping children by presentation, they demonstrated that only 19% of children diagnosed due to symptoms harbored moderate or severe histological changes, compared to 50% of children diagnosed either prenatally or due to a palpable mass (up to 80%). A larger more recent study found that 67% of biopsies from 61 children had glomerular sclerosis (13). Interestingly, the number of affected glomeruli did not significantly correlate with either degree of hydronephrosis nor DRU. In addition, tubulointerstitial changes were found in only 26% of patients, and significant fibrosis was more common in patients older than 1 year of age, suggesting a potentially progressive process with chronic obstruction. Alteration of the renal parenchyma secondary to obstruction has been documented in human fetuses as well. An autopsy study conducted on fetuses with evidence of UPJO on prenatal ultrasound showed that obstructed kidneys have a reduction in glomerular number and cortical thickness as well as an increase

in fibrosis when compared to specimens from age-matched fetuses with normal kidneys (14). The authors found that fibrosis and reduced glomerular numbers correlated strongly with hyperechogenicity on prenatal ultrasound, which is consistent with clinical observations.

In reality, damage from obstruction is likely secondary to partial obstruction that develops later in pregnancy once nephrogenesis is almost complete, otherwise it would lead to cystic dysplasia or renal agenesis (15).

Just as not all hydronephrosis will persist, as will be discussed in the next section, not all obstructed systems harbor the same damage potential. Therefore, the clinician must be able to synthesize the clinical history and diagnostic data to identify the child more at risk of losing renal function.

NATURAL HISTORY OF PRENATALLY DETECTED HYDRONEPHROSIS

While at first it was believed that most UPJ obstructions with severe dilation detected prenatally required intervention, several studies have shown a relatively high rate of spontaneous resolution. This has led to a shift in management, centered on the serial monitoring of renal dilation and function to hopefully identify the children that will eventually require surgery as early as possible without irreversible loss of renal functional potential.

Several statistics are useful when counseling families of newborns with hydronephrosis secondary to UPJO.

First, that rates of resolution and/or improvement even for severe dilation, as in grade 3 and 4 as defined by the Society for Fetal Urology (SFU) are reasonably good. Indeed, complete resolution rates in observed children range from 33 to 70% (16–23). In the literature, lower rates of resolution are associated with more severe hydronephrosis. Furthermore, another important parameter is improvement in hydronephrosis. Indeed, a change in SFU Grade from 3–4 to 1–2 is considered significant and likely reflects a kidney without significant risk of functional deterioration.

Second, not all children with moderate and severe hydronephrosis have poor DRU as measured on diuretic renography. Data from studies shows that between 10 and 39% of children with SFU grade 3 or 4 have a reduced DRU at diagnosis, defined as <40%. These children are usually offered early pyeloplasty. However, if observation is performed for kidneys with a DRU <40%, renal function remains stable in ~80% of them at 1 year (17, 24). It remains undefined how many may experience later deterioration without intervention.

DIAGNOSIS AND INITIAL EVALUATION

The challenges in managing infants with prenatally detected UPJO are secondary to a lack of diagnostic tools that can identify obstruction that will lead to deterioration of renal

function or prevent normal renal functional development. To further complicate matters, the current gold standard evaluation of renal function is diuretic renography; however, we are not sure if a kidney with “normal” DRU on nephrography can be considered completely normal since it likely has received some insults from *in-utero* obstruction (13). Also, diuretic renography does not provide any information regarding the multiple other important functions of the kidney, including tubular homeostatic and endocrine functions. Therefore, urologists need to rely on a combination of ultrasound and diuretic renography findings to individualize management.

Once a baby with prenatal hydronephrosis is delivered, a postnatal ultrasound is obtained to assess persistence of hydronephrosis. Usually it is obtained between 48 and 72 h after birth, due to transient neonatal dehydration. However, it is recommended to obtain this study earlier in specific cases, such as bilateral hydronephrosis, solitary kidney or a history of oligohydramnios. It is also important to record size of the kidney, thickness and echogenicity of the renal parenchyma, as well as appearance of the bladder and post void residuals. Important information can be obtained from the initial ultrasound. Severe hydronephrosis is associated with diffuse and uniform dilation of the calyces with flattening of the renal papillae (**Figure 1**). In severe cases, the hydronephrosis leads to thinning of the renal parenchyma. Asymmetric dilation should raise suspicion of a duplicated system. It is important to remember that a severely dilated renal pelvis with mild-to-moderate dilation of the intra-renal collecting system is usually a hallmark of milder obstruction and pelvic dilation should not be used to draw therapeutic conclusions by itself. Isolated dilation of the extra-renal pelvis is usually considered a benign finding (25). One study showed that while infants extra-renal pelvis dilation have slightly higher rates of UTI, it resolves in 98% of patients on follow-up (26). Furthermore, dilation of the intra-renal pelvis has by far as more significant prognostic values, as highlighted by the adoption of antero-posterior renal pelvis diameter by the UTD classification (27). Finally, the presence of a dilated ureter can indicate either the presence of vesicoureteral reflux or a more distal obstruction.

A voiding cystourethrogram is usually obtained to rule out lower urinary tract obstruction or vesicoureteral reflux, especially for cases with bilateral hydronephrosis, unilateral hydronephrosis in solitary kidneys or oligohydramnios. However, for a child with unilateral renal dilation without ipsilateral ureteral involvement, a voiding cystourethrogram to rule out reflux might not be needed. Indeed, a recent review showed that among children with UPJO the pooled prevalence of vesicoureteral reflux is 8.2%, 3-fold higher than in children without UPJO (28). Lee et al. demonstrated a higher rate of vesicoureteral reflux among patients with higher grades of hydronephrosis. With the goal of reducing unnecessary radiation exposure and testing, they developed a risk-based approach based on ultrasound findings such as presence of duplication, hydroureteronephrosis and renal dysplasia (29). Performing a VCUG only in children with all three aforementioned ultrasound criteria would reduce the number of tests ordered by 40% while maintaining the same miss rate of reflux as if ordering a VCUG

only if severe hydronephrosis were present. However, it remains controversial as to how valuable the VCUG and identification of reflux might be in this population.

DIURETIC NEPHROGRAPHY

Once severe hydronephrosis is confirmed, diuretic renography is ordered to assess the degree of obstruction as well as the level of renal function. Technetium-99m (99mTc) mercaptoacetyltryglycine (MAG3) is the preferred radionuclide due to its short half-life and its excretion via both glomerular filtration and active tubular secretion, allowing for assessment of poorly functioning kidneys. In general, the amount of tracer uptake in the first 2 min after injection correlates with the glomerular filtration rate.

Several elements can be controlled in order to obtain the most informative study (3). The patient should be adequately hydrated prior to the procedure. Second, the bladder should be emptied with a catheter since a full bladder can impair upper tract drainage, as well-increasing gonadal radiation exposure. Finally, the diuretic has been described as being administered 15 min prior to radionuclide injection, at the same time, or 20–30 min after. The most common approach includes administration of the diuretic once the entire dilated collected system is filled with radionuclide in order to better assess washout. The diuretic that is commonly used is furosemide, at a dose of 1 mg/kg for infants.

Diuretic renography provides several useful parameters. First, it estimates differential renal function. It has been shown that unilateral variation within 5% is considered physiological (30), while a loss >5% should be considered as loss of renal function (31). Second, washout curves can be interpreted to assess the degree of obstruction. However, the traditional T1/2 cut-offs used for obstruction should not be used as rigid checkpoints for therapeutic algorithms.

The astute clinician should remember that UPJO can be a dynamic process and should consider changes in degree of hydronephrosis, DRU as well as washout curves when formulating a treatment strategy. The washout curve can show prompt drainage (**Figure 1**) or obstruction if a flat, plateauing shape is seen (**Figure 2**). However, a biphasic curve can show dynamic obstruction. This curve normally shows prompt drainage that eventually plateaus or even raises, suggesting varying degrees of obstruction (**Figure 3**). Finally, delayed cortical transit time, which is defined as the absence of radionuclide in the sub-cortical renal parenchyma within 3–8 min of injection has been associated with outcomes after pyeloplasty. Song et al. demonstrated that children with delayed cortical transit time had greater improvement of their DRU after surgery compared to those with normal values (32). Furthermore, a delayed transit time has been shown to be a prognostic factor identifying which children will progress to surgery while on observation (33, 34). Interestingly, in a porcine model, delayed cortical transit time has been linked to histological changes such as glomerulosclerosis, decreased number of glomeruli, tubular atrophy, and increased fibrosis (35). However, the correlation between hydronephrosis and diuretic renography findings is

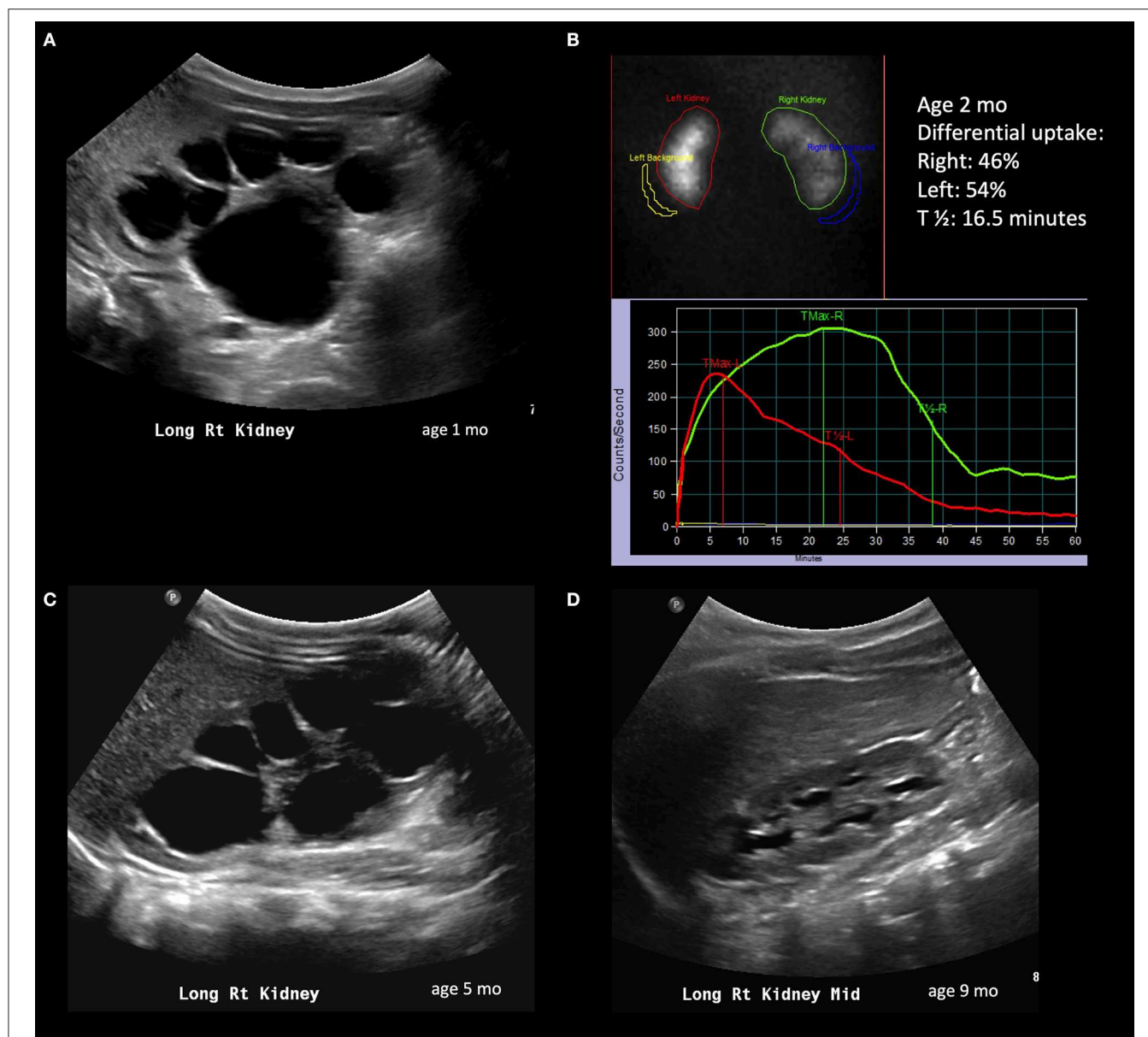


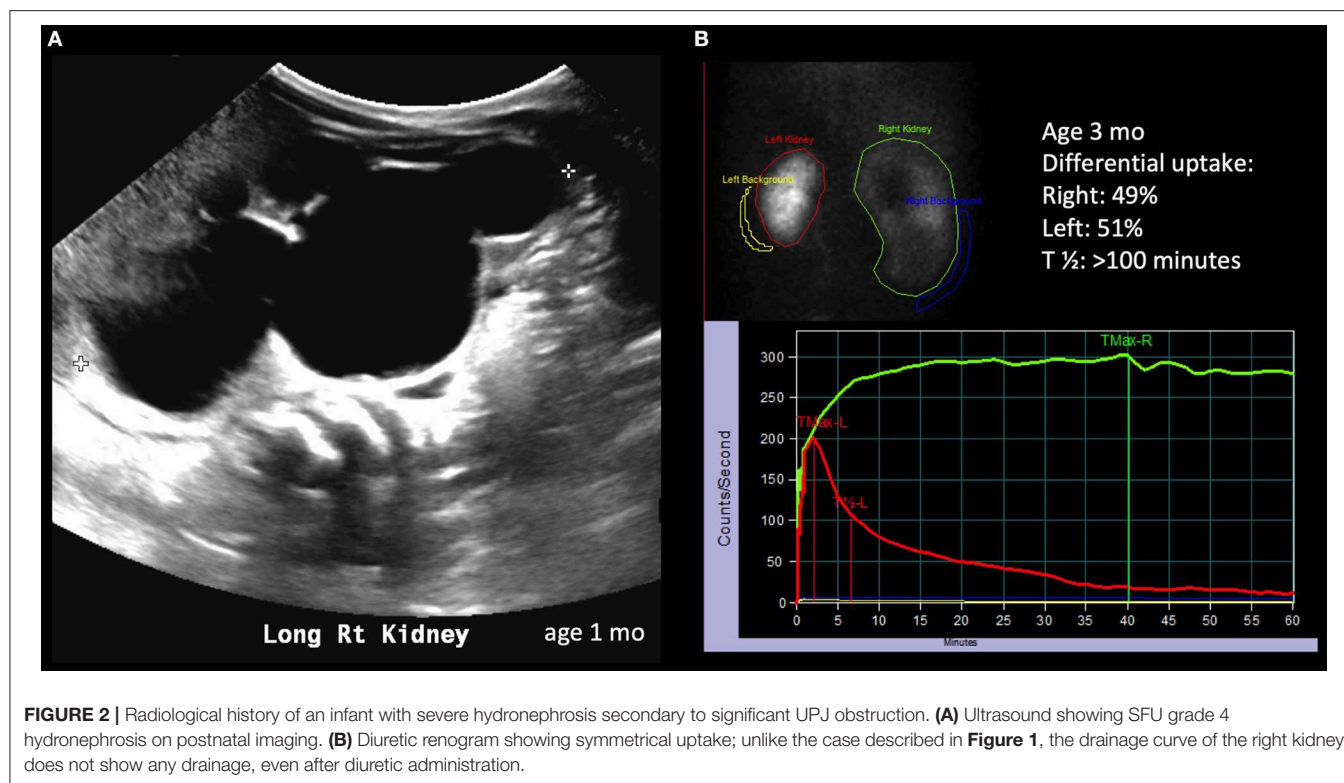
FIGURE 1 | Radiological history of an infant with resolution of severe hydronephrosis. **(A)** Postnatal ultrasound confirming prenatally diagnosed hydronephrosis; the image shows SFU grade 4 hydronephrosis with thinned isoechoic parenchyma. **(B)** Diuretic renogram performed at 2 months of age, showing symmetric uptake; despite the right kidney exhibits a delayed washout curve, it is still considered adequate. **(C)** Repeat ultrasound at 5 months showing persistent SFU grade 4 hydronephrosis. **(D)** Follow-up ultrasound at 9 months showing significant spontaneous improvement of hydronephrosis; the child will still however need follow-up imaging to ensure persistent improvement.

poor (36). Among 13% of children with improving or stable hydronephrosis, DRU worsened more than 5%.

BIOMARKERS

For a long time there has been a focus on urine biomarkers to screen for children with UPJO who will ultimately develop renal damage, yet none are in regular clinical practice to date. Kostic et al. sampled urine and blood from newborns

with either lower or upper urinary obstruction and compared values of biomarkers with healthy infants matched by gender and gestational age (37). They identified NGAL (Neutrophil Gelatinase-Associated Lipocalin), RBP (Retinol Binding Protein), TGF- β 1 (Transcription Growth Factor- β 1), and KIM-1 (Kidney Injury Molecule-1) as promising markers, compared to serum creatinine and cystatin, for identifying which patients with unilateral hydronephrosis will progress and require surgery. All their values decreased after surgery.



These proteins are markers of ischemic and tubule-interstitial pathology, and herald renal damage prior to radiological findings.

The benefits of using urine is that it is readily available, can be collected longitudinally and in a non-invasive manner. However, voided urine contains a mix of urine from both kidneys, and markers from an obstructed system can easily be diluted. Froelich et al. performed urine proteomics analysis by sampling urine from both the obstructed kidney at time of surgery and the bladder (38). They identified 76 proteins that were present both in renal and bladder samples, showing that obstruction produces changes in the urine proteome that are also secondary to compensatory changes in the non-obstructed kidney. A significant number of these proteins were part of the oxidative stress pathway, underling its important role in the pathogenesis of UPJO. Future areas of development for novel biomarkers are magnetic resonance imaging and proteomics and metabolomics (39). While the latter can provide quantitative information on glomerular numbers and volume, the former still requires generation of age-specific normative-data.

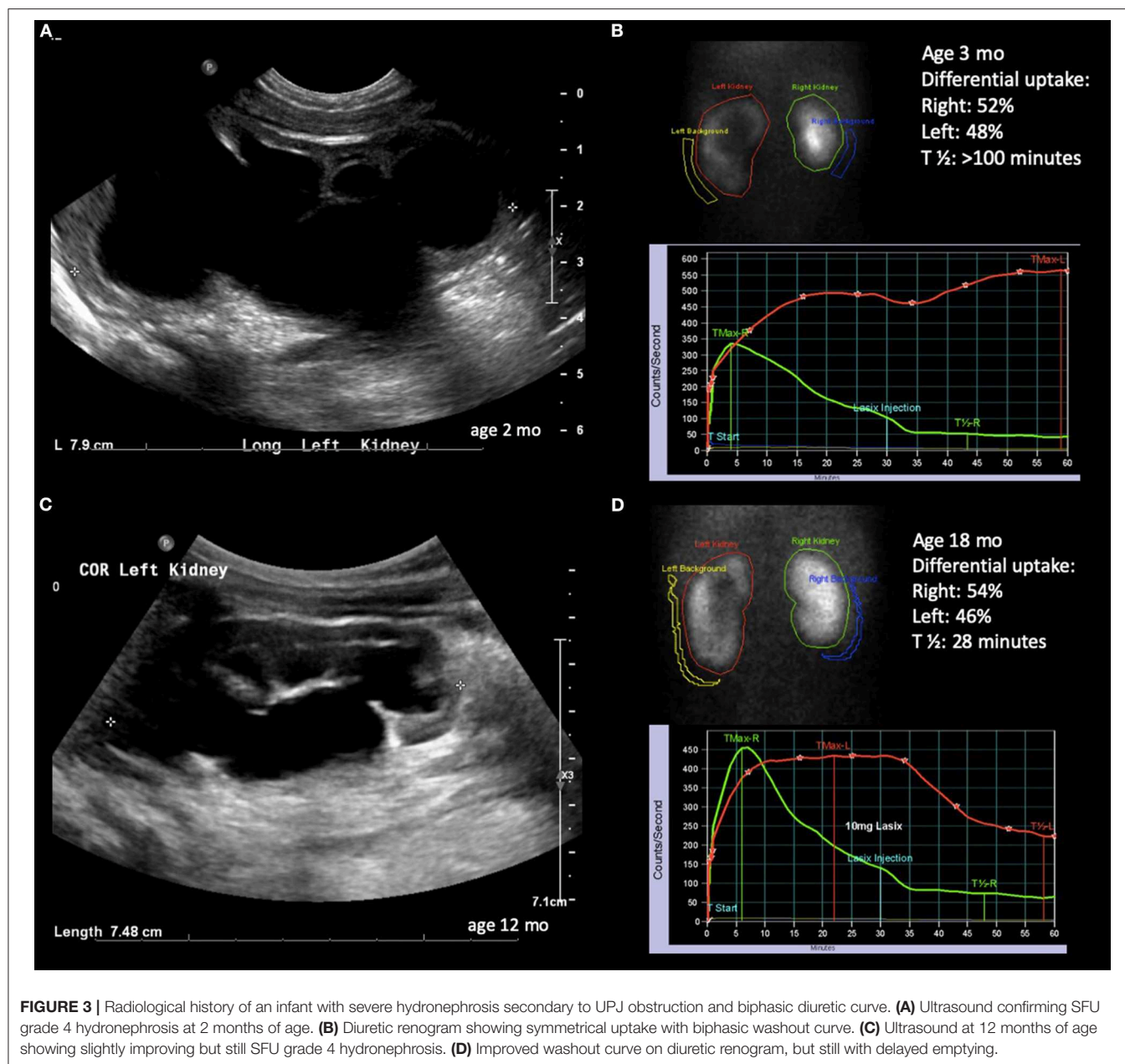
Further multi-disciplinary and multi-institutional studies are needed however to identify a marker that can reliably identify obstructed renal units that are at risk of deterioration.

CLINICAL RISK FACTORS OF RENAL DETERIORATION

A copious literature exists investigating what factors are able to predict renal deterioration and thus identify candidate who

would benefit from early surgery. This is based on the belief that operating on a child whose DRU has not deteriorated yet will lead to better long-term results. However, there are reports showing that lost function during observation will be recovered after surgical correction (18) and will last into puberty (40). Furthermore, early detection of surgical candidates can potentially reduce costs of follow-up imaging as well as stress for the families. The prediction usually relies on parameters obtained from ultrasound and nuclear medicine imaging. With regard to renal function, infants with a >10% difference in DRU between then hydronephrotic kidney and contralateral healthy one at initial evaluation has been found to experience renal deterioration 3 times more often and to be two times more likely to develop symptoms (41). As mentioned earlier, delayed cortical transit time has been found to be a predictor of deterioration, once having adjusted for other factors such as DRU, T_{1/2} and hydronephrosis (32, 42). Anterior-posterior diameter (APD) on initial ultrasound has been found to be an independent predictor of resolution of hydronephrosis (43). An APD of 24 mm an initial evaluation has been shown to have high specificity and sensitivity to predict need of surgery, secondary to either a drop of 10% or greater in DRU or worsening hydronephrosis with an obstructed nephrogram (44).

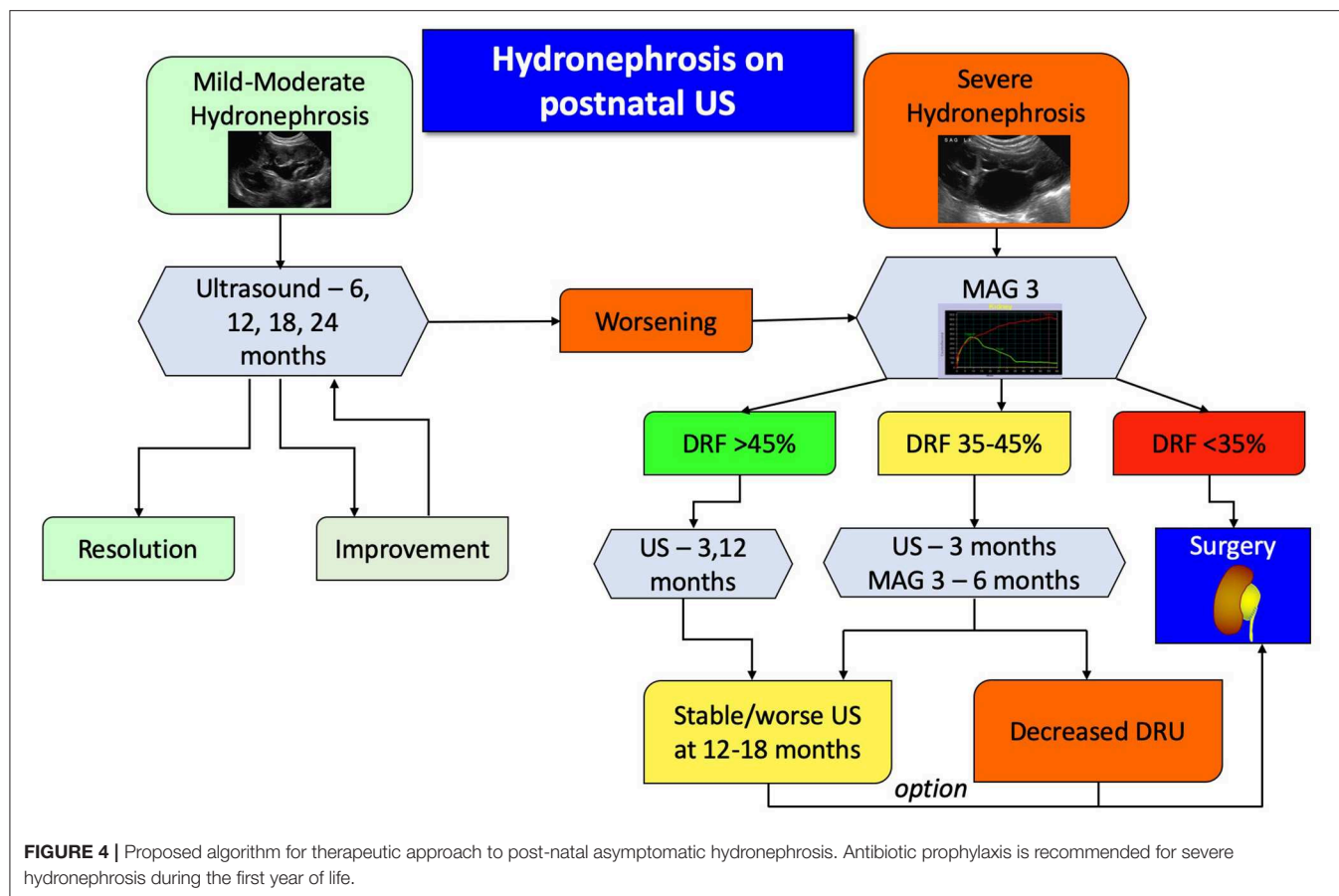
The idea of creating a variable that includes information from both degree of hydronephrosis severity and renal parenchyma thinning was first introduced by Shapiro and coworkers with hydronephrosis index (45). This was obtained by subtracting the area of the calyces and renal pelvis from the total area of the



kidney and then dividing it by the total area. The hydronephrosis index was shown to be easily reproducible and associated with resolution or worsening of hydronephrosis. Later, Cerrolaza et al. (46), by applying machine learning to ultrasound images and diuretic renogram curves, described how quantitative analysis of renal ultrasound images can predict diuretic renography curves and help reduce the number of nuclear medicine studies. More recently, Rickard et al. (47) showed that the renal parenchyma to hydronephrosis area ratio correlates well with DRU and T1/2, and demonstrated a very good performance in selecting children who will require surgery.

TREATMENT ALGORITHM

Absolute candidates for surgical treatment are symptomatic patients, however defining symptoms of UPJO in infants can be challenging, since most won't be able to complain about pain. Significant symptoms also include recurrent urinary tract infections despite antibiotic prophylaxis, hematuria, kidney stones, or mass effect from the severely dilated kidney. Another absolute indication for surgery is the child with clinical obstruction in a solitary kidney and evidence of reduced overall renal function. For all other patients, the algorithm (Figure 4) is a suggested clinically pragmatic approach.



In essence, patients with mild or moderate hydronephrosis, defined as SFU grade 1 or 2, should be followed with serial ultrasounds to detect either improvement and resolution or progression. Children with confirmed severe hydronephrosis on post-natal imaging or those who progress to it should undergo a MAG3 study. The findings of the diuretic renography will dictate the follow up. If the DRU is more than 45%, ultrasound is repeated to assess for degree of dilation, whereas if the DRU is <35% surgery is usually recommended. If the hydronephrosis does not improve on repeated ultrasound images, despite a normal DRU, then surgery can be appropriately offered. For all other patients, US and MAG3 should be repeated, and in case of worsening hydronephrosis or DRU the surgery should be considered. It has been shown that if a patient demonstrates two consecutive drops in their DRU on two consecutive scans, then there is an 85% he or she will require surgery (48). As mentioned earlier, a delayed cortical transit time is also a strong indicator of future renal deterioration and should be incorporated into clinical algorithms without having to wait for actual loss of function.

If the DRU is <10%, some authors argue that a nephrectomy is indicated where there is development of symptoms such as infections or hypertension; otherwise non-intervention is warranted. There are reports of a significant improvement of

function in kidneys with a pre-operative DRU <10%. Wagner et al. reported a return to function to a range of 27–53% at 1 year after pyeloplasty (49). Other authors instead recommend placement of a nephrostomy tube for 4 weeks to determine if there will be some recovery of renal function. In their series, up to 70% of kids treated with a urinary diversion recovered from <10% DRU to an average or 29% (50, 51). While this can occur, significant functional improvement has not been common in the senior author's experience, raising concern as to the validity of initial functional assessments, which can be problematic.

SURGICAL TREATMENT OF UPJO IN THE INFANT PATIENT

The challenges of surgical correction of UPJO in patients younger than 1 year of age mainly reside in the adaptation of minimally invasive techniques due to the patient's size. The open Anderson-Hynes dismembered pyeloplasty is considered the gold standard approach in this population. In the very small infant, the dorsal lumbotomy is preferred by the authors for several reasons. First, it avoids muscle splitting, reducing post-operative pain. Second, it allows for direct access to the posterior aspect of the renal pelvis and ureter. Finally, the incision is in a more

discrete area, compared to a lateral approach. However, the open approach, unlike the laparoscopic or robotic ones, does not allow for access to the entire ureter, in case of a longer than expected stricture. Another potential disadvantage of the open approach is the use of excessive traction on the tissues in order to improve exposure toward the surgical incision. Indeed, the minimally invasive approach allows to bring the instruments to the tissues, instead of having to bring the tissues to the surgical site, avoiding unnecessary tension that could damage the ureter. Furthermore, unless for selective circumstances like a posterior renal pelvis, minimally-invasive pyeloplasty allows for surgical correction without the need to rotate the kidney.

Minimally invasive approaches have shown direct patient benefit in terms of reduced hospital stay, reduced need of pain medications and improved cosmetics results in older children (52). However, both laparoscopic and robotic pyeloplasties were originally received with skepticism in infant populations. The main concerns raised by critics were the smaller operative field offered by an infant pneumoperitoneum, the limited space for port placement, lack of appropriate-sized instruments for the robot and finally the fact that the robotic system would limit access to the patient by the anesthesia team. It was also argued, appropriately to some degree, that there was limited benefit for the costs in time and instrumentation.

The first ever description of a successful laparoscopic dismembered pyeloplasty in the pediatric literature was by the senior author in 1995, on a 7 years old child (53). Subsequently, Dr. Tan (54) reported on a series of 16 children, in which two had persistent post-operative obstruction, and both these patients were 3 months of age at time of surgery. Hence laparoscopic pyeloplasty was discouraged for patients younger than 6 months. Kutikov et al. subsequently published their outcomes of laparoscopic pyeloplasties in children young than 6 months of age, using 3 mm instruments, showing good results and challenging the conclusion that infants are not candidates for minimally invasive approaches (55). Several other series corroborated the feasibility, safety and good outcomes of laparoscopic management for UPJO in infants (56–61). However, all authors acknowledged the technical difficulty of such procedure and advocate for the need of an experienced surgeon and team in order to perform this surgery.

While conventional laparoscopic pyeloplasty has not gained popularity due to its longer learning curve and high technical demands (62), robotic surgery has become vastly more popular due to instruments that allow for 7 degrees of motion, three-dimensional displays with magnification, tremor reduction and surgeon ergonomics (63). Furthermore, the learning curve for robotic pyeloplasty has been shown to be similar to that of open surgery (64).

In a study comparing robotic to laparoscopic pyeloplasty in children of all ages, Lee et al. were the first to report on the feasibility of the robotic approach in infants (52). The first published series of robotic pyeloplasties just in infants, Kutikov et al. reported resolution of hydronephrosis in seven of nine, while the remaining two patients had no evidence of obstruction on diuretic renography (65). Dangle and coworkers

(66) were the first to compare 10 infants who underwent open pyeloplasty to 10 who underwent robotic surgery. They showed similar outcomes with improved aesthetic results and pain control. These authors also recommended using 8-mm instruments instead of the 5-mm ones, which due to their goose-neck joint design require a greater distance from the tissues to fully articulate, reducing the functional space. However, in the hands of an experienced surgeon, 5 mm instruments do not increase either total operative time nor console time when used in infants, compared to larger children (67). The largest-to-date series on robotic pyeloplasty in infants is a multi-center report that includes 62 surgeries in 60 patients, with a mean age of 7.3 months and a median weight of 8.1 kg (68). Resolution or improvement in hydronephrosis was documented in 91% of kidneys and only two patients required redo pyeloplasty, with no intra-operative and only 7 (11%) post-operative complications.

The robotic approach is however under critique for the perceived increase in medical costs, especially when compared to open surgery. Data show that even if robotic equipment increases costs, the shortened post-operative stay and the frequent usage of the system eventually lead to savings (69). In addition, a shorter hospital stay translates into an increased human capital gain for the parents (70). Further data have that robotic surgery is not more expensive than pure laparoscopic pyeloplasty (71). Robotic costs will continue to decrease as more surgeries are performed with this approach. Indeed, between 2003 and 2015, the utilization of robotic pyeloplasty increased by 29% annually. However, this growth was mainly in children and adolescents. While 40% of pyeloplasties in children and adolescents in 2015 were performed robotically, 85% of infant cases were still performed via an open approach (72). Infant patients accounted for 2% and 19% of all robotic and laparoscopic pyeloplasties performed (73), but these trends are likely to change as more surgeons are trained in minimally invasive approaches.

In the end, surgical experience and volume with either open or minimally invasive technique should be a significant factor in the approach chosen to treat UPJO. In the largest report of minimally-invasive pyeloplasties, including 575 pure laparoscopic and robotic cases, a prolonged operative time, but not patient age, was associated with higher complication rates (74). However, success rates were similar. While operative time can be increased by surgical difficulty, it is also a proxy of surgical experience, since progression on the learning curve is associated with shorter operative times (75). Nationwide data from 2008 to 2010 stressed the importance of hospital volume with regards to outcomes of pyeloplasties (76). At high volume centers, peri-operative outcomes of open or minimally-invasive pyeloplasties were similar, however children who underwent minimally-invasive surgery had a shorter hospital stay. Furthermore, the worse outcomes were seen in patients undergoing minimally invasive surgery at low volume centers. Luckily, the same data showed that minimally-invasive pyeloplasties in infants are more frequently performed in high-volume centers than low-volume ones (2.8 vs. 0.4%).

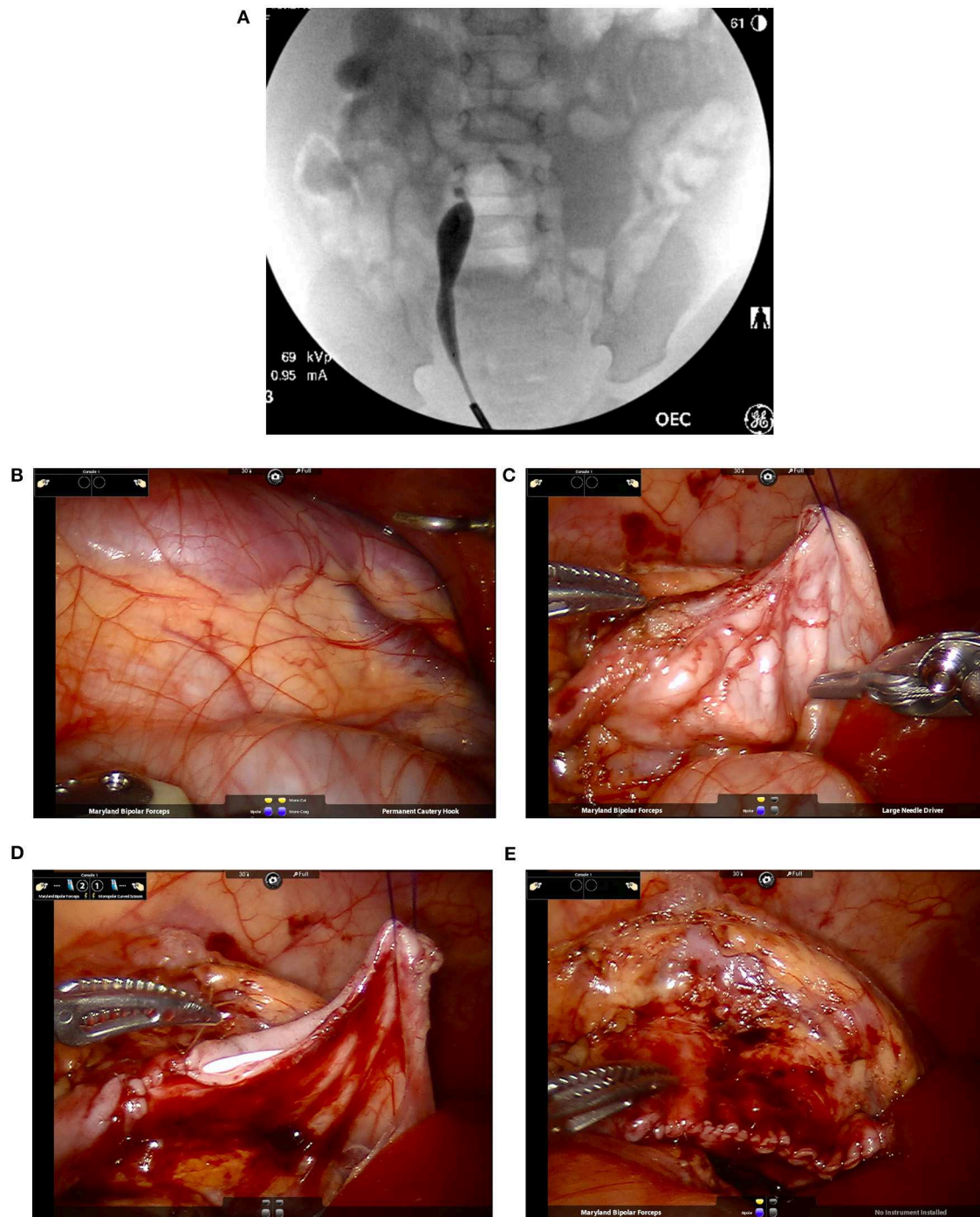


FIGURE 5 | Intra-operative pictures and findings of robotic-assisted laparoscopic pyeloplasty in an infant. **(A)** A retrograde pyelogram performed at the beginning of the case allows for localization of the stricture as well as assessment of its length. This allows for easier planning of reconstructive technique (e.g., dismembered pyeloplasty vs. the need of a flap for longer narrow segments). In addition, it allows for detection of possible distal strictures. A stent is placed at the end prior to the robotic portion of the case. **(B)** Identification of the right kidney with a dilated renal pelvis visible underneath the peritoneum. **(C)** Once the renal pelvis and proximal ureter are dissection, placement of trans-abdominal hitch stitch facilitate exposure of the operative field while avoiding the potential use of excessive retraction force by robotic instruments. **(D)** Suturing over the ureteral stent that was placed in a retrograde fashion at time of retrograde pyelogram. **(E)** Complete repair. In the case used for the images, a fair amount of redundant renal pelvis was excised.

TECHNICAL CONSIDERATIONS FOR THE ROBOTIC APPROACH IN THE INFANT PATIENT

At the beginning of the procedure, the authors recommend performing a cystoscopy with retrograde pyelogram. This can rule out any potential distal obstruction as well as delineating the exact extension of the UPJ obstruction. This also allows for placement of a stent in a retrograde manner with an extraction string, eliminating the need for a second cystoscopy (Figure 5).

To facilitate port placement in infants we recommend decompression of the bladder with a catheter and the stomach with an orogastric tube as well as a rectal tube to help with colonic decompression. Placement of the ports in the midline can facilitate reduction of instrument clashing. This port configuration can be performed easily with either the daVinci Si or Xi systems. The surgeon should must be aware of the extension of intra-abdominal movements which are amplified externally with the robotic arms. The depth of the ports can also be reduced, placing the proximal thin line on port at the skin level. We strongly recommend using a box-stitch secured to the fascia to facilitate port placement and prevent port slippage. This will also help with port closure at the end of the procedure. The use of a hitch stitch to elevate the renal pelvis can facilitate anastomotic suturing. Finally, since there will be less gas to dissolve the heat from the electrocautery, it is better to reduce the settings to 15 or less. We have found that use of AirSeal® insufflation reduces the problems of fogging significantly.

OUTCOMES

Outcomes of minimally invasive pyeloplasty in the hands of experienced surgeons have been excellent. Reported success rates for laparoscopic surgery are 92–99% while for the robotic approach are 94–100%. The range of complications is wider, 6–30% for laparoscopic and 6–33% for robotic, depending on criterion for consideration as a surgical complication (63, 66, 68, 72, 76).

CONCLUSIONS

Prenatal detection of hydronephrosis secondary to UPJO has increased the numbers of asymptomatic cases from which the clinician must discern who will benefit from surgery and who is best observed. The majority of these children will have resolution of their hydronephrosis, however a non-trivial minority will not improve and may be best managed with surgical intervention to preserve renal functional potential. Early signs of worsening obstruction should be caught promptly in order to offer surgical correction, which can be performed safely with a minimally invasive approach in the hands of an experienced surgeon. Leaving significant obstruction untreated for a prolonged period of time can lead to long-term consequences that will manifest later in the life of the child.

AUTHOR CONTRIBUTIONS

CP and NP were involved in literature review. NP drafted the manuscript. CP provided critical review of the manuscript.

REFERENCES

- Ficara A, Syngelaki A, Hammami A, Akolekar R, Nicolaides KH. Value of routine ultrasound examination at 35–37 weeks' gestation in diagnosis of fetal abnormalities. *Ultrasound Obstet Gynecol.* (2020) 55:75–80. doi: 10.1002/uog.20857
- Johnston JH, Evans JP, Glassberg KI, Shapiro SR. Pelvic hydronephrosis in children: a review of 219 personal cases. *J Urol.* (1977) 117:97–101. doi: 10.1016/S0022-534758355-X
- Bayne CE, Majd M, Rushton HG. Diuresis renography in the evaluation and management of pediatric hydronephrosis: what have we learned? *J Pediatr Urol.* (2019) 15:128–37. doi: 10.1016/j.jpuro.2019.01.011
- Peters CA. Urinary tract obstruction in children. *J Urol.* (1995) 154:1874–83; discussion 83–4. doi: 10.1016/S0022-534766815-0
- Calderon-Margalit R, Golan E, Twig G, Leiba A, Tzur D, Afek A, et al. History of childhood kidney disease and risk of adult end-stage renal disease. *N Engl J Med.* (2018) 378:428–38. doi: 10.1056/NEJMoa1700993
- Wuhl E, van Stralen KJ, Verrina E, Bjerre A, Wanner C, Heaf JG, et al. Timing and outcome of renal replacement therapy in patients with congenital malformations of the kidney and urinary tract. *Clin J Am Soc Nephrol.* (2013) 8:67–74. doi: 10.2215/CJN.03310412
- Rodriguez MM, Gomez AH, Abitbol CL, Chandar JJ, Duara S, Zilleruelo GE. Histomorphometric analysis of postnatal glomerulogenesis in extremely preterm infants. *Pediatr Dev Pathol.* (2004) 7:17–25. doi: 10.1007/s10024-003-3029-2
- Chevalier RL. Congenital urinary tract obstruction: the long view. *Adv Chronic Kidney Dis.* (2015) 22:312–9. doi: 10.1053/j.ackd.2015.01.012
- Chevalier RL, Thornhill BA, Chang AY. Unilateral ureteral obstruction in neonatal rats leads to renal insufficiency in adulthood. *Kidney Int.* (2000) 58:1987–95. doi: 10.1111/j.1523-1755.2000.00371.x
- Peters CA, Carr MC, Lais A, Retik AB, Mandell J. The response of the fetal kidney to obstruction. *J Urol.* (1992) 148:503–9. doi: 10.1016/S0022-534736640-5
- Peters CA. Animal models of fetal renal disease. *Prenat Diagn.* (2001) 21:917–23. doi: 10.1002/pd.211
- Elder JS, Stansbrey R, Dahms BB, Selzman AA. Renal histological changes secondary to ureteropelvic junction obstruction. *J Urol.* (1995) 154:719–22. doi: 10.1016/S0022-534767143-X
- Huang WY, Peters CA, Zurakowski D, Borer JG, Diamond DA, Bauer SB, et al. Renal biopsy in congenital ureteropelvic junction obstruction: evidence for parenchymal maldevelopment. *Kidney Int.* (2006) 69:137–43. doi: 10.1038/sj.ki.5000004
- Suresh S, Jindal S, Duvuru P, Lata S, Sadiya N. Fetal obstructive uropathy: impact of renal histopathological changes on prenatal interventions. *Prenat Diagn.* (2011) 31:675–7. doi: 10.1002/pd.2798
- Rosen S, Peters CA, Chevalier RL, Huang WY. The kidney in congenital ureteropelvic junction obstruction: a spectrum from normal to nephrectomy. *J Urol.* (2008) 179:1257–63. doi: 10.1016/j.juro.2007.11.048
- Koff SA, Campbell K. Nonoperative management of unilateral neonatal hydronephrosis. *J Urol.* (1992) 148:525–31. doi: 10.1016/S0022-534736644-2
- Koff SA, Campbell KD. The nonoperative management of unilateral neonatal hydronephrosis: natural history of poorly functioning kidneys. *J Urol.* (1994) 152:593–5. doi: 10.1016/S0022-534732658-7

18. Ulman I, Jayanthi VR, Koff SA. The long-term followup of newborns with severe unilateral hydronephrosis initially treated nonoperatively. *J Urol.* (2000) 164:1101–5. doi: 10.1016/S0022-534767262-X
19. Onen A, Jayanthi VR, Koff SA. Long-term followup of prenatally detected severe bilateral newborn hydronephrosis initially managed nonoperatively. *J Urol.* (2002) 168:1118–20. doi: 10.1016/S0022-534764604-6
20. Chertin B, Pollack A, Koulikov D, Rabinowitz R, Hain D, Hadas-Halpren I, et al. Conservative treatment of ureteropelvic junction obstruction in children with antenatal diagnosis of hydronephrosis: lessons learned after 16 years of follow-up. *Eur Urol.* (2006) 49:734–8. doi: 10.1016/j.eururo.2006.01.046
21. Yang Y, Hou Y, Niu ZB, Wang CL. Long-term follow-up and management of prenatally detected, isolated hydronephrosis. *J Pediatr Surg.* (2010) 45:1701–6. doi: 10.1016/j.jpedsurg.2010.03.030
22. Ross SS, Kardos S, Krill A, Bourland J, Sprague B, Majd M, et al. Observation of infants with SFU grades 3–4 hydronephrosis: worsening drainage with serial diuresis renography indicates surgical intervention and helps prevent loss of renal function. *J Pediatr Urol.* (2011) 7:266–71. doi: 10.1016/j.jpuro.2011.03.001
23. Arena S, Chimenz R, Antonelli E, Peri FM, Romeo P, Impellizzeri P, et al. A long-term follow-up in conservative management of unilateral ureteropelvic junction obstruction with poor drainage and good renal function. *Eur J Pediatr.* (2018) 177:1761–5. doi: 10.1007/s00431-018-3239-2
24. Thorup J, Jokela R, Cortes D, Nielsen OH. The results of 15 years of consistent strategy in treating antenatally suspected pelvi-ureteric junction obstruction. *BJU Int.* (2003) 91:850–2. doi: 10.1046/j.1464-410X.2003.04228.x
25. Lam BC, Wong SN, Yeung CY, Tang MH, Ghosh A. Outcome and management of babies with prenatal ultrasonographic renal abnormalities. *Am J Perinatol.* (1993) 10:263–8. doi: 10.1055/s-2007-994736
26. Katzir Z, Witzling M, Nikolov G, Gvirtz G, Arbel E, Kohelet D, et al. Neonates with extra-renal pelvis: the first 2 years. *Pediatr Nephrol.* (2005) 20:763–7. doi: 10.1007/s00467-005-1851-7
27. Nguyen HT, Benson CB, Bromley B, Campbell JB, Chow J, Coleman B, et al. Multidisciplinary consensus on the classification of prenatal and postnatal urinary tract dilation (UTD classification system). *J Pediatr Urol.* (2014) 10:982–98. doi: 10.1016/j.jpuro.2014.10.002
28. Weitz M, Schmidt M. To screen or not to screen for vesicoureteral reflux in children with ureteropelvic junction obstruction: a systematic review. *Eur J Pediatr.* (2017) 176:1–9. doi: 10.1007/s00431-016-2818-3
29. Lee NG, Rushton HG, Peters CA, Groves DS, Pohl HG. Evaluation of prenatal hydronephrosis: novel criteria for predicting vesicoureteral reflux on ultrasonography. *J Urol.* (2014) 192:914–8. doi: 10.1016/j.juro.2014.03.100
30. Klingensmith WC, 3rd, Briggs DE, Smith WI. Technetium-99m-MAG3 renal studies: normal range and reproducibility of physiologic parameters as a function of age and sex. *J Nucl Med.* (1994) 35:1612–7.
31. Taylor A, Manatunga A, Halkar R, Issa MM, Shenvi NV. A 7% decrease in the differential renal uptake of MAG3 implies a loss in renal function. *Urology.* (2010) 76:1512–6. doi: 10.1016/j.urol.2010.03.066
32. Song SH, Park S, Chae SY, Moon DH, Park S, Kim KS. Predictors of renal functional improvement after pyeloplasty in ureteropelvic junction obstruction: clinical value of visually assessed renal tissue tracer transit in (99m)Tc-mercaptoacetyl triglycine renography. *Urology.* (2017) 108:149–54. doi: 10.1016/j.urol.2017.05.044
33. Harper L, Bourquard D, Grosos C, Abbo O, Ferdynus C, Michel JL, et al. Cortical transit time as a predictive marker of the need for surgery in children with pelvi-ureteric junction stenosis: preliminary study. *J Pediatr Urol.* (2013) 9:1054–8. doi: 10.1016/j.jpuro.2013.03.002
34. Lee JN, Kang JK, Jeong SY, Lee SM, Cho MH, Ha YS, et al. Predictive value of cortical transit time on MAG3 for surgery in antenatally detected unilateral hydronephrosis caused by ureteropelvic junction stenosis. *J Pediatr Urol.* (2018) 14:55 e1–6. doi: 10.1016/j.jpuro.2017.08.009
35. Schlotmann A, Clorius JH, Rohrschneider WK, Clorius SN, Amelung F, Becker K. Diuretic renography in hydronephrosis: delayed tissue tracer transit accompanies both functional decline and tissue reorganization. *J Nucl Med.* (2008) 49:1196–203. doi: 10.2967/jnumed.107.049890
36. Jacobson DL, Flink CC, Johnson EK, Maizels M, Yerkes EB, Lindgren BW, et al. The correlation between serial ultrasound and diuretic renography in children with severe unilateral hydronephrosis. *J Urol.* (2018) 200:440–7. doi: 10.1016/j.juro.2018.03.126
37. Kostic D, Beozzo G, do Couto SB, Kato AHT, Lima L, Palmeira P, et al. The role of renal biomarkers to predict the need of surgery in congenital urinary tract obstruction in infants. *J Pediatr Urol.* (2019) 15:242 e1–9. doi: 10.1016/j.jpuro.2019.03.009
38. Froehlich JW, Kostel SA, Cho PS, Briscoe AC, Steen H, Vaezzadeh AR, et al. Urinary proteomics yield pathological insights for ureteropelvic junction obstruction. *Mol Cell Proteomics.* (2016) 15:2607–15. doi: 10.1074/mcp.M116.059386
39. Chevalier RL. Prognostic factors and biomarkers of congenital obstructive nephropathy. *Pediatr Nephrol.* (2016) 31:1411–20. doi: 10.1007/s00467-015-3291-3
40. Chertin B, Pollack A, Koulikov D, Rabinowitz R, Shen O, Hain D, et al. Does renal function remain stable after puberty in children with prenatal hydronephrosis and improved renal function after pyeloplasty? *J Urol.* (2009) 182(4 Suppl.):1845–8. doi: 10.1016/j.juro.2009.03.008
41. Assmus MA, Kiddoo DA, Hung RW, Metcalfe PD. Initially asymmetrical function on MAG3 renography increases incidence of adverse outcomes. *J Urol.* (2016) 195:1196–202. doi: 10.1016/j.juro.2015.11.011
42. Duong HP, Piepsz A, Collier F, Khelif K, Christophe C, Cassart M, et al. Predicting the clinical outcome of antenatally detected unilateral pelviureteric junction stenosis. *Urology.* (2013) 82:691–6. doi: 10.1016/j.urol.2013.03.041
43. Longpre M, Nguan A, Macneily AE, Afshar K. Prediction of the outcome of antenatally diagnosed hydronephrosis: a multivariable analysis. *J Pediatr Urol.* (2012) 8:135–9. doi: 10.1016/j.jpuro.2011.05.013
44. Arora S, Yadav P, Kumar M, Singh SK, Sureka SK, Mittal V, et al. Predictors for the need of surgery in antenatally detected hydronephrosis due to UPJ obstruction—a prospective multivariate analysis. *J Pediatr Urol.* (2015) 11:248 e1–5. doi: 10.1016/j.jpuro.2015.02.008
45. Shapiro SR, Wahl EF, Silberstein MJ, Steinhart G. Hydronephrosis index: a new method to track patients with hydronephrosis quantitatively. *Urology.* (2008) 72:536–8. doi: 10.1016/j.urol.2008.02.007
46. Cerrolaza JJ, Peters CA, Martin AD, Myers E, Safdar N, Linguraru MG. Quantitative ultrasound for measuring obstructive severity in children with hydronephrosis. *J Urol.* (2016) 195:1093–9. doi: 10.1016/j.juro.2015.10.173
47. Rickard M, Lorenzo AJ, Braga LH, Munoz C. Parenchyma-to-hydronephrosis area ratio is a promising outcome measure to quantify upper tract changes in infants with high-grade prenatal hydronephrosis. *Urology.* (2017) 104:166–71. doi: 10.1016/j.urol.2017.01.015
48. Kaselas C, Papouis G, Grigoriadis G, Klokakis A, Kaselas V. Pattern of renal function deterioration as a predictive factor of unilateral ureteropelvic junction obstruction treatment. *Eur Urol.* (2007) 51:551–5. doi: 10.1016/j.eururo.2006.05.053
49. Wagner M, Mayr J, Hacker FM. Improvement of renal split function in hydronephrosis with less than 10 % function. *Eur J Pediatr Surg.* (2008) 18:156–9. doi: 10.1055/s-2008-1038445
50. Gupta DK, Chandrasekharam VV, Srinivas M, Bajpai M. Percutaneous nephrostomy in children with ureteropelvic junction obstruction and poor renal function. *Urology.* (2001) 57:547–50. doi: 10.1016/S0090-429501046-3
51. Ismail A, Elkholy A, Zaghmout O, Alkadhi A, Elnaggar O, Khairat A, et al. Postnatal management of antenatally diagnosed ureteropelvic junction obstruction. *J Pediatr Urol.* (2006) 2:163–8. doi: 10.1016/j.jpuro.2005.07.005
52. Lee RS, Retik AB, Borer JG, Peters CA. Pediatric robot assisted laparoscopic dismembered pyeloplasty: comparison with a cohort of open surgery. *J Urol.* (2006) 175:683–7. doi: 10.1016/S0022-534700183-7
53. Peters CA, Schluskel RN, Retik AB. Pediatric laparoscopic dismembered pyeloplasty. *J Urol.* (1995) 153:1962–5. doi: 10.1016/S0022-534767378-6
54. Tan HL. Laparoscopic Anderson-Hynes dismembered pyeloplasty in children. *J Urol.* (1999) 162:1045–7. doi: 10.1016/S0022-534768060-1
55. Kutikov A, Resnick M, Casale P. Laparoscopic pyeloplasty in the infant younger than 6 months—is it technically possible? *J Urol.* (2006) 175:1477–9. doi: 10.1016/S0022-534700673-7
56. Piaggio LA, Franc-Guimond J, Noh PH, Wehry M, Figueroa TE, Barthold J, et al. Transperitoneal laparoscopic pyeloplasty for primary repair of ureteropelvic junction obstruction in infants and children: comparison with open surgery. *J Urol.* (2007) 178:1579–83. doi: 10.1016/j.juro.2007.03.159
57. Fuchs J, Luithe T, Warmann SW, Haber P, Blumenstock G, Szavay P. Laparoscopic surgery on upper urinary tract in children younger than 1

- year: technical aspects and functional outcome. *J Urol.* (2009) 182:1561–8. doi: 10.1016/j.juro.2009.06.063
58. Szavay PO, Luthle T, Seitz G, Warmann SW, Haber P, Fuchs J. Functional outcome after laparoscopic dismembered pyeloplasty in children. *J Pediatr Urol.* (2010) 6:359–63. doi: 10.1016/j.jpuro.2009.10.015
 59. Turner RM, 2nd, Fox JA, Tomaszewski JJ, Schneck FX, Docimo SG, Ost MC. Laparoscopic pyeloplasty for ureteropelvic junction obstruction in infants. *J Urol.* (2013) 189:1503–7. doi: 10.1016/j.juro.2012.10.067
 60. Garcia-Aparicio L, Blazquez-Gomez E, Martin O, Manzanara A, Garcia-Smith N, Bejarano M, et al. Anderson-hynes pyeloplasty in patients less than 12 months old. Is the laparoscopic approach safe and feasible? *J Endourol.* (2014) 28:906–8. doi: 10.1089/end.2013.0704
 61. Chandrasekharam VV. Laparoscopic pyeloplasty in infants: single-surgeon experience. *J Pediatr Urol.* (2015) 11:272 e1–5. doi: 10.1016/j.jpuro.2015.05.013
 62. Casale P. Robotic pyeloplasty in the pediatric population. *Curr Opin Urol.* (2009) 19:97–101. doi: 10.1097/MOU.0b013e32831ac6e8
 63. Barbosa JA, Kowal A, Onal B, Gouveia E, Walters M, Newcomer J, et al. Comparative evaluation of the resolution of hydronephrosis in children who underwent open and robotic-assisted laparoscopic pyeloplasty. *J Pediatr Urol.* (2013) 9:199–205. doi: 10.1016/j.jpuro.2012.02.002
 64. Sorensen MD, Delostrinos C, Johnson MH, Grady RW, Lendvay TS. Comparison of the learning curve and outcomes of robotic assisted pediatric pyeloplasty. *J Urol.* (2011) 185(6 Suppl.):2517–22. doi: 10.1016/j.juro.2011.01.021
 65. Kutikov A, Nguyen M, Guzzo T, Canter D, Casale P. Robot assisted pyeloplasty in the infant-lessons learned. *J Urol.* (2006) 176:2237–9. doi: 10.1016/j.juro.2006.07.059
 66. Dangle PP, Kearns J, Anderson B, Gundeti MS. Outcomes of infants undergoing robot-assisted laparoscopic pyeloplasty compared to open repair. *J Urol.* (2013) 190:2221–6. doi: 10.1016/j.juro.2013.07.063
 67. Baek M, Silay MS, Au JK, Huang GO, Elizondo RA, Puttmann KT, et al. Does the use of 5 mm instruments affect the outcomes of robot-assisted laparoscopic pyeloplasty in smaller working spaces? A comparative analysis of infants and older children. *J Pediatr Urol.* (2018) 14:537 e1–6. doi: 10.1016/j.jpuro.2018.06.010
 68. Avery DI, Herbst KW, Lendvay TS, Noh PH, Dangle P, Gundeti MS, et al. Robot-assisted laparoscopic pyeloplasty: multi-institutional experience in infants. *J Pediatr Urol.* (2015) 11:139 e1–5. doi: 10.1016/j.jpuro.2014.11.025
 69. Rowe CK, Pierce MW, Tecci KC, Houck CS, Mandell J, Retik AB, et al. A comparative direct cost analysis of pediatric urologic robot-assisted laparoscopic surgery versus open surgery: could robot-assisted surgery be less expensive? *J Endourol.* (2012) 26:871–7. doi: 10.1089/end.2011.0584
 70. Behan JW, Kim SS, Dorey F, De Filippo RE, Chang AY, Hardy BE, et al. Human capital gains associated with robotic assisted laparoscopic pyeloplasty in children compared to open pyeloplasty. *J Urol.* (2011) 186(4 Suppl.):1663–7. doi: 10.1016/j.juro.2011.04.019
 71. Casella DP, Fox JA, Schneck FX, Cannon GM, Ost MC. Cost analysis of pediatric robot-assisted and laparoscopic pyeloplasty. *J Urol.* (2013) 189:1083–6. doi: 10.1016/j.juro.2012.08.259
 72. Varda BK, Wang Y, Chung BI, Lee RS, Kurtz MP, Nelson CP, et al. Has the robot caught up? National trends in utilization, perioperative outcomes, and cost for open, laparoscopic, and robotic pediatric pyeloplasty in the United States from 2003 to 2015. *J Pediatr Urol.* (2018) 14:336 e1–8. doi: 10.1016/j.jpuro.2017.12.010
 73. Varda BK, Johnson EK, Clark C, Chung BI, Nelson CP, Chang SL. National trends of perioperative outcomes and costs for open, laparoscopic and robotic pediatric pyeloplasty. *J Urol.* (2014) 191:1090–5. doi: 10.1016/j.juro.2013.10.077
 74. Silay MS, Spinoit AF, Undre S, Fiala V, Tandogdu Z, Garmanova T, et al. Global minimally invasive pyeloplasty study in children: results from the pediatric urology expert group of the european association of urology young academic urologists working party. *J Pediatr Urol.* (2016) 12:229 e1–7. doi: 10.1016/j.jpuro.2016.04.007
 75. Tasian GE, Wiebe DJ, Casale P. Learning curve of robotic assisted pyeloplasty for pediatric urology fellows. *J Urol.* (2013) 190(4 Suppl.):1622–6. doi: 10.1016/j.juro.2013.02.009
 76. Sukumar S, Djahangirian O, Sood A, Sammon JD, Varda B, Janosek-Albright K, et al. Minimally invasive vs. open pyeloplasty in children: the differential effect of procedure volume on operative outcomes. *Urology.* (2014) 84:180–4. doi: 10.1016/j.urolgy.2014.02.002

Conflict of Interest: The authors declare that the research was conducted in the absence of any commercial or financial relationships that could be construed as a potential conflict of interest.

Copyright © 2020 Passoni and Peters. This is an open-access article distributed under the terms of the Creative Commons Attribution License (CC BY). The use, distribution or reproduction in other forums is permitted, provided the original author(s) and the copyright owner(s) are credited and that the original publication in this journal is cited, in accordance with accepted academic practice. No use, distribution or reproduction is permitted which does not comply with these terms.



Searching for the Least Invasive Management of Pelvi-Ureteric Junction Obstruction in Children: A Critical Literature Review of Comparative Outcomes

Marco Castagnetti¹, Massimo Iafrate¹, Ciro Esposito² and Ramnath Subramaniam^{3,4*}

¹ Section of Paediatric Urology, Department of Surgical, Oncological, and Gastrointestinal Sciences, University Hospital of Padova, Padua, Italy, ² Department of Paediatrics, Federico II University of Naples, Naples, Italy, ³ Department of Paediatric Urology, Leeds Teaching Hospitals NHS Trust, University of Leeds, Leeds, United Kingdom, ⁴ Department of Paediatric Urology, University of Ghent, Ghent, Belgium

OPEN ACCESS

Edited by:

Abdurrahman Onen,
Onen Pediatric Urology Center, Turkey

Reviewed by:

Craig Andrew Peters,
University of Texas Southwestern
Medical Center, United States
Andres Gomez Fraile,
University Hospital October 12, Spain

*Correspondence:

Ramnath Subramaniam
r.subramaniam@leeds.ac.uk

Specialty section:

This article was submitted to
Pediatric Urology,
a section of the journal
Frontiers in Pediatrics

Received: 16 March 2020

Accepted: 22 April 2020

Published: 02 June 2020

Citation:

Castagnetti M, Iafrate M, Esposito C
and Subramaniam R (2020) Searching
for the Least Invasive Management of
Pelvi-Ureteric Junction Obstruction in
Children: A Critical Literature Review
of Comparative Outcomes.
Front. Pediatr. 8:252.
doi: 10.3389/fped.2020.00252

Introduction: To review the published evidence on the minimally invasive pyeloplasty techniques available currently with particular emphasis on the comparative data about the various minimally invasive alternatives to treat pelvi-ureteric junction obstruction and gauge if one should be favored under certain circumstances.

Materials and Methods: Non-systematic review of literature on open and minimally invasive pyeloplasty including various kinds of laparoscopic procedures, the robotic-assisted laparoscopic pyeloplasty, and endourological procedures.

Results: Any particular minimally invasive pyeloplasty procedure seems feasible in experienced hands, irrespective of age including infants. Comparative data suggest that the robotic-assisted procedure has gained wider acceptance mainly because it is ergonomically more suited to surgeon well-being and facilitates advanced skills with dexterity thanks to 7 degrees of freedom. However, costs remain the major drawback of robotic surgery. In young children and infants, instead, open surgery can be performed via a relatively small incision and quicker time frame.

Conclusions: The best approach for pyeloplasty is still a matter of debate. The robotic approach has gained increasing acceptance over the last years with major advantages of the surgeon well-being and ergonomics and the ease of suturing. Evidence, however, may favor the use of open surgery in infancy.

Keywords: pyeloplasty, pelvi-ureteric junction, obstructive uropathy, hydronephrosis, minimally-invasive surgery, robotic surgery

INTRODUCTION

Open pyeloplasty has been for ages considered the gold standard treatment of pyelo-ureteric junction (PUJ) obstruction, and the standards of open pyeloplasty were set back in 1998 by Gerard Monfort (1). Using optical magnification and fine suture materials, it has been shown that the procedure can be performed as a day case surgery, without any indwelling stent, with >95% success rate. Long-term durability of open pyeloplasty has also been well-documented (2).

Despite the good outcomes of open pyeloplasty, the search for less invasive treatment modalities alternative to open pyeloplasty has continued. The potential advantages of a minimally invasive approach for the dissection have never been questioned; the main hurdle lies with the accomplishment of the pyelo-ureteral anastomosis that can require advanced suturing skills and can be time-consuming even in experienced hands, a fact particularly true with laparoscopic techniques (3). Consistently, in a systematic review and meta-analysis of open vs. minimally invasive pyeloplasty (MIP) performed in 2014, Autorino et al. observed that although MIP procedures can achieve complication and success rates comparable to open surgery, the operating time still largely favors open pyeloplasty (4). More importantly, multiple reports coming for different institutions prove that open pyeloplasty is safe and duplicable in the widespread use, and duplicability of the MIP procedure is more controversial as the skills necessary to perform the procedure can be hard to achieve and maintain (5). The most complex scenario is clearly that of a pyeloplasty performed in an infant (6), which is not an uncommon scenario with prenatal diagnosis, the most common presentation of PUJ obstruction, and most of these patients who require surgery do so in infancy (7).

The aim of the present review was to summarize the available evidence on the MIP techniques currently available with particular emphasis on the comparative data about the various MIP alternatives to gauge if one should be favored under certain circumstances.

MIP TECHNIQUES

MIP is an umbrella term that encompasses several techniques including laparoscopic surgery and robotic-assisted laparoscopic pyeloplasty (RALP) and can be performed using a trans-peritoneal or a retro-peritoneal route. The standard robotic instruments are 8 mm with cable-driven hinges, and although 5-mm instruments with metal hinges are available, the range of movements is difficult to realize especially in limited space. Traditional laparoscopic approach can be achieved with a 5-mm camera and 3-mm instruments, also referred to as “Mini-laparoscopy.” Other recognized approaches include single-site surgery or one-trocar-assisted pyeloplasty (OTAP).

Single-site surgery also known as LESS (laparo-endoscopic single site) surgery is performed introducing all the instruments necessary to perform the procedure via a single umbilical incision, with or without a specific device (8). In the OTAP, instead, the dissection is performed laparoscopically using a retroperitoneal approach, whereas the PUJ is delivered outside the abdomen to perform the pyeloplasty externally like in open surgery (9). This procedure potentially combines the putative advantages of both a minimally invasive dissection and an easier open pyeloplasty keeping the incision small at the same time. The major limitation of the OTAP is patient size, as delivery of the PUJ can possibly be difficult in older patients.

In terms of the procedure, dismembered Anderson–Hynes pyeloplasty is the standard technique of choice. In MIP, this

TABLE 1 | Single institution series on minimally invasive treatment of pelvi-ureteric junction obstruction.

Series	Technique	N of Pts	Conversion rate	Failure rate
Chandarasekaram (17)	Laparoscopy	111	0	1%
Blanc et al. (18)	Retroperitoneoscopy	104	3%	2%
Lima et al. (9)	OTAP	155	8%	1%
Minnillo et al. (19)	RALP	155	0	3%
Parente et al. (14)	Balloon dilatation	50	0	10%

procedure requires advanced skills of suturing, which some surgeons find tedious and not comfortable ergonomically (10, 11). In order to circumvent the problems related to the suturing skills necessary to perform the procedure minimally invasively, in recent years, interest has increased with alternatives, such as the vascular hitch for PUJ obstructions due to extrinsic compression by a crossing vessel (12), or non-dismembered pyeloplasty for intrinsic PUJ obstructions (13). RALP is definitely the superior approach facilitating advanced suturing skills in MIP although cost is the main prohibitive factor preventing widespread acceptance as alluded to later on in this article.

Endourological techniques can also be considered minimally invasive modalities to treat PUJ obstruction. These include a range of procedures, such as the balloon dilatation of the PUJ and the endopyelotomy (14, 15) with availability of cutting balloons combining dilatation and endopyelotomy (16). Any endourological procedures can be performed using a retrograde or antegrade approach.

SINGLE-INSTITUTION RESULTS

For any of the mentioned minimally invasive treatment modalities, single-surgeon or single-institution series exist documenting feasibility and effectiveness (Table 1). The procedure can be carried out successfully at any age including infancy, although it is clearly more demanding in small patients given the small available operating space (20). Only endourological techniques are probably an exception; even in the most experienced hands, reported failure rate is 2- to 3-fold higher than the other techniques (Table 1). Consistently, a systematic review published in 2015 shows that this treatment modality has not gained wide acceptance (only 128 cases reported) and the complication rate (14.8%) is much higher and the median success rate (71%) is much lower than those reported for MIP (15). Nevertheless, for all the MIP techniques, duplicability and cost-effectiveness remain to be proven and we still need comparative data to assess which technique is more effective and under which circumstances.

COMPARATIVE DATA ON MIP PROCEDURES

An analysis of the published literature regarding RALP shows that despite the constantly increasing number of publications over years, the level of evidence for available studies remains limited to case reports, case series, and retrospective comparative studies (21). This issue, however, is unfortunately true for any MIP procedure (21).

In terms of comparative data, we have studies comparing laparoscopy pyeloplasty vs. endourological management, laparoscopic vs. retroperitoneoscopic pyeloplasty, and laparoscopic vs. robot-assisted pyeloplasty.

In the single series comparing retrograde balloon dilatation and laparoscopic pyeloplasty, balloon dilatation had a significantly shorter operating time and hospital stay, and significantly lower analgesic requirement and costs (22). The study confirms, however, that the real issue with the endourological techniques is the success rate, particularly in the long term. Balloon dilatation seems not to be a durable procedure. Both procedures indeed had comparable success rate at 3 months, 94.7% for balloon dilatation vs. 97.1% of laparoscopic pyeloplasty, but the success rate of balloon dilatation progressively dropped to 71% at 2 years follow-up, becoming significantly lower than laparoscopic pyeloplasty, the success rate for which instead remained pretty steady over time (22).

The comparison of laparoscopic vs. retroperitoneoscopic pyeloplasty has been the objective of one of the few randomized clinical trials available in pediatric urology. Badawy et al. compared 19 patients randomized to each MIP approach (23). Success rate was comparable, whereas the retroperitoneal approach had shorter operative time by an average 40 min with earlier resumption of oral feeding and, as a consequence, shorter hospital stay. These data are in contrast with those of what is probably the largest single surgeon series of pyeloplasty available in the literature by Liu et al. (8). This series includes 1,750 pyeloplasties, 451 retroperitoneoscopic, 311 laparoscopic, 322 LESS, and 805 trans-umbilical multiport. The two approaches had comparable complication and success rate in both these reports, with the retroperitoneoscopic approach having quicker resumption of oral feeding and shorter hospital stay. However, in the latter series (8), the complication rate was higher and operative time was significantly longer for retroperitoneoscopy than any other MIP procedure in contrast to the report by Badawy et al. (23). These results are consistent with a meta-analysis of one randomized clinical trial and eight clinical trials (776 participants) in adults (24). In summary, these data suggest that the trans-peritoneal approach may be easier to perform while the creation of a retroperitoneal working chamber might increase the complexity of the procedure, making it longer and increasing the risk of conversion. Potential disadvantages of trans-peritoneal route include a longer post-operative ileus, the risk of intraperitoneal urine leakage post-operatively and adhesions formation in the long term.

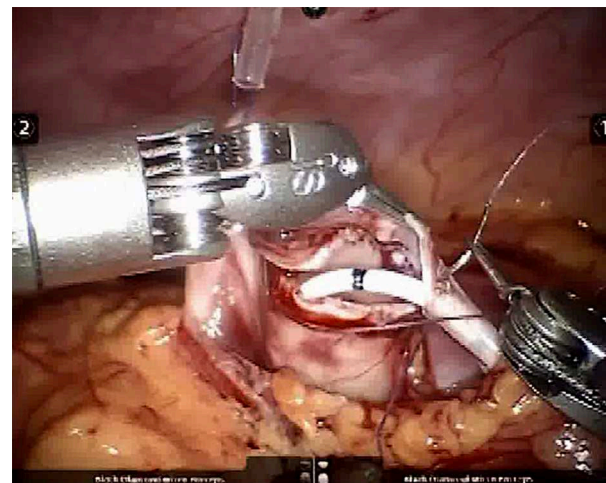


FIGURE 1 | Intraoperative picture showing the potential for articulation of the robotic instruments, which greatly simplifies suturing.

The comparison between laparoscopic and RALP is the one that has attracted more attention in the recent past. Since 2009, four systematic reviews and meta-analyses have been published on this topic (4, 25–27). The most recent one includes 14 studies: 1 prospective trial, 1 case-control, and 12 retrospective series (27). Once again, the general level of evidence is low, but the quality of studies was quite good with a low risk of bias in 10 out of 14. The meta-analysis showed that the operating time was equivalent, whereas all the other outcome parameters including hospital stay, complication rate, success rate, and re-intervention rate favored or tended to favor the robotic-assisted procedure.

This is consistent with the putative advantages of the robotic approach, including comfortable position for the surgeon, 3D view, and steady instruments with 7 degrees of freedom that make suturing much easier (**Figure 1**). It sounds reasonable that operating in a more comfortable way allows better results. It is well-documented that long-lasting laparoscopic procedures might cause chronic musculo-skeletal discomfort to the surgeon (11).

Consistently with this observation, Varda et al., analyzing the trend in utilization of open, laparoscopic, and robotic pyeloplasty in the United States from 2003 to 2015, reported since 2004, when the Da Vinci system became available, that the number of MIP procedures has progressively increased, mainly due to an increase in the number of robotic-assisted procedures, whereas the number of laparoscopic procedure has progressively decreased (28). Although not considered in the meta-analyses, another potential advantage of the robotic approach over conventional laparoscopy is that its learning curve is less steep (29), and since the use of robotic surgery further limits the volume of cases undergoing laparoscopic surgery, it is likely that the increased use of robotic surgery will permanently limit the use of conventional laparoscopic pyeloplasty in children, in the centers where the robot is available.

ROBOTIC-ASSISTED LAPAROSCOPIC PYELOPLASTY

The two major drawbacks of robotic-assisted pyeloplasty include costs and the size of the instruments.

Varda et al. estimated costs of open, laparoscopic, and robotic pyeloplasty and noted that the latter has a significantly higher cost mainly due to the cost of the consumables (28). This model, however, does not take into account the cost of the robot itself. Using a mathematical model, Behan et al. estimated that, in a center performing 100 RALP per year, the cost of the robot would not be neutralized even after 10 years (30).

Costs can be reduced using appropriate strategies. The first step is to reduce the console time and operating room turnover. Seidman et al. estimated that with a 2-days in-stay, RP could be cost-effective (when compared with LP) if it was carried out in under 120 min (31). Console time normally decreases with increasing experience and progression in the learning curve. It should be noted, however, that trainee involvement with the robot may make it difficult to lower console time as fellows and residents turnover regularly (32). Having a team specialized and dedicated just to robotic cases, instead, can reduce turnover time, particularly docking and undocking time (32, 33).

Increased and regular utilization of the robot by multiple services, i.e., increasing the volume of robotic procedures, is another important cost-saving strategy (32, 33).

Finally, increasing competition within the industry could translate into the end of the current monopoly, which could then translate to steadily reduce the cost of the robotic equipment, making robotics a more cost-effective and affordable technique (33).

The other issue is the size of the robotic instruments. The most modern standard instruments are 8 mm in size and also the arms of the robot are cumbersome. Smaller, 5-mm instruments do exist (34), but they have a pulley system that limits articulation and precludes certain movements. For this reason, many surgeons recommend the routine use of 8-mm instruments for all pediatric cases irrespective of age (35).

Consistently, splitting the results reported by Varda et al. by the age of the patients undergoing pyeloplasty, it is apparent that the use of the RALP mainly increased in the adolescent age group (13–18 years), whereas its use was very limited in infants (28).

PYELOPLASTY IN INFANTS

In the era of antenatal diagnosis of hydronephrosis, the infantile group represents an important age group for surgery. In this group of patients, RALP is feasible, but its role seems limited and has not gained wide acceptance. One issue is the size of the instruments mentioned above. In this, the use of 3-mm instruments, the so called mini-laparoscopy, can be advantageous (36) (**Figure 2**). Nevertheless, the accomplishment of a pyeloplasty in the limited space of an infant abdomen can be extremely demanding. Moreover, in younger patients, MIP does not seem to offer the same advantages in terms of shorter

hospital stay and lower narcotic requirements observed instead in pre-adolescent and adolescent patients (37).

The second and perhaps the most relevant issue in this age group is the concern about the potential neurotoxicity of the drugs for the general anesthesia in early childhood (38, 39). For this reason, many authors and scientific societies recommend in this age group, if surgery cannot be postponed, at least

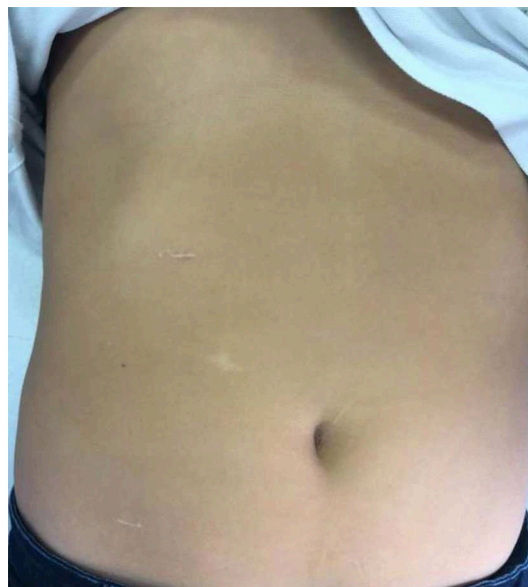


FIGURE 2 | Scar appearance after laparoscopic pyeloplasty.

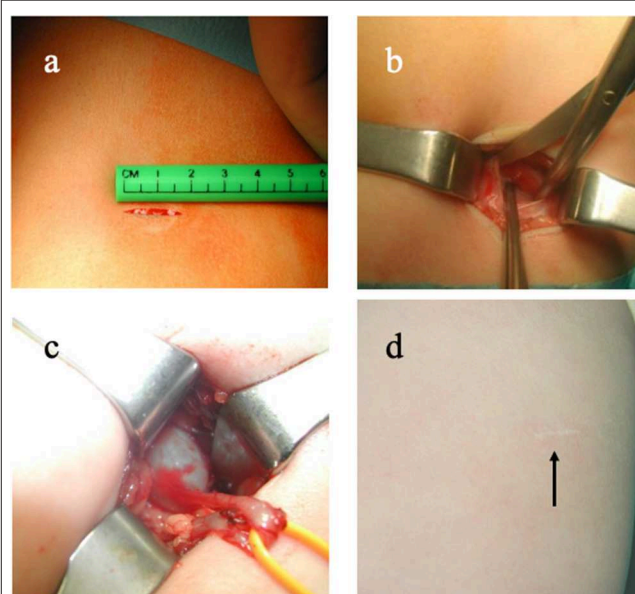


FIGURE 3 | Example of minimally invasive open pyeloplasty. (a) 2-cm incision; (b) muscle-sparing approach; (c) delivery of the pelvi-ureteric junction via the incision; (d) barely visible scar 6 months after the procedure.

the quickest procedure should be preferred. Published evidence overall thus far, as regards operative time, favors open pyeloplasty over MIP procedures (4).

In this respect, it is relevant that the procedure can be performed via such a small approach in infants to be called “minimally invasive open pyeloplasty” (40–42). Chako et al. reported that in patients <5 years, the procedure can be performed via an incision <3 cm in about 100 min on average combining a quick procedure with good cosmetic outcome (42) (**Figure 3**). However, some potential limitations of this approach should be considered. A small incision limits exposure of the anatomical structures, which can be an issue in case of unexpected anatomical variants. For this reason, advocates of this approach have underscored the importance of determining the exact incision site by intraoperative renal ultrasonography (40), and/or performing a retrograde pyelogram at the beginning of the surgery to define exactly the PUJ anatomy (41). Otherwise, a minimally invasive approach might prove somewhat more flexible while dealing with unexpected variants. Nevertheless, performing a pyeloplasty in an abnormal kidney and in an infant abdomen remains a formidable endeavor.

COSMETIC RESULTS OF OPEN VS. MIP

Cosmetic results are a relevant aspect in the decision-making. Gatte et al. performing a randomized, prospective, controlled trial comparing laparoscopic vs. open pyeloplasty concluded that both approaches are comparable and equally effective methods for repair of PUJ obstruction. Although operative time seems statistically shorter in the open group and length of stay seems shorter in the laparoscopic group, the choice should be based

on family preference for incision aesthetics and surgeon comfort with either approach, rather than more classically objective outcome measures (43). In this respect, Wang et al. confirmed that larger initial incisions tend to grow more; therefore, at the same follow-up interval, laparoscopic incisions are smaller than those of open procedures (44). Barbosa et al. studied family preferences based on the assessment of pictures and diagrams of the scars of open pyeloplasty and RALP (45). They reported that families prefer the RALP scars both based on pictures and diagrams. Nevertheless, this held true only provided that there was no apparent medical benefit associated with one of the two procedures. Moreover, the approach did not seem to be a statistically significant factor in patients being pleased or not with the scar appearance in the study by Wang et al. (44).

CONCLUSIONS

Any MIP procedure seems feasible in experienced hands, even in infants. The best approach for pyeloplasty is still a matter of debate. The robotic approach seems to have gained increasing acceptance over the last years with major advantages being ergonomics and the ease of suturing. Costs and the size of the instruments remain major drawbacks for the application of the robotic approach in children. Evidence may favor the use of open surgery in infancy.

AUTHOR CONTRIBUTIONS

MC and RS drafted the manuscript, reviewed the literature, and also supplied one figure each. MI and CE suggested the articles for review and gave advice during the process of writing the manuscript. CE also supplied one figure.

REFERENCES

- Guys JM, Borella F, Monfort G. Ureteropelvic junction obstructions: prenatal diagnosis and neonatal surgery in 47 cases. *J Pediatr Surg.* (1988) 23:156–8. doi: 10.1016/S0022-3468(88)80148-9
- O'Reilly PH, Brooman PJ, Mak S, Jones M, Pickup C, Atkinson C, et al. The long-term results of Anderson-Hynes pyeloplasty. *BJU Int.* (2001) 87:287–9. doi: 10.1046/j.1464-410x.2001.00108.x
- Esposito C, Masieri L, Castagnetti M, Sforza S, Farina A, Cerulo M, et al. Robot-assisted vs laparoscopic pyeloplasty in children with uretero-pelvic junction obstruction (UPJO): technical considerations and results. *J Pediatr Urol.* (2019) 15:667.e1–8. doi: 10.1016/j.jpuro.2019.09.018
- Autorino R, Eden C, El-Ghoneimi A, Guazzoni G, Buffi N, Peters CA, et al. Robot-assisted and laparoscopic repair of ureteropelvic junction obstruction: a systematic review and meta-analysis. *Eur Urol.* (2014) 65:430–52. doi: 10.1016/j.eururo.2013.06.053
- Silay MS, Spinoit AF, Undre S, Fiala V, Tandogdu Z, Garmanova T, et al. Global minimally invasive pyeloplasty study in children: results from the pediatric urology expert group of the european association of urology young academic urologists working party. *J Pediatr Urol.* (2016) 12:229.e1–7. doi: 10.1016/j.jpuro.2016.04.007
- Zamfir Snykers C, De Plaen E, Vermersch S, Lopez M, Khelif K, Luyckx S, et al. Laparoscopic pyeloplasty for ureteropelvic junction obstruction in infants under 1 year of age a good option? *Front Pediatr.* (2019) 7:352. doi: 10.3389/fped.2019.00352
- Vemulakonda V, Yiee J, Wilcox DT. Prenatal hydronephrosis: postnatal evaluation and management. *Curr Urol Rep.* (2014) 15:430. doi: 10.1007/s11934-014-0430-5
- Liu D, Zhou H, Ma L, Zhou X, Cao H, Tao T, et al. Comparison of laparoscopic approaches for dismembered pyeloplasty in children with ureteropelvic junction obstruction: critical analysis of 11-year experiences in a single surgeon. *Urology.* (2017) 101:50–5. doi: 10.1016/j.urol.2016.10.007
- Lima M, Ruggeri G, Messina P, Tursini S, Destro F, Moggiatti M. One-trocar-assisted pyeloplasty in children: an 8-year single institution experience. *Eur J Pediatr Surg.* (2015) 25:262–8. doi: 10.1055/s-0034-1372459
- Piaggio LA, Franc-Guimond J, Noh PH, Wehry M, Figueroa TE, Barthold J, et al. Transperitoneal laparoscopic pyeloplasty for primary repair of ureteropelvic junction obstruction in infants and children: comparison with open surgery. *J Urol.* (2007) 178:1579–83. doi: 10.1016/j.juro.2007.03.159
- Esposito C, El Ghoneimi A, Yamataka A, Rothenberg S, Bailez M, Ferro M, et al. Work-related upper limb musculoskeletal disorders in paediatric laparoscopic surgery. A multicenter survey. *J Pediatr Surg.* (2013) 48:1750–6. doi: 10.1016/j.jpedsurg.2013.01.054
- Villemagne T, Fourcade L, Camby C, Szwarc C, Lardy H, Leclair MD. Long-term results with the laparoscopic transposition of renal lower pole crossing vessels. *J Pediatr Urol.* (2015) 11:174.e1–7. doi: 10.1016/j.jpuro.2015.04.023
- Polok M, Chrzan R, Veenboer P, Beyerlein S, Dik P, Klijn A, et al. Nondismembered pyeloplasty in a pediatric population: results of 34 open and laparoscopic procedures. *Urology.* (2011) 78:891–4. doi: 10.1016/j.urol.2011.04.039

14. Parente A, Angulo JM, Romero RM, Rivas S, Burgos L, Tardáguila A. Management of ureteropelvic junction obstruction with high-pressure balloon dilatation: long-term outcome in 50 children under 18 months of age. *Urology*. (2013) 82:1138–43. doi: 10.1016/j.urology.2013.04.072
15. Corbett HJ, Mullassery D. Outcomes of endopyelotomy for pelviureteric junction obstruction in the paediatric population: a systematic review. *J Pediatr Urol*. (2015) 11:328–36. doi: 10.1016/j.jpuro.2015.08.014
16. Parente A, Perez-Egido L, Romero RM, Ortiz R, Burgos L, Angulo JM. Retrograde endopyelotomy with cutting balloon™ for treatment of ureteropelvic junction obstruction in infants. *Front Pediatr*. (2016) 4:72. doi: 10.3389/fped.2016.00072
17. Chandrasekharam VV. Laparoscopic pyeloplasty in infants: single-surgeon experience. *J Pediatr Urol*. (2015) 11:272.e1–5. doi: 10.1016/j.jpuro.2015.05.013
18. Blanc T, Muller C, Abdoul H, Peev S, Paye-Jaouen A, Peycelon M, et al. Retroperitoneal laparoscopic pyeloplasty in children: long-term outcome and critical analysis of 10-year experience in a teaching center. *Eur Urol*. (2013) 63:565–72. doi: 10.1016/j.eururo.2012.07.051
19. Minnillo BJ, Cruz JA, Sayao RH, Passerotti CC, Houck CS, Meier PM, et al. Long-term experience and outcomes of robotic assisted laparoscopic pyeloplasty in children and young adults. *J Urol*. (2011) 185:1455–60. doi: 10.1016/j.juro.2010.11.056
20. Badawy H, Saad A, Fahmy A, Dawood W, Aboulfotouh A, Kamal A, et al. Prospective evaluation of retroperitoneal laparoscopic pyeloplasty in children in the first 2 years of life: is age a risk factor for conversion? *J Pediatr Urol*. (2017) 13:511.e1–4. doi: 10.1016/j.jpuro.2017.03.025
21. Cundy TP, Harley SJD, Marcus HJ, Hughes-Hallett A, Khurana S. Global trends in paediatric robot-assisted urological surgery: a bibliometric and progressive scholarly acceptance analysis. *J Robot Surg*. (2018) 12:109–15. doi: 10.1007/s11701-017-0703-3
22. Xu N, Chen SH, Xue XY, Zheng QS, Wei Y, Jiang T, et al. Comparison of retrograde balloon dilatation and laparoscopic pyeloplasty for treatment of ureteropelvic junction obstruction: results of a 2-year follow-up. *PLoS ONE*. (2016) 11:e0152463. doi: 10.1371/journal.pone.0152463
23. Badawy H, Zoaier A, Ghoneim T, Hanno A. Transperitoneal versus retroperitoneal laparoscopic pyeloplasty in children: randomized clinical trial. *J Pediatr Urol*. (2015) 11:122.e1–6. doi: 10.1016/j.jpuro.2014.11.019
24. Wu Y, Dong Q, Han P, Liu L, Wang L, Wei Q. Meta-analysis of transperitoneal versus retroperitoneal approaches of laparoscopic pyeloplasty for ureteropelvic junction obstruction. *J Laparoendosc Adv Surg Tech A*. (2012) 22:658–62. doi: 10.1089/lap.2011.0508
25. Braga LH, Pace K, DeMaria J, Lorenzo AJ. Systematic review and meta-analysis of robotic-assisted versus conventional laparoscopic pyeloplasty for patients with ureteropelvic junction obstruction: effect on operative time, length of hospital stay, postoperative complications, and success rate. *Eur Urol*. (2009) 56:848–57. doi: 10.1016/j.eururo.2009.03.063
26. Cundy TP, Harling L, Hughes-Hallett A, Mayer EK, Najmaldin AS, Athanasios T, et al. Meta-analysis of robot-assisted vs conventional laparoscopic and open pyeloplasty in children. *BJU Int*. (2014) 114:582–94. doi: 10.1111/bju.12683
27. Taktak S, Llewellyn O, Aboelsoud M, Hajibandeh S, Hajibandeh S. Robot-assisted laparoscopic pyeloplasty versus laparoscopic pyeloplasty for pelvi-ureteric junction obstruction in the paediatric population: a systematic review and meta-analysis. *Ther Adv Urol*. (2019) 11:1756287219835704. doi: 10.1177/1756287219835704
28. Varda BK, Wang Y, Chung BI, Lee RS, Kurtz MP, Nelson CP, et al. Has the robot caught up? National trends in utilization, perioperative outcomes, and cost for open, laparoscopic, and robotic pediatric pyeloplasty in the United States from 2003 to 2015. *J Pediatr Urol*. (2018) 14:336.e1–8. doi: 10.1016/j.jpuro.2017.12.010
29. Reinhardt S, Ifaoui IB, Thorup J. Robotic surgery start-up with a fellow as the console surgeon. *Scand J Urol*. (2017) 51:335–8. doi: 10.1080/21681805.2017.1302990
30. Behan JW, Kim SS, Dorey F, De Filippo RE, Chang AY, Hardy BE, et al. Human capital gains associated with robotic assisted laparoscopic pyeloplasty in children compared to open pyeloplasty. *J Urol*. (2011) 186:1663–7. doi: 10.1016/j.juro.2011.04.019
31. Seideman CA, Sleeper JP, Lotan Y. Cost comparison of robot-assisted and laparoscopic pyeloplasty. *J Endourol*. (2012) 26:1044–8. doi: 10.1089/end.2012.0026
32. Cardona-Grau D, Bayne CE. Featuring: has the robot caught up? National trends in utilization, perioperative outcomes, and cost for open, laparoscopic, and robotic pediatric pyeloplasty in the United States from 2003 to 2015. *J Pediatr Urol*. (2018) 14:210–1. doi: 10.1016/j.jpuro.2018.05.013
33. Gkegkes ID, Mamais IA, Iavazzo C. Robotics in general surgery: a systematic cost assessment. *J Minim Access Surg*. (2017) 13:243–55. doi: 10.4103/0972-9941.195565
34. Baek M, Silay MS, Au JK, Huang GO, Elizondo RA, Puttmann KT, et al. Does the use of 5 mm instruments affect the outcomes of robot-assisted laparoscopic pyeloplasty in smaller working spaces? A comparative analysis of infants and older children. *J Pediatr Urol*. (2018) 14:537.e1–6. doi: 10.1016/j.jpuro.2018.06.010
35. Boysen WR, Gundeti MS. Robot-assisted laparoscopic pyeloplasty in the pediatric population: a review of technique, outcomes, complications, and special considerations in infants [published correction appears in *pediatr surg int* 2017. *Pediatr Surg Int*. (2017) 33:925–35. doi: 10.1007/s00383-017-4082-7
36. Simforoosh N, Abedi A, Hosseini Sharifi SH, Poor Zamany NKM, Rezaeetalab GH, Obayd K, et al. Comparison of surgical outcomes and cosmetic results between standard and mini laparoscopic pyeloplasty in children younger than 1 year of age. *J Pediatr Urol*. (2014) 10:819–23. doi: 10.1016/j.jpuro.2014.01.026
37. Tanaka ST, Grantham JA, Thomas JC, Adams MC, Brock JW III, Pope JC IV. A comparison of open vs laparoscopic pediatric pyeloplasty using the pediatric health information system database—do benefits of laparoscopic approach recede at younger ages? *J Urol*. (2008) 180:1479–85. doi: 10.1016/j.juro.2008.06.044
38. Rappaport BA, Suresh S, Hertz S, Evers AS, Orser BA. Anesthetic neurotoxicity—clinical implications of animal models. *N Engl J Med*. (2015) 372:796–7. doi: 10.1056/NEJMp1414786
39. Andropoulos DB. Effect of anesthesia on the developing brain: infant and fetus. *Fetal Diagn Ther*. (2018) 43:1–11. doi: 10.1159/000475928
40. Kajbafzadeh AM, Tourchi A, Nezami BG, Khakpour M, Mousavian AA, Talab SS. Miniature pyeloplasty as a minimally invasive surgery with less than 1 day admission in infants. *J Pediatr Urol*. (2011) 7:283–8. doi: 10.1016/j.jpuro.2011.02.030
41. Ruiz E, Soria R, Ormaechea E, Lino MM, Moldes JM, de Badiola FI. Simplified open approach to surgical treatment of ureteropelvic junction obstruction in young children and infants. *J Urol*. (2011) 185:2512–6. doi: 10.1016/j.juro.2011.01.012
42. Chacko JK, Koyle MA, Mingin GC, Furness PD III. The minimally invasive open pyeloplasty. *J Pediatr Urol*. (2006) 2:368–72. doi: 10.1016/j.jpuro.2006.05.001
43. Gatti JM, Amstutz SP, Bowlin PR, Stephany HA, Murphy JP. Laparoscopic vs open pyeloplasty in children: results of a randomized, prospective, controlled trial. *J Urol*. (2017) 197:792–7. doi: 10.1016/j.juro.2016.10.056
44. Wang MK, Li Y, Selekmán RE, Gaither T, Arnheim A, Baskin LS. Scar acceptance after pediatric urologic surgery. *J Pediatr Urol*. (2018) 14:175.e1–6. doi: 10.1016/j.jpuro.2017.11.018
45. Barbosa JA, Barayan G, Gridley CM, Sanchez DC, Passerotti CC, Houck CS, et al. Parent and patient perceptions of robotic vs open urological surgery scars in children. *J Urol*. (2013) 190:244–50. doi: 10.1016/j.juro.2012.12.060

Conflict of Interest: The authors declare that the research was conducted in the absence of any commercial or financial relationships that could be construed as a potential conflict of interest.

Copyright © 2020 Castagnetti, Iafrate, Esposito and Subramaniam. This is an open-access article distributed under the terms of the Creative Commons Attribution License (CC BY). The use, distribution or reproduction in other forums is permitted, provided the original author(s) and the copyright owner(s) are credited and that the original publication in this journal is cited, in accordance with accepted academic practice. No use, distribution or reproduction is permitted which does not comply with these terms.



Ultrasound-Based Scoring System for Indication of Pyeloplasty in Patients With UPJO-Like Hydronephrosis

Bruce Li¹, Melissa McGrath^{2,3,4}, Forough Farrokhyar^{4,5} and Luis H. Braga^{2,3,4,5*}

¹ Michael G. DeGroote School of Medicine, McMaster University, Hamilton, ON, Canada, ² McMaster Pediatric Surgical Research Collaborative, McMaster University, Hamilton, ON, Canada, ³ Division of Urology, McMaster University, Hamilton, ON, Canada, ⁴ McMaster Children's Hospital Foundation, Hamilton, ON, Canada, ⁵ Department of Health Research, Methods, Evidence & Impact, McMaster University, Hamilton, ON, Canada

OPEN ACCESS

Edited by:

Lisandro Ariel Piaggio,
Universidad Nacional del
Sur, Argentina

Reviewed by:

Tarkan Soyğür,
Ankara University, Turkey
Andres Gomez Fraile,
University Hospital October 12, Spain

*Correspondence:

Luis H. Braga
lhbraga@gmail.com

Specialty section:

This article was submitted to
Pediatric Urology,
a section of the journal
Frontiers in Pediatrics

Received: 05 May 2020

Accepted: 28 May 2020

Published: 02 July 2020

Citation:

Li B, McGrath M, Farrokhyar F and
Braga LH (2020) Ultrasound-Based
Scoring System for Indication of
Pyeloplasty in Patients With
UPJO-Like Hydronephrosis.
Front. Pediatr. 8:353.
doi: 10.3389/fped.2020.00353

Background: Previous scoring systems have used renal scan parameters to assess severity of ureteropelvic junction obstruction-like hydronephrosis (UPJO-like HN), however this information is not always reliable due to protocol variation across centers and renogram limitations. Therefore, we sought to evaluate the Pyeloplasty Prediction Score (PPS), which utilizes only baseline ultrasound measurements to predict the likelihood of pyeloplasty in infants with UPJO-like.

Methods: PPS was developed using three ultrasound parameters, Society of Fetal Urology (SFU) grade, transverse anteroposterior (APD), and the absolute percentage difference of ipsilateral and contralateral renal lengths at baseline. PPS was evaluated using prospectively collected prenatal hydronephrosis data ($n = 928$) of patients with UPJO-HN. Children with vesicoureteral reflux, primary megaureter, other associated anomalies, bilateral HN and <3 months of follow-up were excluded. Scores were analyzed regarding its usefulness in predicting which patients would be more likely to undergo pyeloplasty. Sensitivity, specificity, likelihood ratios (LR) and receiver operating characteristic (ROC) curve were determined.

Results: Of 353 patients, 275 (78%) were male, 268 (76%) had left UPJO-like HN, and 81 (23%) had a pyeloplasty. The median age at baseline was 3 months (IQR 1–5). The PPS system was highly accurate in distinguishing patients who underwent pyeloplasty using baseline ultrasound measurements (AUC: 0.902). PPS of 7 and 8 were found to have a sensitivity of 85 and 78%, and specificity of 81 and 90%, respectively. PPS of 8 was associated with a LR of 7.8, indicating that these patients were eight times more likely to undergo pyeloplasty.

Conclusion: Overall, PPS could detect patients more likely to undergo pyeloplasty using baseline ultrasound measurements. Those with a PPS of eight or higher were eight times more likely to undergo pyeloplasty.

Keywords: ureteropelvic junction obstruction, prenatal hydronephrosis, pyeloplasty, classification, ultrasonography

INTRODUCTION

Prenatal hydronephrosis is one of the most commonly detected ultrasound findings, affecting 1–5% of pregnancies, and is usually detected during the third trimester as an incidental finding (1). Ureteropelvic junction obstruction-like hydronephrosis (UPJO-like HN) is one of the most common congenital causes of prenatal hydronephrosis (1). If left untreated, the severe hydronephrosis (HN) due to obstruction can lead to a clinical symptoms such as urinary tract infections, hematuria, progressive deterioration of renal function, and permanent kidney damage (1–3). Thus, early detection and surgical intervention of UPJO cases provides benefits by reducing the length of time the kidney is obstructed. However, a large proportion of UPJO-like [isolated hydronephrosis (pelvic distension) with or without dilated calyces] cases are benign in nature and spontaneously resolve. Therefore, the challenge with UPJO-like patients is identifying those that warrant further testing and would benefit from intervention in a timely manner to reduce associated morbidities.

Scoring systems have been developed to be utilized as an adjunctive tool to help predict those patients in need of pyeloplasty. Many of these scoring systems rely on ultrasound measurements of the afflicted kidney and on diuretic renogram findings. Nevertheless, nuclear studies pose an issue to the external validity of these scoring systems, as their protocols vary significantly across different centers (4). Consequently, interpretation of the drainage patterns, renogram curves and T1/2 times can be subjective and unreliable.

The primary objective of this study was to create a scoring system, the pyeloplasty prediction score (PPS), based on baseline ultrasound findings only, and evaluate its utility in predicting pyeloplasty in infants with UPJO-like. We hypothesized that the proposed scoring system could discriminate those who will resolve spontaneously from those who will end up having surgical intervention.

MATERIALS AND METHODS

After obtaining Research Ethics Board approval (13-62D), we reviewed our prospectively collected prenatal hydronephrosis database ($n = 928$) from a tertiary pediatric hospital and identified those who were diagnosed with UPJO-like hydronephrosis between 2008 and 2019. We excluded infants with vesicoureteral reflux, primary megaureter (hydroureteronephrosis), duplication anomalies, bilateral cases, other genitourinary anomalies (Prune-Belly, posterior urethral valves, horseshoe kidneys, neurogenic bladder, multicystic dysplastic kidney), and those with <3 months of follow-up.

Abbreviations: UPJO-like, Ureteropelvic junction obstruction-like (isolated hydronephrosis); PPS, Pyeloplasty Prediction Score; HN, Hydronephrosis; SFU, Society of Fetal Urology; APD, Anteroposterior diameter; IQR, Interquartile range; CI, Confidence interval; ROC, Receiver operating characteristic curve; LR, Likelihood ratio; PPV, Positive predictive value; HSS, Hydronephrosis Severity Score; DMSA, Dimercaptosuccinic acid; DRF, Differential renal function; SNDRF, Supra-normal differential renal function.

Calculation of the Pyeloplasty Prediction Score

For each case, characteristics were collected, and only baseline (initial visit) ultrasound measurements were analyzed. The PPS scoring system was then retrospectively applied to each included case. Ultrasound measurements were conducted following institutional protocol, such as no pretest patient hydration to minimize measurement bias, with the patient in supine position, measurement pre- and post-void to confirm an empty bladder, using the same two ultrasound machines, by two technicians specialized in pediatric renal bladder ultrasound, who were specifically assigned to the Pediatric Urology Service.

The clinical outcome was resolution of HN or surgical intervention with a pyeloplasty. HN resolution was defined as two consecutive ultrasounds showing either Society for Fetal Urology (SFU) grade 1 or less, or renal pelvis anteroposterior diameter (APD) of 10 mm or less (5). Indications for pyeloplasty were based on the following protocol: **1**-Worsening of hydronephrosis, characterized by increase in the transverse APD of the renal pelvis with or without change (increase) of SFU grade on repeat ultrasounds; or **2**-Deterioration of differential renal function (DRF) >10% on repeated renal scans; or **3**-Initial renal function <40% associated with an obstructive (ascending) curve on renogram; or **4**-Worsening of hydronephrosis associated with a T1/2 time >30 min, or **5**-Development of symptoms (sepsis, febrile urinary tract infections, stones).

PPS was based on three widely used ultrasound variables at baseline: SFU grade, transverse APD, and absolute percentage difference in renal length. APD was calculated in the transverse view, by measuring the distance between the parenchymal lips at the renal hilum in the mid-section. The extra-renal and intra-renal measurements for APD were taken and the larger of the two was recorded in the prospective database to be used in the PPS calculation. Renal length was measured in ipsilateral and contralateral kidneys in the longitudinal view, such that the distance between the most distant points of the upper and lower poles was captured. **Figures 1A,B** demonstrate the technique for measuring renal length and APD using electronic calipers, respectively. Each of these variables were assigned a value out of four, with zero being normal variant or least severe and four being the most severe; thus, making the PPS score total range from 0 to 12.

The SFU grading system ranges from normal, 1, 2, 3, 4 which corresponded to a score of 0, 1, 2, 3, 4, respectively (6).

The APD measurement was grouped as <5, 5–10, 11–15, 16–19, ≥20 mm corresponding to scores of 0, 1, 2, 3, 4, respectively. The APD category values were established based on current evidence that generally, the larger the APD, the greater the risk of obstructive uropathy (7–9), and thus a greater likelihood of surgical intervention (8, 10–12). An APD <5 mm is not considered as HN, which is why a score of 0 was assigned. A post-natal APD value <10 mm is considered as physiologic HN and APD values from 10 to 15 mm are associated with low risk of obstructive uropathy, which both correspond to the Urinary Tract Dilation (UTD) Classification System's P1 designation (13). The P1 designation is the lowest risk stratum in the UTD

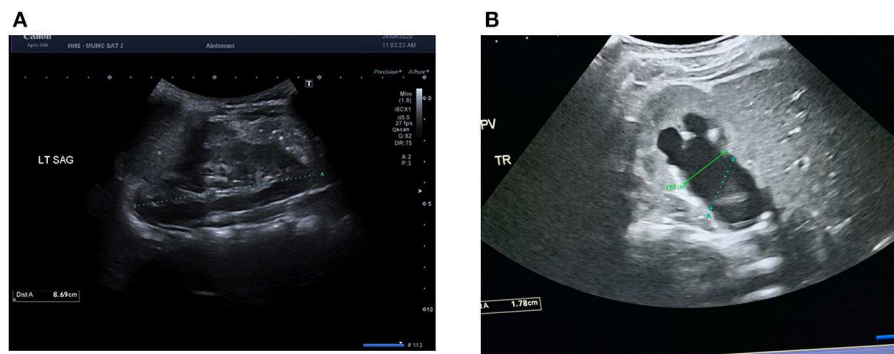


FIGURE 1 | Example measurements of ultrasound renal parameters for the Pyeloplasty Prediction Score in **(A)** longitudinal view of the left kidney with electronic calipers measuring renal length as the maximal distance between the upper and lower poles and **(B)** transverse view of the right kidney with green electronic calipers measuring true anteroposterior diameter (APD) as the distance between the parenchymal lips at the renal hilum in the mid-section. Blue electronic calipers represent the incorrect method of measuring APD as the calipers are not aligned to the parenchymal lips.

post-natal classification, which is why those two APD categories been assigned lower severity scores as 1 and 2, respectively. An APD value of 16 or greater was found by Dias et al. to have the best diagnostic odds ratio to identify infants who had pyeloplasty performed, which corresponds to the category of 16–19 mm (10). Multiple literature sources vary in terms of what APD cutoff value has the greatest likelihood of surgery, but are generally consistent in that an APD of at least 20 mm or greater is associated with the highest likelihood of pyeloplasty, which is why it was designated the greatest score of 4 (14, 15).

Absolute percentage difference between renal lengths was grouped as <5% (error variation), 5–10, 11–15, 16–19, ≥20% corresponding to scores of 0, 1, 2, 3, 4, respectively. The absolute percentage difference was taken by the following equation:

$$\left[100\% \times \frac{\left(\frac{\text{Ipsilateral Renal Length}}{\text{Ipsilateral Renal Length}} - \frac{\text{Contralateral Renal Length}}{\text{Ipsilateral Renal Length}} \right)}{\text{Ipsilateral Renal Length}} \right]$$

The three scores were then summed for a total score out of 12. The details of scoring criteria are described in **Table 1**.

The PPS system was analyzed for its usefulness in predicting which patients were more likely to undergo pyeloplasty. A trial of various cut-points was done to establish an optimal threshold that would maximize sensitivity and specificity of the scoring system. Sensitivity, specificity, likelihood ratios (LR) with their corresponding 95% confidence intervals (CI) and a receiver-operating characteristic (ROC) curve were determined. A *p*-value equal to or <0.05 was considered statistically significant. SPSS version 26 (www.ibm.com) were used for analysis.

RESULTS

Overall, from 928 prenatal HN patients in our database, a total of 353 with UPJO-like (isolated HN) qualified for analysis based on inclusion and exclusion criteria. Of the 353 included infants, 275 (78%) were male and 268 had HN on the left side (76%). The

median age of the cohort at baseline (initial visit) was 3 months (IQR 1–5 months). In 81 of the 353 patients (23%), kidneys were considered obstructed based on our criteria (previously stated in the methods section), and a pyeloplasty was performed.

The area under the ROC curve (AUC) was 0.902, demonstrating the accuracy of the PPS score in identifying patients more likely to undergo a pyeloplasty (**Figure 2A**). The PPS could result in a score of 1 to 12, through testing of various modeling scenarios, a score of 7–8 was found to be the optimal cut-off point, with the highest levels of sensitivity and specificity for discriminating patients that would likely be candidates for a pyeloplasty. The sensitivities of a PPS score of 7 and 8 were found to be 85 and 78%, respectively (**Figure 2B**). The specificities of a PPS score of 7 and 8 were found to be 81 and 90%, respectively (**Figure 2B**).

The LRs of the PPS score range (1–12) increased progressively as the score increased, as expected. The optimal cut-point score of 8 was found to have a LR of 7.8 (**Figure 3**). Based on LR values, we stratified the patients into three risk categories, according to the likelihood of undergoing pyeloplasty (**Figure 3**).

DISCUSSION

The present study involved the development and analysis of a prediction scoring system for pyeloplasty in UPJO-like HN using only baseline ultrasound characteristics. Our findings show that PPS was highly accurate in distinguishing patients who ended up having a pyeloplasty from those managed non-surgically. Based on our findings, the optimal cut-off point where pediatric urologists could consider indicating a pyeloplasty should be a PPS ≥8, provided they followed the same pyeloplasty indications, as outline in our protocol. Only two patients were recorded as false negatives, such that the PPS score was below eight at baseline, yet eventually had pyeloplasty. These two cases initially presented to office with very mild hydronephrosis but over repeated follow-up found worsening of the condition. As previously described, one of the indications for pyeloplasty at our institution is worsening of hydronephrosis by APD or SFU grade, which is why these two

TABLE 1 | The Pyeloplasty Prediction Score is based on three parameters: society of fetal urology (SFU) grade of the ultrasound, transverse anteroposterior diameter (APD) measurement, and the absolute percentage difference between the lengths of the ipsilateral and contralateral kidneys.

A. SFU grading of affected kidney on ultrasound	
0	Normal
1	SFU Grade 1
2	SFU Grade 2
3	SFU Grade 3
4	SFU Grade 4
B. APD measurement of affected kidney on ultrasound	
0	<5 mm
1	5–10 mm
2	11–15 mm
3	16–19 mm
4	≥20 mm
C. Absolute percentage difference between the ipsilateral and contralateral renal lengths [(100% * (Ipsilateral Renal Length- Contralateral Renal Length)/Ipsilateral Renal Length)]	
0	<5%
1	5%–10%
2	11%–15%
3	16%–19%
4	≥20%
PPS = A + B + C	

Each parameter is assigned a score from 0 to 4, 0 being least severe and 4 being most.

patients qualified for surgical intervention. With respect to false positives, there were no patients that scored above 8 and did not have surgical intervention. Based on the sensitivity and specificity calculations, clinicians can expect a 90% probability that those with a score ≥ 8 will end up having a pyeloplasty in the future. The LR indicated that patients with a PPS ≥ 8 were eight times more likely to have surgery vs. no surgery.

Indications for Pyeloplasty

The indications for pyeloplasty at our center are consistent with what has been previously published in the literature. Within the entire prenatal hydronephrosis database of 928 patients, there were 353 cases of UPJO-like HN which were followed prospectively. Of those 353 patients, only 81 had surgical intervention, which translates into a pyeloplasty rate of 23%. Dhillon et al., one of the first groups to introduce the concept of non-surgical management for UPJO-like HN, had highlighted that approximately one-third of the infants in their series ended up having surgical intervention, which is similar to our figures (15).

Pyeloplasty indications have been well-established in the main urological textbooks. According to Campbell-Walsh 12th edition textbook, widely accepted indications for pyeloplasty include

“increasing APD on ultrasonography, low or decreasing DRF, breakthrough infections while on prophylactic antibiotics, or symptomatic hydronephrosis in older infants and children” (16).

Nevertheless, controversy surrounding some of these indications due to inherent subjectivity still exists. Low or decreasing differential renal function does not specify an actual value for decreased function or decreasing function, thus how low or how much has decreased to indicate need for pyeloplasty is subjective to some degree. Some authors may consider < 40% DRF as a cut-off (17) while others may push it even lower to <35% (18). Similarly, this subjectivity issue arises with increase in the APD of renal pelvis. At what APD value and at what rate of increase does pyeloplasty outweigh non-surgical management? Again, these values vary from surgeon-to-surgeon and are the subject of many debates within pediatric urology.

Historically, decreased or decreasing renal function as an indication for pyeloplasty had been controversial (17). Waiting until function has dropped and then performing surgery with the hopes to regain what has already been lost seems to be contradictory to the philosophy in pediatrics of maximizing a child's potential (19). While this view does not convey the thought that surgery should be performed on every child, this does highlight the need for a more advanced measure for screening patients that would benefit significantly from early surgical intervention rather than observation.

Early Intervention Compared to Non-surgical Management

Argument against early intervention of UPJO-like HN consists of evidence demonstrating that most cases of UPJO-like HN are clinically benign and will self-resolve. Koff followed neonates with suspected UPJO-like HN (regardless of degree of HN, shape of diuretic renogram curve, or initial degree of functional impairment) and showed that only 7% eventually had pyeloplasty performed for obstruction, suggesting that due to diagnostic inaccuracy and low risk of developing obstructive injury, many newborn kidneys with HN may rapidly improve without intervention (20, 21). This was further validated by Onen et al. who followed 19 newborns (38 kidneys) with primary SFU grade 3 to 4 bilateral HN for a mean of 54 months. Overall, 25 hydronephrotic kidneys (65%) resolved spontaneously, with renal dilatation and function improving over time in most kidneys (22). Furthermore, Braga et al. analyzed a cohort of 501 UPJO-like HN patients with all SFU grades and observed that 68% of those with grades 3 and 4 HN resolved with non-surgical management over 48 months of follow-up (23). This rate compares well to a recent study from a center known for its conservative approach regarding pyeloplasty indications. They reported a pyeloplasty rate of 38% in 64 patients with grades 3/4 UPJO-like HN at a median age of 21 months (24).

In contrast, benefit of early pyeloplasty in UPJO-like HN has been vastly reported in the literature. With respect to renal function, Babu et al. compared children with UPJO-like HN and SFU grade 3 or 4 who had pyeloplasty done at a mean age of 2.8 vs. 12.5 months. They found that at 1 year follow-up, the

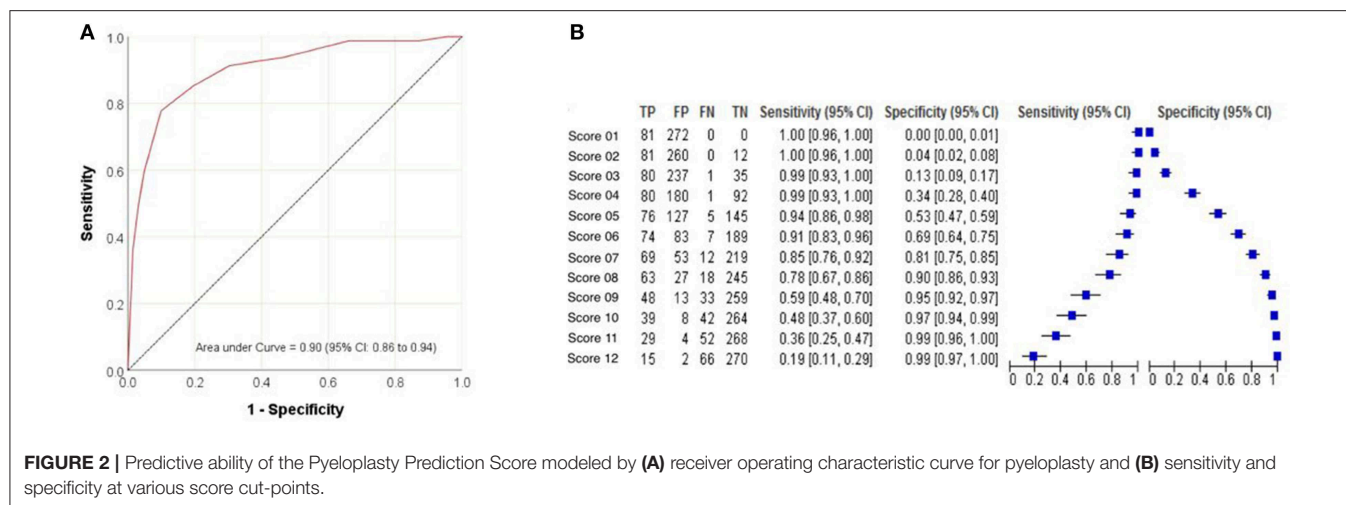


FIGURE 2 | Predictive ability of the Pyeloplasty Prediction Score modeled by (A) receiver operating characteristic curve for pyeloplasty and (B) sensitivity and specificity at various score cut-points.

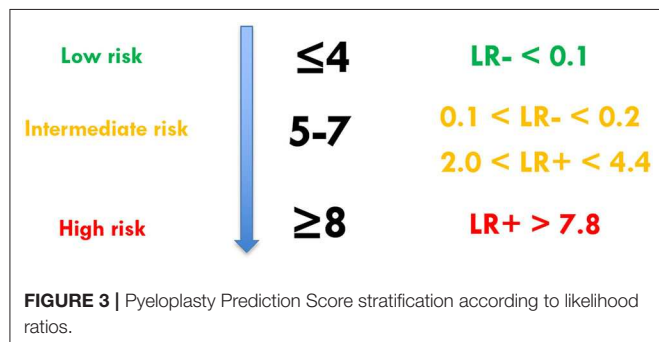


FIGURE 3 | Pyeloplasty Prediction Score stratification according to likelihood ratios.

early group had a significant improvement of split DRF while the delayed group generally had a marginal loss in function (25). Tabari et al. analyzed functional and anatomic indices (cortical thickness, polar length, SFU grade) in patients with early surgical pyeloplasty compared to those with non-surgical management. The early surgical group noted a faster return to anatomical and functional baseline parameters, whereas the non-surgical group had a significant deterioration in function compared to baseline (26). Thus, it is clinically essential to be able to identify those patients with UPJO-like HN that would benefit most from early pyeloplasty, which is exactly what the PPS was intended to do.

Limitations of Other Scoring Systems

Other scoring systems, such as the Hydronephrosis Severity Score (HSS) developed by Babu et al. attempted to predict pyeloplasty using ultrasound and diuretic renogram results (27). The main limitation of the HSS is that it relies greatly on the diuretic renogram and the interpretation of its curve, all factors which are heavily exam and operator dependent. Confounders such as time of furosemide dose (F + 20, F - 15, F - 0), bladder catheterization or no catheterization, oral or intravenous hydration, DRF of the affected kidney, and conjugate views, all may influence the results of the scan (4, 28–31).

Bladder distension and elevated bladder pressures can restrict the upper urinary tract's ability to drain and can prolong the excretory phase, which is difficult to control without bladder catheterization. Patient position has also been demonstrated to affect urine flow, such that when the patient is supine the urine flow can resemble obstruction whereas upright gravity-assisted position can increase flow significantly (29). Timing of furosemide administration is controversial. Earlier furosemide administration (F + 0, F - 15) urine flow is dramatically increased and can increase the specificity by decreasing the false-positive rate but also results in underestimation of renal function due to acceleration of renal transit (30, 32). Later administration of furosemide (F + 20) allows the examiner to compare the drainage curve before and after furosemide to directly observe the modifications to excretion by diuretic. However, prolongation of the excretory phase does run the increased risk of false-positive findings of obstruction (28). It is not difficult to imagine that even with just the variability of one of these three factors, how many protocol variations can be expected across different centers. This will lead to inconsistencies when interpreting study results involving different protocols and radiotracers.

Pyeloplasty Prediction Score Parameters

Therefore, the concept of creating a score relying exclusively on ultrasound parameters was attractive because of its reproducibility. SFU grade, APD and renal length discrepancy measurements were chosen as the components of the PPS system because each one of them has been shown to be significantly associated with obstruction/pyeloplasty, as previously reported. Increasing severity of SFU grade, specifically SFU grades 3 and 4 of post-natal UPJO-like HN, were shown to be independent risk factors for surgery (6, 23, 33, 34). In a prospective study including 501 UPJO-like HN patients, Braga et al. showed that the pyeloplasty rate in patients with SFU grades 3 and 4 was significantly higher than that in those with SFU grades I and II (2% vs. 32%) (23). In a meta-analysis, Lee et al. had demonstrated that severe hydronephrosis (antenatal APD >

15 mm) found during the third trimester had an 88% chance of post-natal pathology (35). Dias et al. had also established that with a prenatal APD > 18 mm in the third trimester and >16 mm in the postnatal period, the sensitivity and specificity of eventually needing pyeloplasty for UPJO-like HN were 100 and 86% (10). Renal length discrepancy on ultrasound has already been shown to be a significantly reliable predictor of abnormal DMSA scans, representing function, and SFU grade, representing obstructive severity. Khazaei et al. showed in children of all ages with a left kidney longer than the right by ≥ 10 mm or right longer than the left by ≥ 7 mm corresponded with a positive predictive value (PPV) of 79 and 100% of abnormal DMSA scan (36). Kelley et al. had found that an increase in renal length was significantly associated with SFU 3 and 4 as compared to SFU 1 and 2 (37). The three parameters chosen for the PPS have thus been shown to capture significant anatomical and functional measures independently, so the next logical step was to combine them into a single scoring system.

Though drop in differential renal function (DRF) is commonly listed as an indication for pyeloplasty, it has been omitted from the PPS formula. DRF can occasionally be misleading with the supra-normal differential renal function (SNDRF) phenomenon. A finding of SNDRF is generally defined as when the hydronephrotic kidney is found to have higher than normal DRF (>55%) (38, 39). It is hypothesized that this finding does not reflect true elevated function but reflects hyper-filtration in the setting of obstruction (38). SNDRF has been found in studies to be associated with significant post-operative decrease in DRF (38, 40). Pippi Salle et al. suggested that SNDRF observed during renography is a true phenomenon and that parenchymal proximity and distribution in relation to the pelvis are critical determinants, thus recommending the conjugate view technique for HN renography (41). There is intrinsic measurement error in renal scans of hydronephrotic kidneys making DRF measurement unreliable, due to variation in technique and the presence of the SNDRF phenomenon. Thus, DRF measurements do not have a consistent unidirectional relationship with disease severity that can be effectively utilized in a prediction model such as with the PPS.

Limitations

The main limitation of this study is that despite including widely accepted parameters that vary according to the severity of UPJO-like HN as components of the PPS, surgery indications are operator-dependent. A surgeon can determine his or her own criteria for pyeloplasty with some degree of flexibility from guidelines. Thus, the PPS system should be adopted for research at other centers for evaluation of the external validity of its predictive abilities.

Another limitation of the present study is that there have been debates regarding using pyeloplasty as an outcome in single-center studies involving UPJO-like HN. Those that are against using surgery as an outcome argue that pyeloplasty

is inherently a surgeon's threshold for surgery rather than an objective point of need for surgery. However, pyeloplasty is one of the few concrete outcomes that is available in the UPJO-like HN natural history. If pyeloplasty cannot be considered as an outcome, no other concrete objective outcomes are currently available, with the exception of renal function loss and symptoms. As previously discussed, waiting for renal function to deteriorate to indicate surgery with the hopes to regain what has already been lost seems counter-intuitive, especially when nephron preservation is the goal. Using an objective criterion for surgery such as DRF deterioration has its own problems. A recent study, which utilized DRF <40% as the main indication for pyeloplasty, regardless of HN grade and APD, showed a much higher febrile UTI rate of 12.5% for patients followed non-surgically, when compared to previous studies (24). This abnormally higher UTI rate seen, which can be considered as a true outlier, was most likely secondary to waiting too long for renal function loss to occur to intervene.

The PPS system was tested with a dataset from a single tertiary pediatric hospital. In order to further assess its external validity, it should be verified at other centers with prospectively collected data and larger sample sizes.

Despite these limitations, we propose that there is value in attempting to predict which UPJO-like HN patients will undergo pyeloplasty, using the PPS. We encourage that this scoring system be adopted at other centers to verify its findings, and to possibly establish an objective, simple, standard measure to quantitatively compare thresholds for surgery between various pediatric urologists.

DATA AVAILABILITY STATEMENT

The data analyzed in this study is subject to the following licenses/restrictions: the authors are not allowed to share data outside their institution without a data sharing agreement. Requests to access these datasets should be directed to Melissa McGrath, mcgram2@mcmaster.ca.

ETHICS STATEMENT

The studies involving human participants were reviewed and approved by Hamilton Integrated Research Ethics Board. No consent from the participant was required, as the study is part of a long term ongoing database.

AUTHOR CONTRIBUTIONS

LB theorized the presented idea. MM and BL developed the theory and performed the computations. LB and FF verified the analytical methods. BL, MM, FF, and LB contributed to interpretation of the results. BL wrote the manuscript in consultation with MM, FF, and LB. LB supervised the project. All authors provided critical feedback and helped design the research, analysis, manuscript, and figures.

REFERENCES

- Capolicchio J-P, Braga LH, Szymanski KM. Canadian urological association/pediatric urologists of Canada guideline on the investigation and management of antenatally detected hydronephrosis. *Can Urol Assoc J.* (2018) 12:85–92. doi: 10.5489/auaj.5094
- Thorup J, Jokela R, Cortes D, Nielsen OH. The results of 15 years of consistent strategy in treating antenatally suspected pelvi-ureteric junction obstruction. *BJU Int.* (2003) 91:850–2. doi: 10.1046/j.1464-410x.2003.04228.x
- de Waard D, Dik P, Lilien MR, Kok ET, de Jong TPVM. Hypertension is an indication for surgery in children with ureteropelvic junction obstruction. *J Urol.* (2008) 179:1976–9. doi: 10.1016/j.juro.2008.01.058
- Shulkin BL, Mandell GA, Cooper JA, Leonard JC, Majd M, Parisi MT, et al. Procedure guideline for diuretic renography in children 3.0. *J Nucl Med Technol.* (2008) 36:162–8. doi: 10.2967/jnmt.108.056622
- Braga LH, McGrath M, Farrokhhyar F, Jegatheeswaran K, Lorenzo AJ. Society for fetal urology classification vs urinary tract dilation grading system for prognostication in prenatal hydronephrosis: a time to resolution analysis. *J Urol.* (2018) 199:1615–21. doi: 10.1016/j.juro.2017.11.077
- Fernbach SK, Maizels M, Conway JJ. Ultrasound grading of hydronephrosis: introduction to the system used by the society for fetal urology. *Pediatr Radiol.* (1993) 23:478–80. doi: 10.1007/bf02012459
- Coplen DE, Austin PF, Yan Y, Blanco VM, Dicke JM. The magnitude of fetal renal pelvic dilatation can identify obstructive postnatal hydronephrosis, and direct postnatal evaluation and management. *J Urol.* (2006) 176:724–7. doi: 10.1016/j.juro.2006.03.079
- Duin LK, Willekes C, Koster-Kamphuis L, Offermans J, Nijhuis JG. Fetal hydronephrosis: does adding an extra parameter improve detection of neonatal uropathies? *J Matern Fetal Neonatal Med.* (2012) 25:920–3. doi: 10.3109/14767058.2011.600365
- Psooy K, Pike J. Investigation and management of antenatally detected hydronephrosis. *Can Urol Assoc J.* (2009) 3:69–72. doi: 10.5489/auaj.1027
- Dias CS, Silva JMP, Pereira AK, Marino VS, Silva LA, Coelho AM, et al. Diagnostic accuracy of renal pelvic dilatation for detecting surgically managed ureteropelvic junction obstruction. *J Urol.* (2013) 190:661–6. doi: 10.1016/j.juro.2013.02.014
- Barbosa JABA, Chow JS, Benson CB, Yorioka MA, Bull AS, Retik AB, et al. Postnatal longitudinal evaluation of children diagnosed with prenatal hydronephrosis: insights in natural history and referral pattern. *Prenat Diagn.* (2012) 32:1242–9. doi: 10.1002/pd.3989
- Dicke JM, Blanco VM, Yan Y, Coplen DE. The type and frequency of fetal renal disorders and management of renal pelvis dilatation. *J Ultrasound Med.* (2006) 25:973–7. doi: 10.7863/jum.2006.25.8.973
- Nguyen HT, Benson CB, Bromley B, Campbell JB, Chow J, Coleman B, et al. Multidisciplinary consensus on the classification of prenatal and postnatal urinary tract dilation (UTD classification system). *J Pediatr Urol.* (2014) 10:982–98. doi: 10.1016/j.jpuro.2014.10.002
- Arora S, Yadav P, Kumar M, Singh SK, Sureka SK, Mittal V, et al. Predictors for the need of surgery in antenatally detected hydronephrosis due to UPJ obstruction—a prospective multivariate analysis. *J Pediatr Urol.* (2015) 11:248.e1–5. doi: 10.1016/j.jpuro.2015.02.008
- Dhillon HK. Prenatally diagnosed hydronephrosis: the great ormond street experience. *Br J Urol.* (1998) 81(Suppl 2):39–44. doi: 10.1046/j.1464-410x.1998.0810s2039.x
- Partin A, Peters C, Kavoussi L, Dmochowski R, Wein A. *Campbell-Walsh-Urology, 12th Edition*. Philadelphia, PA: Elsevier. (2020).
- Castagnetti M, Novara G, Beniamin F, Vezzu B, Rigamonti W, Artibani W. Scintigraphic renal function after unilateral pyeloplasty in children: a systematic review. *BJU Int.* (2008) 102:862–8. doi: 10.1111/j.1464-410X.2008.07597.x
- Xu G, Xu M, Ma J, Chen Z, Jiang D, Hong Z, et al. An initial differential renal function between 35% and 40% has greater probability of leading to normal after pyeloplasty in patients with unilateral pelvic-ureteric junction obstruction. *Int Urol Nephrol.* (2017) 49:1701–6. doi: 10.1007/s11255-017-1665-0
- Peters CA. Urinary tract obstruction in children. *J Urol.* (1995) 154:1874. doi: 10.1016/s0022-5347(01)66815-0
- Koff SA, Campbell KD. The nonoperative management of unilateral neonatal hydronephrosis: natural history of poorly functioning kidneys. *J Urol.* (1994) 152:593–5. doi: 10.1016/s0022-5347(17)32658-7
- Koff SA. Neonatal management of unilateral hydronephrosis. Role for delayed intervention. *Urol Clin North Am.* (1998) 25:181–6. doi: 10.1016/s0094-0143(05)70006-9
- Onen A, Jayanthi VR, Koff SA. Long-term followup of prenatally detected severe bilateral newborn hydronephrosis initially managed nonoperatively. *J Urol.* (2002) 168:1118–20. doi: 10.1097/01.ju.0000024449.19337.8d
- Braga LH, McGrath M, Farrokhhyar F, Jegatheeswaran K, Lorenzo AJ. Associations of initial society for fetal urology grades and urinary tract dilation risk groups with clinical outcomes in patients with isolated prenatal hydronephrosis. *J Urol.* (2017) 197:831–7. doi: 10.1016/j.juro.2016.08.099
- Alsabbab A, Romao R, Dow T, Anderson P, MacLellan D. Severe ureteropelvic junction obstruction (UPJO)-like hydronephrosis in asymptomatic infants: to operate or not? In: *SPU 68th Annual Meeting* (2020).
- Babu R, Rathish VR, Sai V. Functional outcomes of early versus delayed pyeloplasty in prenatally diagnosed pelvi-ureteric junction obstruction. *J Pediatr Urol.* (2015) 11:63.e1–5. doi: 10.1016/j.jpuro.2014.10.007
- Tabari AK, Atqiaee K, Mohajerzadeh L, Rouzrokh M, Ghoroubi J, Alam A, et al. Early pyeloplasty versus conservative management of severe ureteropelvic junction obstruction in asymptomatic infants. *J Pediatr Surg.* (2020) S0022–3468:30513–5. doi: 10.1016/j.jpedsurg.2019.08.006
- Babu R, Venkatachalapathy E, Sai V. Hydronephrosis severity score: an objective assessment of hydronephrosis severity in children—a preliminary report. *J Pediatr Urol.* (2019) 15:68.e1–e6. doi: 10.1016/j.jpuro.2018.09.020
- Piepsz A. Antenatal detection of pelviureteric junction stenosis: main controversies. *Semin Nucl Med.* (2011) 41:11–19. doi: 10.1053/j.semnuclmed.2010.07.008
- Wong DC, Rossleigh MA, Farnsworth RH. Diuretic renography with the addition of quantitative gravity-assisted drainage in infants and children. *J Nucl Med.* (2000) 41:1030–6.
- Turkolmez S, Atasever T, Turkolmez K, Gogus O. Comparison of three different diuretic renal scintigraphy protocols in patients with dilated upper urinary tracts. *Clin Nucl Med.* (2004) 29:154–60. doi: 10.1097/01.rlu.0000113852.57445.23
- Kumar MT, Hanuwant S. Comparison of the F+20 and F-15 diuresis technetium-99m diethylenetriaminepentaacetate renography protocols for diagnosis of ureteropelvic junction obstruction in adult patients with hydronephrosis. *Indian J Nucl Med.* (2018) 33:39–42. doi: 10.4103/ijnm.IJNM_113_17
- Donoso G, Ham H, Tondeur M, Piepsz A. Influence of early furosemide injection on the split renal function. *Nucl Med Commun.* (2003) 24:791–5. doi: 10.1097/01.mnm.0000080253.50447.94
- Chertin B, Pollack A, Koulikov D, Rabinowitz R, Hain D, Hadas-Halpren I, et al. Conservative treatment of ureteropelvic junction obstruction in children with antenatal diagnosis of hydronephrosis: lessons learned after 16 years of follow-up. *Eur Urol.* (2006) 49:734–8. doi: 10.1016/j.eururo.2006.01.046
- Ross SS, Kardos S, Krill A, Bourland J, Sprague B, Majd M, et al. Observation of infants with SFU grades 3–4 hydronephrosis: worsening drainage with serial diuresis renography indicates surgical intervention and helps prevent loss of renal function. *J Pediatr Urol.* (2011) 7:266–71. doi: 10.1016/j.jpuro.2011.03.001
- Lee RS, Cendron M, Kinnamon DD, Nguyen HT. Antenatal hydronephrosis as a predictor of postnatal outcome: a meta-analysis. *Pediatrics.* (2006) 118:586–93. doi: 10.1542/peds.2006-0120
- Khazaei MR, Mackie F, Rosenberg AR, Kainer G. Renal length discrepancy by ultrasound is a reliable predictor of an abnormal DMSA scan in children. *Pediatr Nephrol.* (2008) 23:99–105. doi: 10.1007/s00467-007-0637-5
- Kelley JC, White JT, Goetz JT, Romero E, Leslie JA, Prieto JC. Sonographic renal parenchymal measurements for the evaluation and management of ureteropelvic junction obstruction in children. *Front Pediatr.* (2016) 4:42. doi: 10.3389/fped.2016.00042
- Rickard M, Braga LH, Gandhi S, Oliveria J-P, Demaria J, Lorenzo AJ. Comparative outcome analysis of children who underwent pyeloplasty for ureteropelvic junction obstruction associated with or without supranormal differential renal function. *Urology.* (2017) 99:210–4. doi: 10.1016/j.urology.2016.07.016

39. Inanir S, Biyikli N, Noshari O, Caliskan B, Tugtepe H, Erdil TY, et al. Contradictory supranormal function in hydronephrotic kidneys: fact or artifact on pediatric MAG-3 renal scans? *Clin Nucl Med.* (2005) 30:91–6. doi: 10.1097/00003072-200502000-00004
40. Cho SY, Kim IS, Lee S-B, Choi H, Park K. Nature and fate of supranormal differential renal function: lessons from long-term follow-up after pyeloplasty. *Urology.* (2013) 81:163–7. doi: 10.1016/j.urology.2012.09.017
41. Pippi Salle JL, Cook A, Papanikolaou F, Bagli D, Breen SL, Charron M, et al. The importance of obtaining conjugate views on renographic evaluation of large hydronephrotic kidneys: an *in vitro* and *ex vivo* analysis. *J Urol.* (2008) 180:1559–65. doi: 10.1016/j.juro.2008.06.010

Conflict of Interest: The authors declare that the research was conducted in the absence of any commercial or financial relationships that could be construed as a potential conflict of interest.

Copyright © 2020 Li, McGrath, Farrokhyar and Braga. This is an open-access article distributed under the terms of the Creative Commons Attribution License (CC BY). The use, distribution or reproduction in other forums is permitted, provided the original author(s) and the copyright owner(s) are credited and that the original publication in this journal is cited, in accordance with accepted academic practice. No use, distribution or reproduction is permitted which does not comply with these terms.



Commentary: Ultrasound-Based Scoring System for Indication of Pyeloplasty in Patients With UPJO-Like Hydronephrosis

Abdurrahman Onen*

Section of Pediatric Urology, Department of Pediatric Surgery, Faculty of Medicine, Dicle University, Diyarbakir, Turkey

Keywords: Hydronephrosis, ultrasound scoring, Onen grading, pyeloplasty, UPJ-type obstruction

A Commentary on

OPEN ACCESS

Edited by:

Marco Castagnetti,
University Hospital of Padua, Italy

Reviewed by:

Matthieu Peycelon,
Indiana University, United States
Pedro-José Lopez,
Universidad del Desarrollo, Chile

*Correspondence:

Abdurrahman Onen
aonenmd@gmail.com

Specialty section:

This article was submitted to
Pediatric Urology,
a section of the journal
Frontiers in Pediatrics

Received: 13 August 2020

Accepted: 10 November 2020

Published: 03 December 2020

Citation:

Onen A (2020) Commentary:
Ultrasound-Based Scoring System for
Indication of Pyeloplasty in Patients
With UPJO-Like Hydronephrosis.
Front. Pediatr. 8:594527.
doi: 10.3389/fped.2020.594527

Ultrasound-Based Scoring System for Indication of Pyeloplasty in Patients With UPJO-Like Hydronephrosis

by Li, B., McGrath, M., Farrokhyar, F., and Braga, L. H. (2020). *Front. Pediatr.* 8:353. doi: 10.3389/fped.2020.00353

INTRODUCTION

A recent study has suggested a pyeloplasty prediction score (PPS) using three ultrasound parameters to determine who need surgery and who do not in infants (<3 years old) with ureteropelvic junction obstruction (UPJO)-like hydronephrosis (1). They recommend a combination of SFU grade (A), transverse AP diameter (B) and the absolute percentage difference of ipsilateral and contralateral renal lengths at baseline (C) to predict a criteria for surgical need. This study suggests that any infant UPJO-like hydronephrosis with a PPS of 8 or higher are 8 times more likely to undergo pyeloplasty (1). Unfortunately, none of these parameters is ideal to use due to many disadvantages and/or limitations (2). When we put problematic parameters together it is unlikely to get a correct beneficial result from them.

SFU GRADING SYSTEM (A)

All grades of SFU are very variable between operators and clinicians (2–7). SFU-3 represents only caliceal dilation which does not cause renal damage unless increase in hydronephrosis or development of any symptom (2, 3, 8, 9). Therefore, SFU-3 by itself, should not be an indication for pyeloplasty. SFU-4 represents minimal thinning of medullary parenchyma (ex. 6 mm) and severe thinning of cortical parenchyma (ex. 2 mm) and cyst-like hydronephrotic kidneys at the same grade (2, 3, 8, 9). This wide definition of SFU-4 is failure to demonstrate accurately the severity of hydronephrosis and thus a significant misleading for prompt treatment (2, 3, 8, 10).

ANTERIOR-POSTERIOR (AP) DIAMETER OF RENAL PELVIS (B)

It is a very dynamic parameter that change significantly depending on operator, hydration, bladder filling, position (supin or prone), and respiration (2–4, 11). More importantly its measurement is very variable and misleading due to different renal pelvic configurations (2–4). Hydronephrosis may be moderate even if the AP diameter is high in infants with extrarenal pelvic configuration. On the other hand, hydronephrosis may be very severe with significant parenchymal thinning even if the AP diameter is low in infants with intrarenal pelvic configuration. In the literature, there is no study determining intra- and inter-observer reproducibility of the measurement of AP diameter.

THE ABSOLUTE PERCENTAGE DIFFERENCE OF IPSILATERAL AND CONTRALATERAL RENAL LENGTHS (C)

- The laterality may significantly change the results of absolute percentage.

Example: Normal kidney longitudinal length for an infant who is 11 months of age:

- Normal right kidney longitudinal length; 64.24 ± 2.64 mm. It means that right kidney may be 61.60 mm (4).
- Normal left kidney longitudinal length; 66.36 ± 2.41 mm. It means that left kidney may be 68.77 mm (4).

If this infant has right UPJO-like hydronephrosis; $C = 61.60 - 68.77 = -7.17$! If this infant has left UPJO-like hydronephrosis; $C = 68.77 - 61.60 = 7.17$!

- Any degree of contralateral or bilateral hydronephrosis, ipsilateral atrophy, or contralateral hypertrophy will significantly change the absolute percentage (C).
 - This percentage would be low when there is a contralateral compensatory growth which will miss the severity of hydronephrosis.
 - Similarly, it would be low when there is an atrophy in ipsilateral kidney which, again, will miss the severity of hydronephrosis.
 - In addition, how would it be an objective criteria in bilateral cases?

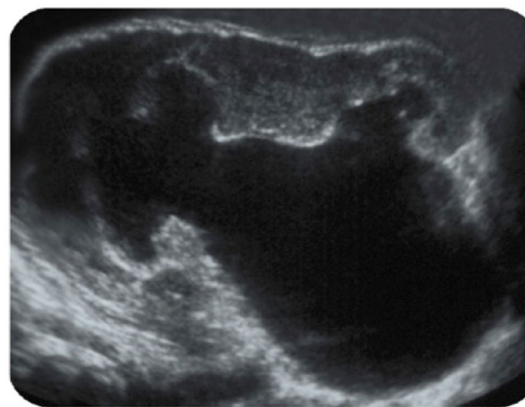
Any of these parameters can change the percentage (C) from 5 to 20% which means that it may get a score from 0 to 4!

PYELOPLASTY PREDICTION SCORE (PPS)

Example-1

- A: SFU-4 (minimal medullary thinning with normal cortex)
- B: AP = 20 mm (extrarenal pelvic configuration)
- C: 17% (without ipsilateral atrophy or contralateral hypertrophy)

$$PPS = A + B + C = 4 + 4 + 3 = 11.$$



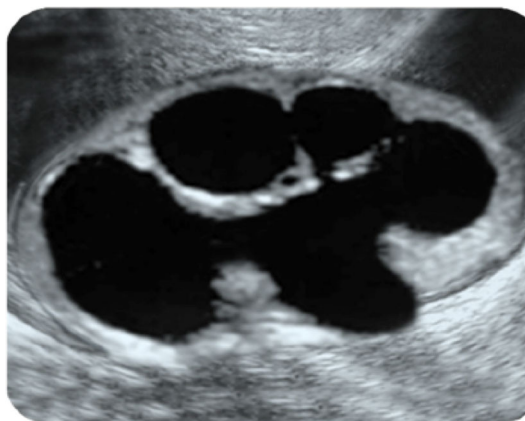Parenchyma: 5.4 mm, AP diameter: 36 mm.

According to PPS, this patient clearly should undergo pyeloplasty. However, such a patient does not need surgery if there is no significant contralateral compensatory growth or ipsilateral atrophy or significant functional decrease.

Example-2

- A: SFU-4 (significant cortical thinning with/without hyperechogenicity)
- B: AP = 15 (intrarenal pelvic configuration)
- C: <5% (in the presence of ipsilateral atrophy and contralateral hypertrophy)

$$PPS = A + B + C = 4 + 2 + 0 = 6.$$



Parenchyma: 2.3 mm, AP diameter: 14 mm.

According to PPS, this patient should be followed conservatively. However, such a patient definitely need surgery. Otherwise irreversible renal damage will develop in this patient if pyeloplasty delayed for a few month.

DISCUSSION

The laterality (normal right and left long length is different), contralateral or bilateral hydronephrosis, ipsilateral atrophy or contralateral hypertrophy significantly change the results of pyeloplasty prediction score (A+B+C) (2). The absolute percentage (C) would be low when there is a contralateral

compensatory growth or an atrophy in ipsilateral kidney which will miss the severity of hydronephrosis. In addition, it is not an objective criteria in bilateral cases. Any of these parameters can change the percentage (C) from 5 to 20% which means the score may change from 0 to 4. We should use objective and reproducible criteria that does not affect from many parameters and applicable for all patients.

Neither AP diameter nor SFU or the percentage of renal length are gold standard to determine the severity of hydronephrosis. Due to the fact that all parameters of PPS are affected by many factors, none of the PPS criteria is suitable or sufficient for standardizing UPJO-like hydronephrosis (2). They do not determine the exact severity of UPJO-like hydronephrosis and do not correctly reflect renal injury in UPJO because they do not take the quality of renal parenchyma into account. They, therefore, may cause permanent renal damage due to a delay in surgical decision in some infants while may cause an unnecessary surgery in others.

The anatomy and physiology of the 4 suborgans of the kidney (renal pelvis, calices, medulla, and cortex) are completely different from each other and each produces different risk of renal damage. Therefore, each part of kidney behave differently as a response to hydronephrosis.

The quality (*thickness* and *appearance*) of renal parenchyma is the most important and objective parameter to determine kidney exposure, renal function and thus the severity of hydronephrosis. Renal *cortical thickness* is the most important functional part of kidney. It is an objective parameter because, opposite to

pelviccaliceal system, it is not affected by hydration, bladder filling, position, and respiration. The measurement points are not controversial and is not operator dependant (2–4, 12). It does not have intra or inter observer variation (2, 4, 13). *Hyperechogenic parenchyma, cystic cortical degeneration and loss of corticomedullary differentiation* on ultrasound are findings suggesting significant renal damage which are compatible with decrease in renal function on scintigraphy (2, 14).

Comparing the PPS criteria, Onen hydronephrosis grading system has evidence-based objective parameters to define the severity of UPJO-like hydronephrosis promptly (10). Onen grading system shows a significant relationship with renal histopathologic grade and thus can be an indicator for renal injury in UPJO-like hydronephrosis (10). It is a reliable, easily reproducible and play a significant role in the diagnosis of obstruction in children (2, 6). It does suggest who need surgery and who can safely be followed non-operatively (2).

AUTHOR CONTRIBUTIONS

The author confirms being the sole contributor of this work and has approved it for publication.

FUNDING

This study was supported by discount code DSC-08001563106PRD.

REFERENCES

- Li B, McGrath M, Farrokhkar F, Braga LH. Ultrasound-based scoring system for indication of pyeloplasty in patients with UPJO-like hydronephrosis. *Front Pediatr*. (2020) 8:353. doi: 10.3389/fped.2020.00353
- Onen A. Grading of hydronephrosis: an ongoing challenge. *Frontiers in Pediatrics Pediatric Urology. Hydronephrosis associated with ureteropelvic junction anomalies: an ongoing challenge* (2020) 8:458. doi: 10.3389/fped.2020.00458
- Onen A. An alternative hydronephrosis grading system to refine the criteria for exact severity of hydronephrosis and optimal treatment guidelines in neonates with primary UPJ-type hydronephrosis. *J Pediatr Urol*. (2007) 3:200–5. doi: 10.1016/j.jpuro.2006.08.002
- Kadioglu A. Renal measurements, including length, parenchymal thickness, and medullary pyramid thickness, in healthy children: what are the normative ultrasound values? *Am J Roentgenol*. (2010) 194:509–15. doi: 10.2214/AJR.09.2986
- Kim SY, Kim MJ, Yoon CS, Lee MS, Han KH, Lee MJ. Comparison of the reliability of two hydronephrosis grading systems: the Society for Fetal Urology grading system vs. the Onen grading system. *Clin Radiol*. (2013) 68:484–90. doi: 10.1016/j.crad.2013.03.023
- De Bessa Jr, Rodrigues CM, Chammas MC, Miranda EP, Gomes CM, Moscardi PR, et al. Diagnostic accuracy of Onen's Alternative Grading System combined with Doppler evaluation of ureteral jets as an alternative in the diagnosis of obstructive hydronephrosis in children. *Peer J*. (2018) 6:e4791. doi: 10.7717/peerj.4791
- Cho HY, Jung I, Kim YH, Kwon JY. Reliability of society of fetal urology and Onen grading system in fetal hydronephrosis. *Obstet Gynecol Sci*. (2019) 62:87–92. doi: 10.5468/ogs.2019.62.2.87
- Onen A. Treatment and outcome of prenatally detected newborn hydronephrosis. *J Pediatr Urol*. (2007) 3:469–76. doi: 10.1016/j.jpuro.2007.05.002
- Fernbach SK, Maizels M, Conway JJ. Ultrasound grading of hydronephrosis: introduction to the system used by the Society for Fetal Urology. *Pediatr Radiol*. (1993) 23:478–80. doi: 10.1007/BF02012459
- Lee YS, Jeong HJ, Im YJ, Kim MJ, Lee MJ, Yun M, et al. Factors indicating renal injury in pediatric bilateral ureteropelvic-junction obstruction. *Urology*. (2013) 81:8739. doi: 10.1016/j.urol.2012.09.064
- Timberlake MD, Herndon CDA. Mild to moderate postnatal hydronephrosis grading systems and management. *Nat Rev Urol*. (2013) 10:649–56. doi: 10.1038/nrurol.2013.172
- Riccabona M, Avni FE, Blickman JG, Dacher JN, Darge K, Lobo ML, et al. Imaging recommendations in paediatric urology: minutes of the ESPR workgroup session on urinary tract ultrasonography and voiding cystourethrography. *Pediatr Radiol*. (2008) 38:138–45. doi: 10.1007/s00247-007-0695-7
- Eze CU, Agwu KK, Ezeasor DN, Agwuna KK, Aronu AE, Mba E. Sonographic biometry of normal kidney dimensions among school-age children in Nsukka, Southeast Nigeria. *West Indian Med J*. (2014) 63:46. doi: 10.7727/wimj.2012.010
- Moghazi S, Jones E, Schroeppe J, Arya K, McClellan W, Hennigar RA, et al. Correlation of renal histopathology with sonographic findings. *Kidney Int*. (2005) 67:1515–20. doi: 10.1111/j.1523-1755.2005.00230.x

Conflict of Interest: The author declares that the research was conducted in the absence of any commercial or financial relationships that could be construed as a potential conflict of interest.

Copyright © 2020 Onen. This is an open-access article distributed under the terms of the Creative Commons Attribution License (CC BY). The use, distribution or reproduction in other forums is permitted, provided the original author(s) and the copyright owner(s) are credited and that the original publication in this journal is cited, in accordance with accepted academic practice. No use, distribution or reproduction is permitted which does not comply with these terms.



Grading of Hydronephrosis: An Ongoing Challenge

Abdurrahman Onen*

Section of Pediatric Urology, Department of Pediatric Surgery, Faculty of Medicine, Dicle University, Diyarbakir, Turkey

OPEN ACCESS

Edited by:

Alberto Parente,
Reina Sofia University Hospital
Córdoba, Spain

Reviewed by:

Francisco Javier Reed,
Hospital Exequiel González
Cortés, Chile
Akiko Sakoda,
Tokyo Women's Medical
University, Japan

*Correspondence:

Abdurrahman Onen
aonenmd@gmail.com

Specialty section:

This article was submitted to
Pediatric Urology,
a section of the journal
Frontiers in Pediatrics

Received: 28 February 2020

Accepted: 30 June 2020

Published: 27 August 2020

Citation:

Onen A (2020) Grading of
Hydronephrosis: An Ongoing
Challenge. *Front. Pediatr.* 8:458.
doi: 10.3389/fped.2020.00458

The crucial point for prompt diagnostics, ideal therapeutic approach, and follow-up of hydronephrosis associated with UPJ anomalies in children is the severity of hydronephrosis. Such many hydronephrosis grading systems as AP diameter, SFU, radiology, UTD, and Onen have been developed to evaluate hydronephrosis severity in infants. Unfortunately, it is still an ongoing challenge and there is no consensus between different disciplines. AP diameter is a very dynamic parameter and is affected by many factors (hydration, bladder filling, position, respiration). More importantly, its measurement is very variable and misleading due to different renal pelvic configurations. The radiology grading system has the same grades 1, 2, and 3 as the SFU grading system with addition of the AP diameter for the first 3 grades. This grading system divides parenchymal loss into two different grades. Grade 4 represents mild parenchymal loss while grade 5 suggests severe parenchymal loss. However, it is operator dependent, is not decisive, and does not differentiate grades 4 and 5 clearly. All grades of SFU are very variable between operators and clinicians. UTD classification aims to put all significant abnormal urinary findings together including the kidney, ureter, and bladder and thus determines the risk level for infants with any urinary disease. Different renal deterioration risks occur depending on the mechanism of hydronephrosis. Therefore, SFU and UTD classification may result in significant confusion and misleading in determining the severity of hydronephrosis. SFU-4 and UTD-P3 represent a considerable range of severity of hydronephrosis. Both represent minimal thinning of the medullary parenchyma and severe thinning of the cortical parenchyma (cyst-like hydronephrotic kidneys) at the same grade. The wide definition of SFU-4 and UTD-P3 fails to indicate accurately the severity of hydronephrosis and thus significantly misleads from a prompt treatment. They do not suggest who need surgical treatment and who can safely be followed non-operatively. The anatomy and physiology of the 4 suborgans of the kidney (renal pelvis, calices, medulla, and cortex) are completely different from each other. Therefore, each part of the kidney affect and behave differently as a response to UPJ-type hydronephrosis (UPJHN) depending on the severity of hydronephrosis. The upgraded Onen hydronephrosis grading system has been developed based on this basic evidence both for prenatal and post-natal periods. The Onen grading system determines specific detailed findings of significant renal damage, which clearly show and suggest who can safely be followed conservatively from who will need surgical intervention for UPJHN. Neither AP diameter nor radiology, SFU, or UTD classification is the gold standard in determining the severity of hydronephrosis. All these grading systems are based on subjective parameters

and are affected by many factors. They do not determine the exact severity of UPJHN and thus cause permanent renal damage due to a delay in surgical decision in some infants while they may cause an unnecessary surgery in others. The Onen grading system has resolved all disadvantages of other grading systems and promises a safer follow-up and a prompt treatment for UPJHN. It is an accurate and easily reproducible grading that has high sensitivity and specificity.

Keywords: children, hydronephrosis, ureteropelvic junction obstruction, grading, treatment, surgery

INTRODUCTION

Urinary ultrasound (US) is the best we have for the diagnosis and follow-up of both prenatal and post-natal hydronephrosis as a similar modality (1–11). It is non-invasive, easily available, fast, and low-cost; can be performed directly in bedside manner; and does not involve radiation. It shows the size of kidneys, thickness, and appearance of parenchyma (echogenicity, corticomedullary differentiation, cortical cysts), severity of hydronephrosis, ureteral dilation, and bladder anatomy (1, 2, 4–6, 8, 10–11).

Ultrasound not only gives anatomic details but also gives some functional clues about the urinary system. It, therefore, provides excellent diagnostic accuracy. There are two important benefits of ultrasound: It determines the severity of hydronephrosis promptly and the time and necessity of other diagnostics (1, 3–6, 8, 10–12).

We need to determine specific criteria and risky findings suggestive of renal damage, which help clinicians to decide a prompt therapeutic approach. In this review, we will outline the most recent criteria to accurately determine the severity of hydronephrosis and thus predict who may develop renal damage and need intervention compared with who can safely be followed conservatively.

ANATOMO-PHYSIO-PATHOLOGY OF URETEROPELVIC JUNCTION TYPE HYDRONEPHROSIS (UPJHN)

The kidney has 2 main parts: The most important part is the renal parenchyma which does function and produce urine. The other is the pelvicaliceal system which collects and sends urine into the ureter. The renal parenchyma has two suborgans: medulla and cortex. The collecting system has two suborgans: renal pelvis and calices.

Two factors affect the kidney in infants with UPJHN: the compliance of renal pelvis and the degree of stenosis at UPJ. First, hydronephrosis develops as a protecting anatomic response. If the stenosis is severe and persists for a long period, then renal damage occurs as a functional response (1, 4, 11).

The anatomy and physiology of renal suborgans (renal pelvis, calices, medulla, and cortex) are completely different from each other. Therefore, each part affects and behaves differently as a response to UPJHN depending on the severity of hydronephrosis.

- *Renal pelvis:* The compliance of renal pelvis is very high in infants. It is particularly true for those who have extrarenal pelvic configuration due to their high expandability. The renal pelvis enlarges significantly to protect the renal parenchyma even in mild increase at renal pelvic pressure. Therefore, the risk of renal parenchymal damage is low and takes time in such infants comparatively. However, the risk of renal damage is high in those who have intra-renal pelvic configuration due to their low compliance.
- *Calices:* The expandability of calices is lower than that of the renal pelvis. Their compliance is low comparatively. Therefore, the dilation of calices means a greater degree (risk) of hydronephrosis compared to renal pelvic dilation alone. On the other hand, the calices enlarge to protect the renal parenchyma.
- *Medulla:* Its structure is somewhat similar to that of the lung. This part of the renal parenchyma is more expandable and compressed rapidly compared to the renal cortex. Depending on the degree of UPJ stenosis and time interval, the medulla becomes shorter and loses its pyramid form. The lower limit of the normal renal parenchymal thickness is 7.5 mm at the neonatal period, 8 mm at 1 year of age, and 10 mm at 2 years of age (10).
- *Cortex:* It is the most important functional part of the kidney. The normal thickness of the cortex is > 3 mm in infants. Its structure is somewhat similar to that of the liver, which is a relatively hard solid organ. Therefore, its compression or thinning means there is a significant risk of renal damage. In such cases, corticomedullary differentiation is lost and the thickness of the cortex decreases. It is an objective parameter because, opposite of the pelvicaliceal system, it is not affected from hydration, bladder filling, position, and respiration. The measurement points are not controversial and are not operator dependent. The renal parenchyma is measured at the thinnest point of the parenchyma on the longitudinal section of the kidney (1, 4, 5, 7, 10). It does not have intraobserver or interobserver variation (1, 10, 11, 13). Long-lasting cortical thinning is associated with low renal function and decrease in the number of nephrons (1, 4, 5, 11, 14). Therefore, the compressed and thinned cortex is suggestive of renal damage. The loss of more than half of the cortex (cortex thickness < 1.5 mm) is mostly associated with renal atrophy and irreversible renal damage.

The quality of the renal parenchyma which includes the *thickness* and *appearance* of the parenchyma is the most important and

objective parameter to determine kidney exposure and thus the severity of hydronephrosis.

- *Thickness of the renal parenchyma:* Severe cortical damage (dilation, epithelial apoptosis, and atrophy of the renal tubules, and inflammation and fibrosis of the glomerulus) and decrease in glomerular filtration and renal function occur in infants, developing parenchymal loss due to severe UPJHN (14). The incidence of permanent functional loss is high (8–16%) while histopathological changes do not improve even after a successful pyeloplasty in infants with severe parenchymal loss which delayed surgery (1, 4, 5, 11, 15, 16). Loss of the renal cortex and reduced renal size are the result of tubular atrophy and correlate with chronic irreversible renal disease (15). The number of nephrons decreases, renal maturation is affected, and renal failure occurs in such cases (17).
- *Appearance of the renal parenchyma:* Hyperechogenic parenchyma, cystic degeneration in the cortex, and loss of corticomedullary differentiation on ultrasound are findings suggesting significant renal damage, which are compatible with decrease in renal function on scintigraphy (1, 11). Cortical echogenicity is a parameter that correlates well with tubular atrophy and interstitial inflammation (15).

Another important parameter is the longitudinal length of both normal and hydronephrotic kidneys. The compensatory hypertrophy of the contralateral kidney (length > 20% of normal) means affected kidney worsening even if Onen-3 hydronephrosis is stable. The longitudinal length of the affected kidney should be higher than the normal value, depending on the severity of hydronephrosis. If the affected kidney length stays in the normal range despite severe hydronephrosis, it means the affected kidney undergoes atrophy.

HYDRONEPHROSIS GRADING SYSTEMS

Anterior–Posterior (AP) Diameter of Renal Pelvis (APDRP)

The measurement of the AP diameter of the renal pelvis is not standardized between different disciplines, and there is a consensus only in 64% of physicians (10, 18). Unfortunately, it is significantly operator dependent. Some sonographers measure the AP diameter at the largest point of the renal pelvis while others measure it at vertical plan. However, the APDRP is mostly measured at the parenchymal edge (hilus) during the transverse section of the kidney.

The renal pelvis and AP diameter is very dynamic; its measurement changes significantly depending on hydration, bladder filling, position (supine or prone), and respiration (1, 10, 12, 18, 19).

More importantly, its measurement is very variable and misleading due to different renal pelvic configurations. Hydronephrosis may be moderate even if the AP diameter is high in infants with extrarenal pelvic configuration. On the other hand, hydronephrosis may be very severe with significant parenchymal thinning even if the AP diameter is low in infants with intrarenal pelvic configuration. Therefore, if the

quality of parenchyma which is the most important factor in determining the degree of hydronephrosis is omitted and the AP diameter itself is accepted as the only finding for severity of hydronephrosis, then some infants may undergo an unnecessary surgery while some may result in permanent renal damage due to a delay for prompt surgery.

Disadvantages/limitations of APDRP:

- The rate of operator differences is very high
- AP diameter is low in dehydrated infants
- AP diameter is low in the empty bladder
- AP diameter is low in the expirium phase
- AP diameter is less ideally measured in supine position
- AP diameter (even low) is very risky in the presence of intrarenal pelvic configuration.

SFU Grading System

This grading system has been developed in 1993 (9) (**Figure 1**). It is quantitative and subjective. All grades of SFU are very variable between operators and clinicians (1, 4–6, 10, 11, 20–22). Therefore, it is not popular between disciplines other than pediatric urologists (1, 4, 5, 7, 10, 11, 19–21, 23–25).

Disadvantages/limitations of SFU

- *SFU-1 and SFU-2a:* Both indicate different degrees of renal pelvic dilation. Therefore, it is confusing and very difficult to differentiate each other (1, 2, 4). Moreover, follow-up, treatment, and prognosis of these two degrees are similar; all of them resolve spontaneously without renal damage (1, 2, 4, 5, 20).
- *SFU-2b and SFU-3:* Both represent different degrees of calyceal dilation. It is very operator dependent in differentiating the dilation of peripheral (minor) calices from those of central (major) calices due to a high discrepancy within and between raters for interpretation of the two types of calyceal dilation (26, 27). Therefore, it is subjective and confusing and it is very difficult to differentiate each other (1, 4).
- *SFU-3:* Although it represents only calyceal dilation, the pictures used for SFU-3 in the original article clearly show severe medullary thinning. This causes significant confusion among clinicians and radiologists.
- *SFU-4:* It represents minimal thinning of the medullary parenchyma (e.g., 6 mm) and severe thinning of the cortical parenchyma (e.g., 2 mm) and cyst-like hydronephrotic kidneys at the same grade (2). The wide definition of SFU-4 fails to demonstrate accurately the severity of hydronephrosis and thus significant misleads from a prompt treatment. It does not suggest who need surgery and who can safely be followed non-operatively. The first example (medulla thin) can safely be followed non-operatively while the second (cortex thin) clearly need surgery. This wide definition makes prognosis difficult to predict in UPJHN cases (1, 4–6, 8, 11, 28).

Radiology Grading System

The radiology grading system has partially been modified from SFU for post-natal use (7, 9) (**Figure 2**). It has the same grades 1, 2, and 3 as the SFU grading system (8, 14). In addition, it includes AP diameter for the grades 1, 2, and 3.

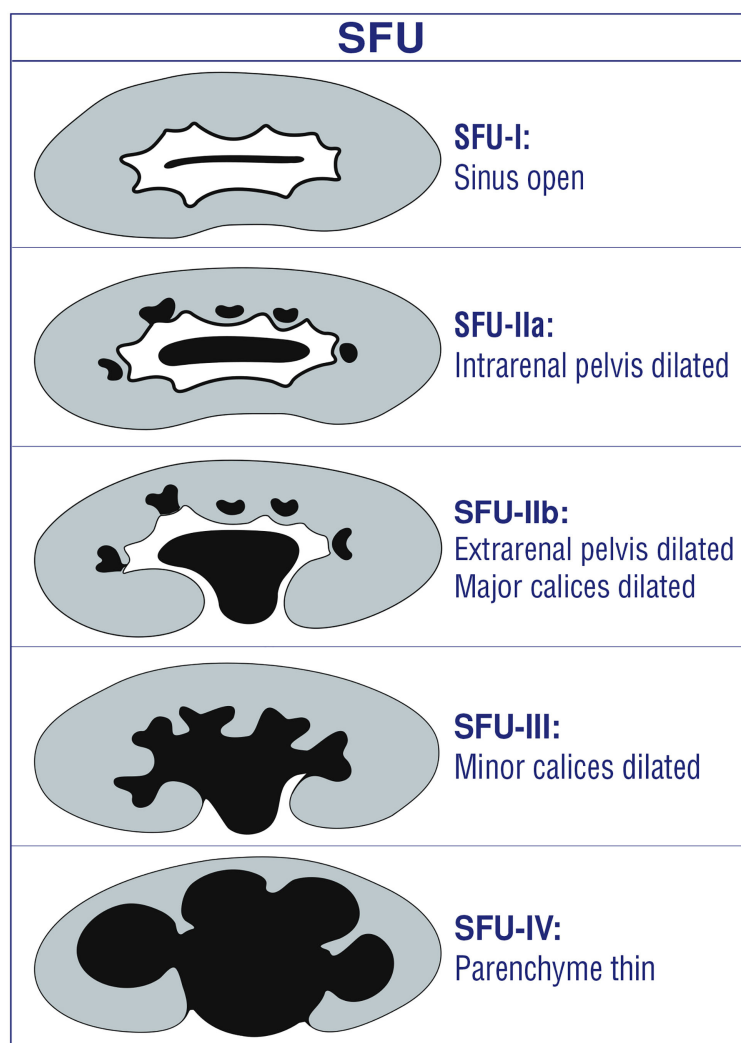


FIGURE 1 | SFU hydronephrosis grading system.

This grading system divides parenchymal loss into two different grades, suggesting the importance of the renal parenchyma to determine the severity of hydronephrosis which has a somewhat similar idea as in the Onen grading system (1, 4, 7). Grade 4 hydronephrosis represents mild parenchymal loss; grade 5, severe parenchymal loss.

Disadvantages/limitations of the radiology grading system

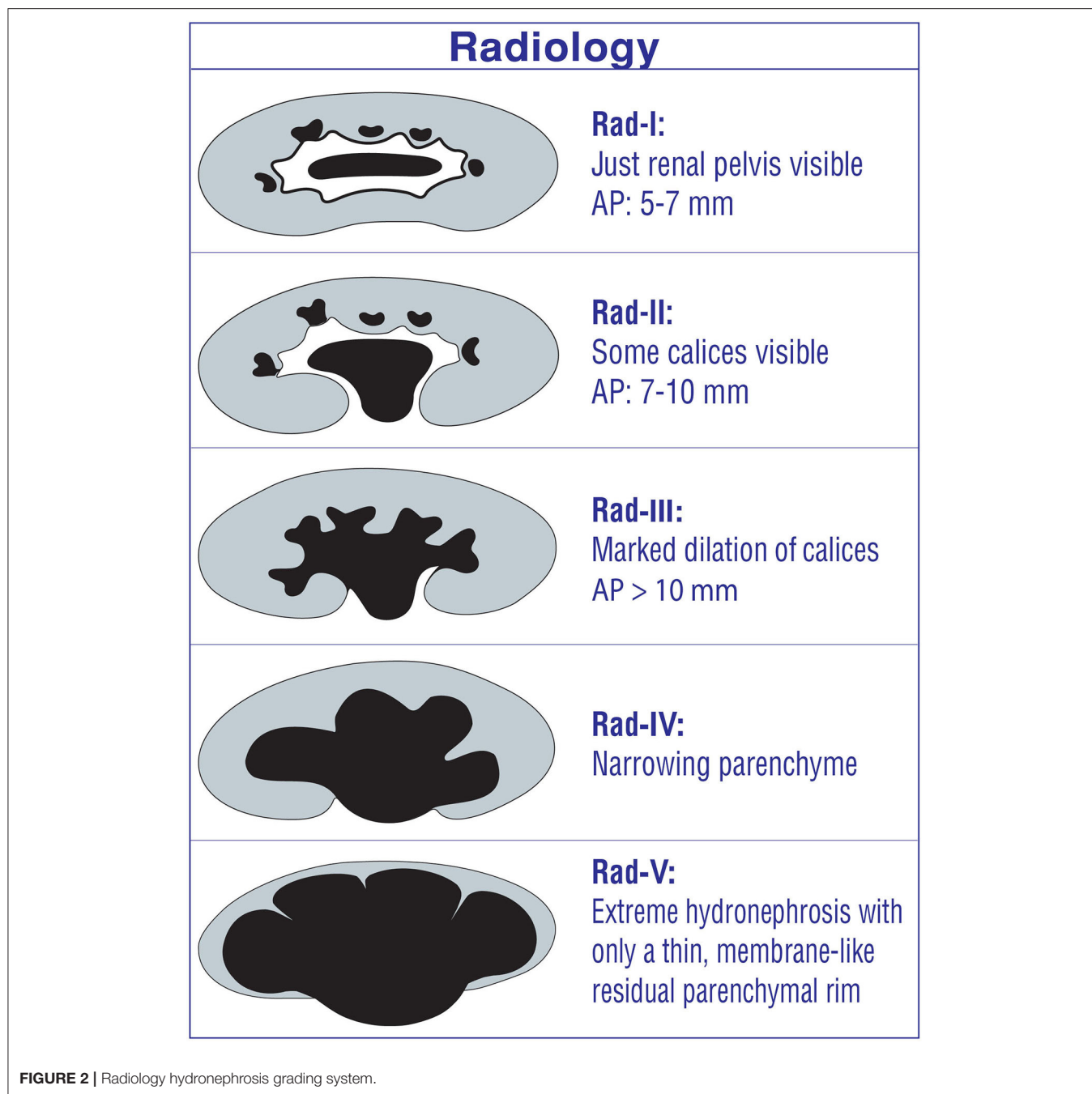
- **Radiology grades 1 and 2 (SFU-1 and SFU-2a):** Both indicate different degrees of renal pelvic dilation. Therefore, it is confusing and very difficult to differentiate each other (1, 2, 4). Moreover, follow-up, treatment, and prognosis of these two degree are similar; all of them resolve spontaneously without renal damage (1, 2, 4, 5, 20).
- **The usage of the AP diameter:** It makes this grading system even more confusing, because SFU grades and AP diameter are not parallel for many patients depending on different renal pelvic configurations. In addition, the AP diameter is affected

significantly by many factors as previously described in this review (1, 10, 12, 18, 19).

- **Radiology grades 4 and 5:** Grade 4 represents mild parenchymal loss, while grade 5 represents severe parenchymal loss. It is completely operator dependent, is not decisive, and does not differentiate grades 4 and 5 clearly. Therefore, between- and intra-rater reliability is low.

UTD Classification

UTD has been created retrospectively based on reviewing, combining, and summarizing the current literature (2) (Figure 3). It, therefore, is not an evidence-based grading system. Actually, it most likely has been modified from SFU and Onen grading systems (4, 9). It aims to put all significant abnormal urinary findings together including the kidney, ureter, and bladder and thus determines the risk level for a hydronephrotic infant with any kind urinary diseases. It



includes such parameters as AP diameter of renal pelvis, central and peripheral calyceal dilation, renal parenchyma, ureteral abnormalities, and bladder abnormalities (2). All these findings are very important by themselves. However, the natural history, diagnosis, follow-up, treatment, and prognosis of urinary diseases are significantly different from each other depending on the etiopathology of hydronephrosis.

This classification suggests the general term “urinary tract dilation” to indicate ultrasound findings that include all ureteral and kidney dilations (2). It is clear that UPJ-type hydronephrosis,

UVJ-type hydroureteronephrosis, vesicoureteral reflux, bladder pathologies (ureterocele, diverticula, etc.), and posterior urethral valve cause hydronephrosis in very different ways. They may cause different levels and types of renal damage and prognosis (1, 4, 5). For example, Onen-3 (medulla thin) hydronephrosis due to UPJHN can be followed non-operatively while an infant with the same degree of hydronephrosis due to grade 5 reflux has a much higher risk of UTI, renal scar, and surgical need (1). Different renal deterioration risks occur depending on the mechanism of hydronephrosis. Therefore, UTD classification

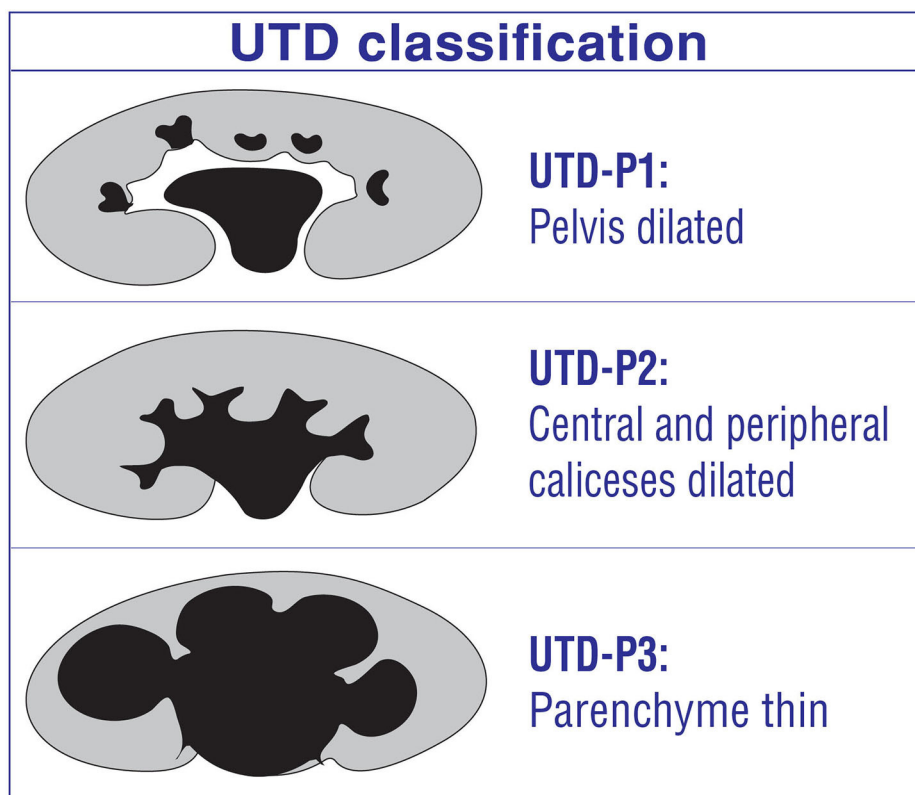


FIGURE 3 | UTD classification for post-natal hydronephrosis.

may result in significant confusion and mislead in determining the severity of hydronephrosis (1).

Disadvantages/limitations of UTD classification

- **Central and peripheral calices:** It is very operator dependent to differentiate the dilation of peripheral (minor) calices from those of central (major) calices due to a high discrepancy within and between raters for interpretation of the two types of calyceal dilation (26, 27). Therefore, it is subjective and confusing and is very difficult to differentiate each other (1, 4).
- **UTD-P3:** Like SFU, it represents minimal thinning of the medullary parenchyma (e.g., 6 mm) and severe thinning of the cortical parenchyma (e.g., 2 mm) and cyst-like hydronephrotic kidneys at the same grade (2). The wide definition of UTD-P3 fails to demonstrate accurately the severity of hydronephrosis and thus significant misleads from prompt treatment. It does not suggest who need surgical treatment and who can safely be followed non-operatively. The first example (medulla thin) can safely be followed non-operatively while the second (cortex thin) clearly need surgery. This wide definition makes prognosis difficult to predict in UPJHN cases (1, 4–6, 8, 11, 28).

Onen Grading System

This grading system has been developed for both prenatal and post-natal UPJHN (**Figure 4**). It is appropriate and

applicable for both fetus and children, which standardize the language of the sonographers, clinicians, method of evaluation, and measurement of kidneys. The Onen grading system is terminologically simple and clear. Therefore, all disciplines including radiology, perinatology, pediatric nephrology, and pediatric urology can easily use not only for clinical practice but also for future researches.

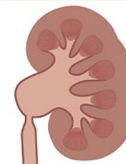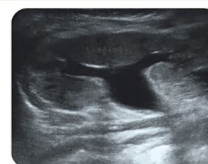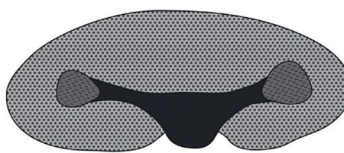
The Onen grading system has evidence-based standardized objectives and reproducible parameters (4). It includes two categories of kidney findings. The first is dilation of the pelvicalyceal system; the second which is the most important category is the quality of the renal parenchyma (thickness and appearance) (1). This grading system divides thinning of the renal parenchyma into two grades: medullary thinning and cortical thinning. In addition, the appearance of the parenchyma (echogenicity, cortical cysts, corticomedullary differentiation) which is suggestive of renal damage is also taken into account in this grading system.

It was proposed on the basis of a well-known tight association between the severity of hydronephrosis and prognosis; renal deterioration may occur in severe hydronephrosis not timely and promptly treated (1, 4–6, 8, 11, 23, 29, 30). This grading system is beneficial in determining the possible risk of renal damage, surgical necessity, and prognosis in infants with UPJHN. Therefore, such cases can safely be followed based on this grading

Onen Hydronephrosis Grading System

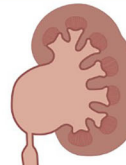
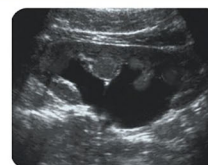Grade-1:

- Renal **pelvic dilation** alone.
- AP diameter is not important.



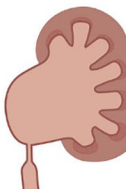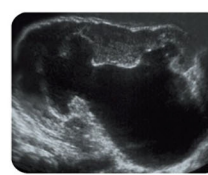

Grade-2:

- Pelvis + **Caliceal dilation**.
- Renal parenchyme (Medulla and Cortex) are normal (>7 mm).
- AP diameter is not important.



Grade-3:

- Pelvis + Caliceal dilation.
- **Medulla is short and thin.**
- Cortex is normal.
- Total parenchymal thickness: (PK: 2 trimester 2–5 mm, 3 trimester 2.5–6 mm, postnatal 3–7 mm).
- Corticomedullary differentiation is normal.
- AP diameter is not important.



Grade-4:

- Pelvis + Caliceal dilation.
- There is no medulla (total loss).
- **Cortex is thin** (Second trimester <2 mm, third trimester <2.5 mm, Postnatal <3 mm).
- **There is no corticomedullary differentiation.**
- Recesses between calyces significantly short and slim.
- AP diameter is not important.

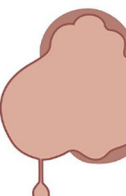
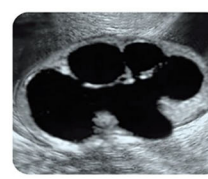

FIGURE 4 | Onen hydronephrosis grading system for both prenatal and post-natal UPJHN.

system. Because it determines clearly those infants who can be followed with ultrasound alone, who need renal scan, and who require surgery.

Our treatment and follow-up protocol for UPJHN based on the Onen grading system

- **Onen-1 UPJHN** cases neither need invasive evaluation nor need surgical treatment or antibiotic due to their benign nature; all they need is follow-up with ultrasound alone (Figure 5). A detailed urinary ultrasound at post-natal 1–3–6th months, 1 year, and 2 years of age is enough. If the Onen-1 does not increase or resolve, the follow-up can be ceased.
- **Onen-2 UPJHN** cases neither need invasive evaluation nor need antibiotic due to their benign nature; all they need is follow-up with ultrasound alone. However, about 10% of such infants will worsen and need pyeloplasty during follow-up. Therefore, they might be followed with ultrasound more closely comparing those of Onen-1 hydronephrosis. A detailed urinary ultrasound at post-natal 1–3–6th months and every 6 months until 3 years of age is enough. If Onen-2 decreases

to Onen-1 or resolve, the follow-up can be ceased. If Onen-2 persists, an ultrasound might be seen annually until 5 years of age and then the follow-up can be ceased with informing patients about such a symptom as pain or UTI.

- **Onen-3 UPJHN (medulla thin, PK = 3–7 mm)** patients need close follow-up including renal scan because about one-third of such children need pyeloplasty during follow-up. A detailed urinary ultrasound at post-natal 1st month, every 3 months until 2 years of age, and every 6 months until 3 years of age is reasonable. If the asymptomatic Onen-3 persists until 3 years of age with normal renal function, one of two ways might be discussed with the family; one is continuing invasive follow-up until adulthood, the other is performing a pyeloplasty with high success and thus preventing long-life invasive follow-up and prophylactic antibiotics (1, 5). If Onen-3 is diagnosed, we perform a renal scan. If the function and appearance (on ultrasound) of the ipsilateral kidney as well as contralateral kidney are normal, we follow them and see another ultrasound in 3 months. If Onen-3 decreases or stabilizes, we see the patient in the next 3 months; however, if Onen-3 gets worse,

Treatment and follow up protocol for UPJHN based on Onen grading system*									
	Ultrasound	Ultrasound interval	Renal scan	Renal scan interval	Prophylaxis	Treatment	Followup period	Surgical risk	Information
Onen-1	Yes	6 months	No	No	No	Conservative	2 years	1 %	Neither need invasive evaluation nor surgical treatment or antibiotic due to their benign nature; they do not develop UTI or renal deterioration.
Onen-2	Yes	3-6 months	No	No	No	Conservative	3 years	10 %	Neither need invasive evaluation nor surgical treatment or antibiotic due to their benign nature; they do not develop UTI or renal deterioration. They need more frequent ultrasound compared to Onen-1 hydronephrosis.
Onen-3	Yes	3 months	Yes	6 months	Yes (first year of life)	Conservative	3 years	30 %	Surgical indications: Onen-3 (thin medulla) (3-7mm) + • Presence of symptom (UTI, pain, stone) or • >20% compensatory growth in contralateral kidney • >10 units decrease in renal function or • Renal function <35% • Persistence until 3 years of age? (discuss with family)
Onen-4	Yes	2 weeks	Yes	1 month	Yes	Surgery	2 years	99%	Early intervention, after a short period (1-3 months) of follow up, is safer for preservation of renal function. Kidney function may not be measured accurately with this severity of hydronephrosis. This is particularly true for bilateral cases. Delay in prompt treatment may cause irreversible renal deterioration.

* Criteria for bad prognosis: Cortex less than half (<1,5mm), cyst-like kidney with no obvious recesses, cortical atrophy (marked reduction of kidney size), hyperechogenicity.

FIGURE 5 | Treatment and follow-up protocol for UPJHN based on the Onen grading system.

we perform a second renal scan to see renal function. If the function is under 35 or decrease by > 10 units, we perform pyeloplasty. If Onen-3 is diagnosed with renal function under 35, we look at the pictures of the scan in detail. If we believe that the decrease in renal function is correct and the reason of decrease in function is UPJHN, we decide to do surgery because we do not use the washout curve as a treatment criterion. On the other hand, if there is normal clearance of the pelvis and good washout, we look to ultrasound, renal scan, and sometimes VCUG to see if there is any other reason for the hydronephrosis such as a megaureter and reflux.

- **Onen-4 UPJHN** (cortex thin, PK < 3 mm, no corticomedullary differentiation) patients need surgical correction after a short period of follow-up (1–3 months). Renal function cannot objectively and accurately be assessed with this severity of hydronephrosis. It is particularly true for bilateral once (1, 4–6, 11, 30). Progressive permanent renal damage is inevitable when surgery is delayed in such cases (1, 4–6, 31). On the other hand, timely prompt surgical correction promises to improve decreased renal function in those severe cases (1, 4–6, 11, 30–32). When we see such a neonate with Onen-4, we perform an ultrasound in 1 week of life and then a second ultrasound with MAG3 1 month later. According to the results of these two tests, we decide to perform surgery or follow them conservatively for another month.

SURGICAL INDICATIONS FOR SEVERE HYDRONEPHROSIS ASSOCIATED WITH UPJ ANOMALIES BASED ON GRADING SYSTEMS

In the literature, a surgical decision for UPJHN has been made based on the increase in hydronephrosis on ultrasound in 70%

of cases, increase in hydronephrosis on ultrasound, decrease in renal function on scintigraphy in 15%, decrease in renal function on scintigraphy in 10%, and presence of symptom in 5% of UPJHN cases (1). Overall, a surgical decision has been made based on ultrasound findings in 85% of such cases. This rate will even increase if the false-positive findings and misleading (hydration, immobilization, catheterization, position, etc.) of renal scan is taken into account and if nobody uses drainage problems as a surgical indication. Therefore, correct determination of hydronephrosis severity is crucial for infants associated with UPJHN.

Surgical Indications for UPJHN Based on EAU and ESPU 2019 Guideline

Based on EAU and ESPU 2019 Guidelines on pediatric urology, surgical indications for UPJHN are impaired renal function (<40%), significant renal functional decrease (>10%) in control scans, poor drainage after furosemide injection, increased AP diameter, and SFU-III/IV (33). *All of these indications are problematic:*

- Impaired renal function (<40%) or a decrease in renal function of >10% can be a surgical indication with at least presence of Onen-3 or 4 (thin parenchyma) UPJHN. However, in children with calyceal dilation (Onen-2) alone, the reason of impaired function may be that either an etiology other than UPJHN or the impaired function may actually be false positive.
- Poor drainage function after administration of furosemide by itself should never be used as a surgical indication. This is because the drainage is poor even in UPJHN cases with only calyceal dilation (Onen-2).
- An increased AP diameter on ultrasound by itself should never be used as a surgical indication. It is very discussable. What degree is the increase in AP diameter? How many mm or

percent is the increase in AP diameter? At what location of renal pelvis is the AP diameter measured?

- SFU-3 represents only calyceal dilation with the normal renal parenchyma which should never be used as a surgical indication by itself.
- SFU-4 represents any degree of thinning in the renal parenchyma. The wide definition of SFU-4 fails to demonstrate accurately the severity of hydronephrosis and thus significantly misleads from prompt treatment. Those with cortical thinning definitely will need surgery while medullary thinning by itself (with normal renal function) does not need surgery.

Surgical Indications for UPJHN Based on the Hydronephrosis Severity Score (HSS)

It has been developed to determine the predictivity of pyeloplasty based on ultrasound and diuretic renogram findings (34). The crucial problem and disadvantage of HSS is that it relies on diuretic renogram and its curve. As we all know, renal scan is greatly affected from hydration, bladder catheterization, position, immobilization, function of the affected kidney, laterality (bilateral), diuretic timing, and operator experience (35–38).

Surgical Indications for UPJHN Based on the Pyeloplasty Prediction Score (PPS)

A recent study has suggested a pyeloplasty prediction score (PPS) using three ultrasound parameters to determine who need surgery and who do not in infants with UPJ-like hydronephrosis (39). They recommend a combination of SFU grade (A), transverse AP diameter (B), and the absolute percentage difference of ipsilateral and contralateral renal lengths at baseline (C) to predict a criterion for surgical need. This study suggests that any infant with UPJO-like hydronephrosis with a PPS of 8 or higher is 8 times more likely to undergo pyeloplasty (39). Unfortunately, none of these parameters is ideal to use due to many disadvantages and/or limitations as described in this review in details. We think that when we put problematic parameters together, it is difficult to get a correct beneficial result from them. Moreover, the laterality (normal right and left long length is different), contralateral or bilateral hydronephrosis, ipsilateral atrophy, or contralateral hypertrophy significantly changes the results of the pyeloplasty prediction score ($A + B + C$). The absolute percentage (C) would be low when there is a contralateral compensatory growth or an atrophy in ipsilateral kidney which will miss the severity of hydronephrosis. In addition, how would it be an objective criterion in bilateral cases? Any of these parameters can change the percentage (C) from 5 to 20%, which means the score may change from 0 to 4. We should use objective and reproducible criteria that are not affected by many parameters and are applicable for all patients.

Our Surgical Indications for UPJHN Based on the Onen Grading System

- Onen-4 (thin cortex) (<3 mm)
- Onen-3 (thin medulla) (3–7 mm) plus
- Presence of symptom (UTI, pain, stone) or

- >20% compensatory growth in contralateral kidney or
- >10 units decrease in renal function or
- Renal function <35%.

DISCUSSION

Although there are many studies in the literature, indications for invasive diagnostics, and surgery in infants with asymptomatic primary UPJHN are an ongoing challenge, and there is no consensus between different disciplines (1, 40). The surgical decision of such patients is done mostly based on ultrasound findings in the literature due to the invasiveness and high negative predictivity of renal scans in infants.

The crucial point for prompt diagnostics, ideal therapeutic approach, and follow-up of such patients is the severity of hydronephrosis. Such many hydronephrosis grading systems as AP diameter, SFU, radiology, UTD, and Onen have been developed to evaluate hydronephrosis severity in infants (1, 2, 4, 7, 9, 18, 23, 40–42) (Figure 6).

Though some authors have proposed cutoff values for the anterior posterior diameter of the renal pelvis, a simple threshold AP diameter value which separates non-obstructive dilation from obstructive dilatation of kidney does not exist (43). AP diameter is a very dynamic parameter and is affected by many factors (1, 10–12, 18, 19). Its measurement is very variable and misleading due to different renal pelvic configurations (1, 4, 10). Therefore, the use of AP diameters has certain disadvantages and limitations. It does not promptly demonstrate the degree of hydronephrosis (1, 2, 4–6, 11, 43). In the literature, there is no study determining intraobserver and interobserver reproducibility of the measurement of AP diameter. In addition, AP diameter does not consider calyceal dilation or the quality of the parenchyma, which may suggest severe cases of obstruction (1, 4, 12, 43).

The radiology grading system has the same grades 1, 2, and 3 as the SFU grading system with addition of the AP diameter for these 3 groups (7, 9). As we discussed above in detail, the AP diameter should not be a parameter in determining the severity of hydronephrosis for many significant reasons. This grading system divides parenchymal loss into two different grades, suggesting the importance of the renal parenchyma to determine the severity of hydronephrosis, which has somewhat a similar idea as that of the Onen hydronephrosis grading system (1, 4, 7). Radiology grade-4 hydronephrosis represents mild parenchymal loss while grade-5 represents severe parenchymal loss (7). However, it is operator dependent, is not decisive, and does not differentiate grades 4 and 5 clearly. Therefore, between- and intra-rater reliability is low.

The SFU grading system has many certain disadvantages and limitations. All grades are problematic and subjective. Both SFU-1 and SFU-2a represent different degrees of renal pelvic dilation. Therefore, it is confusing and is very difficult to differentiate each other (1, 2, 4). Moreover, follow-up, treatment, and prognosis of these two degree are similar; all of them resolve spontaneously without renal damage (1, 2, 4, 11, 20). They should be in

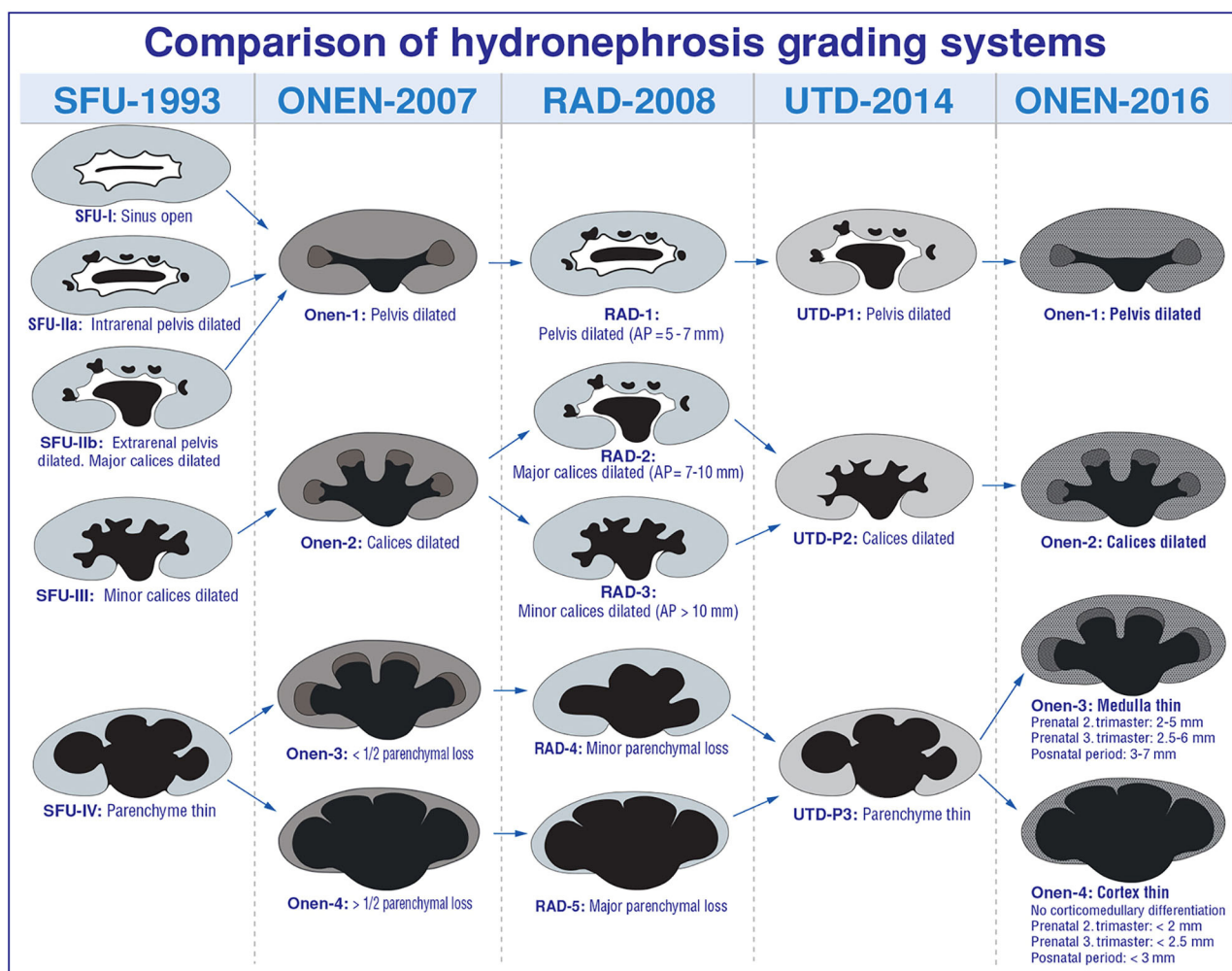


FIGURE 6 | Comparison of hydronephrosis grading systems.

the same degree of hydronephrosis. Both SFU-2b and SFU-3 represent different degrees of calyceal dilation (major vs. minor). Therefore, it is subjective, confusing, and very difficult to differentiate each other (1, 4). It can be influenced by the examiner (22). It has modest inter-rater reliability. Although SFU-3 represents only calyceal dilation, the pictures for SFU-3 show severe medullary thinning clearly. This causes significant confusion among the clinicians and radiologists (1, 4). High grades of SFU represent various features, making prognosis difficult to predict (1, 4, 8, 11, 28). It is subjective and can be influenced by the examiner (22). It has modest inter-rater reliability (43).

UTD-P classification appears to be modified partially from SFU and Onen grading system (4, 9). UTD-P1 and 2 have been modified from the Onen grading system (Onen-1 and 2) (4) while UTD-P3 has been modified from the SFU grading system (SFU-4) (9). This classification includes 3 different risk groups: low-risk (UTD-P1), intermediate-risk (UTD-P2), and high-risk (UTD-P3) groups (2, 29). None of these risk groups is the

gold standard for all patients. AP diameter >15 mm, peripheral calyceal dilation, and dilated ureter represent intermediate risk (UTD-P2). For example, bilateral grade-4 intra-renal reflux has exactly these findings. However, we all know that this does not represent intermediate risk. It should be in the high-risk group due to the fact that most of these patients develop significant renal damage and UTI breakthrough with fever. There are many similar examples suggesting that this risk scoring is not the standard for all such patients. Between- and within-rater reliability is moderate for this classification (26, 27).

Significant variability exists within and between raters in SFU, radiology grading, and UTD classification. This is because it is significantly operator dependent to differentiate the dilation of peripheral (minor) calices from those of central (major) calices due to a high discrepancy between raters for interpretation of the two types of calyceal dilation (26, 27). Therefore, the UTD score reliability has been found to be low (26, 27). It is exactly the same for SFU-2b and SFU-3 as well as radiology grades 2 and 3 (1, 4, 7, 9, 26, 27). Central (major) calices are somewhat like a neck

between the renal pelvis and peripheral (minor) calices. In fact, the real calices are peripheral ones. Therefore, in our opinion, the exact calyceal dilation should be accepted as peripheral (minor) calyceal dilation. It is because it is significant dilation that is clearly different from renal pelvic dilation and is well-visualized and there is no high discrepancy between raters for interpretation (1, 4). Opposite to SFU, radiology, and UTD classification, the Onen grading system does not differ the central and peripheral calyceal dilation.

SFU-4 and UTD-P3 represent the same degree of hydronephrosis. Both represent any kind of renal parenchymal thinning (medulla or cortex), which is a considerable range of severity of hydronephrosis (2, 9). This wide definition of SFU-4 and UTD-P3 fails to demonstrate accurately the severity of hydronephrosis and thus significantly misleads from prompt treatment. They do not suggest who need surgical treatment and who can safely be followed non-operatively in infants with severe UPJHN (1, 2, 4–6, 11). In addition, these two grades make prognosis difficult to predict in UPJHN cases (1, 4, 8, 28).

The Onen hydronephrosis grading system which has been updated in 2016 determined specific detailed findings of significant renal damage, which clearly showed and suggested who can safely be treated conservatively from who will need surgical intervention for UPJHN (1). The intra-rater reliability of Onen grading is higher than that of SFU (2, 20). This grading system has been shown to have good inter- and intra-observer agreements in the diagnosis and follow-up of hydronephrosis in children (20). Intra-observer agreement for the diagnosis of hydronephrosis in prenatal ultrasound recently showed an almost perfect agreement in the Onen grading system (22).

Onen grading system has a sensitivity of 100%, specificity of 76%, and accuracy of 86.4% (21). In a recent study, all units that had Onen-1 and 2 were not obstructed and had renal function > 40% while Onen grade-4 had 100% specificity, meaning that it consistently predicts kidney damage due to obstruction when present (1, 21). Therefore, renal scan is required for only Onen-3 patients; thus, renal scan could be avoided in more than two-thirds of cases (1, 21).

The upgraded Onen grading system not only uses the quality of the renal parenchyma but also takes into account both affected and contralateral kidney size including longitudinal length and atrophy (1). Considering parenchymal loss, SFU and UTD are the same, differing from the Onen grading system that stratifies it in cortical and medullary loss, which was found clearly more precise (1, 21). Recent studies have shown that patients with Onen-3 had better renal function than Onen-4, proving that this difference is relevant to choosing this grading system for children (1, 4, 5, 11, 21). Bienias and Sikora have shown that 21/25 (84%) children with Onen grades 3 and 4 developed obstructive nephropathy with impaired relative function from 15 to 35% (44). If the study separated Onen-3 and 4, almost 100% of Onen-4 would have shown significant renal damage when they did not undergo surgery. Patients with Onen grade-4 had a 100% specificity while those with parenchymal loss not specified (SFU-4, UTD-3) had only 76% specificity regarding obstruction (21). Therefore, dividing SFU-4 or UTD-P3 into Onen grade-3 (medulla thin) and Onen-4 (cortex thin) provides

valuable important information in the follow-up and prognosis of high-grade hydronephrosis (1, 4, 8, 11, 21, 28).

DRF and SFU grade of hydronephrosis do not correctly reflect renal injury in bilateral UPJO; however, Onen hydronephrosis grade shows a significant relationship with renal histopathologic grade and can be an indicator for renal injury in UPJO (45). The Onen grading system is more relevant to post-natal prognosis of fetal hydronephrosis compared to SFU and UTD classification (1, 4, 5, 11). It has previously been shown that the Onen grading system determines the severity of UPJHN better and make follow-up more practical compared to SFU and UTD (1, 11). It is reliable and easily reproducible and plays a significant role in the diagnosis of obstruction in children (1, 21). Therefore, the use and popularity of this grading system are increasing around the world (20–22, 45).

In summary, neither AP diameter nor radiology or SFU or UTD is the gold standard in determining the severity of hydronephrosis. They have been shown to be unsuitable for standardizing due to evaluation criteria (1, 4, 21). All these grading systems are based on subjective parameters and are affected by many factors (1, 2, 4–7, 11, 25). They do not determine the exact severity of UPJHN and thus cause permanent renal damage due to delay in surgical decision in some infants while causing unnecessary surgery in others. In addition, they make prognosis difficult in UPJHN cases (1, 4, 8, 11, 28).

The 4 special structures of the kidney (pelvis, calices, medulla, cortex), each having different anatomophysiologic properties, should be taken into account in determining the severity of hydronephrosis. This is because each produces different risks of renal damage. The upgraded Onen hydronephrosis grading system has been developed based on this basic evidence. Therefore, it has resolved all disadvantages of other grading systems. It is an accurate and easily reproducible grading that has high sensitivity and specificity for diagnosis of obstruction, follow-up, prompt treatment (surgical requirement), and prognosis of infants with UPJHN (1, 4–6, 11, 21).

Regardless of the type of hydronephrosis grading systems, AP diameter and calyceal dilation by themselves are insufficient parameters in determining the severity of hydronephrosis. The quality of the renal parenchyma (thickness and appearance) which is the crucial parameter that parallels with renal function and damage should be taken into account in determining the severity of hydronephrosis. This is because it is an important parameter that significantly and objectively suggests who need invasive diagnostic and surgery while giving information about the clinical prognosis of infants associated with UPJHN.

AUTHOR CONTRIBUTIONS

The author confirms being the sole contributor of this work and has approved it for publication.

ACKNOWLEDGMENTS

The author would like to give his sincere thanks to Prof Steve Koff for improving my vision on hydronephrosis.

REFERENCES

- Onen A. Üreteropelvik bileşke darlığı. *Çocuk Cerrahisi Dergisi*. (2016) 30:55–79. doi: 10.5222/JTAPS.2016.055
- Nguyen HT, Benson CB, Bromley B, Campbell JB, Chow J, Coleman B, Cooper C, et al. Multidisciplinary consensus on the classification of prenatal and postnatal urinary tract dilation (UTD classification system). *J Pediatr Urol*. (2014) 10:982–99. doi: 10.1016/j.jpuro.2014.10.002
- Passerotti CC, Kalish LA, Chow J, Passerotti AMS, Recabal P, Cendron M, et al. The predictive value of the first postnatal ultrasound in children with antenatal hydronephrosis. *J Pediatr Urol*. (2011) 7:128–36. doi: 10.1016/j.jpuro.2010.09.007
- Onen A. An alternative hydronephrosis grading system to refine the criteria for exact severity of hydronephrosis and optimal treatment guidelines in neonates with primary UPJ-type hydronephrosis. *J Pediatr Urol*. (2007) 3:200–5. doi: 10.1016/j.jpuro.2006.08.002
- Onen A. Treatment and outcome of prenatally detected newborn hydronephrosis. *J Pediatr Urol*. (2007) 3:469–76. doi: 10.1016/j.jpuro.2007.05.002
- Onen A. Neonatal Hidronefrozarlar. In: Onen A, editor. *Çocuk Cerrahisi ve Çocuk Ürolojisi Kitabı*. İstanbul: Nobel Tip Kitabevi. (2006). p. 345–66.
- Riccabona M, Avni FE, Blickman JG, Dacher JN, Darge K, Lobo ML, et al. Imaging recommendations in paediatric urology: minutes of the ESPR workgroup session on urinary tract ultrasonography and voiding cystourethrography. *Pediatr Radiol*. (2008) 38:138–45. doi: 10.1007/s00247-007-0695-7
- Onen A. Üreteropelvik bileşke darlıkları ve nadir üreter anomalileri. In: Onen A, editor. *Çocuk Cerrahisi ve Çocuk Ürolojisi Kitabı*. İstanbul: Nobel Tip Kitabevi (2006). p. 367–72.
- Fernbach SK, Maizels M, Conway JJ. Ultrasound grading of hydronephrosis: introduction to the system used by the society for fetal urology. *Pediatr Radiol*. (1993) 23:478–80. doi: 10.1007/BF02012459
- Kadioglu A. Renal measurements, including length, parenchymal thickness, and medullary pyramid thickness, in healthy children: what are the normative ultrasound values? *Am J Roentgenol*. (2010) 194:509–15. doi: 10.2214/AJR.09.2986
- Onen A, Yalinkaya A. *Possible Predictive Factors for A Safe Prenatal Follow-Up of Fetuses with Hydronephrosis. The 29th Congress of European Society of Pediatric Urology 11th – 14th April. Helsinki: EPU* (2018).
- Nguyen HT, Herndon ACD, Cooper C, Gatti J, Kirsch A, Kokorowski P, et al. The society for fetal urology consensus statement on the evaluation and management of antenatal hydronephrosis. *J Pediatr Urol*. (2010) 6:212–31. doi: 10.1016/j.jpuro.2010.02.205
- Eze CU, Agwu KK, Ezeasor DN, Agwuna KK, Aronu AE, EI Mba EL. Sonographic biometry of normal kidney dimensions among school-age children in Nsukka, Southeast Nigeria. *West Indian Med J*. (2014) 63:46–53. doi: 10.7727/wimj.2013.010
- Konda R, Sakai K, Ota S, Abe Y, Hatakeyama T, Orikasa S. Ultrasound grade of hydronephrosis and severity of renal cortical damage on 99mtechnetium dimercaptosuccinic acid renal scan in infants with unilateral hydronephrosis during followup and after pyeloplasty. *J Urol*. (2002) 167:2159–63. doi: 10.1016/S0022-5347(05)65118-X
- Moghazi S, Jones E, Schroeppe J, Arya K, McClellan W, Hennigar RA, et al. Correlation of renal histopathology with sonographic findings. *Kidney Int*. (2005) 67:1515–20. doi: 10.1111/j.1523-1755.2005.00230.x
- Stock JA, Krous HF, Heffernan J, Packer M, Kaplan GW. Correlation of renal biopsy and radionuclide renal scan differential function in patients with unilateral ureteropelvic junction obstruction. *J Urol*. (1995) 154:716–8. doi: 10.1016/S0022-5347(01)67142-8
- Chevalier RL, Thornhill BA, Forbes MS, Kiley SC. Mechanism of renal injury and progression of renal disease in congenital obstructive nephropathy. *Pediatr Nephrol*. (2010) 25:687–97. doi: 10.1007/s00467-009-1316-5
- Timberlake MD, Herndon CDA. Mild to moderate postnatal hydronephrosis grading systems and management. *Nat Rev Urol*. (2013) 10:649–56. doi: 10.1038/nrurol.2013.172
- Pereira AK, Reis ZS, Bouzada MC, de Oliveira EA, Osanan G, Cabral AC. Antenatal ultrasonographic antero-posterior renal pelvis diameter measurement: is it a reliable way of defining fetal hydronephrosis? *Obstet Gynecol Int*. (2011) 2011:861–5. doi: 10.1155/2011/861865
- Kim SY, Kim MJ, Yoon CS, Lee MS, Han KH, Lee MJ. Comparison of the reliability of two hydronephrosis grading systems: the society for fetal urology grading system vs. the Onen grading system. *Clin Radiol*. (2013) 68:484–90. doi: 10.1016/j.crad.2013.03.023
- De Bessa Jr, Rodrigues CM, Chammas MC, Miranda EP, Gomes CM, Moscardi PR, et al. Diagnostic accuracy of Onen's alternative grading system combined with doppler evaluation of ureteral jets as an alternative in the diagnosis of obstructive hydronephrosis in children. *Peer J*. (2018) 6:e4791. doi: 10.7717/peerj.4791
- Cho HY, Jung I, Kim YH, Kwon JY. Reliability of society of fetal urology and Onen grading system in fetal hydronephrosis. *Obstet Gynecol Sci*. (2019) 62:87–92. doi: 10.5468/ogs.2019.62.2.87
- Dhillon HK. Prenatally diagnosed hydronephrosis: the great ormond street experience. *Br J Urol*. (1998) 81:39–44. doi: 10.1046/j.1464-410X.1998.0810s2039.x
- Keays MA, Guerra LA, Mihill J, Raju G, Al-Asheeri N, Geier P, et al. Reliability assessment of society for fetal urology ultrasound grading system for hydronephrosis. *J Urol*. (2008) 180:1680–2. doi: 10.1016/j.juro.2008.03.107
- Yamaçake KGR, Nguyen HT. Current management of antenatal hydronephrosis. *Pediatr Nephrol*. (2013) 28:237–43. doi: 10.1007/s00467-012-2240-7
- Back SJ, Edgar JC, Weiss DA, Oliver ER, Bellah RD, Darge K. Rater reliability of postnatal urinary tract consensus classification. *Pediatric Radiol*. (2018) 48:1606–11. doi: 10.1007/s00247-018-4173-1
- Rickard M, Easterbrook B, Kim S, DeMaria J, Lorenzo AJ, Braga LH, et al. Six of one, half a dozen of the other: a measure of multidisciplinary inter/intra-rater reliability of the society for fetal urology and urinary tract dilation grading systems for hydronephrosis. *J Pediatr Urol*. (2017) 13:80.e81–5. doi: 10.1016/j.jpuro.2016.09.005
- Sidhu G, Beyene J, Rosenblum ND. Outcome of isolated antenatal hydronephrosis. A systematic review and metaanalysis. *Pediatr Nephrol*. (2006) 21:218–24. doi: 10.1007/s00467-005-2100-9
- Pelliccia P, Papa SS, Cavallo F, Tagi VM, Serafino MD, Esposito F, et al. Prenatal and postnatal urinary tract dilation: advantages of a standardized ultrasound definition and classification. *J Ultrasound*. (2018) 22:5–12. doi: 10.1007/s40477-018-0340-3
- Onen A, Jayanthi VR, Koff SA. Long-term follow-up of prenatally detected severe bilateral newborn hydronephrosis initially managed nonoperatively. *J Urol*. (2002) 168:1118e20. doi: 10.1016/S0022-5347(05)64604-6
- Bansal R, Ansari MS, Srivastava A, Kapoor R. Longterm results of pyeloplasty in poorly functioning kidneys in the pediatric age group. *J Pediatr Urol*. (2012) 8:25–8. doi: 10.1016/j.jpuro.2010.12.012
- Jindal B, Bal CS, Bhatnagar V. The role of renal function reserve estimation in children with hydronephrosis. *J Indian Assoc Paediatr Surg*. (2007) 12:196–201. doi: 10.4103/0971-9261.40834
- Radmayr C, Bogaert G, Dogan HS, Kocvara R, Nijman JM, Stein R, et al. EAU guidelines on pediatric urology. In: *European Society for Paediatric Urology and European Association of Urology*. Arnhem: EAU Guidelines Office (2019). p. 55–9.
- Babu R, Venkatachalapathy E, Sai V. Hydronephrosis severity score: an objective assessment of hydronephrosis severity in children-a preliminary report. *J Pediatr Urol*. (2019) 15:68.e6. doi: 10.1016/j.jpuro.2018.09.020
- Shulkin BL, Mandell GA, Cooper JA, Leonard JC, Majd M, Parisi MT, et al. Procedure guideline for diuretic renography in children 3.0. *J Nucl Med Technol*. (2008) 36:162–8. doi: 10.2967/jnmt.108.056622
- Piepsz A. Antenatal detection of pelviureteric junction stenosis: main controversies. *Semin Nucl Med*. (2011) 41:11–9. doi: 10.1053/j.semnuclmed.2010.07.008
- Wong DC, Rossleigh MA, Farnsworth RH. Diuretic renography with the addition of quantitative gravity-assisted drainage in infants and children. *J Nucl Med*. (2000) 41:1030–6.
- Turkolmez S, Atasver T, Turkolmez K, Gogus O. Comparison of three different diuretic renal scintigraphy protocols in patients with dilated upper urinary tracts. *Clin Nucl Med*. (2004) 29:154–60. doi: 10.1097/01.rlu.0000113852.57445.23
- Li B, McGrath M, Farrokhkar F, Braga LH. Ultrasound-based scoring system for indication of pyeloplasty in patients with UPJO-like hydronephrosis. *Front Pediatr*. (2020) 8:353. doi: 10.3389/fped.2020.00353

40. Zanetta VC, Rosman BM, Bromley B, Shipp TD, Chow JS, Campbell JB, et al. Variations in management of mild prenatal hydronephrosis among maternal-fetal medicine obstetricians, pediatric urologists and radiologists. *J Urol.* (2012) 188:1935–9. doi: 10.1016/j.juro.2012.07.011
41. Carr MC. Ureteropelvic junction obstruction and multicystic dysplastic kidney: surgical management. In: Docimo SG, Canning DA, Khoury AE, editors. *The Kelalis-King-Belman Textbook of Clinical Pediatric Urology*, 5th ed. United Kingdom: Informa Healthcare UK Ltd. (2007). p. 479–86.
42. Carr MC, Ghoneimi AE. Anomalies and surgery of the ureteropelvic junction in children. In: Wein AJ, Kavoussi LR, Novick AC, Partin AW, Peters CA, editors. *Campbell-Walsh Urology*, 9th ed. Philadelphia: Saunders Elsevier (2007). p. 3359–82.
43. Sarin YK. Is it always necessary to treat an asymptomatic hydronephrosis due to ureteropelvic junction obstruction? *Indian J Pediatr.* (2017) 84:531–9. doi: 10.1007/s12098-017-2346-9
44. Bienias B, Sikora P. Potential novel biomarkers of obstructive nephropathy in children with hydronephrosis. *Hindawi Dis.* (2018) 2018:105726. doi: 10.1155/2018/1015726
45. Lee YS, Jeong HJ, Im YJ, Kim MJ, Lee MJ, Yun M, et al. Factors indicating renal injury in pediatric bilateral ureteropelvic-junction obstruction. *Urology.* (2013) 81:873–9. doi: 10.1016/j.urology.2012.09.064

Conflict of Interest: The author declares that the research was conducted in the absence of any commercial or financial relationships that could be construed as a potential conflict of interest.

Copyright © 2020 Onen. This is an open-access article distributed under the terms of the Creative Commons Attribution License (CC BY). The use, distribution or reproduction in other forums is permitted, provided the original author(s) and the copyright owner(s) are credited and that the original publication in this journal is cited, in accordance with accepted academic practice. No use, distribution or reproduction is permitted which does not comply with these terms.



Prenatal Diagnosis and Findings in Ureteropelvic Junction Type Hydronephrosis

Recep Has* and Tugba Sarac Sivriköz

Division of Perinatology, Department of Obstetrics and Gynecology, Istanbul Faculty of Medicine, Istanbul University, Istanbul, Turkey

OPEN ACCESS

Edited by:

Venkata R. Jayanthi,
Nationwide Children's Hospital,
United States

Reviewed by:

Roberto Iglesias Lopes,
Hospital for Sick Children, Canada
Onur Telli,
Istanbul Kartal Dr. Lutfi Kirdar
Education and Research
Hospital, Turkey

*Correspondence:

Recep Has
recephas@gmail.com

Specialty section:

This article was submitted to
Pediatric Urology,
a section of the journal
Frontiers in Pediatrics

Received: 16 February 2020

Accepted: 14 July 2020

Published: 04 September 2020

Citation:

Has R and Sarac Sivriköz T (2020)
Prenatal Diagnosis and Findings in
Ureteropelvic Junction Type
Hydronephrosis. *Front. Pediatr.* 8:492.
doi: 10.3389/fped.2020.00492

The widespread use of obstetric ultrasonography has increased the detection rate of antenatal hydronephrosis. Although most cases of antenatal hydronephrosis are transient, one third persists and becomes clinically important. Ultrasound has made differential diagnosis possible to some extent. Ureteropelvic junction type hydronephrosis (UPJHN) is one of the most common cause of persistent fetal hydronephrosis and occurs three times more in male fetuses. It is usually sporadic and unilateral. However, when bilateral kidneys are involved and presents with severe hydronephrosis, the prognosis may be poor. Typical ultrasound findings of UPJHN is hydronephrosis without hydroureter. The size and appearance of the fetal bladder is usually normal without thickening of the bladder wall. Several grading systems are developed and increasingly being used to define the severity of prenatal hydronephrosis and provides much more information about prediction of postnatal renal prognosis. If fetal urinary tract dilation is detected; laterality, severity of hydronephrosis, echogenicity of the kidneys, presence of ureter dilation should be assessed. Bladder volume and emptying, sex of the fetus, amniotic fluid volume, and presence of associated malformations should be evaluated. Particularly the ultrasonographic signs of renal dysplasia, such as increased renal parenchymal echogenicity, thinning of the renal cortex, the presence of cortical cysts, and co-existing oligohydramnios should be noticed. Unfortunately, there is no reliable predictor of renal function in UPJHN cases. Unilateral hydronephrosis cases suggesting UPJHN are mostly followed up conservatively. However, the cases with bilateral involvement are still difficult to manage. Timing of delivery is also controversial.

Keywords: fetal hydronephrosis, ureteropelvic junction obstruction, fetal pelviectasia, pediatric urinary tract dilation, ultrasound

KEY CONCEPTS

- UPJHN is the most common cause of persistent antenatal hydronephrosis. It is usually unilateral and three times more in male fetuses.
- UPJHN may be 10–30% bilateral and should be managed cautiously for the deterioration of renal functions.
- In all cases with prenatal UPJHN, AP renal pelvis diameter, presence and localization of calyx dilation, renal parenchymal features, presence of urinoma and oligohydramnios should be assessed.

- Patients in the high-risk group should be monitored during the prenatal period with an interval of 2–4 weeks, however patient monitoring should be customized according to the other negative findings.
- When UPJHN is detected during the prenatal period, consulting with pediatric urologists before delivery may contribute the postnatal management plans.

INTRODUCTION

Congenital hydronephrosis is one of the most common anomalies encountered at the prenatal ultrasound evaluation. It is observed in 1–4% of all pregnancies (1, 2).

Prenatal urinary system evaluation should preferably follow an anatomical sequence in order to identify the cause of the dilation. Therefore, urinary system examination in the prenatal period should demonstrate position of bilateral kidneys, dilation of renal pelvis and presence of calyx dilation (central and peripheral), echogenicity of kidney parenchyma, both ureters, bladder size and wall thickness, and anatomy of the external genitalia.

Detection of urinary system malformations are related to the week of gestation when the screening has been performed. Urinary system is usually assessed at 19–21 weeks of gestation, and late onset hydronephrosis is commonly missed during this period. Therefore, urinary system anomalies are not infrequently identified in the third trimester up to a rate of 5% (3).

URINARY SYSTEM EVALUATION WITH PRENATAL ULTRASOUND

Examination of the urinary system in fetal ultrasound scan begins with identifying the presence of kidneys and bladder. From the 11–12 weeks of gestation, fetal kidneys can be visualized by transvaginal ultrasonography as hyperechogenic structures (4) (**Figure 1a**). Fetal kidneys are imaged in the abdomen at both sides of vertebral column on axial, longitudinal and coronal planes (**Figures 1b–d**). Kidneys appear as two

round paravertebral structures on axial views and renal pelvis oriented toward the midline (**Figure 1b**). The appearance of normal kidney looks bean-like on longitudinal and coronal planes. At coronal plane, both kidneys can be visualized on the same section and can be compared to each other (**Figure 1d**). Size of the kidneys can be evaluated by measuring the renal length and comparing it to normal charts. Normal kidneys have the same echogenicity with liver and spleen (**Figure 1c**). When kidney echogenicity is higher than spleen or liver, it is considered to be hyperechogenic. The cortex and medulla of the kidneys also become differentiable in fetuses older than 18 weeks and difference becomes more significant toward the third trimester (**Figures 1c,d, 2c**). The renal cortex is slightly echogenic at the periphery of medulla. The adrenal glands are located cranial to the kidneys as more hypoechogenic structures (**Figures 1c, 2d**).

After evaluation of the location of both kidneys, parenchymal features, the assessment of the dilation (pelviectasis) of the renal pelvis should be made. From the beginning of the second trimester, renal pelvis becomes detectable and the kidneys generally lose their previous hyperechogenic appearance. Renal pelvis always appears as a sonolucent area in the medial of the kidneys (**Figure 1b**). Pelviectasis or hydronephrosis is evaluated in the sections of the fetal abdominal transverse planes, by measuring the anteroposterior diameter (APD) of the renal pelvis, where possible the fetal back is perpendicular to the probe (**Figure 2a**). Dilation of the renal pelvis may differ by gestational week, maternal hydration, or bladder distension (5–7).

The bladder can be visualized into the fetal pelvis from the 10th week of pregnancy, however from the 12th week on the pelvis it should be visible as a sonolucent cystic structure between both umbilical vessels (**Figure 2b**). Ideal position to measure bladder wall thickness is near the umbilical arteries in axial plane of the fetal pelvic area. Bladder wall thickness does not exceed 2 mm in prenatal period regardless of gestational week (8, 9). Fetal bladder empties and refills every 25–30 min during second and third trimester. Although nomogram charts to check the bladder size may be used, subjective assessment is usually gives

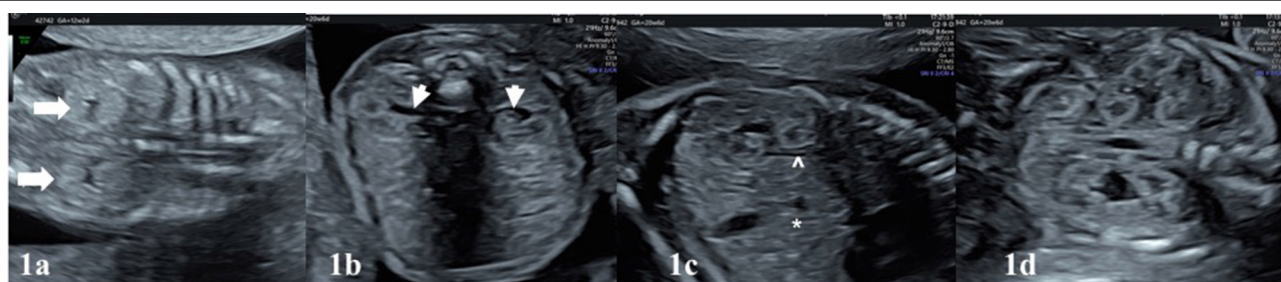


FIGURE 1 | In (a), kidneys of a 12-week fetus. The best visualization of kidneys (white bold arrows) can be obtained in coronal plane with transvaginal ultrasound at this gestational age. (b) Transabdominal ultrasound shows the normal appearance of both kidneys on the axial plane at 20 + 6 weeks of gestation. Kidneys are located both sides of vertebra and renal pelvis (white arrow-heads) oriented toward the midline. (c) Longitudinal plane, echogenicity of the kidney is comparable to the liver (*). Hypoechoic adrenal gland (Λ) is located cranial to the kidney. Cortico-medullary differentiation (white chevron) can be noticed. (d) Coronal plane shows two bean-like kidneys in the same section. This plane is useful to compare the kidneys. The corticomedullary differentiation can be noticed easily on the coronal plane.

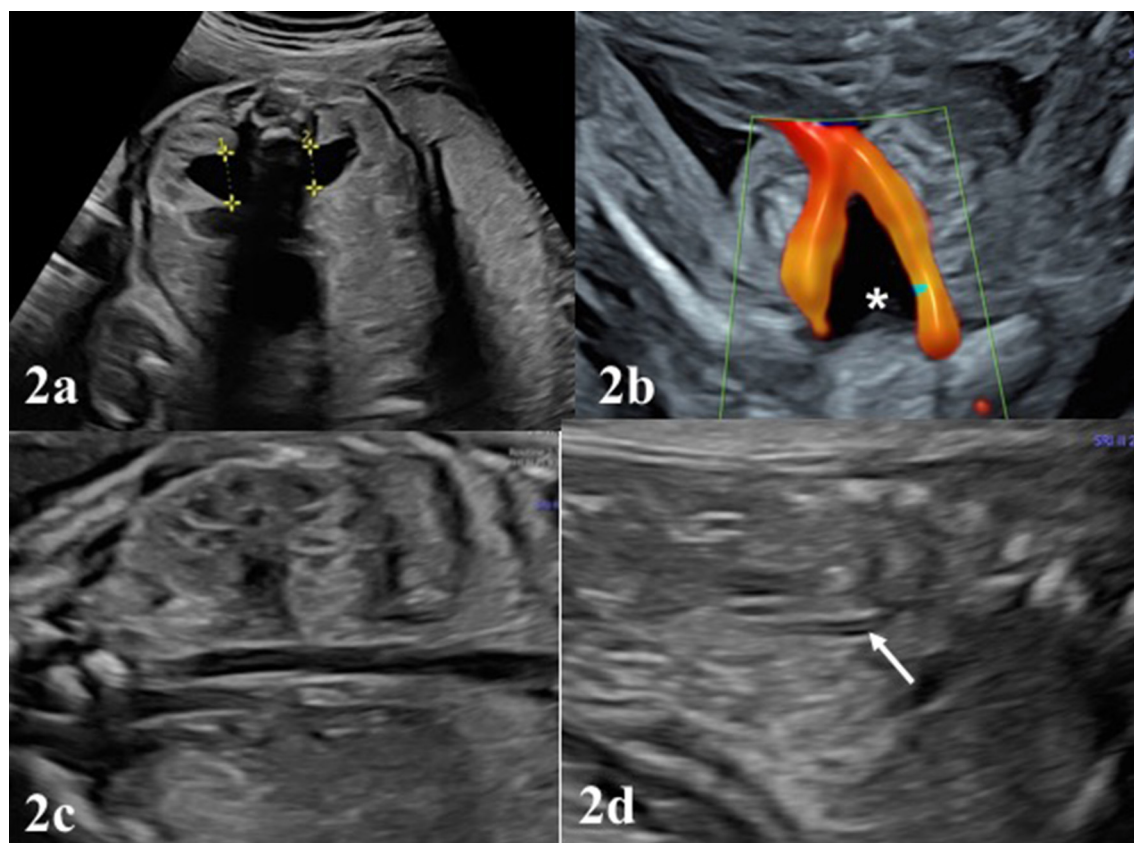


FIGURE 2 | (a), the normal appearance of the fetal bladder (white asterisk) in the pelvis between both umbilical vessels. (b) The appearance of kidneys in the 22 weeks with mild renal pelvis diameter. Antero-posterior diameter (APD) of pelvis renalis should be measured in the axial plane, better if fetus in dorso-anterior position. (c) Note the corticomedullary differentiation in a normal appearing fetal kidney. In (d), white arrow depicts the suprarenal gland lying on the kidney, shown as echogenic medulla and hypoechogenic cortex.

satisfactory information. Ureters and urethra are not typically visible structures in the prenatal period. These structures may be visualized when dilated in case of bladder outlet obstruction or vesicoureteral reflux.

Fetal urine is the primary source of the amniotic fluid after 14–16 weeks of gestation. Normal volume of amniotic fluid is not only the predictor of normal renal function, but also needed for proper development of fetal lungs. Therefore, the assessment of urinary system should also include evaluation of amniotic fluid volume.

To summarize, when antenatal hydronephrosis (ANH) is diagnosed, the following parameters should be examined in a certain order by ultrasound:

- Severity and progress of hydronephrosis: As the APD increases, the possibility of concomitant congenital urinary system anomalies increases. Presence of calyx dilation and involvement of central or peripheral calices should be assessed. Repeat ultrasound examinations in the second and third trimesters will guide to determine neonatal prognosis. In the presence of severe pelviectasis, the need for surgical intervention may significantly increase in the neonatal period (10).
- Laterality: Such as, if UPJHN is bilateral, the risk for additional congenital kidney anomalies and renal function impairment is increased.
- Parenchymal appearance: An echogenic renal cortex suggests abnormal change of the renal parenchyma. The presence of parenchyma thinning or cortical cyst is associated with impaired renal function. These changes are often observed as consequence of UPJHN, and other lower urinary tract obstructions such as posterior urethral valve (PUV) or VUR.
- Urinoma/urinary ascites: Urinoma is an encapsulated paranephric pseudocyst confined to the Gerota's fascia. It often develops secondary to obstructive pathologies. Although it is rare, it co-exists with dysplastic non-functional kidney on the same side in 80% of cases (11). Urinary ascites develops in cases with lower urinary tract obstruction following to spontaneous or iatrogenic rupture of the kidney or bladder.
- Ureter: Ureter dilation is not observed with UPJHN. It is typically associated with obstructions distal to the uretero-pelvic junction, such as PUV and other infravesical obstructions or vesico-ureteral reflux (VUR) (Figures 4a,b).
- Bladder/ureterocele: Bladder size, appearance, and wall thickness are normal in UPJHN. If increased bladder wall thickness and trabeculation is detected, obstruction distal to

the bladder neck (PUV) should be considered (**Figures 4a,b**). Ureterocele is a cystic dilation of ureter detected inside the bladder. It is usually seen with duplication of the collecting system anomalies, secondary to distended ureters.

- Amniotic fluid volume: Oligohydramnios develops after decreased urine output due to the urinary tract obstruction or decreased urine production as a result of impaired renal function. It is usually predictor of poor prognosis and implicates severe renal disease, where both kidneys are affected.

EVALUATION OF ANTEROPOSTERIOR PELVIS DIAMETER (APD) AND CLASSIFICATION

Fetal hydronephrosis is usually detected by ultrasound in the second trimester and defined as a renal pelvis diameter measurement above ≥ 4 mm. As gestational week progresses, definition of threshold values for dilation of the renal pelvis increases in the prenatal period (7) (**Table 1**). A measurement of ≤ 3 mm is considered normal in all gestational weeks (12). Mild hydronephrosis (APD 4–10 mm) may be a transient finding, or rarely associated with renal or chromosomal abnormalities. More severe dilation increases the risk of congenital anomalies of the kidney and urinary tract (CAKUT). Nguyen et al. reported that 50–70% of the urinary system dilations detected in antenatal period are temporary (7). Determining specific limit values for each trimester of the pregnancy is important for the frequency, follow-up and management of the pelviectasis in both prenatal and postnatal period. Among the prenatal mild pelviectasis cases, only a small proportion have a serious problem in the postnatal period. Renal pathology is confirmed in postnatal period in 12–14% of mild, 45% of moderate and 90% of severe pelviectasis cases detected in the second and third trimesters of pregnancy (13). Presence of calyx dilation and identification of parenchymal echogenicity is important for the prediction of clinically significant ANH cases (14). When calyx dilation (pelvicaliectasis) is accompanied to the renal pelvis dilation, the location should also be defined as central or peripheral. This is important for the classification and prediction of prognosis.

In order to plan postnatal follow-up, several classification systems for the urinary tract dilation (UTD) have been proposed based on ultrasonographic findings. The most common used classification systems are the Society for Fetal Urology (SFU) Hydronephrosis Grading System and the Urinary Tract Dilation (UTD) Classification System (1, 7). SFU system has five grades (0–4) (7). In this classification system, intra and extra-renal dilation of the renal pelvis is defined subjectively. Dilation of central and peripheral calyces is assessed and parenchymal thickness is described subjectively (**Table 2**).

In UTD classification system, measurement of renal pelvis antero-posterior diameter, presence of calyx dilation, subjective definition of parenchymal thickness and parenchymal appearance are specified. Dilation of ureters, assessment of

TABLE 1 | Stage of antenatal hydronephrosis (ANH) based on renal pelvis APD in relation to gestational age.

Degree of ANH	APD at 2nd trimester	APD at 3rd trimester
Mild	4–7 mm	7–9 mm
Moderate	7–10 mm	9–15 mm
Severe	> 10 mm	> 15 mm

TABLE 2 | The sonographic SFU Grading system for fetal urology (<https://www.uab.edu/images/peduro/SFU>).

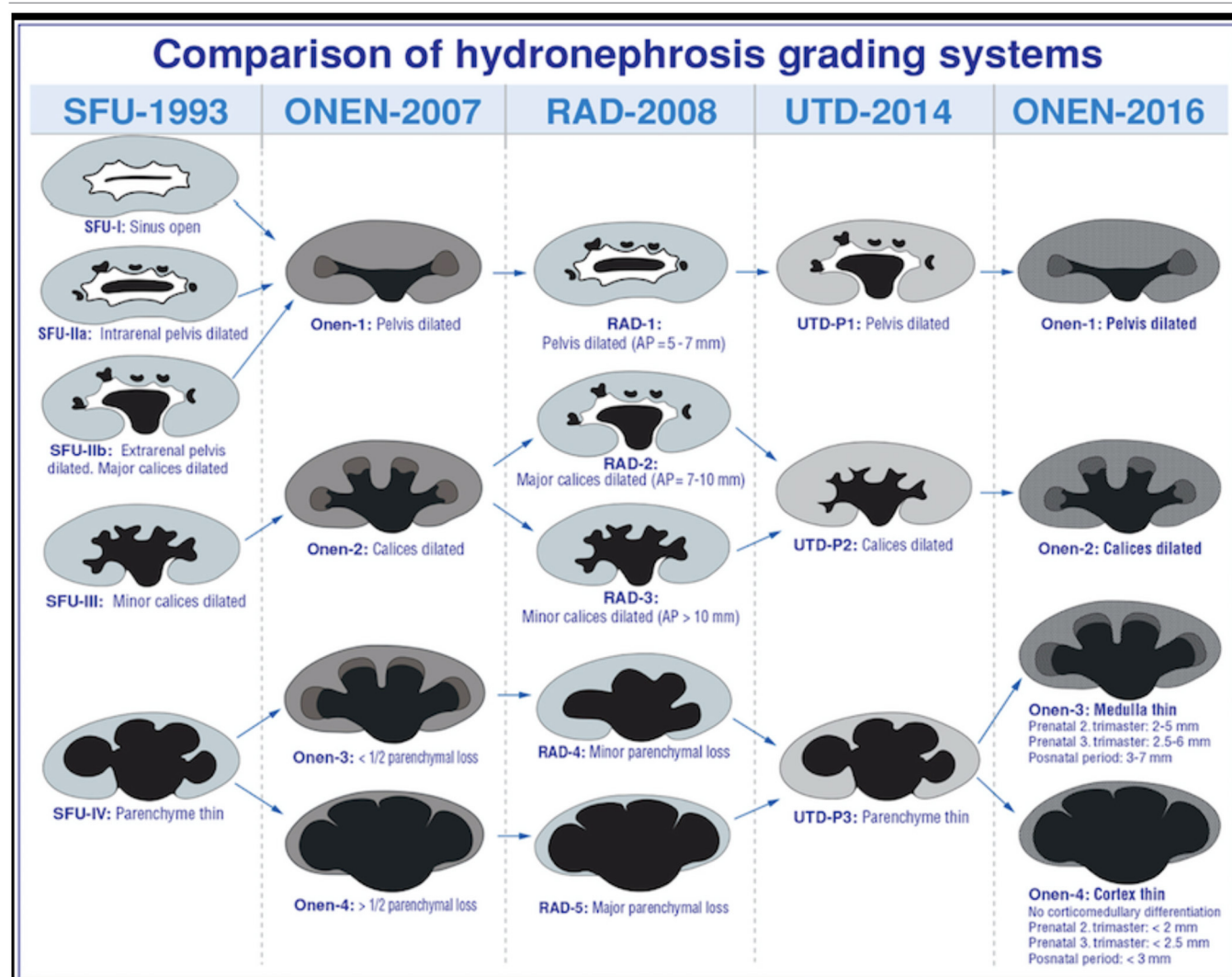
	Pattern of renal sinus
SFU grade 0	No splitting
SFU grade 1	Urine in pelvis barely splits sinus
SFU grade 2	Urine fills intrarenal pelvis
SFU grade 2	Urine fills extrarenal pelvis, major (central) calyces dilated
SFU grade 3	SFU G2 and minor (peripheral) calyces uniformly dilated and parenchyma preserved
SFU grade 4	SFU G3 and parenchyma thin

bladder (wall thickness, ureterocele, and dilated posterior urethra) and presence of oligohydramnios are also considered (**Table 3**) (1). The most important difference of this classification is, quantitative assessment of urinary system (1). Patients are monitored in the prenatal period by separating them into low-risk and high-risk groups according to the severity of the features determined in the UTD classification. As the grade advances prognostic significance increases in UTD system. For example, a fetus has 9 mm renal pelvis AP diameter with increased echogenicity of the kidneys is classified in high-risk group. UTD system may be used also for postnatal cases. This system can evaluate antenatal and postnatal hydronephrosis simultaneously, therefore, some studies stated that it is the classification system with the highest correlation with neonatal results (15).

An alternative classification system for primary UPJHN was proposed by Onen in 2007 (14). According to Onen's grading system (AGS), isolated pelvic dilation was classified as grade 1. Grade 2 is the presence of calyx dilation in addition to renal pelvis dilation. Grade 3 includes <50% loss in renal parenchyma and grade 4 has severe parenchymal loss. AGS covers essentially neonatal period and is used only for primary UPJHN. Using AGS grading system may simplify the follow-up and treatment plan in postnatal patients with UPJHN. However, it may be difficult to assess the thinning of medulla and cortex separately in the fetus particularly before the third trimester and this system needs to be studied in prenatal period to make a statement on it. UTD system is actually combination of APD classification and SFU and provides more information for the diagnosis. More studies are needed to be done in the prenatal period to compare the SFU, UTD, and AGS classification systems for UPJHN. A comparison of all three grading systems and radiological assessment is demonstrated in **Table 4** (16).

TABLE 3 | Urinary Tract Dilatation Classification System.

Ultrasound findings	Time at presentation		
	16–27 weeks	≥28 weeks	Postnatal (>48 h)
Anterior-posterior renal pelvis diameter (APRPD)	<4 mm	<7 mm	<10 mm
Calyceal dilatation	No	No	No
Central	No (if yes high risk)	No (if yes high risk)	No (if yes high risk)
Peripheral			
Parenchymal thickness	Normal	Normal	Normal
Parenchymal appearance(echogenicity, corticomedullar differentiation, pericortical cysts, urinoma)	Normal	Normal	Normal
Ureter(s)	Normal	Normal	Normal
Bladder	Normal	Normal	Normal
Oligohydramnios	No	No	NA

TABLE 4 | Prenatal and postnatal evaluation systems used in UPJHN classification (Courtesy of Onen A, 2020, in press).

ULTRASONOGRAPHIC FINDINGS OF UPJHN IN THE PRENATAL PERIOD

The main cause of hydronephrosis is obstruction at any level of the urinary system. Some obstructive changes may develop

very early in fetal life and may cause cystic-dysplastic pathology in the fetal kidney. Therefore, the initial time of obstruction and its consequences are as important as the severity of the dilation. UPJHN is the most common reason of ANH. Other causes include vesico-ureteral reflux, uretero-vesical junction

obstruction, posterior urethral valve, and other rare incidents (1). Each is caused by different levels of obstruction and carries different ultrasonographic features. Accurate prenatal diagnosis will not only provide appropriate follow-up and prenatal interventions, but also help to prepare for the postnatal management.

The most common pathological cause of antenatal hydronephrosis UPJHN constitutes 10–30% of antenatal hydronephrosis (7). It is reported in 1/750–1/1,500 live births (17). UPJHN is three times more common in males than in females particularly in the neonatal period (18). It is usually sporadic, unilateral and mostly the left side (68%) is affected (19, 20). The etiology of uretero-pelvic junction obstruction is obscure with an adynamic narrow segment causing the obstruction (21).

Typical finding in UPJHN in prenatal ultrasound is unilateral renal pelvis dilation with or without caliectasis, while the ureter is not dilated (**Figures 3a,b, Video S1**). Bladder dimensions and bladder wall thickness are normal in UPJHN. Presence and

localization of caliectasis as central or peripheral, is important for grading systems of SFU and UTD, particularly in prenatal period. Evaluation of appearance of the parenchyma is also essential. As the pelviectasia/caliectasia advances, the parenchyma thickness decreases and echogenicity increases on the affected kidney.

Assessment of the severity of the dilation is essential for the grading systems in all cases of hydronephrosis detected in prenatal ultrasound. For example, in SFU grade 3 dilation, pelvis and peripheral calyces are dilated, but parenchymal thickness is normal (**Table 2**) (7). However, in SFU grade 4, the parenchyma gets thinner. The difference between SFU grade 1 and 2 is the presence of central calyx dilation in grade 2, independent of the measurement of pelvic dilation. Similar to the UTD system, the SFU grading system can be used both in the pediatric and in the prenatal period.

Most of the urinary system anomalies can be diagnosed by prenatal ultrasound. However, with maternal obesity, advanced gestational week or presence of oligohydramnios, visualization of the structures may be challenging. Fetal magnetic resonance

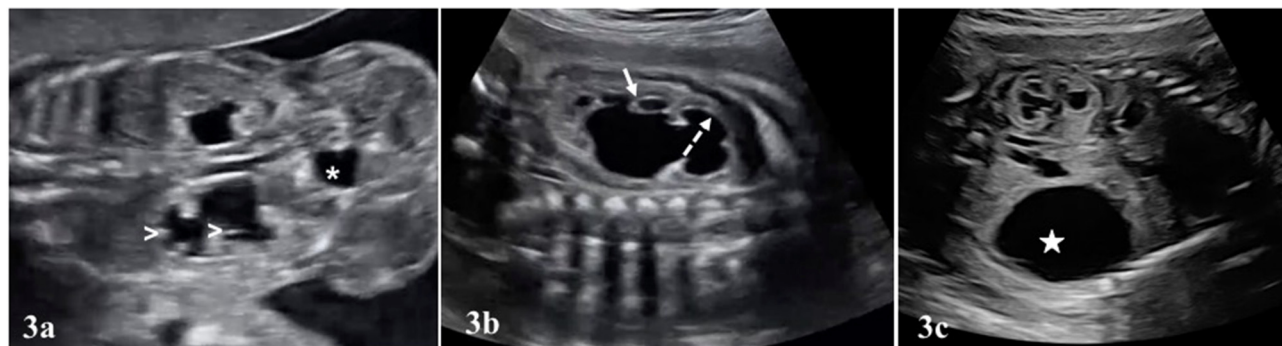


FIGURE 3 | In (a), bilateral UPJHN is seen in a fetus at 22 weeks of pregnancy. Renal pelvis dilated in both kidneys. There is also dilated calyces in the lower kidney (white arrow heads). The size and appearance of the bladder (asterisk *) is normal, and ureters are not visible. (b) Central (dashed arrow) and peripheral calyces (short arrow) in the renal pelvis are dilated. Renal parenchyma is also thinned. (c) Increased echogenicity in the renal parenchyma (upper kidney). A large urinoma (white star) was seen in the lower kidney.

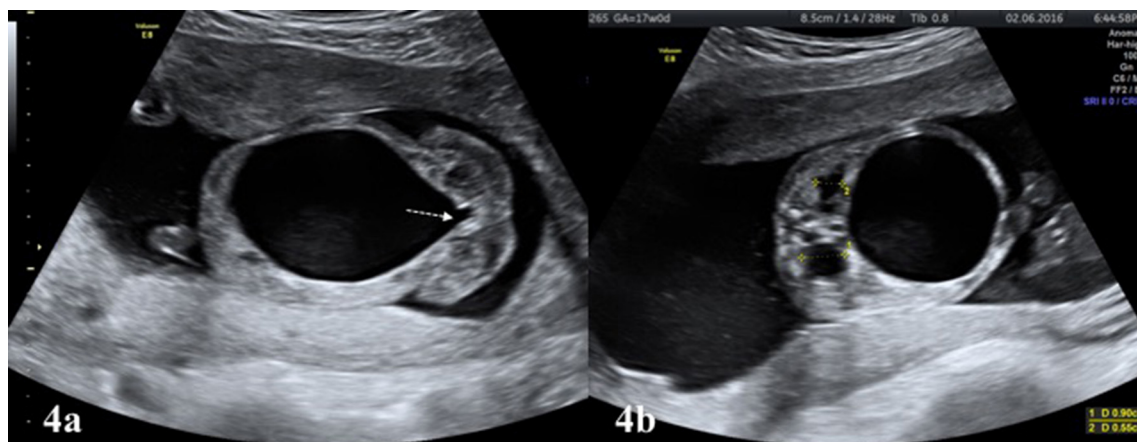


FIGURE 4 | (a) Large bladder with “key hole” appearance (white colored dashed arrow) is typical finding of infravesical obstruction, mostly due to PUV in male fetuses. (b) The affected kidneys in the same fetus (a) showing increased renal pelvis diameter and parenchymal echogenicity.

imaging (MRI) is an important adjunct to ultrasound in evaluation of fetal urogenital system. While ultrasound remains the primary diagnostic modality, MRI helps in more complicated cases or where ultrasound is limited due to technical factors such as poor acoustic window (22). Prenatal MRI may also be useful in differential diagnosis of VUR from UPJHN, particularly in positions where the fetal pelvis is difficult to visualize the ureter dilation (23). Imaging in T1-T2-weighted MRI sequences is rather guiding to evaluate the functional status of fetal kidneys (24). Kajbafzadeh et al. reported that the sensitivity of prenatal MRI in differential diagnosis of urinary system anomalies was 92% in their study (24). Particularly, MRI is informative when type of calyx dilation is difficult to distinguish in cases with prenatal UPJHN (24).

OTHER URINARY SYSTEM ULTRASOUND FINDINGS IN PRENATAL UPJHN

The excessively dilated collection system rarely ruptures spontaneously in UPJHN. As a result, an encapsulated paranephric pseudocyst (urinoma) confined to the Gerota's fascia is formed (25, 26). The urinoma is located on the affected kidney side as an elliptical or crescentic cystic mass adjacent to the kidney and vertebral column (**Figure 3c**). Similar to in UPJHN, urinoma can occur in the cases with PUV, where the intrarenal pressure can be high enough to cause rupture. PUV can be differentiated more easily with the presence of large bladder which typically looks like a key hole and coexist with bilateral hydronephrosis (**Figures 4a,b**).

Urinoma is often detected at 19–30 weeks of gestation in UPJHN. Other cystic structures such as lymphangioma, neuroblastoma and ureteric duplication, which are located in this region, should also be considered in differential diagnosis (27). Modifying the time of delivery or interventions such as shunt placement to the urinoma is not necessary in the prenatal period. Urinomas may regress spontaneously before birth, but this does not imply better prognosis. The presence of urinoma with the dysplastic changes in the kidney parenchyma is associated with a poor prognosis (25, 27). Postnatal normal kidney function in UPJHN cases affected by ipsilateral urinoma is only 7% (28, 29). Another study reported that the prognosis is more morbid in the presence of urinoma with prenatal UPJHN than other urinary tract obstructions (11).

Oligohydramnios is one of the most important prognostic parameters in evaluating kidney functions in fetal life. Single vertical pocket (SVP) or amniotic fluid index (AFI) are the most frequently used methods in the evaluation of oligohydramnios. The threshold used to define oligohydramnios is $SVP \leq 2$ cm or $AFI \leq 5$ cm. Bilateral UPJHN with dysplastic changes in kidneys and subsequent oligohydramnios indicates poor prognosis (18, 30). Since chronic oligohydramnios is associated with fetal lung hypoplasia, it affects neonatal prognosis directly.

Bilateral UPJHN is detected 10–30% in prenatal ultrasound (20) (**Figure 3a**, **Video S1**) and it is frequently detected in <6 month old infants in neonatal period (8, 20). The most diagnostic challenge is differentiation of bilateral UPJHN cases

with VUR. VUR is more common in girls, and hydronephrosis is typically presented with ureter dilation (**Video S2**). Since postnatal management of VUR cases is different from UPJHN, its differentiation in the prenatal period is also important for follow up and management.

Another factor determining the prognosis in prenatal and postnatal period is the appearance of the contralateral kidney. Additional urinary system anomalies are present in 50% of UPJHN. The most common condition which is seen in contralateral kidney is UPJHN. Among the other urinary system anomalies, multicystic dysplastic kidney (MCDK) (**Figure 5a**), VUR, duplication of the collecting system, rotation and fusion anomalies in the other kidney are reported in conjunction with UPJHN (18). The actual incidence of MCDK with UPJHN is unknown, and its frequency has been reported to range between 2 and 27% (31). Since monitoring and management changes in the presence of other kidney anomalies, the anatomy and location of the contralateral kidney should be carefully evaluated.

OTHER SYSTEM ANOMALIES CO-EXISTING WITH UPJHN IN PRENATAL ULTRASONOGRAPHY

The incidence of chromosome anomalies accompanying prenatal UPJHN obstruction is relatively low and reported around 1–3%. Karyotype analysis is not crucial in isolated cases when other parameters are favorable. However, in the presence of associated anomalies, prenatal diagnostic invasive procedures should be offered (32). Congenital heart disease, VA(C)TER(L) association, Schinzel-Giedon syndrome and Camptomelic dysplasia are among the most common other system anomalies associated with UPJHN in the prenatal period (33, 34). A comprehensive fetal anatomy scan should be carried out for other systems, particularly including fetal heart, gastrointestinal tract and spine (8, 18).

PARAMETERS DETERMINING POOR PROGNOSIS IN PRENATAL UPJHN

Prenatal management of UPJHN primarily depends on the APD, taken into account by the gestational week. Progression of the obstruction, presence of dilation in calyx system and parenchymal condition of the affected kidney guides the follow-up. Gestational age at presentation, presence of unilateral or bilateral involvement, and other coexisting anomalies are important to determine the prognosis. If there is bilateral UPJ obstruction, associated anomaly in the contra-lateral kidney and/or oligohydramnios, the prognosis will be negatively affected.

Jiang et al. reported a spontaneous regression rate of 61%, and persistence rate of 23% in cases diagnosed with antenatal bilateral UPJHN (35). Probability of postnatal surgery was 15% in cases where renal pelvis AP diameter was ≥ 15 mm (35). When calyx dilatation is ≥ 10 mm, spontaneous resolution is 37%, the possibility of persistence is 29% and the surgical requirement is around 33% (35). However, in cases where calyx dilatation

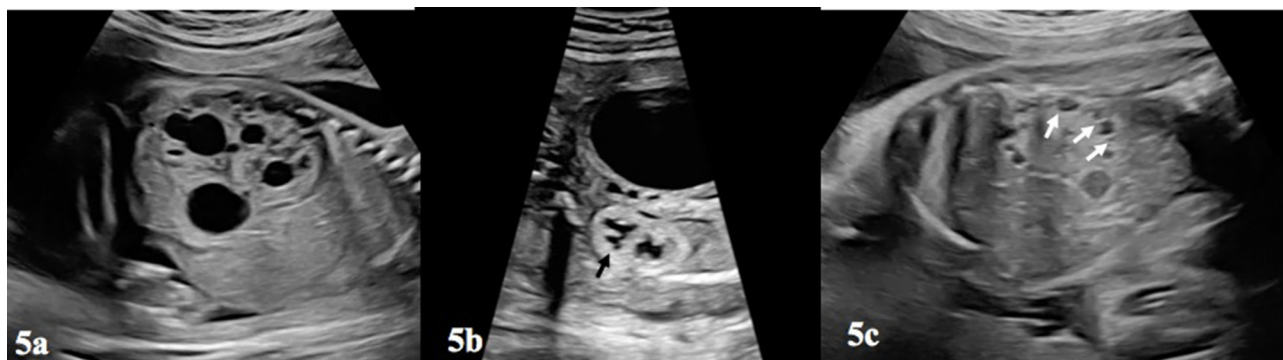


FIGURE 5 | (a) Depicts a multicystic-dysplastic kidney, which can be seen in the contralateral kidney in a fetus with prenatal UPJHN in other kidney. Notice the difference between (a,c) and **Figure 3. (b)** This figure shows increased echogenicity of the lower kidney and loss of cortico-medullary differentiation of renal parenchyma (black arrow). (c) Pericortical cysts (white arrows) and echogenic parenchyma was shown on (b).

was <5 mm and AP diameter was <10 mm, 90–100% regression was reported, and there is virtually no need for surgery (0–3.7%) (35). This study has shown that pelvic AP diameter plays a primary role along with calyx dilation in determining the follow-up process and the need for intervention. Perlman et al. analyzed the outcome of 35 fetuses diagnosed with severe isolated hydronephrosis (AP diameter >15 mm) and 48 fetuses with associated with congenital anomalies of the kidney and urinary tract (CAKUT) (10). The CAKUT group was associated with a significantly increased incidence of postnatal need for surgery (17.6 vs. 44.2%, $P = 0.014$), dysplastic kidney (0 vs. 14%, $P = 0.023$), and total abnormal outcome (52.9 vs. 86%, $P = 0.001$). A recent meta-analysis assessed the diagnostic value of APD of the fetal renal pelvis in predicting postnatal surgery. Diagnostic OR of antero-posterior diameter for predicting postnatal surgery was 13.3 mm. The authors suggested 15 mm AP diameter of APD may be used as a cut-off for the prediction of surgery (36). Elmaci et al. emphasized that spontaneous resolution rate was 71%, especially in cases with UPJHN-type antenatal hydronephrosis, where APD was ≤ 20 mm (37).

Regardless of etiology of hydronephrosis, abnormal parenchyma (thin and/or echogenic) appearance is a common parameter used in both SFU (grade 4) and UTD (high risk) classifications. The thickness and echogenicity of parenchyma affected by UPJHN is particularly important to predict renal function (**Figures 3c, 5b**). However, there is no consensus regarding the location of the assessment of parenchymal thickness prenatally. Moreover, subjective determination of parenchymal thickness may cause more conflicting results. Correlation between parenchymal thickness and prognosis is not clear even in postnatal studies (38). Nevertheless, loss of uniform structure of the renal parenchyma, presence of peri-cortical renal cysts (**Figure 5c**) and increased renal parenchymal echogenicity in prenatal ultrasound are associated with impaired renal function (**Figures 3b, 5b**) (39).

Despite all efforts, the contribution of SFU and UTD systems to prediction of prognosis in antenatal hydronephrosis is still uncertain (40). Both is proposed to be used regardless of

etiology of hydronephrosis. Several studies have shown that inter-observer reliability of UTD classification is superior to SFU classification (41, 42). The use of other urinary system ultrasound parameters (kidney echogenicity, ureter dilation, ureterocele, oligohydramnios) in UTD classification increases its reliability. Renal pelvis AP diameter is the only quantitative criteria in UTD classification. However, other studies have shown that AP diameter does not make any significant predictive impact in terms of prognosis compared to other parameters (40, 41). A comparison of UTD and SFU grading system for their ability to predict time to hydronephrosis resolution showed that cumulative resolution rate at 3 years was higher in SFU grades (43). Among 401 patients 328 (82%) had resolution in 24 ± 18 months in study population (43). The lower the grade the better the resolution in both grading systems.

PRENATAL FOLLOW-UP AND MANAGEMENT OF DELIVERY

Fetuses with UPJHN should be followed up with ultrasound at regular intervals in prenatal period. Observation of regression, stable continuation or progression should be noted. Spontaneous resolution is often associated with mild dilated renal pelvis AP diameter. Of the 80% cases of the dilation between 4 and 8 mm are resolved, whereas only $<15\%$ of the >9 mm cases are regressed in the second trimester (44). Low-risk group includes patients with mild APD with normal kidney echogenicity, normal cortico-medullary differentiation, absence of peripheral calyx dilation. Therefore, it may be appropriate to re-evaluate the low-risk cases only for a second time in the third trimester. The unfavorable prognostic findings are; severe AP dilation (≥ 7 mm before 28 week or ≥ 10 mm after), increased kidney echogenicity, parenchymal thinning, peripheral calyx dilatation, presence of oligohydramnios, abnormality in the contra-lateral kidney and presence of bilateral UPJHN. Prenatal ultrasound follow-up examination in 2 week intervals is recommended by most authors in cases with unilateral severe UPJHN, bilateral

UPJHN or contra-lateral kidney anomaly (7, 30). Other mild cases should be followed up with 4–6 week intervals until birth (1, 7, 45).

It is recommended to evaluate these cases together with pediatric urologists during the prenatal period, where possible. Multidisciplinary management of the cases will contribute positively to the postnatal outcome (46).

Several studies have shown that the timing or type of delivery does not affect the postnatal course in cases with UPJHN. Benjamin et al. investigated the impact of gestational age on urologic outcomes for the fetuses with hydronephrosis and concluded that late preterm/early term delivery resulted in worse short-term postnatal renal outcomes. They recommended delivery at 39 weeks (47). However, the cases with oligohydramnios (bilateral UPJHN or contralateral kidney anomaly) are associated with loss of renal function in the third trimester, and earlier delivery may be considered for this group, although the benefit is questionable.

CONCLUSION

Ultrasonography has the essential place in prenatal diagnosis, and has a key role in the antenatal diagnosis of kidney anomalies. Hydronephrosis is the most frequently diagnosed urinary system anomaly in the prenatal period. UPJHN is the most common pathological finding of the fetal genitourinary

system. Although it is usually unilateral and have a favorable postnatal prognosis, outcome may be poor when bilateral or when associated with severity indicators. Unfavorable prognostic factors which indicate loss of kidney function are; increase in kidney echogenicity, loss of cortico-medullary differentiation, presence of pericortical cysts, and oligohydramnios. Ultrasound follow up of the findings in the urinary system at certain intervals is important for the management of pre and postnatal period. Adaption of one of the classification systems such as UTD or SFU or AGS may contribute to the objective assessment of both prenatal and postnatal management. In the absence of obstetric risk factors such as presence of oligohydramnios, positive contribution of delivery timing to the prognosis has not been demonstrated yet.

AUTHOR CONTRIBUTIONS

RH: drafting the work and revising it. TS: providing images, drafting the work, and revising it. All authors listed on manuscript have participated in the present work.

SUPPLEMENTARY MATERIAL

The Supplementary Material for this article can be found online at: <https://www.frontiersin.org/articles/10.3389/fped.2020.00492/full#supplementary-material>

REFERENCES

1. Nguyen HT, Benson CB, Bromley B, Campbell JB, Crow J, Coleman B, et al. Multidisciplinary consensus on the classification of prenatal and postnatal urinary tract dilatation (UTD Classification system). *J Pediatr Urol.* (2014) 10:982–99. doi: 10.1016/j.jpuro.2014.10.002
2. Chiodini B, Ghassemi M, Khelif K, Ismaili K. Clinical outcome of children with antenatally diagnosed hydronephrosis. *Front Pediatr.* (2019) 7:103. doi: 10.3389/fped.2019.00103
3. Odibo AO, Marchiano D, Quinones JN, Riesch D, Egan JF, Macones GA. Mild pyelectasis: evaluating the relationship between gestational age and renal pelvic anterior-posterior diameter. *Prenat Diagn.* (2003) 23:824–7. doi: 10.1002/pd.709
4. Bronshtein M, Kushnir O, Ben-Rafael Z, Shalev E, Nebel L, Mashiah S, et al. Transvaginal sonographic measurement of fetal kidneys in the first trimester of pregnancy. *J Clin Ultrasound.* (1990) 18:299–301. doi: 10.1002/jcu.1870180413
5. Anderson N, Clautice-Engle T, Allan R, Abbott G, Wells JE. Detection of obstructive uropathy in the fetus: predictive value of sonographic measurements of renal pelvic diameter at various gestational ages. *Am J Roent.* (1995) 164:719–23. doi: 10.2214/ajr.164.3.7863901
6. Odibo AO, Raab E, Elowitz M, Merrill JD, Macones GA. Prenatal mild pyelectasis: evaluating the thresholds of renal pelvic diameter associated with normal postnatal renal function. *J Ultrasound Med.* (2004) 23:513–7. doi: 10.7863/jum.2004.23.4.513
7. Nguyen HT, Herndon CD, Cooper C, Gatti J, Kirsch A, Kokorowski P, et al. Society for urology consensus statement on the evaluation and management of antenatal hydronephrosis. *J Pediatr Urol.* (2010) 6:478–80. doi: 10.1016/j.jpuro.2010.02.005
8. Paladini D, Volpe P. *Ultrasound of Congenital Anomalies*, 2nd ed. New York, NY: CRC Press (2014). p. 307–309. doi: 10.1201/b16779
9. Leung VY, Rasalkar DD, Liu JX, Sreedhar B, Yeung CK, Chu WC. Dynamic ultrasound study on urinary bladder in infants with antenatally detected fetal hydronephrosis. *Pediatr Res.* (2010) 67:440–3. doi: 10.1203/PDR.0b013e3181d22b91
10. Perlman S, Roitman L, Lotan D, Kivilevitch Z, Pode-Shakked N, Pode-Shakked B, et al. Severe fetal hydronephrosis: the added value of associated congenital anomalies of the kidneys and urinary tract (CAKUT) in the prediction of postnatal outcome. *Prenat Diagn.* (2018) 38:179–83. doi: 10.1002/pd.5206
11. Oktar T, Salabas E, Kalelioglu I, Atar A, Ander H, Ziyilan O, et al. Fetal urinoma and prenatal hydronephrosis: how is renal function affected? *Turkish J Urol.* (2013) 39:96–100. doi: 10.5152/tud.2013.016
12. Pates JA, Dashe JS. Prenatal diagnosis and management of hydronephrosis. *Early Human Dev.* (2006) 82:3–8. doi: 10.1016/j.earlhumdev.2005.11.003
13. Ismaili K, Avni F, Martin WK, Hall M. Brussels free university perinatal nephrology study group. Long term clinical outcome of infants with mild and moderate fetal pyelectasis: validation of neonatal ultrasound as a screening tool to detect significant nephrouropathies. *J Pediatr.* (2004) 144:759–65. doi: 10.1016/j.jpeds.2004.02.035
14. Onen A. An alternative grading system to refine the criteria for severity of hydronephrosis and optimal treatment guidelines in neonates with primary UPJ-type hydronephrosis. *J Pediatr Urol.* (2007) 3:200–5. doi: 10.1016/j.jpuro.2006.08.002
15. Zhang H, Zhang L, Guo N. Validation of “urinary tract dilation” classification system: correlation between fetal hydronephrosis and postnatal urological abnormalities. *Medicine.* (2020) 99:18707. doi: 10.1097/MD.00000000000018707
16. Onen A. Grading of hydronephrosis: an ongoing challenge. *Front Pediatr.* (in press).
17. Dias CS, Silva JMP, Pereira AK, Marino VS, Silva LA, Coelho AM, et al. Diagnostic accuracy of renal pelvic dilatation for detecting surgically managed ureteropelvic junction obstruction. *J Urol.* (2013) 190:661–6. doi: 10.1016/j.juro.2013.02.014

18. Karnak I, Woo LL, Shah SN, Sirajuddin A, Kay R, Ross JH. Prenatally detected ureteropelvic junction obstruction: clinical features and associated urologic abnormalities. *Pediatr Surg Int.* (2008) 24:395–402. doi: 10.1007/s00383-008-2112-1
19. Churchill BM, Feng WC. Ureteropelvic junction anomalies: congenital UPJ problems in children. In: Gearhart JP, Rink RC, Mouriquand PDE, editors. *Pediatric Urology*. Philadelphia, PA: WB Saunders Company (2001). p. 318–46.
20. Leo CFT, Lakshmanan Y. Anomalies of the renal collecting system: ureteropelvic junction obstruction (pyelocaliectasis) and infundibular stenosis. *Clinical Ped Urol. Martin Dunitz, London.* (2002) 168:559–631. doi: 10.1097/00005392-200212000-00114
21. Babu R, Vittalraj P, Sundaram S, Shalini S. Pathological changes in ureterovesical and ureteropelvic junction obstruction explained by fetal ureter histology. *J Pediatr Urol.* (2019) 15:240e1–e7. doi: 10.1016/j.jpuro.2019.02.001
22. Faghihimehr A, Gharavi M, Mancuso M, Sreedher G. Fetal MR imaging in urogenital system anomalies. *J Matern Fetal Neonatal Med.* (2019) 32:3487–94. doi: 10.1080/14767058.2018.1465039
23. Cassart M, Massez A, Metens T, Rypens F, Lambot MA, Hall M, et al. Complementary role of MRI after sonography in assessing bilateral urinary tract anomalies in the fetus. *Am J Roent.* (2004) 182:689–95. doi: 10.2214/ajr.182.3.1820689
24. Kajbafzadeh AM, Payabvash S, Elmi A, Jamal A, Hantoshzadeh Z, Mehdizadeh M. Comparison of magnetic resonance urography with ultrasound studies in detection of fetal urogenital anomalies. *J Pediatr Urol.* (2008) 4:32–39. doi: 10.1016/j.jpuro.2007.07.005
25. Stathopoulos L, Merrot T, Chaumoitre K, Bretelle F, Michel F, Alessandrini P. Prenatal urinoma related to ureteropelvic junction obstruction: poor prognosis of affected kidney. *J Urology.* (2010) 76:190–4. doi: 10.1016/j.urol.2010.03.030
26. Kleiner B, Callen PW, Filly RA. Sonographic analysis of the fetus with ureteropelvic junction obstruction. *Am J Roent.* (1987) 148:359–63. doi: 10.2214/ajr.148.2.359
27. Ghidini A, Strobelt N, Lynch L, Berkowitz RL. Fetal urinoma: a case report and review of its clinical significance. *J Ultrasound Med.* (1994) 13:989–91. doi: 10.7863/jum.1994.13.12.989
28. Benacerraf BR, Peters CA, Mandell J. The prenatal evaluation of a non-functioning kidney in the setting of obstructive hydronephrosis. *J Clin Ultrasound.* (1991) 19:446–50. doi: 10.1002/jcu.1870190716
29. Gorincour G, Rypens F, Toivainen-Salo S, Grignon A, Lambert R, Audibert F, et al. Fetal urinoma: two new cases and a review of the literature. *Ultrasound Obstet Gynecol.* (2006) 28:848–52. doi: 10.1002/uog.2830
30. Liu DB, Armstrong WR, Maizels M. Hydronephrosis: prenatal and postnatal evaluation and management. *Clin Perinatol.* (2014) 41:661–78. doi: 10.1007/s11934-014-0430-5
31. Mathiot A, Liard A, Eurin D, Dacher JN. Prenatally detected multicystic renal dysplasia and associated anomalies of the genito-urinary tract. *J Radiol.* (2002) 83:731–5.
32. Bornstein E, Barnhard Y, Donnenfeld AE, Ferber A, Divon MY. The risk of a major trisomy in fetuses with pyelectasis: the impact of an abnormal maternal serum screen or additional sonographic markers. *Am J Obstet Gynecol.* (2007) 196:24–6. doi: 10.1016/j.ajog.2007.01.011
33. Evans JA. Urinary tract. In: Stevenson RE, Hall JG, editors. *Human Malformations and Related Anomalies*. 2nd ed. Oxford: Oxford University Press (2006). p. 1161–1190.
34. Tough H, Fujinaga T, Okuda M, Aoshi H. Schinzel-giedion syndrome. *Int J Urol.* (2001) 8:237–41. doi: 10.1046/j.1442-2042.2001.00291.x
35. Jiang D, Chen Z, Lin H, Xu M, Geng H. Predictive factors of contralateral operation after initial pyeloplasty in children with antenatally detected bilateral hydronephrosis due to ureteropelvic junction obstruction. *J Urol Int.* (2018) 100:322–26. doi: 10.1159/000487196
36. Zhang L, Li Y, Liu C, Li X, Sun H. Diagnostic value of anteroposterior diameter of renal pelvis for predicting postnatal surgery: a systematic review and meta-analysis. *J Urol.* (2018) 200:1346–53. doi: 10.1016/j.juro.2018.06.064
37. Elmaci MA, Donmez MI. Time to resolution of isolated antenatal hydronephrosis with anteroposterior diameter ≤ 20 mm. *Eur J Ped.* (2019) 178:823–8. doi: 10.1007/s00431-019-03359-y
38. Arora S, Yadav P, Kumar M, Singh SK, Sureka SK, Mittal V, et al. Predictors for need of surgery in antenatally detected hydronephrosis due to UPJ obstruction – A prospective multivariate analysis. *J Ped Urol.* (2015) 11:248e1–e5. doi: 10.1016/j.jpuro.2015.02.008
39. Chi T, Feldstein VA, Nguyen HT. Increased echogenicity as a predictor of poor renal function in children with grade 3 to 4 hydronephrosis. *J Urol.* (2006) 175:1898–901. doi: 10.1016/S0022-5347(05)00930-4
40. Chalmers DJ, Meyers ML, Brodie KE, Palmer C, Campbell JB. Inter-rater reliability of the APD, SFU and UTD grading systems in fetal sonography and MRI. *J Pediatr Urol.* (2016) 12:305e1–5. doi: 10.1016/j.jpuro.2016.06.012
41. Han M, Kim HG, Lee JD, Park SY, Sur YK. Conversation and reliability of two urological systems in infants: the society for fetal urology and the urinary tract dilatation classification system. *Pediatr Radiol.* (2017) 47:65–73. doi: 10.1007/s00247-016-3721-9
42. Nelson CP, Heller HT, Benson CB, Asch EH, Durfee SM, Logvinenko T, et al. Interobserver reliability of the antenatal consensus classification system for urinary tract dilatation. *J Ultrasound Med.* (2019) 39:551–57. doi: 10.1002/jum.15133
43. Braga LH, McGrath M, Farrokhyar F, Jegatheeswaran K, Lorenzo AJ. Society for fetal urology classification vs urinary tract dilation grading system for prognostication in prenatal hydronephrosis: a time to resolution analysis. *J Urol.* (2018) 199:1615–21. doi: 10.1016/j.juro.2017.11.077
44. Feldman DM, DeCambre M, Kong E, Borgida A, Jamil M, McKenna P, et al. Evaluation and follow-up of fetal hydronephrosis. *J Ultrasound Med.* (2001) 20:1065–9. doi: 10.7863/jum.2001.20.10.1065
45. Zanetta VC, Rosman BM, Bromley B, Shipp TD, Chow JS, Campbell JB, et al. Variation in management of mild prenatal hydronephrosis among maternal-fetal medicine obstetricians, and pediatric urologists, and radiologists. *J Urol.* (2012) 188:1935–9. doi: 10.1016/j.juro.2012.07.011
46. Gong Y, Xu H, Li Y, Zhou Y, Zhang M, Shen Q, et al. Exploration of postnatal integrated management for prenatal renal and urinary tract anomalies in China. *J Matern Fetal Neonatal Med.* (2019) 29:1–6. doi: 10.1080/14767058.2019.1608176
47. Benjamin T, Amodeo RR, Patil AS, Robinson BK. The impact of gestational age at delivery on urologic outcomes for the fetus with hydronephrosis. *Fetal Pediatr Pathol.* (2016) 35:359–68. doi: 10.1080/15513815.2016.1202361

Conflict of Interest: The authors declare that the research was conducted in the absence of any commercial or financial relationships that could be construed as a potential conflict of interest.

Copyright © 2020 Has and Sarac Sivriköz. This is an open-access article distributed under the terms of the Creative Commons Attribution License (CC BY). The use, distribution or reproduction in other forums is permitted, provided the original author(s) and the copyright owner(s) are credited and that the original publication in this journal is cited, in accordance with accepted academic practice. No use, distribution or reproduction is permitted which does not comply with these terms.



Urinary Ultrasound and Other Imaging for Ureteropelvic Junction Type Hydronephrosis (UPJHN)

Ayşe Kalyoncu Ucar^{1*} and Sebuğ Kurugöglü²

¹ Istanbul Kanuni Sultan Süleyman Training and Research Hospital, Istanbul, Turkey, ² Istanbul University Cerrahpaşa Faculty of Medicine, Istanbul, Turkey

OPEN ACCESS

Edited by:

Abdurrahman Onen,
Onen Pediatric Urology Center, Turkey

Reviewed by:

Andres Gomez Fraile,
University Hospital October 12, Spain
Huixia Zhou,
Bayi Children's Hospital, China

*Correspondence:

Ayşe Kalyoncu Ucar
aysekucar@gmail.com

Specialty section:

This article was submitted to
Pediatric Urology,
a section of the journal
Frontiers in Pediatrics

Received: 16 May 2020

Accepted: 29 July 2020

Published: 16 September 2020

Citation:

Ucar AK and Kurugöglü S (2020)
Urinary Ultrasound and Other Imaging
for Ureteropelvic Junction Type
Hydronephrosis (UPJHN).
Front. Pediatr. 8:546.
doi: 10.3389/fped.2020.00546

Ultrasound is the main imaging study used to diagnose ureteropelvic junction (UPJ) obstruction. On ultrasound, abnormal dilatation of the pelvicalyceal system of varying degrees is seen, whereas the ureter is normal in caliber. A properly performed study provides essential information regarding laterality, renal size, thickness, and architecture of the renal cortex and degree of dilatation of the pelvicalyceal system. Doppler ultrasound may identify a crossing vessel, when present. This imaging method also has been used differentiating obstructive from non-obstructive hydronephrosis by renal arterial resistive index measurements. Abdominal radiographs may show soft tissue fullness, bulging of the flank, and displacement of bowel loops from the affected side. The voiding/micturating cystourethrogram helps exclude other causes of upper tract dilatation, including vesicoureteral reflux, urethral valves, and ureteroceles. Computerized Tomography angiography with multiplanar reformation and three-dimensional images may be used to depict suspected crossing vessels as a cause of UPJ obstruction in older children and adults. Magnetic Resonance Urography has progressed significantly in recent years due to the development of both hardware and software that are used to generate high-resolution images. This imaging technique currently allows for the detailed assessment of urinary tract anatomy, while also providing information regarding renal function, including differential renal function, and the presence or absence of obstructive uropathy.

Keywords: child, UPJ type hydronephrosis, ultrasonography, CT angiography, MR urography

INTRODUCTION

Ureteropelvic junction (UPJ) obstruction is the most common cause of pathologic obstructive hydronephrosis in children which is defined as a partial or complete obstruction of the flow of urine from the renal pelvis to the proximal ureter (1, 2). Many theories have been put forward to explain the pathophysiology; however, the cause is not clear. As an intrinsic cause of obstruction abnormally developed ureteral smooth muscle at the UPJ resulting in an aperistaltic segment is considered, while extrinsic obstruction is thought to be caused by an overlying renal vessel (3, 4). UPJ obstruction might lead to progressive damage to the renal function by increasing back pressure on the kidney (5). But the majority of cases resolve spontaneously without a real obstruction and renal damage. Especially in newborns and infants, hydronephrosis develops as a useful adaptation mechanism that protects the kidney from high pressure and damage secondary to the good

compliance of the renal pelvis, not as a result of obstruction (6). Therefore, the differentiation of true obstruction from urinary tract dilatation is crucial to avoid unnecessary surgical intervention. All efforts are made to recognize which cases to follow and which ones to treat. Imaging methods play an important and crucial role at this point.

The purpose of this review is to discuss the radiological findings of hydronephrosis related to UPJ obstruction under the title of “ureteropelvic junction type hydronephrosis (UPJHN),” based mainly on ultrasonography and other imaging methods.

ULTRASONOGRAPHY

Ultrasonography (US) is the main imaging study used for evaluating the urinary system in the postnatal period in children with suspected or diagnosed prenatal hydronephrosis (7). This method has lots of advantages such as being safe and non-invasive, cheap, easily accessible in most institutions and also being repeatable with using no radiation exposure. The widespread use of antenatal US screening leads to a significant increase in the detection rate of UPJHN (8). All newborns

with a history of antenatal hydronephrosis should be evaluated by US in postnatal period (9). If US is performed in the first postnatal days, mild hydronephrosis may not be detected or the degree of hydronephrosis may appear milder than the fact due to transient dehydration as a result of physiological oliguria in the early postnatal period and subsequent polyuria. Therefore, it is more appropriate to perform the first urinary US examination usually after first week of birth (10, 11). However, in cases of bilateral hydronephrosis, severe hydronephrosis in a solitary kidney, elevated creatinine levels, urinary tract infection, suspected perforation, or posterior urethral valve, early neonatal US may require urgency. If postnatal US is normal, it should be repeated after 4–6 weeks (9). For instance, data in a study shows that 5% of patients requiring surgery for obstructive uropathies had abnormal US findings at 1 month of age despite normal US findings at 1 week of age (12).

A variety of (multifrequency) transducers are used in the evaluation of pediatric urinary tract. For standard pediatric exams, both use of convex probes ranging from 2.5 to 10 MHz and linear probes ranging from 5 to 17 MHz are advisable. High-frequency, high-resolution linear probes are necessary for evaluating details or for assessing neonatal patients. Each

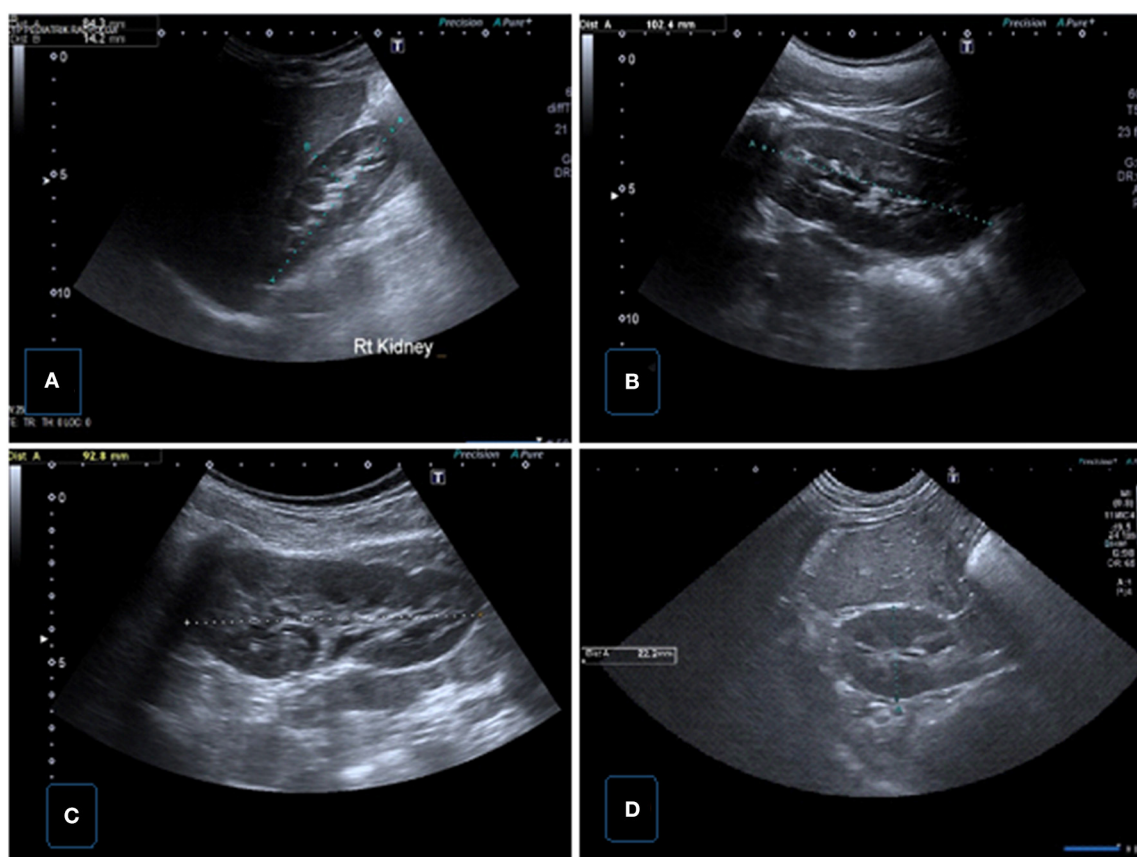


FIGURE 1 | Normal renal sonographic images obtained with convex probes. **(A)** Longitudinal US image of the right kidney demonstrating renal length and parenchymal thickness in supine position. **(B)** Longitudinal US image of the left kidney demonstrating renal length in supine position. **(C)** Longitudinal US image of the left kidney demonstrating renal length in prone position. **(D)** Transverse US image of the right kidney showing renal AP size.

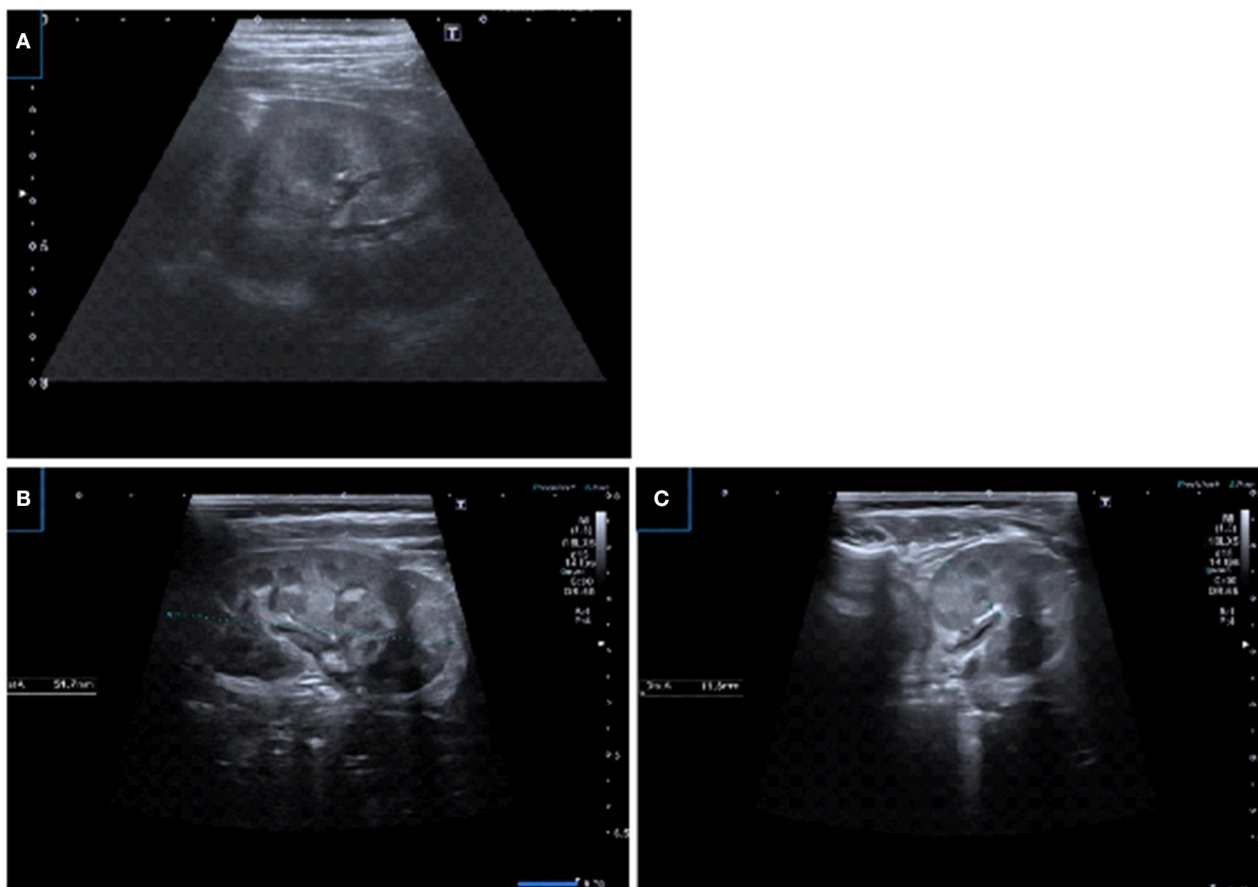


FIGURE 2 | US images using linear transducers. **(A)** Transverse US image demonstrating corticomedullary differentiation in prone position and detailed visualization of the parenchyma. **(B,C)** Renal longitudinal and transverse US images in prone position demonstrating physiologic medullary echogeneity with corticomedullary differentiation and uroepithelial thickening in pelvis.

kidney should be assessed both in transverse and longitudinal planes. In addition to supine and decubitus positions, prone position reduces the distance to the kidneys, increases image quality, provides better image quality, and enables the medullary structure to be better evaluated (13).

In the presence of UPJHN, US demonstrates multiple dilated calyces of uniform size which communicate with a dilated renal pelvis and abrupt narrowing at the level of the UPJ whereas the ureter is normal in caliber (14). Dilatation may vary depending on position, hydration, fullness of bladder, and kidney function. In the setting of dilatation, the patient should be reexamined after emptying bladder in order to assess the exact severity of dilatation. Since the position of the patient is one of the factors affecting hydronephrosis evaluation, the same position should be used for each follow-up measurement to make accurate comparisons (15).

In addition to ensuring an accurate determination of hydronephrosis, sonographic evaluation has an important role in determining the timing and necessity of other examinations. Since most unnecessary nuclear imaging

and voiding cystourethrography examinations are mainly caused by inadequate or inaccurate information in US reports, a detailed and well-performed US can minimize unnecessary invasive tests that seriously concern children and their parents.

US examination provides essential information regarding laterality, kidney size, appearance (such as echogenicity, corticomedullary differentiation, cyst), parenchymal thickness, presence of pelvicalyceal dilatation (**Figure 1**) (7, 13, 16, 17). High frequency linear transducers maximize the sonographic resolution of the kidney enabling better evaluation of the medulla and cortex (**Figure 2**) (13). US also gives important information about contralateral kidney, ureter, and bladder. Due to the increased incidence of other congenital abnormalities of the urinary tract in patients with UPJ obstruction such as vesicoureteral reflux, renal duplication, ureterovesical obstruction, and bilateral UPJ obstruction (10%) (5, 18), a properly performed study should include all the necessary data. However, this is directly correlated to the practitioners training and experience.

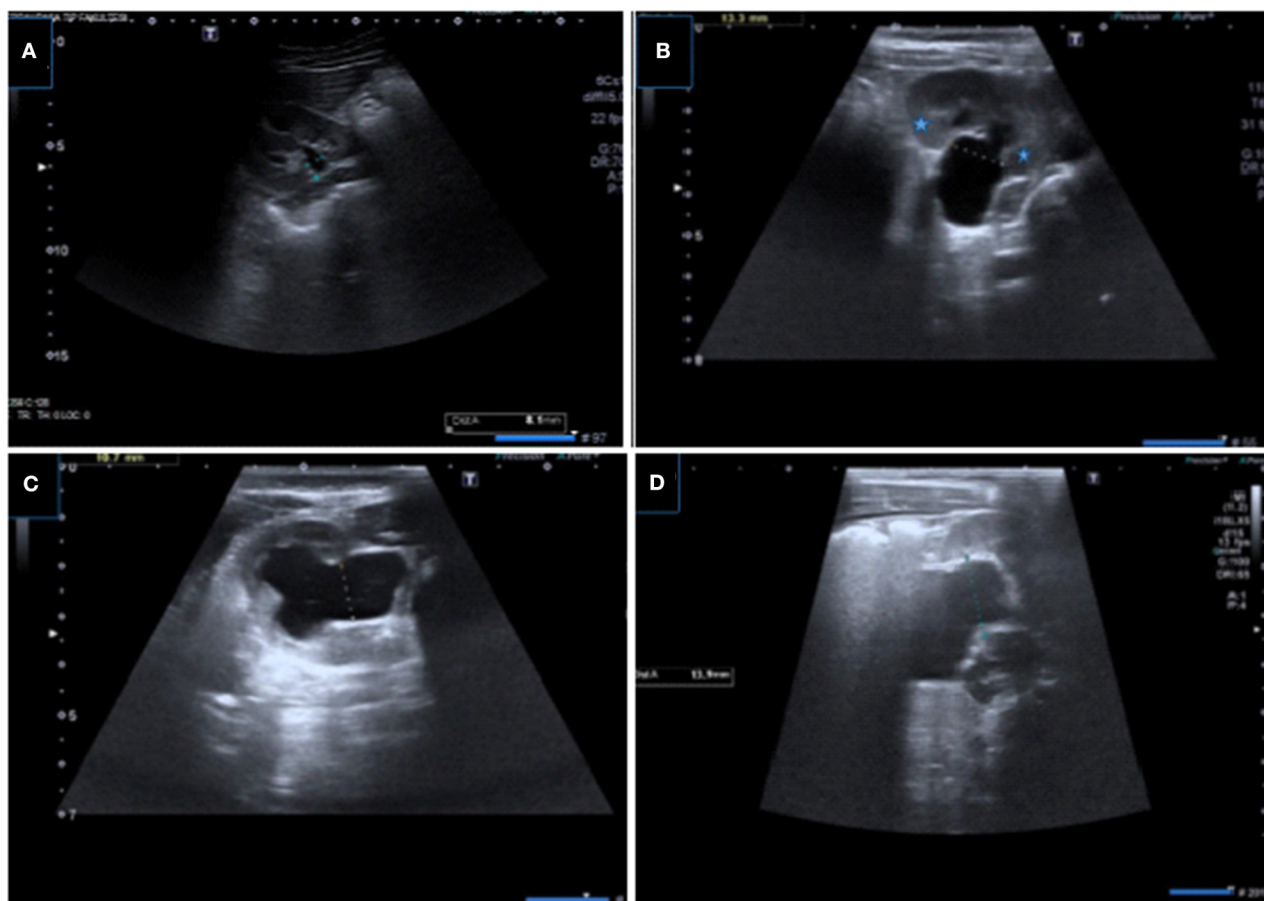


FIGURE 3 | Renal US images showing measurement of APRPD with different grades of hydronephrosis. (A–D) Samples of optimal APRPD measurements obtained within the confines of the renal cortex in transverse plane.

US examination is important to determine the exact level and severity of obstruction in patients with UPJHN, the appropriate treatment, and follow-up decision. This imaging method should be performed periodically at varying intervals according to the severity of hydronephrosis. The primary aim of treatment is to prevent or minimize renal damage and loss of function. In order to ensure the right decision regarding the necessity of surgery and follow-up, some measurements and grading systems have been developed (19–22). The most commonly approved sonographic measurement systems to assess hydronephrosis are the antero-posterior renal pelvic diameter (APRPD), the Society for Fetal Urology (SFU) grading system, the Urinary Tract Dilation (UTD) system, and the Onen classification.

ANTERIO-POSTERIOR RENAL PELVIC DIAMETER

Antero-posterior renal pelvic diameter (APRPD) is a quantitative parameter based on the measurement of the greatest diameter on US images acquired in a transverse plane

in order to assess the degree of dilatation of the renal pelvis (Figure 3) (22, 23). Monitoring the degree of pelvic dilatation is an important aspect of follow-up in UPJHN. Measurement of APRPD is commonly used as a comparable and sensitive parameter. But this measurement is not fully standardized among radiologists. The most common mistake is to measure the pelvis in longitudinal plane or from the widest extrarenal level (Figure 4). Even if the APRPD measurement is performed optimally, it may vary depending on the hydration status, the bladder being full/empty and the position where it is measured (supine or prone). Hydration can increase renal pelvic dilatation by causing fluctuation in bladder volume and an increase in fluid excretion (24, 25). Although there is no standard renal sonogram protocol regarding hydration status in the evaluation of pediatric hydronephrosis, the effect of hydration on the diameter of the pelvis has been well-documented (25). Hasch (26) recommended a fasting US scan in order to exclude a persistent hydronephrosis, as well as a reassessment after fluid intake so as not to overlook a case of intermittent hydronephrosis. However, performing this method on infants and younger children is not a simple task.

The accurate measurement of APRPD can be affected by patient position. According to Sharma et. al's study in many

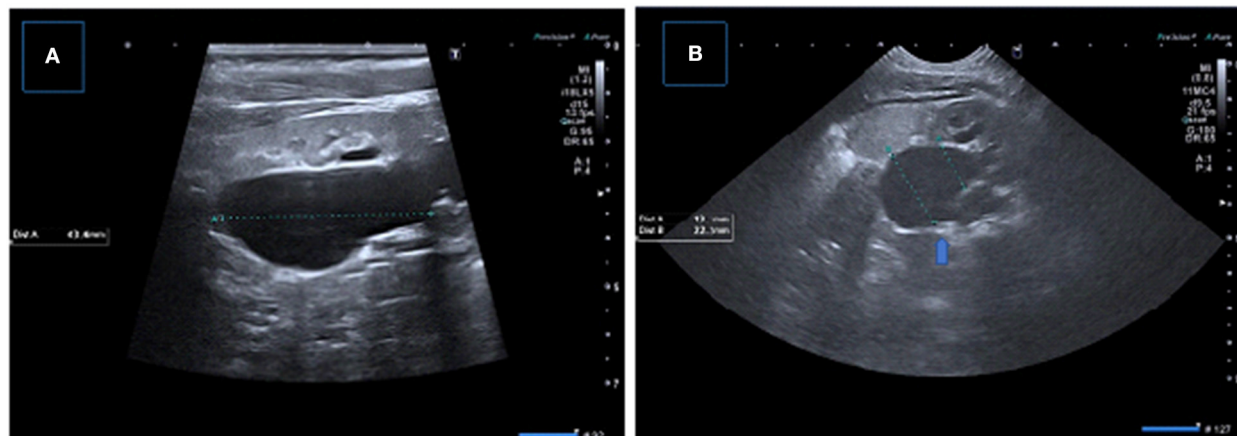


FIGURE 4 | Incorrect measurement of APRPD in longitudinal (A) and transverse (B) US images showing incorrect measurement at extrarenal level (arrow), correct measurement level is also shown.

cases the APRPD decreases when measured in the prone position (15). US done in the prone and supine positions can also help to differentiate non-obstructive dilatation from obstructive dilatation. While a non-obstructive dilated pelvis can drain better in the prone position, obstructive systems cannot. The measurement of APRPD in the supine and prone positions does not change in the setting of obstruction (15).

Besides the disadvantage of the dynamic nature of APRPD, it is not sufficient alone as it does not provide information about the presence of abnormal renal morphology, parenchymal integrity, or tension in the calices (27).

In some cases, there may be a serious difference between the measurement of APRPD and the actual degree of hydronephrosis, deeming it essential to indicate whether the pelvis is extrarenal or intrarenal, as the kidneys with extrarenal pelvis have lower parenchymal damage by keeping the pressure low for longer. If APRPD is measured from the extrarenal level, it may be perceived as having a more severe obstruction than in actuality (28–30). Therefore, measurement should be procured within the confines of the renal cortex in transverse plane. If the pelvis is located intrarenal, the maximum calyx diameter measurement becomes important in addition to the measurement of APRPD in patients with hydronephrosis. According to a recent study combining the presence of diffuse calyceal dilatation with standard APRPD grading, the first postnatal US provides more information for clinical management and improves the predictive probability of surgery (31). It is also reported in another study that pelvic dilatation with calyceal dilatation may be associated with worse postnatal outcomes than pelvic dilatation without calyceal dilation (32).

APRPD measurement has also a predictive importance in determining whether renal function loss occurs. Previous studies in neonates revealed that an APRPD of >6 mm implies obstruction, while a diameter >15 mm is highly accurate in distinguishing infants with severe uropathy (sensitivity and specificity, $>90\%$) (33–36).

Dias et al. reported that combination of prenatal and postnatal APRPD, with cutoffs of 16 and 18 mm, respectively, was 100% sensitive and 86% specific for predicting surgical intervention for UPJ obstruction (33). Burgu et al. found that an APRPD of <20 mm correlated with the persistence of differential renal function. Stable or decreased APRPD on serial US examinations has predictive value to retained or improved function, postnatally (36). In Coplen's study, 15 mm threshold was used, with a 73% sensitivity and 82% specificity for predicting urological obstruction (37). In Sharifian et al.'s study the best APRPD cutoff to predict surgery was 15 mm (38). Dhillon et al. concluded that in the setting of preserved differential renal function ($>40\%$), all patients in their study ($n = 36$) had APRPD of ≥ 40 mm and experienced renal deterioration requiring surgical intervention while no patients with renal pelvic diameters of <15 mm progressed to surgery (30).

SOCIETY FOR FETAL UROLOGY (SFU) GRADING SYSTEM

The SFU classification system was developed to replace the traditional grading system, which uses the subjective descriptors “mild,” “moderate,” and “severe.” The SFU grading system is the most widely used grading system in assessment of hydronephrosis in the postnatal period (27).

The SFU grading system is a qualitative assessment of hydronephrosis in determining the degree of dilatation which describes the degree of hydronephrosis according to renal pelvic dilatation, calyceal dilatation, and the presence of cortical thinning. It is classified as grade 0 = no hydronephrosis, grade 1 = only visualized renal pelvis, grade 2 = dilatation of a few but not all calyces, grade 3 = dilatation of virtually all calyces, and grade 4 = dilatation of the renal pelvis and calyces in addition to parenchymal thinning (19). According to the SFU system the status of the calices is more important than the size of renal pelvis.

Although the SFU is a useful system, it can be influenced by the practitioner.

Some studies have demonstrated that the severity of hydronephrosis in the SFU grading system correlate with postnatal outcomes. Hydronephrosis with high SFU grades exhibit various features that result in a less predictable prognosis, whereas hydronephrosis with low SFU grades show good prognosis and resolve spontaneously (39). For example, Ross et al.'s study examined neonatally diagnosed patients with grade 3 or 4 hydronephrosis, who were followed up with serial diuretic renography. The study deduced that patients with grade 4 hydronephrosis were more susceptible to having impaired renal function or decreased drainage relative to patients with grade 3 hydronephrosis, making the former more likely to require surgical intervention (40).

SFU grading system has limitations such as being qualitative and subjective; the system is unable to consistently discern diffuse and segmental parenchymal thinning, and the difference between grade 3 and 4 disease remains unclear (41). Similarly, two separate cases that should have different management are defined in the same grade (SFU-4): hydronephrosis with a slightly thinned parenchyma, and a slightly reduced function with hydronephrosis with severely thinned parenchyma and a very severe loss of renal function. To address this shortfall, Sibai et al. (31) suggested the subcategorization of SFU grade 4 as two groups: segmental cortical thinning (grade 4A) and diffuse cortical thinning (grade 4B) (42). In the literature there are also some studies combining the SFU with APRPD (31, 43, 44). Dos Santos et al. proposed a grading system conjoining SFU and APRPD quartiles of <6, 6–9, 9–15, and >15 mm. They additionally included the presence of diffuse caliectasis as a factor in grading (31). In another study, Longpre et al. offered that grade 4 hydronephrosis and a starting APRPD >29 mm holds predictive value for surgical intervention (44).

UTD CLASSIFICATION

Established in 2014, the Urinary tract dilation (UTD) classification system is a system developed by representatives from societies which specialize in the diagnosing and treatment of fetuses and children with hydronephrosis. The corresponding eight societies comprise the following: American College of Radiology, American Society of Pediatric Nephrology, Society for Fetal Urology, American Institute of Ultrasound in Medicine, Society for Maternal-Fetal Medicine, Society for Pediatric Radiology, Society for Pediatric Urology, and Society of Radiologists in Ultrasound (20).

The UTD classification system describes the urinary system with the use of six US findings: (1) APRPD, (2) calyceal dilation with distinction between central and peripheral calyces postnatally (central calyces in place of major calyces and peripheral calyces in place of minor calyces), (3) thickness of renal parenchyma, (4) appearance of renal parenchyma, (5) bladder abnormalities, and (6) ureteral abnormalities (20).

While there are only three antenatal subclassifications (normal, UTD A1, UTD A2–3), four subclassifications are

defined in the postnatal period (normal, low risk (UTD P1); intermediate risk (UTD P2); and high-risk (UTD P3) (45).

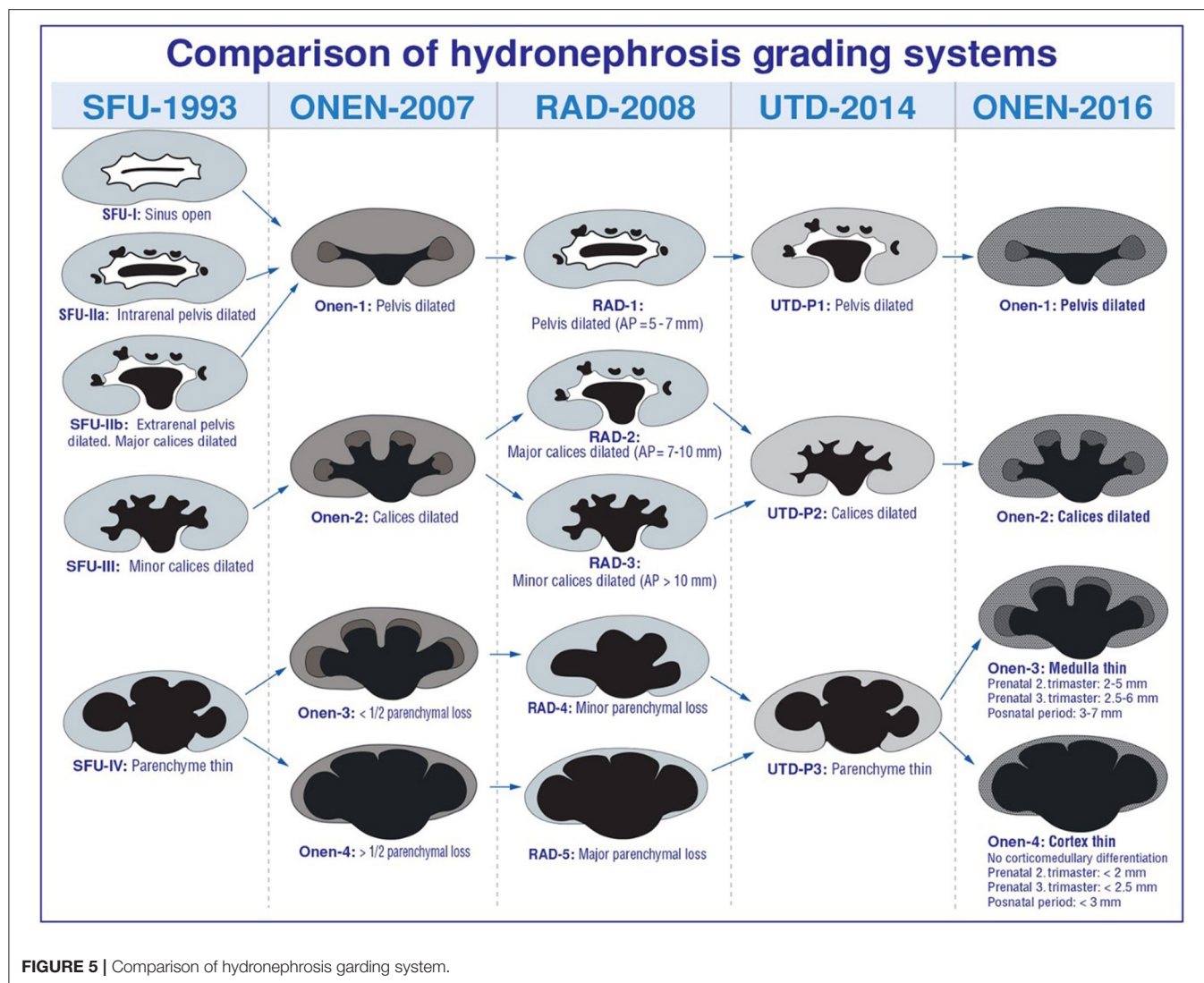
The criteria of the postnatal classification are made regardless of the child's age. According to this classification system a normal kidney has an APRPD of <10 mm and should have no calyceal or ureteral dilation. If the APRPD measurement is between 10 and 15 mm or has central calyceal dilation, the urinary tract is classified as UTD P1. If the APRPD is >15 mm or peripheral calyces are dilated, it is classified as UTD P2. Classification is based on the most concerning US finding, if there is ureteral dilation with APRPD >10 mm it is evaluated as UTD P2. Accompanying with urinary tract dilation of either the renal parenchymal echogenicity, thickness or bladder is abnormal, it is upgraded to UTD P3 (45).

This classification system can be used in prenatal and postnatal evaluation with some advantages over SFU, since it also provides information about ureter and bladder. However, if the cause of hydronephrosis is only due to UPJ obstruction it is not advantageous to include these two parameters, and mentions of superiority would be unsubstantial. Its complicated nature is also a disadvantage for routine clinical practice.

ONEN CLASSIFICATION

In 2006, Onen proposed an alternative grading system by modifying the SFU grading system to display better the severity of dilatation and to enable easier follow-up in the prenatal and postnatal period evaluations. The system maintains that APRPD is affected by various factors and parenchymal thickness is a more important criterion and relies on the appearance of hydronephrotic kidney, the thickness of renal parenchyma, and the presence of caliceal dilatation. Regardless of the APRPD, severity of hydronephrosis is defined by the degree of caliceal dilatation and of renal parenchymal loss. Grade 1 represents pelvic dilatation alone, Grade 2 with calyceal dilation, Grade 3 with <50% loss of the renal parenchyma, and Grade 4 with severe loss of renal parenchyma (21). While the Onen grade 1 is a combination of SFU grades 1 and 2, SFU grade 4 is divided into two grades (<50% renal parenchymal loss as Onen grade 3; more than 50% renal parenchymal loss as Onen grade 4) (21, 46). The system has been upgraded. Findings such as the absence of corticomedullary differentiation, cortical parenchyma <3 mm, the loss of medullary parenchyma, and significant hyperechogenicity have also been defined AGS grade 4 (47). In our opinion these parenchymal details contribute significantly in the assessment of UPJ obstruction cases.

In addition to these classification systems, alternative several sonographic parameters have been proposed to assess the severity of the hydronephrosis such as pelvicalyceal area (48), parenchymal to pelvicalyceal area (hydronephrosis index) (49), calyx to parenchymal ratio (50), and pelvicalyceal volume using three dimensional (3D) US (51). These methods are more complicated to perform, necessitate specialized software, therefore they are not commonly utilized in routine clinical practice.



In the literature, many studies comparing these classification systems reported different results with some superiorities and predictive values for surgery (46, 52, 53). There is no definitive standardized imaging algorithm, classification systems, or consensus in terms of necessity of surgical intervention and follow-up (Figure 5). As a result, the current approach is mostly based on a physician's or institutional individual's practice. The decision for surgery is determined based mainly on the severity of hydronephrosis on US, impairment of kidney function in renal scintigraphy, unilaterality, or bilaterality of hydronephrosis and the presence of clinical symptoms including pain, infection, and renal stones (5, 21, 28, 53, 54). US is used as a primary diagnostic tool during follow up of hydronephrosis (7, 13, 17, 55). It is very important to accurately determine whether there is an increase in hydronephrosis on US. Hafez et al. showed the importance of US examination in the follow up of hydronephrosis patients (55). Worsening of hydronephrosis on two successive US scans is considered an indication for the necessity of surgery as it suggests deterioration in renal

functions (Figure 6) (54–56). In addition to worsening of hydronephrosis on follow-up US, it is very important to identify the findings that may develop secondary to urinary stasis such as infection or stone development (Figure 7). As management decisions are made based upon consecutive examinations, we suggest US scans be performed by the same practitioners with the same US device, under standardized circumstances and protocols.

In our institution according to the age and consciousness of the child we perform US examination with the bladder full and then emptied. By means of urinary US, drawing from the previous classification systems mentioned above, instead of using classification systems we report all the US measurements and findings of the patient's urinary tract such as; renal size (craniocaudal and axial), location of pelvis (intrarenal or extrarenal), APRPD, calyceal dilatation (central or peripheral), parenchymal thickness, the condition of the renal parenchyma (echogenicity of cortex and medulla, medullary compression, existence of cyst), ureter (caliber, peristalsis,

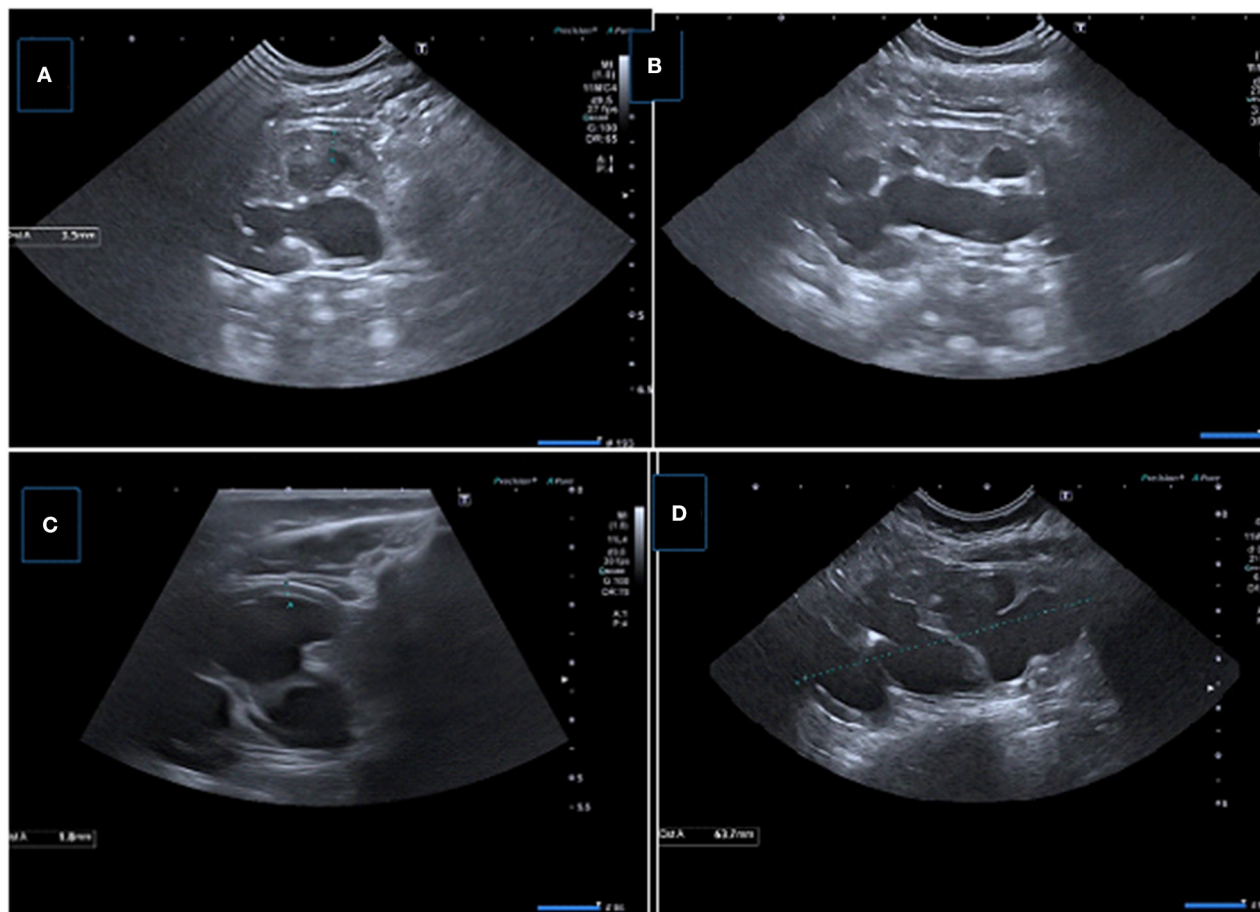


FIGURE 6 | Two consecutive US examinations in a 6-month-old girl with UPJ obstruction. **(A,B)** Baseline US images demonstrate decreased parenchymal thickness with pelvicalyceal dilatation. **(C,D)** Control (2 months later) US images showing significant decrease in renal parenchymal thickness with worsening pelvicalyceal dilatation. A new small echogenic focus suggesting microlithiasis is also present.

lateralization of the ureterovesical junction, ureteric jet), bladder (capacity, luminal echogenicity, and wall thickness), status of constipation, and possible accompanying urinary malformations. In a pediatric nephrourology council consisting of pediatric nephrologists, pediatric urologists, pediatric radiologists, and nuclear medicine specialists, we discuss the children with all the data collected from the radiologic (prenatal, postnatal, and follow-up), and scintigraphic examinations, paying special attention to the patient's clinical status. A decision is then made for either surgical intervention or follow-up.

DOPPLER ULTRASONOGRAPHY

Color doppler US may identify a crossing vessel, when present. The UPJ obstruction due to crossing vessel is one of the extrinsic causes of obstruction that occurs at higher ages than intrinsic causes (3). These vessels usually supply the lower pole of the kidney and most of the time originate from the renal artery or

the aorta. Since its treatment is surgical, it is important to detect the presence of a crossing vessel.

Color doppler US might also allow to differentiate a dilated pelvicalyceal system from prominent vessels in the hilum of kidney. Furthermore, assessment of ureteric jets in the bladder can be used to differentiate obstructive causes of hydronephrosis from non-obstructive ones in children. In the presence of obstructive hydronephrosis, the frequency of ureteric jets on the affected side may be greatly reduced when compare with the contralateral normal side (57, 58).

Traditional US does not provide functional data about obstruction. With the use of pulsed doppler, obstructive hydronephrosis can be distinguished from non-obstructive hydronephrosis by renal arterial resistive index (RI) measurements (59, 60). RI is described as the peak systolic velocity minus the lowest diastolic velocity divided by the peak systolic velocity. Because of vasoconstriction caused by renin, angiotensin, and other hormones, diastolic arterial flow velocities are decreased and RI values are elevated in patients with obstructive hydronephrosis (61). A RI of >0.7

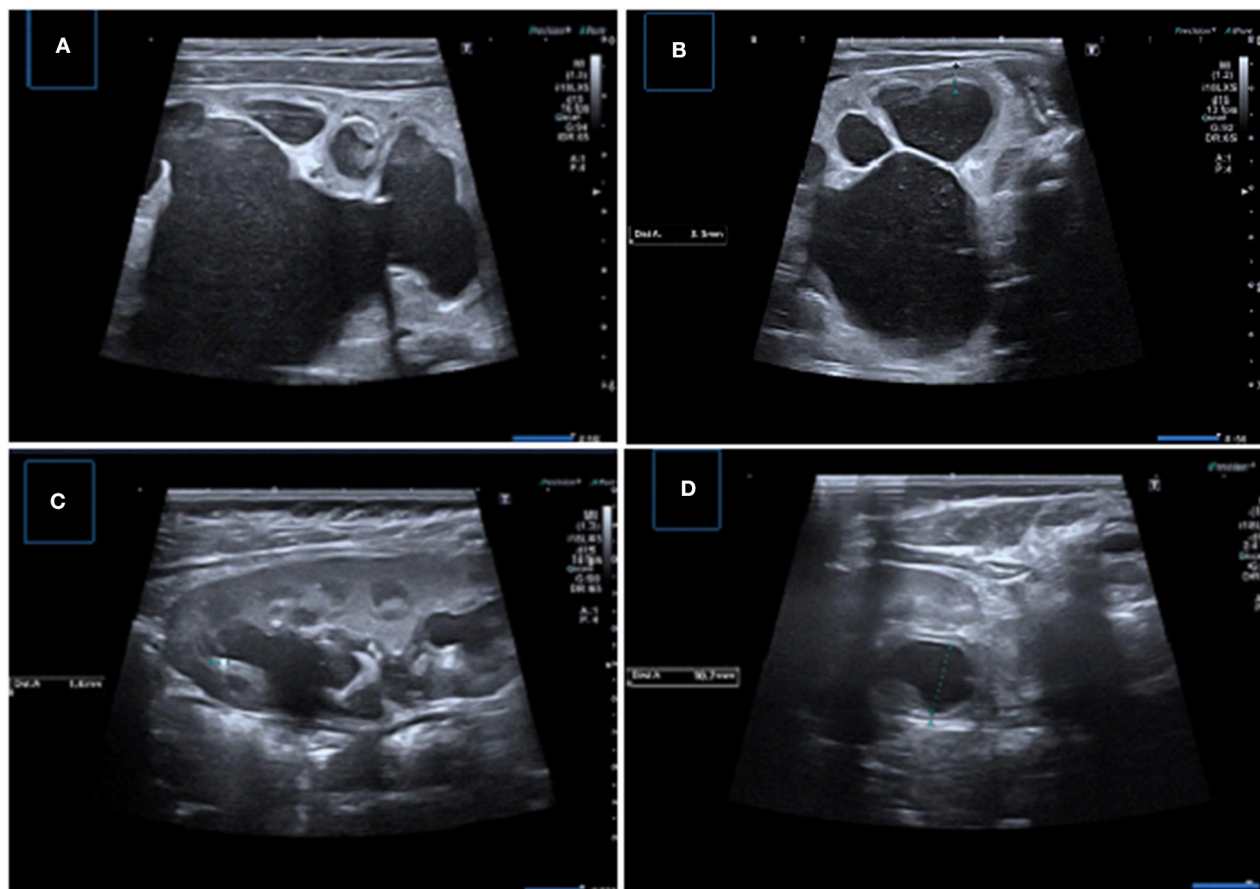


FIGURE 7 | Samples of important US findings in giving surgical decision. **(A,B)** Longitudinal and transverse US images of the left kidney demonstrating severe pelvicalyceal dilatation with serious parenchymal thinning, medullary compression, and echogeneity and luminal debris suggesting infection and/or cristallury. **(C)** Longitudinal US image showing pelvicalyceal dilatation with the presence of micro calculi, **(D)** Transverse US image showing uroepithelial thickening and layering of low-level debris consistent with pyonephrosis.

and a RI difference of >0.08 between kidneys in children are suggestive of renal obstruction, while a RI of <0.70 generally indicates non-obstructive dilation (59). An elevated RI is not a characteristic finding for obstruction, the value could be >0.70 without obstruction, in patients with renal parenchymal diseases. It should also be remembered that RI values may be higher than that of adults during the newborn and infant period (0.70–1.0). Furthermore, hypotension, a low heart rate, and dehydration can alter the RI values. Nevertheless, a normal RI values are still an important parameter in order to exclude obstruction (62).

ELASTOGRAPHY

US shear-wave elastography (SWE) with acoustic radiation force impulse technology, is a non-invasive, non-ionizing imaging method that might be used to evaluate the stiffness of tissues. In the presence of UPJ obstruction, back pressure from upper urinary tract obstruction may affect renal parenchymal

stiffness. A preclinical animal model investigation by Gennisson et al. (63) reported a progressive linear increase in renal stiffness related to increasing urinary pressure. Sohn et al. (64) found that SWE values were higher in kidneys with high-grade hydronephrosis than in normal kidney. In another study by Habibi et al. (65) showed different results: SWE values were higher in control kidneys compared with kidneys affected by UPJ obstruction. In Dillmann et al.'s study to distinguish obstructive hydronephrosis from non-obstructive ones was found no difference in SWE between two groups (66). In addition to limited experience with SWE technology to evaluate kidney, it is not a practical imaging method in the assessment of younger children and requires special application.

ABDOMINAL RADIOGRAPHS

Abdominal radiographs may show soft tissue fullness, bulging of the flank from the affected side and status of bowel loops

(i.e., constipation). It may also demonstrate possible stone formation in the effected kidney and give information about the lumbosacral vertebrae.

VOIDING/MICTURATING CYSTOURETHROGRAM

As this imaging modality will be discussed in detail within the scope of this journal as a separate article, we want to mention only briefly.

The voiding/micturating cystourethrogram cannot evaluate the obstruction but enables to exclude other causes of hydronephrosis, including accompanying vesicoureteral reflux (VUR), urethral valves, and ureterocele (67). VUR may coexist with UPJ obstruction in 8–14% of cases. Identification of VUR is important since children with concurrent VUR and UPJ obstruction may have increased risk for infection (68). Because of its invasive nature, radiation exposure, the risk of urinary tract infection after procedure, indications of voiding cystourethrography should be carefully determined. In the presence of bilateral hydronephrosis (or solitary kidney), duplicated system, small kidney, abnormal echogenicity, dilated ureter, ureterocele, suspected infravesical obstruction, and abnormal bladder voiding cystourethrogram should be performed (69).

INTRAVENOUS PYELOGRAPHY

Intravenous pyelography (IVP) or intravenous urography (IVU) has been the important imaging modality for assessment of the urinary tract (70). Although IVP indications have decreased with advances in imaging technology, it is still used in some centers where advanced imaging methods are limited. Dilatation of collecting system, with parenchymal changes in the nephrogram phase, and delay in excretion of contrast medium are characteristic findings of obstructive hydronephrosis (71). But IVP is not sufficient for visualization of poorly functioning kidneys which are severely blocked due to poor contrast excretion (72). It has some disadvantageous such as impaired image quality as a result of bowel gas, the risk of radiation exposure, contrast nephrotoxicity, and hypersensitivity reactions. It may also requires several radiographs with total examination time period extending up to many hours in cases of urinary tract obstruction.

COMPUTERIZED TOMOGRAPHY UROGRAPHY AND ANGIOGRAPHY

In spite of all advances, as a rule, computed tomography (CT) must be avoided in pediatric patients because of the x-ray content as much as possible (73). Despite ionizing radiation exposure, it can be useful in some specific indications in kidneys and urinary tract diseases in children (74). This method should be considered as a second line imaging technique in children; it can support the diagnosis after a comprehensive US evaluation including Doppler

US. CT scan can detect the location and cause of obstruction such as crossing vessels

While maintaining the diagnostic value of CT examinations as in the ALARA principle, it should be aimed to minimize the dose of X-ray radiation as in the ALARA principle (75–77). For this purpose, the patient should be evaluated with age-adapted kVp and mAs values, multi-phase examinations should be avoided and appropriate amount of contrast, and delay time should be selected (77). If IV contrast medium administration injection is necessary, low or iso-osmolar and non-ionic iodinated ones should be administered and renal function must be checked prior to the examination. Children should be hydrated before the examination. Contrast agent dose may range from 1 and 4 ml/kg, generally 2 ml/kg (78). Since the scan times is shorter, sedation is not often needed.

Multidetector CT scanners allow for rapid and complete imaging of the urinary tract and comprehensive evaluation of the urinary system pathologies. Thin CT slices thickness of <1 mm provides optimal reconstruction in coronal and sagittal planes. The sagittal-coronal projections, additional 2D and 3D-reconstructions 3D-volume rendering and maximal intensity projection (MIP) images are very helpful in better visualizing the anatomy of the collecting system and as well the crossing vessel. Application of CT in the assessment of the urinary tract is called CT urography (CTU), vascular structures evaluation is called CT angiography (CTA).

CTU examination is used for imaging the kidneys and urinary tracts, where the excretory phase is mandatory (79). The triple-phase technique includes separate non-enhanced, contrast-enhanced, and excretory phases. Non-enhanced phase may be obtained to detect stones that may occur secondary to obstruction. On contrast enhanced excretory phased CT, the obstructed kidney demonstrates delayed opacifications, and excretions of contrast material. But it is essential to remember the increased radiation exposure risk of multi-phase studies in children. Therefore, several imaging protocols have been used in practice, in order to decrease radiation exposure such as split bolus technique (80). The contrast medium is administered in two parts, with a several minutes interval between the portions. A split bolus of the contrast agent, combining the parenchymal, and excretory phases may help to reduce the need for multiple phases in some conditions. In addition to ensuring that two examination phases during one scan, this protocol reduces the radiation dose while maintaining the diagnostic value of both phases (78, 80).

The arterial phase is very important and crucial in order to detect the crossing vessel and CTA with multiplanar reformatted and three-dimensional images are used to evaluate the cause of the crossing vessel as a cause of UPJ obstruction especially in older children (Figure 8) (81).

Although the radiation risk is well-known in pediatric patients, CTU, and CTA examinations provide important information both for anatomy and function of the urinary tract (renal parenchyma, collecting system, accessory vessel, stone formation, and contrast excretion) with higher acquisition speed especially in patients who are unable to undergo MRI or in center where MRI is not available.

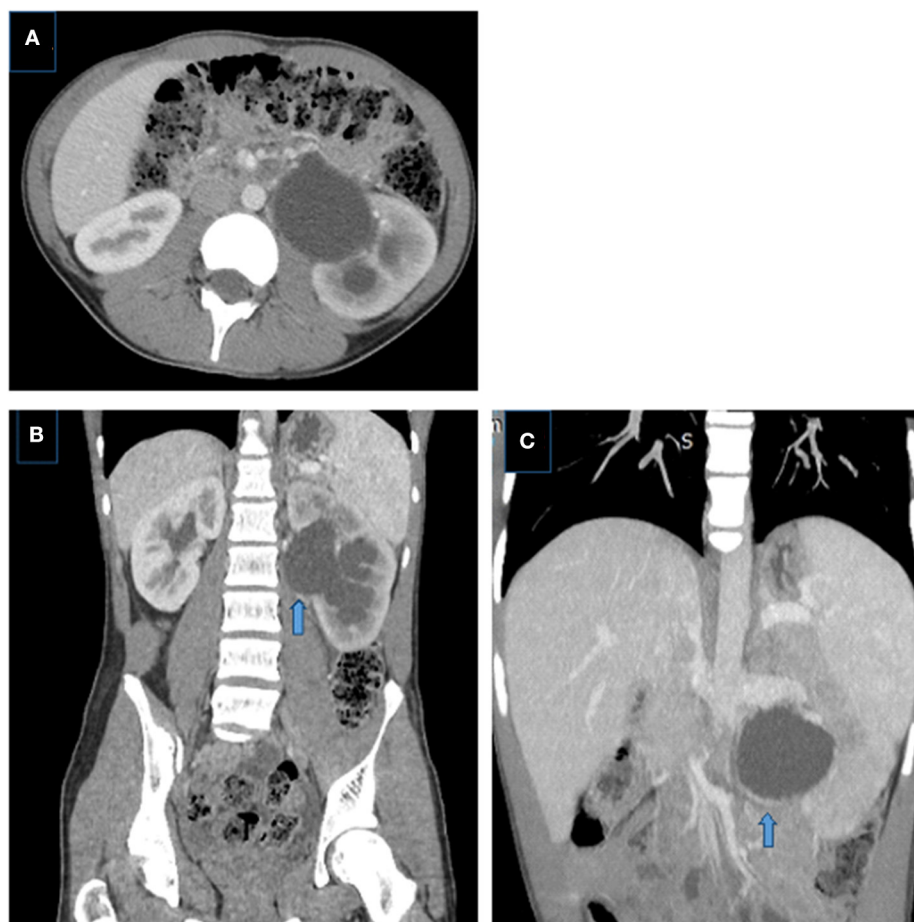


FIGURE 8 | Crossing aberrant renal artery causing left UPJ obstruction in a 14 year-old boy. **(A)** Axial and **(B)** coronal CT images showing left pelvicalyceal system dilatation with delayed nephrogram phase, pelvis is extrarenally located, dilatation is more prominent in the pelvis than calices, note the crossing vessel (arrow). **(C)** Coronal MIP image better demonstrates the crossing vessel as the cause of UPJ obstruction (aberrant lower pole artery) (arrows).

MAGNETIC RESONANCE UROGRAPHY

In recent years, Magnetic Resonance Urography (MRU) has substantially progressed due to the development of high-resolution image generating software and hardware. This imaging technique currently permits the detailed evaluation of complex renal and urinary tract anatomy, while also providing information regarding renal function, including differential renal function, and the presence or absence of obstructive uropathy without the use of ionizing radiation (82, 83). MRU has all the disadvantages of MRI, such as requiring sedation to prevent motion artifacts in younger children. The use of gadolinium, which may be the cause of nephrogenic systemic fibrosis in patients with low glomerular filtration rate (GFR), presence of a metallic prosthesis, staying 35–70 min in an enclosed area for claustrophobic patients and costs are other additional disadvantages (74).

MRU is a promising alternative method, being a single examination able to assess kidneys and the entire urinary tract as it combines both anatomic and functional information (84–86).

In addition to providing detailed anatomical and morphological information about the kidney, MRU enables the evaluation of the whole ureter course and identification of ectopic insertions and potential causes of obstruction (such as crossing vessel) (87, 88).

It is possible that a pediatric MRU be performed at 1.5 or 3 Tesla (T) in children of any age by using multi-element phased-array surface coils. 3 T magnets provide better image resolution, whereas 1.5 T magnets tend to provide more homogeneous fat saturation and are less susceptible to artifacts. A bladder catheter is placed, which permits for continual drainage of urine to avert patient discomfort and promote excretion and assessment of the urethra on imaging. The bladder catheter is first clamped to allow evaluation of the bladder, then the catheter is left to drain. A peripheral IV catheter is positioned to administer hydration, diuretic (usually furosemide) and IV contrast material (86).

MRU examination consists of two basic approaches. The first technique allows evaluation of the anatomical structures of the kidney, ureter, and bladder by using a diversity of T2-weighted pulse sequences (e.g., single shot fast spin echo, two-dimensional fast spin echo [2D] [FSE], and three-dimensional [3D] FSE) (74,

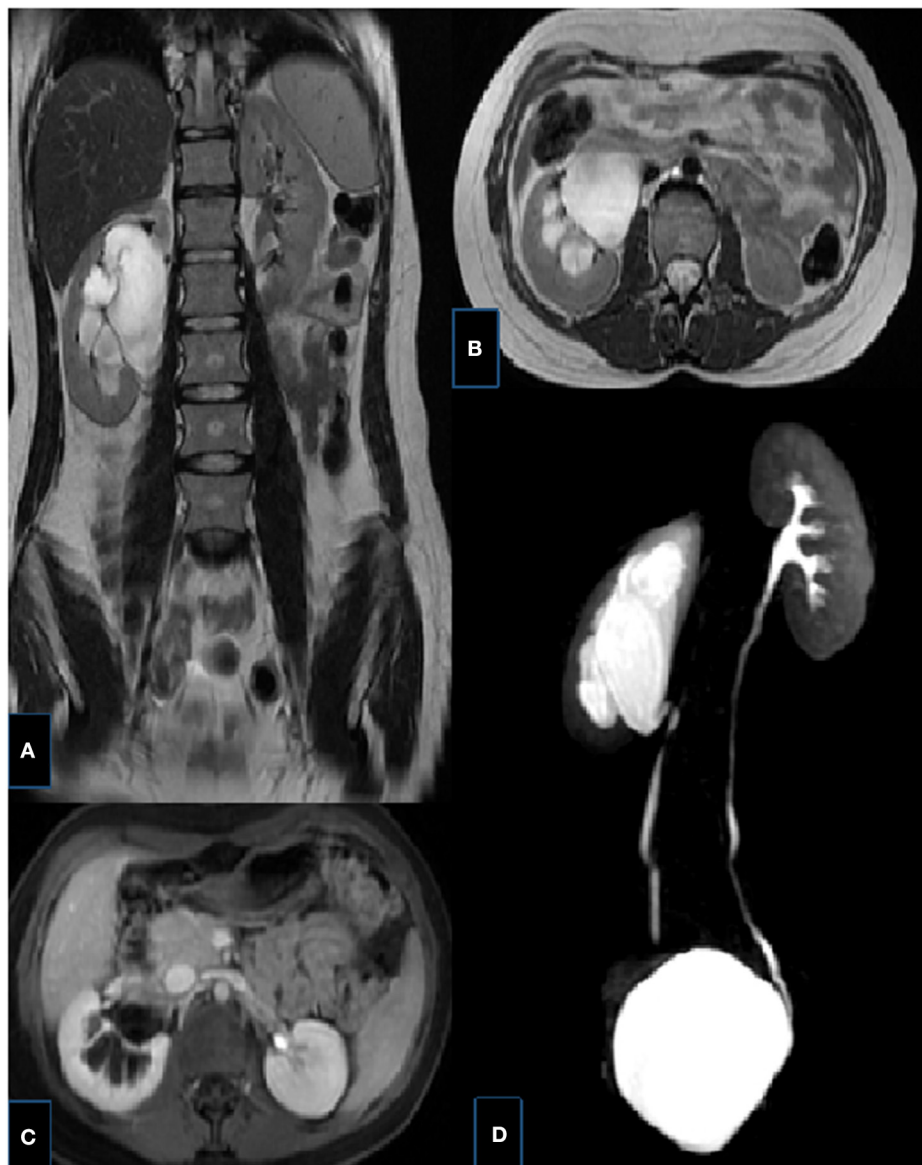

FIGURE 9 | Right UPJ obstruction in a 14-year-old girl. **(A,B)** T2-weighted fast spin-echo coronal (a) and axial (b) MR images showing right renal collecting system dilatation, pelvis is extrarenally located, the thickness of renal parenchyma is decreased and corticomedullary differentiation is lost. **(C)** Axial post-contrast excretory phase showing delayed excretion in the right renal collecting system, notice the contrast material in the left pelvis. **(D)** MIP MR image showing UPJ obstruction with kinking and angulation at the UPJ and a normal caliber ureter, left kidney is normal.

86). It enables direct visualization of UPJ anatomic structures, assessing the degree of luminal narrowing, and determining the presence of UPJ kinking or tortuosity as well as the site of ureteral insertion on the renal pelvis (e.g., abnormally high insertion) (87, 88).

The second technique involves dynamic and delayed postcontrast MRU images that allow evaluation of renal perfusion (including imaging of renal arteries, quality of parenchymal enhancement, contrast material excretion into the renal collection systems, and ureters). Delayed postcontrast images can also be utilized in generating 2D

reformations that provide optimal visualization of relevant anatomic structures (e.g., the UPJ) and 3D reconstructions, including MIP and volume-rendered images, which provide an overview of urinary tract anatomic structures on a single image (**Figure 9**). This method also allows the measurement of differential renal function [based on the amount (volume) of enhancement of renal parenchyma or based upon glomerular filtration of contrast material] and time vs. signal intensity washout/excretion curves. Currently, accurate absolute quantification of glomerular filtration rate is not possible with MRU (89).

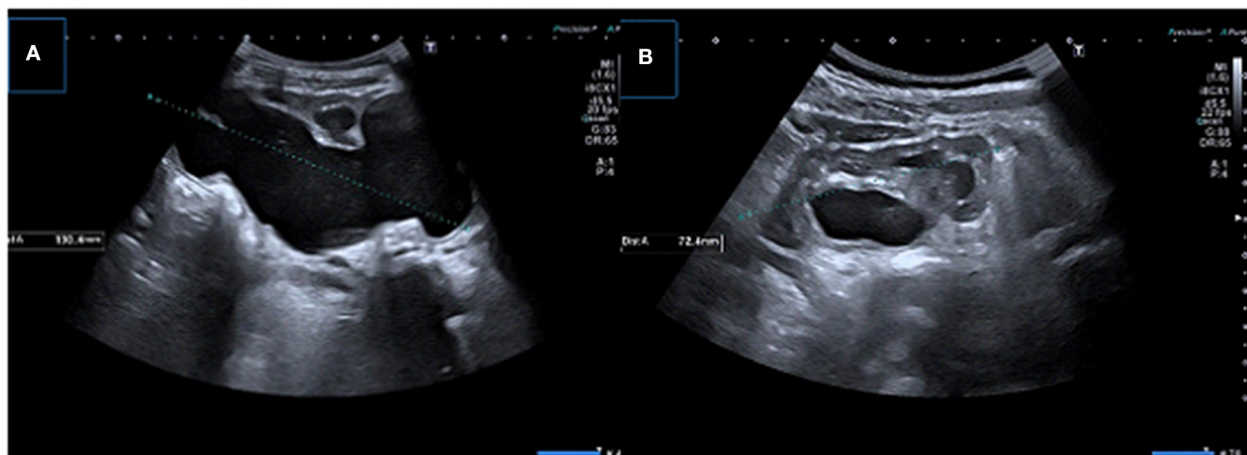


FIGURE 10 | (A) Longitudinal US image in a 1-month-old boy infant showing significant dilation of the pelvicalyceal system with parenchymal thinning **(B)** Control US image obtained after pyeloplasty demonstrates significant resolution of dilatation.

MRU is a promising imaging modality with superior anatomical and functional information in a single test free of the use of ionizing radiation and functional MRU might be able in the future to replace the renogram, because of the quality of the signal. However, due to difficulties of implementation in pediatric group, the absence of each center and the need to increase experience in this regard, it is not widely use yet.

POST-OPERATIVE EVALUATION

Many modalities have been used, US, IVP, radionuclide scan (RS), and MRU to evaluate patients in postoperative period at various time intervals. US and RS are the most widely used investigations (90). As in pre-operative evaluation of UPJ obstruction, there is also no consensus about the follow-up approach and interval in the post-operative period. Studies suggest that follow-up can be performed with both US and RS at certain time intervals in the postoperative period which can direct the necessity of further investigations (91, 92). However, it is obvious that the US should be the first choice to avoid both radiation and urethral catheterization with an increased risk of urethral trauma and urinary system infections in pediatric patients. If there is suspicion about complications in post-operative periods such as urinary tract infections, pyelonephritis, urine extravasation, US is also the first imaging modality.

Properly performed US provides an accurate assessment of renal pelvis/caliceal dilatation, renal parenchymal thickness, echogenicity, and renal growth postoperatively. After successful pyeloplasty, renal function stabilization takes ~1 year and renal function may improve (Figure 10). If there is no problem in the early postoperative period, first control with urinary US may be performed 1 month after the operation. Persistence of the pelvicalyseal dilatation does not indicate continued obstruction (93). In this early post-operative period, significant

resolution of hydronephrosis should not be expected, no worsening, or a slight decrease in hydronephrosis can be sufficient (93). Because even if obstruction is surgically removed, the average time for the renal pelvis to regain flexibility is achieved around 2 years (21, 30). On the other hand, it should also be known that early improvement in dilatation on US could be due to surgical reduction of the renal pelvis rather than true improvement. Measurement of pelvis AP diameter and parenchymal thickness may be useful for follow-up but there is no cut-off value in pelvic diameter due to these factors mentioned above and the level of hydronephrosis is also affected by hydration or the amount of urine in the bladder. However, we can say that worsening or persistence of hydronephrosis, decrease in cortical thickness and clinical findings (i.e., colic pain, urinary tract infection) are not expected findings and should alert to determine the functional patency of the UPJ.

Although majority of surgical failures occur within 1 year after pyeloplasty, there are also cases reported later and failure rate has been described in published reports as 5–10% (94, 95). Serial renal US are recommended at 3, 6, and 12 months, and then annually for 2 years, with additional testing based on US and clinical presentation (95).

IVP was previously widely used to assess surgical success after pyeloplasty, although it is not preferred now. CT and MRU are other radiological options to assess surgical anastomoses (e.g., in the context of UPJ obstruction repair) and reimplanted ureters (96).

CONCLUSION

US is the main imaging study used to diagnose UPJ obstruction. This method has lots of advantages but does not provide functional information about the urinary tract. The question is to differentiate true obstruction from urinary tract dilatation which is very crucial in determining the treatment decision.

US examination provides essential information regarding laterality, kidney size, appearance (such as echogenicity, corticomedullary differentiation, cyst), parenchymal thickness, degree of obstruction. In order to provide right decision, necessity of surgery and standardization, grading, and classification systems have been developed. However, there is no definite consensus and worldwide accepted standard protocols and as a result current therapeutic approach is mostly based on US findings, follow-up results, clinical and scintigraphic findings, and dependent on physician or

institutional individual practices. CT and MR are not routinely performed radiologic studies but are often reserved for special cases such as demonstration of an aberrant artery as the cause of obstruction.

AUTHOR CONTRIBUTIONS

All authors listed have made a substantial, direct and intellectual contribution to the work, and approved it for publication.

REFERENCES

- Cohen HL, Kravets F, Zucconi W, Ratani R, Shah S, Dougherty D, et al. Congenital abnormalities of the genitourinary system. *Semin Roentgenol.* (2004) 39:282–303. doi: 10.1053/j.ro.2003.12.005
- Gonzalez R, Schimke CM. Ureteropelvic junction obstruction in infants and children. *Pediatr Clin North Am.* (2001) 48:1505–18. doi: 10.1016/S0031-3955(05)70388-6
- Yiee JH, Johnson-Welch S, Baker LA, Wilcox DT. Histologic differences between extrinsic and intrinsic ureteropelvic junction obstruction. *Urology.* (2010) 76:181–4. doi: 10.1016/j.urol.2010.02.007
- Hosgor M, Karaca I, Ulukus C, Ozer E, Ozkara E, Sam B, et al. Structural changes of smooth muscle in congenital ureteropelvic junction obstruction. *J Pediatr Surg.* (2005) 40:1632–6. doi: 10.1016/j.jpedsurg.2005.06.025
- Hashim H, Woodhouse CRJ. Ureteropelvic junction obstruction. *Eur Urol. Suppl.* (2012) 11:25–32. doi: 10.1016/j.eursup.2012.01.004
- Koff SA. The beneficial and protective effects of hydronephrosis. *APMIS.* (2003) 111:7–12.
- Epelman M, Victoria T, Meyers KE, Chauvin N, Servaes S, Darge K. Postnatal imaging of neonates with prenatally diagnosed genitourinary abnormalities: a practical approach. *Pediatr Radiol.* (2012) 42(Suppl 1):S124–41. doi: 10.1007/s00247-011-2177-1
- Brown T, Mandell J, Lebowitz RL. Neonatal hydronephrosis in the era of sonography. *AJR Am J Roentgenol.* (1987) 148:959–63. doi: 10.2214/ajr.148.5.959
- Sinha A, Bagga A, Krishna A, Bajpai M, Srinivas M, Uppal R, et al. Revised guidelines on management of antenatal hydronephrosis. *Indian J Nephrol.* (2013) 23:83–97. doi: 10.4103/0971-4065.109403
- Wiener JS, O'Hara SM. Optimal timing of initial postnatal ultrasonography in newborns with prenatal hydronephrosis. *J Urol.* (2002) 168:1826–9. doi: 10.1016/S0022-5347(05)64423-0
- Laing FC, Burke VD, Wing VW, Jeffrey RB Jr, Hashimoto B. Postpartum evaluation of fetal hydronephrosis: optimal timing for follow-up sonography. *Radiology.* (1984) 152:423–4. doi: 10.1148/radiology.152.2.6539930
- Signorelli M, Cerri V, Taddei F, Groli C, Bianchi UA. Prenatal diagnosis and management of mild fetal pyelectasis implications for neonatal outcome and follow-up. *Eur J Obstet Gynecol Reprod Biol.* (2005) 118:154–9. doi: 10.1016/j.ejogrb.2004.04.023
- Choi YH, Cheon JE, Kim WS, Kim IO. Ultrasonography of hydronephrosis in the newborn: a practical review. *Ultrasonography.* (2016) 35:198–211. doi: 10.14366/usg.15073
- Siegel MJ. Urinary tract. In: Siegel MJ, editor. *Pediatric Sonography.* Philadelphia, PA: Lippincott Williams & Wilkins. (2011). p. 384–460.
- Sharma G, Sharma A, Maheshwari P. Predictive value of decreased renal pelvis anteroposterior diameter in prone position for prenatally detected hydronephrosis. *J Urol.* (2012) 187:1839–43. doi: 10.1016/j.juro.2011.12.093
- Rumack CM, Wilson SR, Charboneau JW. *Diagnostic Ultrasound.* 3rd ed. St. Louis, MO: Elsevier Health Sciences (2005). p. 16–20.
- Paliwalla M, Park K. A practical guide to urinary tract ultrasound in a child: pearls and pitfalls. *Ultrasound.* (2014) 22:213–22. doi: 10.1177/1742271X14549795
- Lebowitz AL, Blickman JG. The coexistence of ureteropelvic junction obstruction and reflux. *AJR.* (1983) 140:231–8. doi: 10.2214/ajr.140.2.231
- Fernbach SK, Maizels M, Conway JJ. Ultrasound grading of hydronephrosis: introduction to the system used by the society for fetal urology. *Pediatr Radiol.* (1993) 23:478–80. doi: 10.1007/BF02012459
- Nguyen HT, Benson CB, Bromley B, Campbell JB, Chow J, Coleman B, et al. Multidisciplinary consensus on the classification of prenatal and postnatal urinary tract dilation (UTD classification system). *J Pediatr Urol.* (2014) 10:982–98. doi: 10.1016/j.jpuro.2014.10.002
- Onen A. An alternative grading system to refine the criteria for severity of hydronephrosis and optimal treatment guidelines in neonates with primary UPJ-type hydronephrosis. *J Pediatr Urol.* (2007) 3:200–5. doi: 10.1016/j.jpuro.2006.08.002
- Nguyen HT, Herndon CD, Cooper C, Gatti J, Kirsch A, Kokorowski P, et al. The society for fetal urology consensus statement on the evaluation and management of antenatal hydronephrosis. *J Pediatr Urol.* (2010) 6:212–31. doi: 10.1016/j.jpuro.2010.02.205
- Nguyen H. Degree of fetal renal pelvic dilatation predicts postnatal obstruction. *Nat Clin Pract Urol.* (2007) 4:10–11. doi: 10.1038/ncpuro0651
- Angell SK, Pruthi RS, Shortliffe LD. The urodynamic relationship of renal pelvic and bladder pressures, and urinary flow rate in rats with congenital vesicoureteral reflux. *J Urol.* (1998) 160:150–6. doi: 10.1016/S0022-5347(01)63074-X
- Peerbooccus M, Damry N, Pather S, Devriendt A, Avni F. The impact of hydration on renal measurements and on cortical echogenicity in children. *Pediatr Radiol.* (2013) 43:155–65. doi: 10.1007/s00247-013-2748-4
- Hasch E. Changes in renal pelvic size in children after fluid intake demonstrated by ultrasound. *Ultrasound Med Biol.* (1977) 2:287–90. doi: 10.1016/0301-5629(77)90028-X
- Timberlake MD, Herndon CDA. Mild to moderate postnatal hydronephrosis - grading systems and management. *Nat Rev Urol.* (2013) 10:649–56. doi: 10.1038/nrurol.2013.172
- Ulman I, Jayanthi VR, Koff SA. The long-term follow up of newborns with severe unilateral hydronephrosis initially treated non-operatively. *J Urol.* (2000) 164:1101–5. doi: 10.1097/00005392-200009020-00046
- Onen A. The natural history and therapeutic approach of antenatally diagnosed primary UPJ-type hydronephrosis. *Turk J Pediatr Surg.* (2006) 20:33–8.
- Dhillon HK. Prenatally diagnosed hydronephrosis: the great ormond street experience. *Br J Urol.* (1998) 81:39–44. doi: 10.1046/j.1464-410X.1998.0810s2039.x
- Dos Santos J, Parekh RS, Piscione TD, Hassouna T, Figueroa V, Gonima P, et al. A new grading system for the management of antenatal hydronephrosis. *Clin J Am Soc Nephrol.* (2015) 10:1783–90. doi: 10.2215/CJN.12861214
- Oktar T, Acar O, Atar A, Salabas E, Ander H, Ziyilan O, et al. How does the presence of antenatally detected caliectasis predict the risk of postnatal surgical intervention? *Urology.* (2012) 80:203–6. doi: 10.1016/j.urol.2012.01.083
- Dias CS, Silva JM, Pereira AK, Marino VS, Silva LA, Coelho AM, et al. Diagnostic accuracy of renal pelvic dilatation for detecting surgically managed ureteropelvic junction obstruction. *J. Urol.* (2013) 190:661–6. doi: 10.1016/j.juro.2013.02.014
- Bouzada MC, Oliveira EA, Pereira AK, Leite HV, Rodrigues AM, Fagundes LA, et al. Diagnostic accuracy of postnatal renal pelvic diameter as a

- predictor of uropathy: a prospective study. *Pediatr Radiol.* (2004) 34:798–804. doi: 10.1007/s00247-004-1283-8
35. Yiee J, Wilcox D. Management of fetal hydronephrosis. *Pediatr Nephrol.* (2008) 23:347–53. doi: 10.1007/s00467-007-0542-y
 36. Burgu, B, Aydogdu O, Soygur T, Baker L, Snodgrass W, Wilcox D, et al. When is it necessary to perform nuclear renogram in patients with a unilateral neonatal hydronephrosis. *World J Urol.* (2012) 30:347–52. doi: 10.1007/s00345-011-0744-6
 37. Coplen DE, Austin PF, Yan, Y, Blanco VM, Dicke JM. The magnitude of fetal renal pelvic dilation can identify obstructive postnatal hydronephrosis, direct postnatal evaluation management. *J Urol.* (2006) 176:724–7. doi: 10.1016/j.juro.2006.03.079
 38. Sharifian M, Esfandiar N, Mohkam M, Dalirani R, Baban Taher E, Akhlaghi A. Diagnostic accuracy of renal pelvic dilatation in determining outcome of congenital hydronephrosis. *Iran J Kidney Dis.* (2014) 8:26–30.
 39. Sidhu G, Beyene J, Rosenblum ND. Outcome of isolated antenatal hydronephrosis: a systematic review and metaanalysis. *Pediatr Nephrol.* (2006) 21:218–24. doi: 10.1007/s00467-005-2100-9
 40. Ross SS, Kardos S, Krill A, Bourland J, Sprague B, Majd M, et al. Observation of infants with SFU Grades 3–4 hydronephrosis: worsening drainage with serial diuresis renography indicates surgical intervention and helps prevent loss of renal function. *J Pediatr Urol.* (2011) 7:266–71. doi: 10.1016/j.jpuro.2011.03.001
 41. Keays MA, Guerra LA, Mihill J, Raju G, Al-Asheeri N, Geier P, et al. Reliability assessment of society for fetal urology ultrasound grading system for hydronephrosis. *J Urol.* (2008) 180 (Suppl. 4):1680–2. doi: 10.1016/j.juro.2008.03.107
 42. Sibai H, Salle JL, Houle AM, Lambert R. Hydronephrosis with diffuse or segmental cortical thinning: impact on renal function. *J. Urol.* (2001) 165:2293–5. doi: 10.1097/00005392-200106001-00019
 43. Riccabona M, Avni FE, Blickman JG, Dacher JN, Darge K, Lobo ML, et al. Imaging recommendations in paediatric urology: minutes of the ESPR workgroup session on urinary tract infection, fetal hydronephrosis, urinary tract ultrasonography and voiding cystourethrography, Barcelona, Spain, June 2007. *Pediatr Radiol.* (2008) 38:138–45. doi: 10.1007/s00247-007-0695-7
 44. Longpre M, Nguan A, Macneily AE, Afshar K. Prediction of the outcome of antenatally diagnosed hydronephrosis: a multivariable analysis. *J Pediatr Urol.* (2012) 8:135–9. doi: 10.1016/j.jpuro.2011.05.013
 45. Chow JS, Koning JL, Back SJ, Nguyen HT, Phelps A, Darge K. Classification of pediatric urinary tract dilation: the new language. *Pediatr Radiol.* (2017) 47:1109–15. doi: 10.1007/s00247-017-3883-0
 46. Kim SY, Kim MJ, Yoon CS, Lee MS, Han KH, Lee MJ. Comparison of the reliability of two hydronephrosis grading systems: the society for foetal urology grading system vs. the Onen grading system. *Clin Radiol.* (2013) 68:484–90. doi: 10.1016/j.crad.2013.03.023
 47. Onen A. Üreteropelvik bileşke darlığı. *Çocuk Cerrahisi Dergisi.* (2016) 30:55–79. doi: 10.5222/JTAPS.2016.055
 48. Cost GA, Merguerian PA, Cheerasarn SP, Shortliffe LM. Sonographic renal parenchymal and pelvicalceal areas: new quantitative parameters for renal sonographic followup. *J Urol.* (1996) 156:725–9. doi: 10.1016/S0022-5347(01)65798-7
 49. Shapiro SR, Wahl EF, Silberstein MJ, Steinhart G. Hydronephrosis index: a new method to track patients with hydronephrosis quantitatively. *Urology.* (2008) 72:536–8. Discussion 8–9. doi: 10.1016/j.urology.2008.02.007
 50. Imaji R, Dewan PA. Calyx to parenchyma ratio in pelviureteric junction obstruction. *BJU Int.* (2002) 89:73–7. doi: 10.1046/j.1464-410X.2002.02543.x
 51. Riccabona M, Fritz GA, Schollnast H, Schwarz T, Deutschmann MJ, Mache CJ. Hydronephrotic kidney: pediatric three-dimensional US for relative renal size assessment initial experience. *Radiology.* (2005) 236:276–83. doi: 10.1148/radiol.2361040158
 52. Braga LH, McGrath M, Farrokhvar F, Jegatheeswaran K, Lorenzo AJ. Associations of initial society for fetal urology grades and urinary tract dilatation risk groups with clinical outcomes in patients with isolated prenatal hydronephrosis. *J Urol.* (2017) 197:831–7. doi: 10.1016/j.juro.2016.08.099
 53. Chalmers DJ, Meyers ML, Brodie KE, Palmer C, Campbell JB. Inter-rater reliability of the APD, SFU UTD grading systems in fetal sonography MRI. *J Pediatr Urol.* (2016) 12:305.e1–305.e5. doi: 10.1016/j.jpuro.2016.06.012
 54. Onen A. The natural history and therapeutic approach of antenatally diagnosed primary UPJ-type hydronephrosis. *Turk J Pediatr Surg.* (2006) 20:33–8.
 55. Hafez AT, McLorie G, Bagli D, Khoury A. Analysis of trends on serial ultrasound for high grade neonatal hydronephrosis. *J Urol.* (2002) 168:1518e21. doi: 10.1016/S0022-5347(05)64508-9
 56. Onen A. Neonatal hydronephrosis. In: Onen A, editor. *Pediatric Surgery and Urology.* Istanbul: Nobel Tip Kitapevi (2006), p. 345–65.
 57. De Bessa J Jr, Denes FT, Chammass MC, Cerri L, Monteiro ED, Buchpiguel CA, et al. Diagnostic accuracy of color Doppler sonographic study of the ureteric jets in evaluation of hydronephrosis. *J Pediatr Urol.* (2008) 4:113–7. doi: 10.1016/j.jpuro.2007.10.013
 58. Cvitkovic Kuzmic A, Brkljacic B, Rados M, Galesic K. Doppler visualization of ureteric jets in unilateral hydronephrosis in children and adolescents. *Eur J Radiol.* (2001) 39:209–14. doi: 10.1016/S0720-048X(01)00329-1
 59. Kessler RM, Quevedo H, Lankau CA, Ramirez-Seijas F, Cepero-Akselrad A, Altman DH, et al. Obstructive vs nonobstructive dilatation of the renal collecting system in children: distinction with duplex sonography. *AJR Am J Roentgenol.* (1993) 160:353–7. doi: 10.2214/ajr.160.2.8424349
 60. Okada T, Yoshida H, Iwai J, Matsunaga T, Yoshino K, Ohtsuka Y, et al. Pulsed doppler sonography of the hilar renal artery: differentiation of obstructive from nonobstructive hydronephrosis in children. *J Pediatr Surg.* (2001) 36:416–20. doi: 10.1053/jpsu.2001.21607
 61. Gilbert R, Garra B, Gibbons MD. Renal duplex Doppler ultrasound: an adjunct in the evaluation of hydronephrosis in the child. *J Urol.* (1993) 150:1192–4. doi: 10.1016/S0022-5347(17)35723-3
 62. Shokeir AA, Provoost AP, Nijman RJM. Resistive index in obstructive uropathy. *Br J Urol.* (1997) 80:195–200. doi: 10.1046/j.1464-410X.1997.00243.x
 63. Gennison JL, Grenier N, Combe C, Tanter M. Supersonic shear wave elastography of *in vivo* pig kidney: influence of blood pressure, urinary pressure and tissue anisotropy. *Ultrasound Med Biol.* (2012) 38:1559–67. doi: 10.1016/j.ultrasmedbio.2012.04.013
 64. Sohn B, Kim MJ, Han SW, Im YJ, Lee MJ. Shear wave velocity measurements using acoustic radiation force impulse in young children with normal kidneys versus hydronephrotic kidneys. *Ultrasonography.* (2014) 33:116–21. doi: 10.14366/usg.14002
 65. Habibi H, Cicek R, Kandemirli S, Ure E, Ucar AK, Aslan M, et al. Acoustic radiation force impulse (ARFI) elastography in the evaluation of renal parenchymal stiffness in patients with ureteropelvic junction obstruction. *J Med Ultrason.* (2017) 44:167–72.1. doi: 10.1007/s10396-016-0760-7
 66. Dillman JR, Smith EA, Davenport MS, DiPietro MA, Sanchez R, Kraft KH, et al. Can shear-wave elastography be used to discriminate obstructive hydronephrosis from nonobstructive hydronephrosis in children? *Radiology.* (2015) 277:259–67. doi: 10.1148/radiol.2015142884
 67. Blickman JG. *Pediatric Urinary Tract Infection: Imaging Techniques With Special Reference to Voiding Cystoerethrography.* Rotterdam: Erasmus University (1991).
 68. Silay MS, Spinoit AF, Bogaert G, Hoebeke P, Nijman R, Haid B, et al. Imaging for vesicoureteral reflux and ureteropelvic junction obstruction. *Eur Urol Focus.* (2016) 2:130–8. doi: 10.1016/j.euf.2016.03.015
 69. Psooy K, Pike J. Investigation and management of antenatally detected hydronephrosis. *Can Urol Assoc J.* (2009) 3:69–72. doi: 10.5489/cauj.1027
 70. Platt JF. Urinary obstruction. *Radiol Clin North Am.* (1996) 34:1113–29.
 71. Esmaeili M, Esmaeili M, Ghane F, Alamdaran A. Comparison between diuretic urography (IVP) and diuretic renography for diagnosis of ureteropelvic junction obstruction in children. *Iran J Pediatr.* (2016) 2:e4293. doi: 10.5812/ijp.4293
 72. Tsai JD, Huang FY, Lin CC, Tsai TC, Lee HC, Sheu JC, et al. Intermittent hydronephrosis secondary to ureteropelvic junction obstruction: clinical and imaging features. *Pediatrics.* (2006) 117:139–46. doi: 10.1542/peds.2005-0583
 73. Frush D, Donnelly LF, Rosen, NS. Computed tomography and radiation risks: what pediatric health care providers should know. *Pediatrics.* (2003) 112:951–7. doi: 10.1542/peds.112.4.951
 74. Riccabona M, Avni FE, Dacher J-N, Damasio MB, Darge K, Lobo L, et al. ESPR urology task force and ESUR paediatric working group: imaging and procedural recommendations in paediatric urology, part III. minutes of the ESPR urology task force minisymposium on intravenous urography,

- uro-CT and MR-urography in childhood. *Pediatr Radiol.* (2010) 40:1315–20. doi: 10.1007/s00247-010-1686-7
75. Strauss KJ, Goske MJ, Kaste SC, Bulas D, Frush DP, Butler P, et al. Image gently: ten steps you can take to optimize image quality and lower CT dose for paediatric patients. *AJR Am J. Roentgenol.* (2010) 194:868–73. doi: 10.2214/AJR.09.4091
 76. Thomas KE, Wang B. Age-specific effective doses for paediatric MSCT examinations at a large children's hospital using DLP conversion coefficients: a simple estimation method. *Pediatr Radiol.* (2008) 38:645–56. doi: 10.1007/s00247-008-0794-0
 77. Basics of Radiation Protection for Everyday Use. *How to Achieve ALARA: Working Tips and Guidelines.* Geneva: WHO (2004).
 78. Damasio MB, Darge K, Riccabona M. Multi-detector CT in the paediatric urinary tract. *Eur J Radiol.* (2013) 82:11181125 doi: 10.1016/j.ejrad.2011.12.005
 79. Van Der Molen AJ, Cowan NC, Mueller-Lisse UG, Nolte-Ernsting CC, Takahashi S, Cohan RH. CT urography: definition, indications and techniques: a guideline for clinical practice. *Eur Radiol.* (2008) 18:4–17. doi: 10.1007/s00330-007-0792-x
 80. Dillman JR, Caoili EM, Cohan RH, Ellis JH, Francis IR, Nan B, et al. Comparison of urinary tract distension and opacification using single-bolus 3-phase vs split-bolus 2-phase multidetector row CT urography. *J Comput Assist Tomogr.* (2007) 31:750–7. doi: 10.1097/RCT.0b013e318033df36
 81. Mitsumori A, Yasui K, Akaki S, Togami I, Joja I, Hashimoto H, et al. Evaluation of crossing vessels in patients with ureteropelvic junction obstruction by means of helical CT. *Radiographics.* (2000) 20:1383–93, discussion 1393–1395. doi: 10.1148/radiographics.20.5.g00se061383
 82. Darge K, Higgins M, Hwang TJ, Delgado J, Shukla A, Bellah R. Magnetic resonance and computed tomography in pediatric urology: an imaging overview for current and future daily practice. *Radiol Clin North Am.* (2013) 51:583–98 doi: 10.1016/j.rcl.2013.03.004
 83. Perez-Brayfield MR, Kirsch AJ, Jones RA, Grattan-Smith JD. A prospective study comparing ultrasound, nuclear scintigraphy and dynamic contrast enhanced magnetic resonance imaging in the evaluation of hydronephrosis. *J Urol.* (2003) 170:1330–4. doi: 10.1097/01.ju.0000086775.66329.00
 84. McDaniel BB, Jones RA, Scherz H, Kirsch AJ, Little SB, Grattan-Smith JD. Dynamic contrast-enhanced MR urography in the evaluation of pediatric hydronephrosis: Part 2, anatomic and functional assessment of ureteropelvic junction obstruction. *AJR Am J Roentgenol.* (2005) 185:1608–14. doi: 10.2214/AJR.04.1574
 85. Zielonko J, Studniarek M, Markuszewski M. MR urography of obstructive uropathy: diagnostic value of the method in selected clinical groups. *Eur Radiol.* (2003) 13:802–9. doi: 10.1007/s00330-002-1550-8
 86. Dickerson EC, Dillman JR, Smith EA, Di Pietro MA, Lebowitz RL, Darge K. Pediatric MR urography: indications, techniques, and approach to review. *RadioGraphics.* (2015) 35:1208–30 doi: 10.1148/rg.2015140223
 87. Wong MCY, Piaggio G, Damasio MB, Molinelli C, Ferretti SM, Pistorio A, et al. Hydronephrosis and crossing vessels in children: optimization of diagnostic-therapeutic pathway and analysis of color Doppler ultrasound and magnetic resonance urography diagnostic accuracy. *J Pediatr Urol.* (2018) 14:68:1–6. doi: 10.1016/j.jpuro.2017.09.019
 88. Parikh KR, HammerMR, Kraft KH, Ivančić V, Smith EA, Dillman JR. Pediatric ureteropelvic junction obstruction: can magnetic resonance urography identify crossing vessels? *Pediatr Radiol.* (2015) 45:1788–95. doi: 10.1007/s00247-015-3412-y
 89. Piepsz A, Ismaili K, Hall M, Collier F, Tondeur M, Ham H. How to interpret a deterioration of split function? *Eur Urol.* (2005) 47:686–90. doi: 10.1016/j.eururo.2004.10.028
 90. Salem YH, Majd M, Rushton HG, Belman AB. Outcome analysis of pediatric pyeloplasty as a function of patient age, presentation and differential renal function. *J Urol.* (1995) 154:1889–93. doi: 10.1016/S0022-5347(01)66819-8
 91. Kis E, Verebely T, Kovi R, Mátyus I. The role of ultrasound in the follow-up of postoperative changes after pyeloplasty. *Pediatr Radiol.* (1998) 28:247–9. doi: 10.1007/s002470050342
 92. Amling CL, O'Hara SM, Wiener JS, Schaeffer CS, King LR. Renal ultrasound changes after pyeloplasty in children with ureteropelvic junction obstruction: long-term outcome in 47 renal units. *J Urol.* (1996) 156:2020–4.
 93. Lim DJ, Walker RD. Management of the failed pyeloplasty. *J Urol.* (1996) 156:738–40. doi: 10.1016/S0022-5347(01)65801-4
 94. Helmy TE, Sarhan OM, Hafez AT, Elsherbiny MT, Dawaba ME, Ghali AM, et al. Surgical management of failed pyeloplasty in children: single-center experience. *J Pediatr Urol.* (2009) 5:87–9. doi: 10.1016/j.jpuro.2008.09.001
 95. Thomas JC, DeMarco RT, Donohoe JM, Adams MC, Pope JC IV, Brock JW III. Management of the failed pyeloplasty: a contemporary review. *J Urol.* (2005) 174:2363–6. doi: 10.1097/01.ju.0000180420.11915.31
 96. Kirsch, AJ, McMann LP, Jones RA, Smith EA, Scherz HC, Grattan-Smith JD. (2006) Magnetic resonance urography for evaluating outcomes after pediatric pyeloplasty. *J. Urol.* 176:1755–61. doi: 10.1016/j.juro.2006.03.115

Conflict of Interest: The authors declare that the research was conducted in the absence of any commercial or financial relationships that could be construed as a potential conflict of interest.

Copyright © 2020 Ucar and Kurugoglu. This is an open-access article distributed under the terms of the Creative Commons Attribution License (CC BY). The use, distribution or reproduction in other forums is permitted, provided the original author(s) and the copyright owner(s) are credited and that the original publication in this journal is cited, in accordance with accepted academic practice. No use, distribution or reproduction is permitted which does not comply with these terms.



Symptomatology and Clinic of Hydronephrosis Associated With Uretero Pelvic Junction Anomalies

Ilmay Bilge*

Division of Pediatric Nephrology, Department of Pediatrics, School of Medicine, Koc University, Istanbul, Turkey

OPEN ACCESS

Edited by:

Abdurrahman Onen,
Onen Pediatric Urology Center, Turkey

Reviewed by:

Baran Tokar,
Eskişehir Osmangazi University, Turkey
Andres Gomez Fraile,
University Hospital October 12, Spain

*Correspondence:

Ilmay Bilge
ibilge@ku.edu.tr

Specialty section:

This article was submitted to
Pediatric Urology,
a section of the journal
Frontiers in Pediatrics

Received: 28 February 2020

Accepted: 22 July 2020

Published: 30 September 2020

Citation:

Bilge I (2020) Symptomatology and
Clinic of Hydronephrosis Associated
With Uretero Pelvic Junction
Anomalies. *Front. Pediatr.* 8:520.
doi: 10.3389/fped.2020.00520

The most common cause of hydronephrosis in the pediatric age group is ureteropelvic junction-type hydronephrosis (UPJHN). Since the advent of widespread maternal ultrasound screening, clinical presentation of hydronephrosis associated with UPJ anomalies has changed dramatically. Today most cases are diagnosed in the prenatal period, and neonates present without signs or symptoms. For those who are not detected at birth, UPJHN eventually presents throughout childhood and even adulthood with various symptoms. Clinical picture of UPJHN highly depends on the presence and severity of obstruction, and whether it affects single or both kidneys. Abdominal or flank pain, abdominal mass, hematuria, kidney stones, urinary tract infections (UTI), and gastrointestinal discomfort are the main symptoms of UPJHN in childhood. Other less common findings in such patients are growth retardation, anemia, and hypertension. UTI is a relatively rare condition in UPJHN cases, but it may occur as pyelonephritis. Vesicoureteric reflux should be kept in mind as a concomitant pathology in pediatric UPJHN that develop febrile UTI. Although many UPJHN cases are known to improve over time, close clinical observation is critical in order to avoid irreversible kidney damage. The most appropriate approach is to follow-up the patients considering the presence of symptoms, the severity of hydronephrosis and the decrease in kidney function and, if necessary, to decide on early surgical intervention.

Keywords: ureteropelvic junction, hydronephrosis, urinary tract infection, pain, children

INTRODUCTION

Widespread use of prenatal ultrasonography (US) gave clinicians the opportunity to diagnose urinary tract abnormalities much earlier and more frequently than the past (1). The approximate varying incidence of 1 per 750–2,000, ureteropelvic junction type hydronephrosis (UPJHN) is the most common cause of childhood hydronephrosis (2). It occurs in 13% of children with prenatally detected renal pelvis dilatation, and is more common on the left side, more common in boys (2:1- male to female), and is rarely seen bilaterally (2–4).

An obstruction at ureteropelvic junction level which is defined as restriction of urine outflow from pelvis renalis to the ureter may result in progressive deterioration or hinder normal renal development (5–8). Over 50% of all cases considered to have kidney abnormalities in the prenatal period are hydronephrosis, but unfortunately there are currently no reliable prenatal diagnostic test that can distinguish obstructive hydronephrosis from non-obstructive (8–10). The differentiation between urinary tract obstruction and dilatation is the most important problem in the management of these patients (6, 11, 12). Since the clinical course are quite diverse, and generalization is rather

difficult, the most appropriate approach of UPJHN seen in children would be to evaluate on a patient basis (4, 13–16).

In this review, the purpose is to provide general information about the clinical presentation and symptomatology of hydronephrosis associated with uretero pelvic junction anomalies, as well as discussing the clinical findings through some case examples.

CLINICAL PRESENTATION

Over the last decades, clinical presentation of patients with UPJHN has shifted from the “symptomatic” patients to the “asymptomatic” neonates who present with prenatal diagnosis (1–4, 15, 16). UPJHN cases without a prenatal diagnosis present with various symptoms such as febrile urinary tract infection (UTI), abdominal masses, pain, pyuria, hematuria, and some gastrointestinal symptoms in the post-natal period or later years. Failure to thrive, anemia, hypertension, and urinary extravasation are much more rare symptoms of UPJHN in childhood (14–16).

Clinical picture of hydronephrosis associated with uretero pelvic junction anomalies highly depends on the presence and severity of obstruction, and whether it affects single or both kidneys. However, most infants with severe hydronephrosis are otherwise asymptomatic and rarely require intervention during follow-up (6, 8, 12). Therefore, parallel to the change in its clinical presentation, the first enthusiasm for early intervention of hydronephrosis associated with UPJ anomalies has turned into a more conservative approach in recent years (11, 15, 17–19). Although there are numerous publications regarding conservative management of UPJ hydronephrosis, and the current trend is to follow the infants through clinical and US findings, the general practice shows a wide variety even today (20–26).

The most accurate answers to the questions of which treatment is better for symptomatic infants, which kidney will benefit from surgery and which patients should be followed up expectantly are still not clear. There are two issues that do not have much discussion during follow-up period of UPJHN patients. First; close monitoring is mandatory for high-grade hydronephrosis managed conservatively; secondly, severe hydronephrosis suggesting an obstruction in solitary kidney is an indisputable condition that requires urgent intervention. An urgent intervention may also be required in patients presenting with urosepsis or acute renal failure (13, 15, 26, 27). In general, the surgical decision in UPJOHN cases is made based on US findings. Therefore, accurate determination of hydronephrosis severity is very important for infants associated with UPJHN. In severe cases of hydronephrosis (SFU 4) with renal parenchymal thinning, clinicians should make a surgical decision without delay, as kidney function may also be impaired in a short time. Based on EAU and ESPU 2019 Guidelines on pediatric urology, surgical indications for UPJHN are impaired renal function (<40%), significant renal functional decrease (>10%) in control scans, poor drainage after furosemide injection, increased AP diameter, and SFU-III/IV (8, 26). Although there are problems

with some of these indications, absolute surgical indications in the follow-up of UPJHN cases can be considered as renal parenchymal thinning (<3 mm), contralateral kidney balancing hypertrophy and decreased kidney function. Differential renal uptake on diuretic renography <30% in unilateral cases and <35% in bilateral cases is usually required a surgical intervention. Surgical treatment can also be recommended in children whose SFU3 hydronephrosis continues for 3 years and develops compensated hypertrophy in the contralateral kidney (27). If the main goal during conservative monitoring is to protect the child from the risk of permanent kidney damage, waiting for ultrasonographic or functional deterioration is a cornerstone that must be distinguished very carefully in each case. It should be noted that at this cornerstone, the presence of symptoms such as recurrent UTI, hematuria, kidney stones or pain will speed up the decision of surgical intervention (21, 26, 27).

As mentioned above, the clinical picture of UPJHN should be evaluated in two different categories, considering that most cases are asymptomatic and diagnosed on routine prenatal US screening; (a) asymptomatic infants who are usually managed conservatively (b) children who present at an older ages with urinary symptoms or as a result of incidental findings during the analysis of unrelated problems.

INFANTS WITH PRENATAL DIAGNOSIS

Symptomatology in a newborn with antenatally diagnosed UPJHN is usually the absence of symptoms. However, the most frequent symptom of UPJHN in neonates and infants was a palpable flank mass in the past. Most of the abdominal masses encountered in the neonatal period are related to hydronephrotic kidneys. Therefore, a palpable abdominal mass may be the first finding to be considered in a physical examination in a newborn with UPJHN.

Since UPJHN is often associated with other congenital anomalies, including imperforated anus, contralateral multicystic kidney, congenital heart disease, VATER syndrome, and esophageal atresia, in a newborn with established prenatal diagnosis, a thorough examination of all systems should be performed (8). Occasionally, UPJHN can also be diagnosed during extended diagnostics of other congenital abnormalities. On the other hand, in all children with a diagnosis of urinary tract infection (UTI) within the early neonatal period, urinary tract obstruction, UPJHN should also be considered.

Urinary Tract Infection

Children with UPJHN and impaired urinary drainage are considered to be prone to severe UTIs (28, 29). Although UTI is an uncommon presentation in UPJHN cases with an incidence of 1.3–12%, it may be quite severe requiring urgent intervention and drainage (4, 30–35). Previous reports suggest that the risk of UTI increases with the degree of hydronephrosis, and patients with high-grade hydronephrosis have significantly higher UTI rates than those with mild hydronephrosis (13.8 vs. 4.1%) (36–39). Although the studies are not standardized in terms of the use of prophylactic antibiotics, the method of detecting infection or the selection of patients for VCUG, it has

been clearly demonstrated that patients with mild or moderate hydronephrosis are at much lower risk of significant UTI than patients with severe hydronephrosis.

When a child with UPJHN applies with a febrile UTI, the possibility of associated VUR is an important issue to consider. Based on the fact that some studies show one-third of cases having a VUR (8, 40, 41); VCUG is often favored by European guidelines for all children with UPJO (42, 43). Before deciding to apply VCUG, an invasive procedure with radiation exposure in UPJHN patients, it should be taken into account that in many cases that are often asymptomatic, VUR may improve over time and the concept of benefit-harm to the patient (44–46).

Madden et al. (47) performed VCUG in more than 80% of their patients with UPJHN and in no case detected VUR. In the same study, it was reported that patients who did not undergo VCUG remained asymptomatic and no imaging was required except for follow-up ultrasounds (47). Given the low rate of UTI reported, it may be considered that antibiotic prophylaxis has a limited role in the management of such patients (13, 47–49), and VCUG screening is considered to be optional (50). However, more aggressive evaluation and intervention, including antibiotic prophylaxis and VCUG are often indicated in those with worsening or high-grade hydronephrosis (47, 51–53). It should be noted that the presence of ureter dilatation is also important to suspect VUR even in severe hydronephrosis cases.

Another issue that can be considered for the prevention UTI in boys with UPJHN may be circumcision. Ellison et al. (54) reported that the risk of UTI in boys with UPJHN decreased significantly when circumcised. Although there may be no direct relationship since the stasis is in renal pelvis away from the external urethral meatus, in clinical practice, circumcision may be recommended for infant boys who have UTI history.

CHILDREN WITHOUT PRENATAL DIAGNOSIS

Unlike asymptomatic presentation early in life, older children with UPJHN are often diagnosed due to their specific or non-specific symptoms. A carefully gathered clinical history played a very important role in the diagnosis of patients with UPJHN. These symptoms are usually febrile UTIs, a palpable mass, or unexplained abdominal or flank pain. In addition, UPJHN can be detected during evaluation of stone disease and sudden onset hypertension (8). Another small group ordered for a completely unrelated issue during imaging is diagnosed by chance.

Pain

In children with UPJHN/UPJO, pain is primarily the result of dilation, stretching and spasm of the urinary tract, when the urine flow exceeds the capacity to drain properly. The causes of pain are generally muscle spasm, increased proximal peristalsis, local inflammation, irritation and edema at the site of obstruction. It develops through chemoreceptor activation and stretching of the submucosal free nerve endings. The severity of pain depends on the individual's pain threshold and perception, and on the speed and degree of changes in hydrostatic pressure within the

proximal ureter and renal pelvis. Chronic severe obstruction usually does not cause pain.

Although it is generally thought to have gastrointestinal symptoms, It should be noted that attacks of unexplained recurrent vomiting or abdominal discomfort may be associated with UPJ obstruction in infants (55). Sudden onset of severe abdominal pain, nausea, and vomiting, often in the late evening, is typical in older children with UPJO. This colicky-type pain usually begins in the upper lateral midback over the costovertebral angle and occasionally subcostally. It radiates inferiorly and anteriorly toward the groin. At their initial presentation, this symptomatology is far more common than febrile urinary tract infections or hematuria (8, 56). Pain along with increased diuresis should also raise the level of suspicion for an obstructive process. This usually occurs in children who receive a diuretic challenge during a furosemide renal scan.

It is important to recognize that patients with extrinsic anatomic abnormalities (e.g., lower pole crossing vessels) can present with colicky flank pain, which is sometimes associated with vomiting, and may present misleadingly unremarkable test results during their asymptomatic periods (56, 57). There is no history of hydronephrosis in the neonatal period In 75–100% of children with crossing vessels (57–59). The incidence of colicky pain in pure extrinsic UPJHN has been reported as 71.8–100%, increasing with age (57–59). The average age of patients with a crossing vessel is between 7 and 11 years and is statistically higher than in patients with pure intrinsic obstruction (58–61). An ultrasonography performed in the symptomatic period can prevent delay in diagnosis of extrinsic UPJHN due to crossing vessel.

Urinary Stone Disease

Hydronephrosis is considered as a risk factor for stone formation in children. Although the etiology of stone formation does not depend solely on the pelvicaliceal anatomy, impaired urinary drainage, decreased or abnormal peristalsis, increased urine transit times and larger pelvicaliceal volumes play a subtle role during the beginning of the nucleation process in UPJHN patients with nephro/urolithiasis (62) (**Figure 1**).

Hypertension

Published pediatric reports of hypertension obviously caused by hydronephrosis are few, and the numbers of patients included in these reports are very low (63–68). On clinical basis, the number of cases diagnosed with UPJHN/UPJO by referring to the results or symptoms of high blood pressure in the child age group is very few. While the development of clinically significant hypertension or proteinuria is very rare in patients with unilateral hydronephrosis, the same is not the case for bilateral disease (8, 63). Depending on the onset, level, and degree of obstruction as well as the presence of renal parenchymal damage or dysplasia, hypertension may develop during the follow-up.

It has been demonstrated that the function of the hydronephrotic kidney is rather well-preserved in young children, therefore it appears that the intrarenal mechanism leading to hypertension is also reversible (6, 11). The clinical importance of such finding is that surgical management may

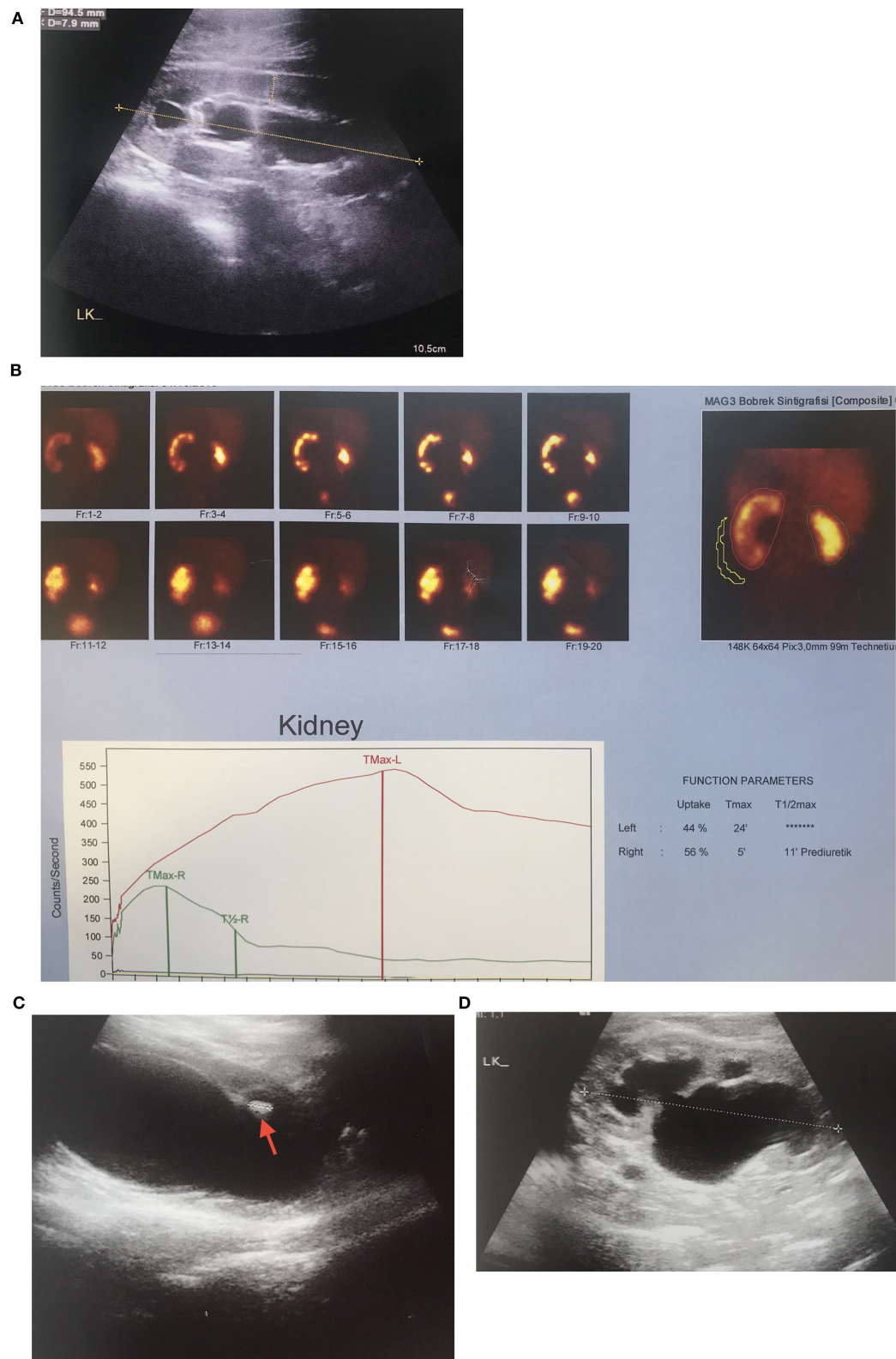


FIGURE 1 | UPJHN in 3 months-old boy with prenatally detected left hydronephrosis **(A)** Severe hydronephrosis with 2.4 mm paranchymal thickness and 22 mm in AP diameter of pelvis renalis **(B)** Left obstructive hydronephrosis with 44% of differential function on MAG 3 scintigraphy **(C)** Mobile hyperechogenic particles in renal pelvis and calyces, hyperechogenicity in the lower calyces which are suggested urinary stone formation **(D)** Mild hydronephrosis with 8 mm paranchymal thickness and 16 mm in AP diameter of pelvis renalis in 9 years after left pyeloplasty.

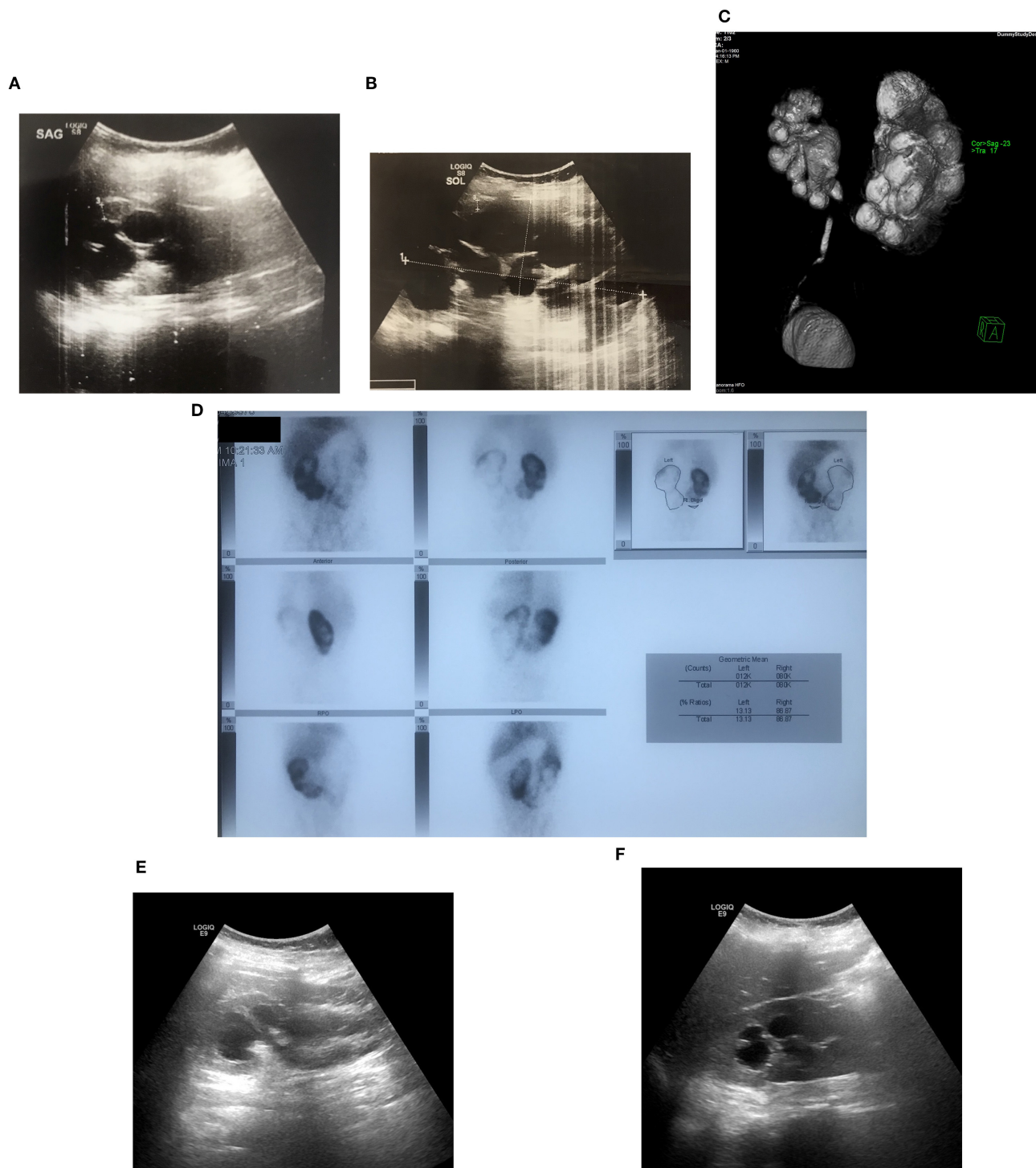


FIGURE 2 | Bilateral UPJHN in 12 years-old boy with prenatally detected bilateral hydronephrosis with no follow-up who presented with severe hypertension and high serum creatinine (1.6 mg/dl) **(A,B)** pre-operative US images showing right and left severe hydronephrosis **(C)** Severe renal parenchymal loss on left kidney with 13% of differential function on DMSA scintigraphy **(D)** bilateral obstructive UPJ type hydronephrosis shown by MR urography **(E,F)** post-operative (bilaterally pyeloplasty) US image showing a resolution of left and right hydronephrosis, which was followed by resolution serum creatinine (0.67 mg/dl) and hypertension.

prevent the development of chronic hypertension and associated comorbidities in patients with severe hydronephrosis (68–70). The pediatric urologist and nephrologist may have to pay more attention to the risk of development of high blood pressure in patients with severe hydronephrosis (Figure 2).

CONCLUSION

Current management approach for most children with UPJHN is often considered conservative follow-up because hydronephrosis associated with UPJ anomalies can safely improve over the time. However, it is clear that delayed decision making in the case of obstructive hydronephrosis, which requires surgical intervention, leads to impaired kidney function and long-term morbidity.

REFERENCES

- Thomas DFM. Prenatal diagnosis: what do we know of long term outcomes? *J Pediatr Urol.* (2010) 6:204–11. doi: 10.1016/j.jpuro.2010.01.013
- Woodward M, Frank D. Postnatal management of antenatal hydronephrosis. *BJU Int.* (2002) 89:149–56. doi: 10.1046/j.1464-4096.2001.woodward.2578.x
- Nguyen HT, Benson CB, Bromley B, Campbell JB, Chow J, Coleman B, et al. Multidisciplinary consensus on the classification of prenatal and postnatal urinary tract dilation (UTD classification system). *J Pediatr Urol.* (2014) 10:982–99. doi: 10.1016/j.jpuro.2014.10.002
- Passerotti CC, Kalish LA, Chow J, Passerotti AM, Recabal P, Cendron M, et al. The predictive value of the first postnatal ultrasound in children with antenatal hydronephrosis. *J Pediatr Urol.* (2011) 7:128–36. doi: 10.1016/j.jpuro.2010.09.007
- Whitaker RH. Some observations and theories on the wide ureter and hydronephrosis. *Br J Urol.* (1975) 47:377–85. doi: 10.1111/j.1464-410X.1975.tb03990.x
- Koff SA. Requirements for accurately diagnosing chronic partial upper urinary tract obstruction in children with hydronephrosis. *Pediatr Radiol.* (2008) 38 (Suppl. 1):S41–8. doi: 10.1007/s00247-007-0590-2
- Chevalier RL, Chung KH, Smith CD, Ficenec M, Gomez RA. Renal apoptosis and clusterin following ureteral obstruction: the role of maturation. *J Urol.* (1996) 156:1474–9. doi: 10.1097/00005392-199610000-00075
- Lorenzo AJ, Csaicsich D, Aufricht C, Khoury AE. *Obstructive Genitourinary Disorders.* Elsevier BV (2008). doi: 10.1016/B978-0-323-04883-5.50043-X
- Elder JS. Antenatal hydronephrosis. Fetal and neonatal management. *Pediatr Clin North Am.* (1997) 44:1299–321. doi: 10.1016/S0031-3955(05)70558-7
- Reddy PP, Mandell J. Prenatal diagnosis. Therapeutic implications. *Urol Clin North Am.* (1998) 25:171–80. doi: 10.1016/S0094-0143(05)70005-7
- Ulman I, Jayanthi V, and Koff SA. The longterm follow-up of newborns with severe unilateral hydronephrosis managed nonoperatively. *J Urol.* (2000) 164 (3 pt 2):1101–5. doi: 10.1097/00005392-200009020-00046
- Ransley PG, Dhillon HK, Gordon I, Duffy PG, Dillon MJ, Barrat TM. The postnatal management of hydronephrosis diagnosed by prenatal ultrasound. *J Urol.* (1990) 144:584–7. doi: 10.1016/S0022-5347(17)39528-9
- Nguyen HT, Herndon CD, Cooper C, Gatti J, Kirsch A, Kokorowski P, et al. The Society for fetal urology consensus statement on the evaluation and management of antenatal hydronephrosis. *J Pediatr Urol.* (2010) 6:212–31. doi: 10.1016/j.jpuro.2010.02.205
- Keays MA, Guerra LA, Mihill J, Raju G, Al-Asheeri NA, Pike J, et al. Reliability assessment of society for fetal urology ultrasound grading system for hydronephrosis. *J Urol.* (2008) 180:1680–2; discussion 1682–3. doi: 10.1016/j.juro.2008.03.107
- Herndon A. Antenatal hydronephrosis: differential diagnosis, evaluation, and treatment options. *ScientificWorld J.* (2006) 6:2345–65. doi: 10.1100/tsw.2006.366
- Onen A. Treatment and outcome of prenatally detected newborn hydronephrosis. *J Pediatr Urol.* (2007) 3:469–76. doi: 10.1016/j.jpuro.2007.05.002
- King L. Fetal hydronephrosis: what is the urologist to do? *Urology.* (1993) 42:229–31. doi: 10.1016/0090-4295(93)90609-E
- Koff SA. Postnatal management of antenatal hydronephrosis using an observational approach. *Urology.* (2000) 55:609–11. doi: 10.1016/S0090-4295(00)00459-3
- Perez L, Friedman R, King L. The case for relief of ureteropelvic junction in neonates and young children at time of diagnosis. *Urology.* (1991) 38:195–201. doi: 10.1016/S0090-4295(91)80343-6
- Weitz M, Schmidt M, Laube G. Primary non surgical management of unilateral ureteropelvic junction obstruction in children: a systematic review. *Pediatr Nephrol.* (2017) 32:2203–13. doi: 10.1007/s00467-016-3566-3
- Braga LH, Ruzhynsky V, Pemberton J, Farrokhhyar F, Demeira J, Lorenzo AJ. Evaluating practice patterns in postnatal management of antenatal hydronephrosis: a national survey of Canadian pediatric urologists and nephrologists. *Urology.* (2014) 83:909–14. doi: 10.1016/j.urol.2013.10.054
- Williams B, Tareen B, Resnick MI. Pathophysiology and treatment of ureteropelvic junction obstruction. *Curr Urol Rep.* (2007) 8:111–7. doi: 10.1007/s11934-007-0059-8
- Ingraham SE, McHugh KM. Current perspectives on congenital obstructive nephropathy. *Pediatr Nephrol.* (2011) 26:1453–61. doi: 10.1007/s00467-011-1799-8
- Chertin B, Rolle U, Farkas A, Puri P. Does delaying pyeloplasty affect renal function in children with prenatal diagnosis of pelvi-ureteric junction obstruction? *BJU Int.* (2002) 90:72–5. doi: 10.1046/j.1464-410X.2002.02829.x
- Onen A, Jayanthi VR, Koff SA. Long-term follow-up of prenatally detected severe bilateral newborn hydronephrosis initially managed non operatively. *J Urol.* (2002) 168:1118–20. doi: 10.1016/S0022-5347(05)64604-6
- Radmayr C, Bogaert G, Dogan HS, Kocvara R, Nijman JM, Stein R, et al. *EAU Guidelines on Pediatric Urology.* European Society for Paediatric Urology and European Association of Urology (2020). p. 59–61. Arnhem: EAU Guidelines Office. Available online at: <http://uroweb.org/guidelines/compilations-of-all-guidelines/>
- Onen A. Grading of hydronephrosis: an ongoing challenge. *Front. Pediatr.* (2020). doi: 10.3389/fped.2020.00458

28. Riccabona M, Sorantin E, Hausegger K. Imaging guided interventional procedures in pediatric urology- a case based overview. *Eur J Radiol.* (2002) 43:167–79. doi: 10.1016/S0720-048X(02)00110-9
29. Khan A, Jhaveri R, Seed PC, Arshad M. Update on associated risk factors, diagnosis, and management of recurrent urinary tract infections in children. *J Pediatric Infect Dis Soc.* (2019) 8:152–9. doi: 10.1093/jpids/piy065
30. Yang Y, Hou Y, Niu ZB, Wang CL. Long-term follow-up and management of prenatally detected, isolated hydronephrosis. *J Pediatr Surg.* (2010) 45:1701–6. doi: 10.1016/j.jpedsurg.2010.03.030
31. Sidhu G, Beyene J, Rosenblum ND. Outcome of isolated antenatal hydronephrosis: a systematic review and meta-analysis. *Pediatr Nephrol.* (2006) 21:218–24. doi: 10.1007/s00467-005-2100-9
32. Lee RS, Cendron M, Kinnamond DD, Nguyen HT. Antenatal hydronephrosis as a predictor of postnatal outcome: a meta-analysis. *Pediatrics.* (2006) 118:586–93. doi: 10.1542/peds.2006-0120
33. Tombesi MM, Alconcher LF. Short-term outcome of mild isolated antenatal hydronephrosis conservatively managed. *J Pediatr Urol.* (2012) 8:129–33. doi: 10.1016/j.jpuro.2011.06.009
34. Estrada CR, Peters CA, Retik AB, Nguyen HT. Vesicoureteral reflux and urinary tract infection in children with a history of prenatal hydronephrosis—should voiding cystourethrography be performed in cases of postnatally persistent grade II hydronephrosis? *J Urol.* (2009) 181:801–6; discussion 806–7. doi: 10.1016/j.juro.2008.10.057
35. Coelho GM, Bouzada MC, Lemos GS, Pereira AK, Lima BP, Oliveira EA. Risk factors for urinary tract infection in children with prenatal renal pelvic dilatation. *J Urol.* (2008) 179:284–9. doi: 10.1016/j.juro.2007.08.159
36. Timberlake MD, Herdorn A. Mild to moderate postnatal hydronephrosis-grading systems and management. *Nat Rev Urol.* (2013) 10:649–56. doi: 10.1038/nrurol.2013.172
37. Coelho GM, Bouzada MC, Pereira AK, Figueiredo BF, Leite MR, Oliveira DS, et al. Outcome of isolated antenatal hydronephrosis: a prospective cohort study. *Pediatr Nephrol.* (2007) 22:1727–34. doi: 10.1007/s00467-007-0539-6
38. Szymanski KM, Al-Said AN, Pippi Salle JL, Capolicchio JP. Do infants with mild prenatal hydronephrosis benefit from screening for vesicoureteral reflux? *J Urol.* (2012) 188:576–81. doi: 10.1016/j.juro.2012.04.017
39. Stein R, Dogan HS, Hoebeke P, Kočvara R, Nijman RJ, Radmayr C, et al. European association of urology; european society for pediatric urology. *Eur Urol.* (2015) 67:546–58. doi: 10.1016/j.euro.2014.11.007
40. Woo HH, Farnsworth RH. Vesico-ureteric reflux and surgically treated pelvi-ureteric junction obstruction in infants under the age of 12 months. *Aust N Z J Surg.* (1996) 66:824–5. doi: 10.1111/j.1445-2197.1996.tb00758.x
41. Perrelli L, Calisti A, Pintus C, D'Errico G. Management of pelviureteric junction obstruction in the first six months of life. *Z Kinderchir.* (1985) 40:158–62. doi: 10.1055/s-2008-1059736
42. Beetz R, Bokenkamp A, Brandis M, Hoyer P, John U, Kemper MJ, et al. Diagnosis of congenital dilatation of the urinary tract. Consensus Group of the Pediatric Nephrology Working Society in cooperation with the pediatric urology working Group of the German Society of urology and with the pediatric urology working Society in the Germany Society of pediatric surgery. *Urologe A.* (2001) 40:495–507; quiz 508–499. doi: 10.1007/s001200170015
43. Silay MS, Undre S, Nambiar AK, Dogan HS, Kocvara R, Nijman RJM, et al. Role of antibiotic prophylaxis in antenatal hydronephrosis: a systematic review from the European Association of Urology/European Society for Paediatric Urology Guidelines Panel. *J Pediatr Urol.* (2017) 13:306–15. doi: 10.1016/j.jpuro.2017.02.023
44. Weitz M, Schmidt M. To screen or not to screen for vesicoureteral reflux in children with ureteropelvic junction obstruction: a systematic review. *Eur J Pediatr.* (2017) 176:1–9. doi: 10.1007/s00431-016-2818-3
45. Williams G, Fletcher JT, Alexander SI, Craig JC. Vesicoureteral Reflux. *J Am Soc Nephrol.* (2008) 19:847–62. doi: 10.1681/ASN.2007020245
46. Stratton KL, Pope JC, Adams MC, Brock JW III, Thomas JC. Implications of ionizing radiation in the pediatric urology patient. *J Urol.* (2010) 183:2137–42. doi: 10.1016/j.juro.2010.02.2384
47. Madden JM, Wiener JS, Routh JC, Ross SS. Resolution rate of isolated low-grade hydronephrosis diagnosed within the first year of life. *J Pediatr Urol.* (2014) 10:639–44. doi: 10.1016/j.jpuro.2014.07.004
48. Lee JH, Choi HS, Kim JK, Won HS, Kim KS, Moon DH, et al. Nonrefluxing neonatal hydronephrosis and the risk of urinary tract infection. *J Urol.* (2008) 179:1524–8. doi: 10.1016/j.juro.2007.11.090
49. Skoog SJ, Peters CA, Arant BS Jr, Copp HL, Elder JS, Hudson RG, et al. Pediatric vesicoureteral reflux guidelines panel summary report: clinical practice guidelines for screening siblings of children with vesicoureteral reflux and neonates/infants with prenatal hydronephrosis. *J Urol.* (2010) 184:1145–51. doi: 10.1016/j.juro.2010.05.066
50. Nicolau N, Renkema KY, Bongers EM, Giles RH, Knoers NV. Genetic, environmental and epigenetic factors involved in CAKUT. *Nat Rev Nephrol.* (2015) 11:720–31. doi: 10.1038/nrneph.2015.140
51. Shaikh N, Ewing AL, Bhatnagar S, Hoberman A. Risk of renal scarring in children with a first urinary tract infection: a systematic review. *Pediatrics.* (2010) 126:1084–91. doi: 10.1542/peds.2010-0685
52. Zanetta VC, Rosman BM, Bromley B, Shipp TD, Chow JS, Campbell JB, et al. Variations in management of mild prenatal hydronephrosis among maternal-fetal medicine obstetricians, and pediatric urologists and radiologists. *J Urol.* (2012) 188:1935–9. doi: 10.1016/j.juro.2012.07.011
53. Docimo SG, Silver RL. Renal ultrasonography in newborns with prenatally detected hydronephrosis: why wait? *J Urol.* (1997) 157:1387–9. doi: 10.1016/S0022-5347(01)64996-6
54. Ellison JS, Geolani W, Fu BC, Holt SK, Gore JL, Merguerian PA. Neonatal circumcision and urinary tract infections in infants with hydronephrosis. *Pediatrics.* (2018) 142:1–7. doi: 10.1542/peds.2017-3703
55. Mergener K, Weinerth JL, Baillie J. Diet's crisis: a syndrome of episodic abdominal pain of urologic origin that may present to gastroenterologist. *Am J Gastroenterol.* (1997) 92:2289–91.
56. Cain MP, Rink RC, Thomas AC, Austin PF, Kaefer M, Casale AJ. Symptomatic ureteropelvic junction obstruction in children in the era of prenatal sonography- is there a higher incidence of crossing vessels? *Urology.* (2001) 57:338–41. doi: 10.1016/S0090-4295(00)00995-X
57. Polok M, Toczewski K, Borselle D, Apoznanski W, Jedrzejuk D, Patkowski D. Hydronephrosis in children caused by lower pole crossing vessels—how to choose the proper method of treatment? *Front Pediatr.* (2019) 7:1–4. doi: 10.3389/fped.2019.00083
58. Esposito C, Blevé C, Escolino M, Caione P, Gerocarni Nappo S, Farina A, et al. Laparoscopic transposition of lower pole crossing vessels (vascular hitch) in children with pelviureteric junction obstruction. *Transl Pediatr.* (2016) 5:256–61. doi: 10.21037/tp.2016.09.08
59. Weiss D, Kadakia S, Kurzweil R, Srinivasan A, Darge K, Shukla A. Detection of crossing vessels in pediatric ureteropelvic junction obstruction: clinical patterns and imaging findings. *J Pediatr Urol.* (2015) 11:173.e1–5. doi: 10.1016/j.jpuro.2015.04.017
60. Chiarenza S, Blevé C, Fasoli L, Battaglini F, Bucci V, Novek S, et al. Ureteropelvic junction obstruction in children by polar vessels. Is laparoscopic vascular hitching procedure a good solution? Single center experience on 35 consecutive patients. *J Pediatr Surg.* (2016) 51:310–4. doi: 10.1016/j.jpedsurg.2015.10.005
61. Schneider A, Ferreira CG, Delay C, Lacreuse I, Moog R, Becmeur F. Lower pole vessels in children with pelviureteric junction obstruction: laparoscopic vascular hitch or dismembered pyeloplasty? *J Pediatr Urol.* (2013) 9:419–23. doi: 10.1016/j.jpuro.2012.07.005
62. Khan SR, Pearle MS, Robertson WG, Gambaro G, Canales BK, Doizi S, et al. Kidney Stones. *Nat Rev Dis Primers.* (2016) 2:16008. doi: 10.1038/nrdp.2016.8
63. Farnham SB, Adams MC, Brock JW, Pope JC. Pediatric urological causes of hypertension. *J Urol.* (2005) 173:697–704. doi: 10.1097/01.ju.0000153713.46735.98
64. Abramson M, Jackson B. Hypertension and unilateral hydronephrosis. *J Urol.* (1984) 132:746–8. doi: 10.1016/S0022-5347(17)49855-7
65. Wanner C, Luscher TF, Schollmeyer P, Vetter W. Unilateral hydronephrosis and hypertension: cause or coincidence? *Nephron.* (1987) 45:236–41. doi: 10.1159/000184125
66. Carlström M, Wählin N, Sällström J, Skott O, Brown R, Persson AE. Hydronephrosis causes salt-sensitive hypertension in rats. *J Hypertens.* (2006) 24:1437–43. doi: 10.1097/01.hjh.0000234126.78766.00
67. Mizuiri S, Amagasaki Y, Hosaka H, Fukasawa K, Nakayama K, Nakamura N, et al. Hypertension in unilateral atrophic kidney secondary to ureteropelvic junction obstruction. *Nephron.* (1992) 61:217–9. doi: 10.1159/000186876

68. Chalisey A, Karim M. Hypertension and hydronephrosis: rapid resolution of high blood pressure following relief of bilateral ureteric obstruction. *J Gen Intern Med.* (2013) 28:478–81. doi: 10.1007/s11606-012-2183-5
69. Al-Mashhadi A, Häggman M, Läckgren G, Ladjevardi S, Nevéus T, Stenberg A, et al. Changes of arterial pressure following relief of obstruction in adults with hydronephrosis. *Ups J Med Sci.* (2018) 123:216–24. doi: 10.1080/03009734.2018.1521890
70. de Waard D, Dik P, Lilien MR, Kok ET, de Jong TP. Hypertension is an indication for surgery in children with ureteropelvic junction obstruction. *J Urol.* (2008) 179:1976–8; discussion 1978–9. doi: 10.1016/j.juro.2008.01.058

Conflict of Interest: The author declares that the research was conducted in the absence of any commercial or financial relationships that could be construed as a potential conflict of interest.

Copyright © 2020 Bilge. This is an open-access article distributed under the terms of the Creative Commons Attribution License (CC BY). The use, distribution or reproduction in other forums is permitted, provided the original author(s) and the copyright owner(s) are credited and that the original publication in this journal is cited, in accordance with accepted academic practice. No use, distribution or reproduction is permitted which does not comply with these terms.



Redo Laparoscopic Pyeloplasty in Infants and Children: Feasible and Effective

Hamdan Al-Hazmi^{1,2†}, Matthieu Peycelon^{1,3,4†}, Elisabeth Carricaburu^{1,3}, Gianantonio Manzoni^{1,5}, Khalid Fouda Neel^{1,2}, Liza Ali^{1,3}, Christine Grapin^{1,3,4}, Annabel Paye-Jaouen^{1,3} and Alaa El-Ghoneimi^{1,3,4*}

OPEN ACCESS

Edited by:

Luis Henrique Braga,
McMaster University, Canada

Reviewed by:

Baran Tokar,
Eskişehir Osmangazi University, Turkey
Pedro-José Lopez,
Universidad del Desarrollo, Chile
Lisandro Ariel Piaggio,
Universidad Nacional del
Sur, Argentina

*Correspondence:

Alaa El-Ghoneimi
alaa.elghoneimi@aphp.fr

[†]These authors have contributed
equally to this work and share first
authorship

Specialty section:

This article was submitted to
Pediatric Urology,
a section of the journal
Frontiers in Pediatrics

Received: 29 March 2020

Accepted: 12 August 2020

Published: 10 November 2020

Citation:

Al-Hazmi H, Peycelon M,
Carricaburu E, Manzoni G, Neel KF,
Ali L, Grapin C, Paye-Jaouen A and
El-Ghoneimi A (2020) Redo
Laparoscopic Pyeloplasty in Infants
and Children: Feasible and Effective.
Front. Pediatr. 8:546741.
doi: 10.3389/fped.2020.546741

¹ Department of Pediatric Urology, Robert-Debré University Hospital, Assistance Publique - Hôpitaux de Paris (APHP), Paris, France, ² College of Medicine and King Saud University Medical City, King Saud University, Riyadh, Saudi Arabia, ³ National Reference Center of Rare Urinary Tract Malformations (MARVU), Paris, France, ⁴ University of Paris, Paris, France, ⁵ Department of Pediatric Urology Fondazione Cà Granda Ospedale Maggiore Policlinico, Milan, Italy

Purpose: To determine the feasibility and effectiveness of redo laparoscopic pyeloplasty among patients with failed previous pyeloplasty, specifically examining rates of success and complications.

Materials and Methods: We retrospectively reviewed the charts of all patients, who underwent redo laparoscopic pyeloplasty from 2006 to 2017. This included patients who underwent primary pyeloplasty at our institution and those referred for failures. Analysis included demographics, operative time, complications, length of hospital stay, complications, and success. Success was defined as improvement of symptoms and hydronephrosis and/or improvement in drainage demonstrated by diuretic renogram, especially in those with persistent hydronephrosis. Descriptive statistics are presented.

Results: We identified 22 patients who underwent redo laparoscopic pyeloplasty. All had Anderson-Hynes technique except two cases in which ureterocalicostomy was performed. Median (IQR) follow-up was 29 (2–120) months, median time between primary pyeloplasty and redo laparoscopic pyeloplasty was 12 (7–49) months. The median operative time was 200 (50–250) min, and median length of hospital stay was 3 (2–10) days. The procedure was feasible in all cases without conversion. During follow-up, all but two patients demonstrated an improvement in the symptoms and the degree of hydronephrosis. Ninety-one percent of patients experienced success and no major complications were noted.

Conclusions: Redo laparoscopic pyeloplasty is feasible and effective with a high success rate and low complication rate.

Keywords: redo laparoscopic pyeloplasty, uretero-pelvic junction obstruction, open pyeloplasty, minimally invasive surgical procedures, children

INTRODUCTION

Secondary uretero-pelvic junction obstruction (UPJO) may occur following pyeloplasty in up to 11% of patients who may require redo surgical intervention (1). Redo surgical intervention (open, laparoscopic, or robotic) has been shown to be more effective than endourological procedures (JJ stent insertion, balloon dilatation, and endopyelotomy) (2, 3). Laparoscopic and robotic redo pyeloplasty are alternatives to redo open pyeloplasty (ROP), which have been reported with good success (2, 4, 5).

Redo laparoscopic pyeloplasty (RLP) offers a minimally invasive approach with the benefits of a shorter period of convalescence and decreased morbidity compared to open surgery; however, it requires advanced laparoscopic skills (6). Herein, we report our outcomes with redo laparoscopic pyeloplasty to determine the feasibility and effectiveness of this procedure in a relatively large case series. And our hypothesis was: do infants and children with persistent UPJO undergoing redo laparoscopic pyeloplasty have the same overall success rate in comparison to the ones reported in open redo pyeloplasty series?

MATERIALS AND METHODS

Patient Selection and Study Design

After obtaining ethical board approval for conduct of the study, we retrospectively reviewed the charts of all patients who underwent laparoscopic pyeloplasty for secondary UPJO at a single institution, University Hospital of Robert-Debré, Paris, France, from December 2006 to October 2017. Inclusion criteria were all patients with persistent UPJO undergoing redo transperitoneal laparoscopic pyeloplasty at our institution regardless of if their primary pyeloplasty was performed at our institution or elsewhere. Exclusion criteria were: primary UPJO repair or any redo pyeloplasty performed by an open, retroperitoneal laparoscopic or robot-assisted approach.

Variables and Outcome Measures

Variables collected from the reviewed charts included: patient sex, age at primary surgery and redo surgery; type of previous interventions and number of attempts to repair the UPJO; confirmation of persistent UPJO following initial surgery, both clinically and radiologically (renal ultrasound, dynamic renal scintigraphy (MAG-3) and/or magnetic resonance urography (MRU); indication for redo pyeloplasty; use of stents and drains; length of hospitalization; postoperative complications; need for readmission and subsequent procedures; and success rate.

Indications for redo laparoscopic pyeloplasty were persistent severe hydronephrosis (defined as (1) AP diameter > 30 mm or (2) AP diameter > 15 mm and flank pain or (3) AP diameter > 15 mm and other US criteria (calyceal dilation, thin parenchyma)) associated with at least one of the following:

Abbreviations: APD, Anteroposterior diameter; IQR, Interquartile; Kg, kilogram; MCUG, Micturating cysto-urethrogram; MRU, Magnetic resonance urography; OP, Open pyeloplasty; PP, Primary pyeloplasty; RLP, Redo laparoscopic pyeloplasty; ROP, Redo open pyeloplasty; UPJ, Uretero-pelvic junction; UPJO, Uretero-pelvic junction obstruction; UTI, Urinary tract infection.

repeated febrile urinary tract infection (UTI) documented by positive urine culture, flank pain, and persistence obstruction on retro or ante grade imaging (retrograde pyelography, renal scintigraphy, MRU). Surgical complications were classified according to the Clavien-Dindo classification (7). Febrile UTIs included both a fever and a urine cultures with >100,000 colony forming units.

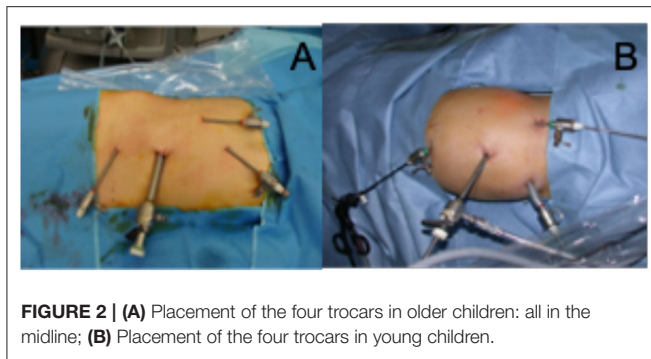
Follow-up evaluation was performed using renal ultrasound and dynamic renal scintigraphy. Success defined as improvement of symptoms (neither UTI, nor flank pain) and decrease of hydronephrosis, determined by the measurement of post-operative anteroposterior diameter (APD, in millimeters) and/or the absence of calyceal dilation. In patients with persistent hydronephrosis, an absence of obstruction on the drainage curve on functional imaging (defined as a $t_{1/2}$ <20 min on nuclear scan) was used to define success. A single dedicated radiologist was not available to perform all follow-up imaging.

Surgical Details

The surgery was performed by staff pediatric urologists. A transperitoneal approach was used for all patients undergoing redo laparoscopic pyeloplasty. The patient was positioned in the supine position with an inflatable device under the flank of the operated side. The surgeon stood on the opposite side of the obstructed kidney (**Figure 1**), and all ports were inserted with the child in the supine position. Four ports were used for all patients (**Figure 2**), namely a 5-mm umbilical port by open access for the camera; and insufflation was maintained at 10 mm Hg. Then two 3-mm working ports were inserted under direct vision, one midway between the xiphoid process and umbilicus and the other midway between the symphysis pubis and the umbilicus, and the fourth accessory trocar, 3-mm, in the ipsilateral iliac fossa. The fourth was used to help to reduce the operative time for suction and exposition. There was some modification in the placing of trocars between young and older children (**Figures 2A,B**). A 45° lateral position was obtained by inflating the device. The

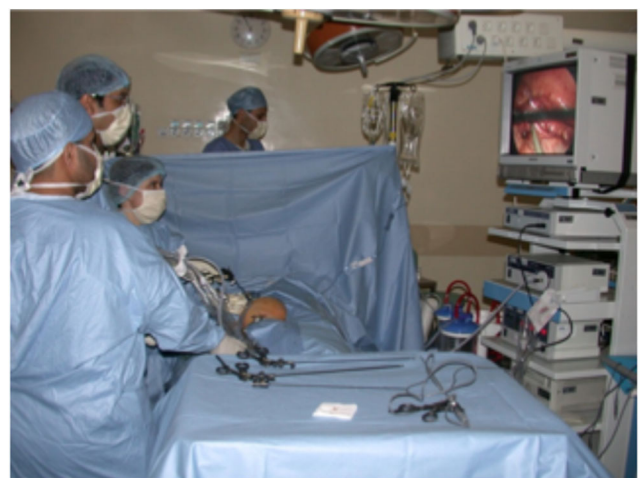

FIGURE 1 | Position of the surgeon and all assistants.



colon was mobilized to expose the renal pelvis after removing all the adhesions until the UPJ was identified. The reason for the failure of previous surgery was identified. All patients underwent Anderson-Hynes dismembered pyeloplasty except two cases in which ureterocalicostomy was performed because the renal pelvis was intrarenal and difficult to identify due to severe fibrosis from the prior surgery, one of them had already failed redo robotic pyeloplasty elsewhere. Continuous suture was used for the anastomosis in all patients except one in whom interrupted suturing was required due to a thick-walled renal pelvis and signs of inflammation. We used a 5-0 Polyglactin suture for all patients. A JJ stent was placed in an antegrade fashion in all cases except one who had trouble in passing the JJ stent through the ureterovesical junction, so an externalized stent was placed instead (Multipurpose stent, BARD®, Salt Lake City, UT). A Foley catheter was placed and left until day 1 postoperatively.

All patients were followed-up clinically for pain or UTI, and radiologically by renal ultrasound (four times the 1st year, then twice the next year and finally once a year for 5 years). An isotopic renal scan or MRU was obtained in the setting of persistent severe hydronephrosis. The choice to use either an isotopic renal scan or a MRU was done on the functional imaging studies used for the preoperative evaluation.

Descriptive statistics were performed with SPSSV20 software (IBM SPSS Statistics, IBM Corp, Armonk, NY).

RESULTS

Twenty-two patients (four girls and 18 boys) underwent laparoscopic pyeloplasty for persistent UPJO during the study period. Thirteen patients (59.1%) were referred from an outside hospital after failed pyeloplasty. Median age at initial surgery was 8 months (IQR: 3–48). Surgery was performed on the right side in 10 patients and the left in 12 patients. Pre-operative micturating cysto-urethrogram (MCUG) was ordered in case of UTI after the first pyeloplasty ($N = 4$) and was normal in these selected patients except one patient with contralateral grade I vesicoureteral reflux that was observed. Previous surgical details are listed in **Table 1**.

Median age at redo pyeloplasty was 22 months (IQR: 11–84 months), median weight at surgery was 10 kg (8–15 kg), and median time between primary and redo repair was 12 months (7–49 months). Patient details at time of redo laparoscopic

TABLE 1 | Previous surgical details ($N = 22$).

	Patients (%)
Initial surgeries	
Retroperitoneal laparoscopic pyeloplasty	3 (13.6)
Open dorsal lumbotomy	15 (68.1)
Open anterior subcostal incision	4 (18.2)
Temporizing interventions	
Nephrostomy tube	8 (36.4)
JJ stent	5 (22.7)
Endoscopic balloon dilatation	2 (9.1)
None	7 (31.2)

TABLE 2 | Demographic and clinical data ($N = 22$).

	Minimum	Maximum	Median
Age at redo (months)	4.5	183	22
Weight (kg)	6	50	10
Operative time (min)	50	250	200
Hospital stay (days)	2	10	3
Follow-up duration (months)	2	120	29

pyeloplasty are shown in **Table 2**. Cause of failure of the primary repair was identified during laparoscopy as follows: adhesions around the UPJ area causing the obstruction (10 patients, 45.4%), stenotic UPJ area (seven patients, 31.8%), high anastomosis (anastomosis was not in the dependent area) (two patients, 9.1%), crossing vessels (one patient, post primary open repair, 4.5%), long segment stricture (one patient, 4.5%), and one patient had a twist of the anastomosis (4.5%) (**Table 3**). Preoperative and postoperative imaging features are reported in **Table 4**.

A JJ stent was used for all patients for a median duration of 2.5 months (IQR: 2–3 months). There was a single exception to this in the case of a patient in whom there was difficulty passing the JJ stent beyond the uretero-vesical junction, so an externalized ureteral catheter was used for 10 days.

Median operative time was calculated from the start of insufflation until exsufflation and was 200 min (IQR: 180–225 minutes). Median length of hospital stay was 3 days (IQR: 3–4.25 days). Two patients had a prolonged hospital stay: the first one kept admitted 10 days to await resolution of a urine leak from the anastomosis site. The other was readmitted on day 11 after surgery for pyelonephritis. Intravenous antibiotics were injected at hospital for 6 days.

The procedure was feasible in all cases without conversion to open surgery. No major complications (Clavien \geq III) were recorded.

Median follow-up duration was 29 months (IQR: 15–62 months). All patients were asymptomatic except one patient who presented with post-operative pain and pyelonephritis 11 days after surgery. Nineteen patients demonstrated an improvement in hydronephrosis. Three showed severe hydronephrosis with an obstructed curve on nuclear study. One patient had a wide dependent draining anastomosis on retrograde pyelography

TABLE 3 | Side, intraoperative finding, procedure, and outcome (N = 22).

	Number	Percentage (%)
Symptoms	10	45.5
UTI	7	31.8
Pain	4	18.2
Asymptomatic	12	54.5
Obstruction side: Right/Left	10/12	45.5/54.5
Intraoperative Cause of Failure		
1. Adhesions causing obstruction	10	45.5
2. UPJ obstruction	7	31.8
3. Highly inserted ureter	2	9
4. Crossing vessels	1	4.5
5. Long segment stricture	1	4.5
6. Twist of the anastomosis	1	4.5
Intraoperative Procedure:		
1. Anderson-Hynes technique	20	90.9
2. Ureterocalicostomy	2	9.1
Readmission		
Yes	2	9.1
No	20	90.9
Outcome		
Success	20	90.9
Failure	2	9.1

without obstruction and therefore was not considered a failure. The other two patients had obstruction confirmed on retrograde pyelography (RPG). In these patients, the kidney was palpable and on ultrasound exhibited worsening of hydronephrosis with the average APD increased from 33 mm to 51 mm and decreased renal function by renography from 25 to 7%. One underwent endoscopic balloon dilatation after the RPG and the second underwent a redo laparoscopic pyeloplasty. Both are doing well after their repeat intervention.

Overall success of redo laparoscopic pyeloplasty was 90.9%.

DISCUSSION

The first attempt of laparoscopic pyeloplasty for primary ureteropelvic junction obstruction was described for adults at the end of twentieth century in 1993 followed by reports for children in 1995 (8–10). Only one of these cases had secondary ureteropelvic junction obstruction after failure of open pyeloplasty (8). Since that time, the role of laparoscopic and robotic assisted pyeloplasty has evolved to take a more primary role in the management of primary UPJO, regardless of age or trans peritoneal vs. retroperitoneal approach (11–15). However, the gold standard for redo cases has general been considered an open pyeloplasty and thus redo laparoscopic pyeloplasty in children has not been widely applied. With the advent of improving minimally invasive techniques and increasing familiarity with these approaches, many have advocated using minimally invasive techniques in the redo setting. In a prospective, case–control study of open vs. laparoscopic pyeloplasty, 30 patients with UPJO were compared. This showed comparable results with the laparoscopic approach

TABLE 4 | Preoperative and postoperative imaging features (N=22).

	Preoperative evaluation	Postoperative evaluation	p-value
Anteroposterior diameter on renal ultrasound (mm) (median and IQR)	36 (34–50)	15 (9–45)	0.04
Functional imaging (N, %)			0.99
Renal scintigraphy	3 (13.6)	2 (9)	
MRU	19 (86.4)	10 (45.5)	
$t_{1/2}$ (median and IQR)	40 (35–50)	14 (13.5–14.5)	
Split renal function on functional studies (%) (median and IQR)	32 (24–46)	33 (21–39)	0.79
Pyelography (N, %)			0.52
Antegrade	5 (22.7)	0 (0)	
Retrograde	8 (36.4)	2 (9)	

being associated with a decrease in hospital stay and complication rates when compared to children in the open cohort (16, 17).

Management options in failed pyeloplasty include JJ stent placement, balloon dilatation endopyelotomy, and redo surgery (2, 3). Lower success rates have been reported endoscopic procedures as compared to redo pyeloplasty, which is not surprising (2, 3, 18). However, Dy et al. reported that at least one endoscopic procedure was performed prior to definitive redo-pyeloplasty in 11% of children with failed pyeloplasty (1).

Performing a redo-UPJO is a challenging surgery. Despite encouraging outcomes achieved with both laparoscopy and robotics, success rates are likely to be lower than those obtained in the primary setting (19).

Redo laparoscopic pyeloplasty has well-established merits, including reduced morbidity, reduced hospital stays, and reduced pain compared to open pyeloplasty (19). However, this challenging technique must be performed by experienced surgeons due to the extensive scarring and fibrosis noted from the previous procedure (4). Basiri et al. evaluated the feasibility and effectiveness of RLP and found that 100% of children showed improved renal function after undergoing secondary UPJO treated by RLP, lending credence to its value over immediately attempting an open repair (20).

In our previously reported experience, primary laparoscopic pyeloplasty has a 98% success rate, which is higher than the 90.9% reported in the current study of redo laparoscopic pyeloplasties (21). Our current findings are similar to those reported by Abdel-Karim et al. (22). Similarly, Moscardi et al. had a 90% success rate of 11 redo laparoscopic pyeloplasty, and they showed no difference in the outcome between primary laparoscopic pyeloplasty and redo laparoscopic pyeloplasty in terms of operative time, complications, and success rate (23).

Redo laparoscopic pyeloplasty has been reported in adults and children usually using the transperitoneal approach but occasionally through a retroperitoneal approach (4, 24). Although the retroperitoneal approach is still our preference for primary cases, we have chosen the transperitoneal approach for secondary cases (21). This choice has been made to avoid dissecting through secondary adhesions in the retroperitoneal space, and to limit the dissection to the UPJ and proximal ureter.

Interestingly, most of the cases that we report in the current study were performed in an open fashion for the primary surgery, and not all initially underwent a retroperitoneal approach for their initial surgery. It raises the question of whether a better option would be a retroperitoneal laparoscopic approach for a redo pyeloplasty if the patient originally underwent a transperitoneal approach.

Factors, such as young age at initial surgery (<6 months), missed anatomic findings at the first intervention (long ureteral segment narrowing or crossing vessels) and dry anastomosis (prolonged urinary diversion) have been associated with pyeloplasty failure (13, 25). The degree of adhesion and fibrosis is highly variable, which may be secondary to healing factors of the patients as well as the technical difficulty in the primary surgery, such as an incomplete or unfavorable position of the anastomosis between the renal pelvis and ureter or urinoma (26). Additionally, peri pelvic fibrosis, excessive scarring, and thermal energy, which can cause more tissue reactions and fibrosis can be associated with failures (27). These reasons support the findings we report in our cohort.

The long median time between primary and redo surgeries in our series is explained by the large (13 out of 22) number of patients referred to us from outside, which is the same observation noticed by Moscardi et al. (23). It would have been pertinent to examine factors associated with primary pyeloplasty failure, given the fact that over half of the patients were referrals, we did not feel that we could justify such an analysis using our data.

In our experience, two factors have been identified for the success of this procedure. First, the use of MRU as an anatomical and functional imaging studies during the preoperative management is a useful tool to assess the anatomy of the kidney and the renal pelvis, to measure the thickness of the parenchyma and to evaluate the split renal function. The first study from Perez-Brayfield et al. in 2003 concluded that dynamic contrast enhanced MRI provided equivalent information about renal function but superior information regarding morphology in a single study without ionizing radiation (28). A multi-institutional study in 2014 including 369 patients reported an equivalence of MRU to renal scintigraphy making substitution of MRU for RS acceptable (29). In our study, 19 (86.4%) patients were evaluated with a MRU. We strongly believe this imaging is better than a renal scintigraphy as it provides a better evaluation of the pelvis anatomy. Median split renal function of the operated kidney was 32 and 33% preoperatively and postoperatively, respectively ($p > 0.05$). However, functional studies were not unfortunately performed routinely after the redo surgery either in cases of preoperative evaluation showed asymmetrical function or remaining hydronephrosis. Secondly, the experience of our team in using minimally invasive surgery in our daily practice helps the laparoscopic approach to provide easily a global exposure of the pelvis and the ureter without the need to extensively dissect or mobilize the kidney (12, 21, 30–34). In selected cases with an extensive fibrosis of multi-operated renal pelvis, an alternative approach by ureterocalicostomy was deemed most appropriate.

There are multiple limitations worth discussing in the present study. First and foremost is the retrospective nature and small number of included patients. Furthermore, the fact that over half of the patients were referred to our institution makes it challenging to comment at all on how the initial surgical approach could have impacted the redo procedure that we report upon herein. The minority of patients underwent a laparoscopic pyeloplasty for their primary repair. However, as the primary goal of the study was to examine the feasibility and effectiveness of performing laparoscopic pyeloplasty in the redo setting, particularly in the setting of such a high proportion of prior open repairs, we feel that the limitations are acceptable so long as the reader is aware of them.

CONCLUSION

Redo laparoscopic pyeloplasty is both a feasible and effective procedure for the management of failed primary pyeloplasty, regardless of whether the initial surgery was performed open or laparoscopic. Given the benefits of shorter hospitalization and reduced pain following any minimally invasive procedure, it should be strongly considered as an option for any pediatric patient presenting with a recurrent UPJ obstruction.

DATA AVAILABILITY STATEMENT

The raw data supporting the conclusions of this article will be made available by the authors, without undue reservation.

ETHICS STATEMENT

The studies involving human participants were reviewed and approved by IRB and ethical board approval at our institution was obtained for this study. Written informed consent to participate in this study was provided by the participants' legal guardian/next of kin. Written informed consent was obtained from the minor(s)' legal guardian/next of kin for the publication of any potentially identifiable images or data included in this article.

AUTHOR CONTRIBUTIONS

HA-H, MP, EC, GM, CG, AP-J, and AE-G contributed conception and design of the study. HA-H, MP, EC, KN, LA, and AE-G organized the database. HA-H, LA, and MP performed the statistical analysis. HA-H wrote the first draft of the manuscript. MP, GM, AP-J, LA, and AE-G wrote sections of the manuscript. All authors contributed to manuscript revision, read, and approved the submitted version.

ACKNOWLEDGMENTS

The authors thank M. Francesca MONN, Department of Urology, Eastern Virginia Medical School, VA (USA) for valuable comments on the study and for assistance with language editing and proofreading.

REFERENCES

- Dy GW, Hsi RS, Holt SK, Lendvay TS, Gore JL, Harper JD. National trends in secondary procedures following pediatric pyeloplasty. *J Urol.* (2016) 195:1209–14. doi: 10.1016/j.juro.2015.11.010
- Romao RLP, Koyle MA, Pippi Salle JL, Alotay A, Figueroa VH, Lorenzo AJ, et al. Failed pyeloplasty in children: revisiting the unknown. *Urology.* (2013) 82:1145–7. doi: 10.1016/j.urology.2013.06.049
- Thomas JC, de Marco RT, Donohoe JM, Adams MC, Pope JC, Brock JW. Management of the failed pyeloplasty: a contemporary review. *J Urol.* (2005) 174:2363–6. doi: 10.1097/01.ju.0000180420.11915.31
- Piaggio LA, Noh PH, González R. Reoperative laparoscopic pyeloplasty in children: comparison with open surgery. *J Urol.* (2007) 177:1878–82. doi: 10.1016/j.juro.2007.01.053
- Lindgren BW, Hagerty J, Meyer T, Cheng EY. Robot-assisted laparoscopic reoperative repair for failed pyeloplasty in children: a safe and highly effective treatment option. *J Urol.* (2012) 188:932–7. doi: 10.1016/j.juro.2012.04.118
- Knoedler J, Han L, Granberg C, Kramer S, Chow G, Gettman M, et al. Population-based comparison of laparoscopic and open pyeloplasty in paediatric pelvi-ureteric junction obstruction. *BJU Int.* (2013) 111:1141–7. doi: 10.1111/bju.12039
- Clavien PA, Barkun J, de Oliveira ML, Vauthey JN, Dindo D, Schulick RD, et al. The Clavien-Dindo classification of surgical complications: five-year experience. *Ann Surg.* (2009) 250:187–96. doi: 10.1097/SLA.0b013e3181b13ca2
- Schuessler WW, Grune MT, Tecuanhuey LV, Preminger GM. Laparoscopic dismembered pyeloplasty. *J Urol.* (1993) 150:1795–9. doi: 10.1016/S0022-5347(17)35898-6
- Kavoussi LR, Peters CA. Laparoscopic pyeloplasty. *J Urol.* (1993) 150:1891–4. doi: 10.1016/S0022-5347(17)35926-8
- Peters CA, Schluskel RN, Retik AB. Pediatric laparoscopic dismembered pyeloplasty. *J Urol.* (1995) 153:1962–5. doi: 10.1016/S0022-5347(01)67378-6
- Yeung CK, Tam YH, Sihoe JD, Lee KH, Liu KW. Retroperitoneoscopic dismembered pyeloplasty for pelvi-ureteric junction obstruction in infants and children. *BJU Int.* (2001) 87:509–13. doi: 10.1046/j.1464-410X.2001.00129.x
- El-Ghoneimi A, Farhat W, Bolduc S, Bagli D, McLorie G, Aigrain Y, et al. Laparoscopic dismembered pyeloplasty by a retroperitoneal approach in children. *BJU Int.* (2003) 92:104–8. doi: 10.1046/j.1464-410X.2003.04266.x
- Metzelder ML, Schier F, Petersen C, Truss M, Ure BM. Laparoscopic transabdominal pyeloplasty in children is feasible irrespective of age. *J Urol.* (2006) 175:688–91. doi: 10.1016/S0022-5347(05)00179-5
- Atug F, Burgess SV, Castle EP, Thomas R. Role of robotics in the management of secondary ureteropelvic junction obstruction. *Int J Clin Pract.* (2006) 60:9–11. doi: 10.1111/j.1368-5031.2006.00701.x
- Reddy M, Nerli RB, Bashetty R, Ravish IR. Laparoscopic dismembered pyeloplasty in children. *J Urol.* (2005) 174:700–2. doi: 10.1097/01.ju.0000164738.78606.78
- Piaggio LA, Corbetta JP, Weller S, Dingevan RA, Duran V, Ruiz J, et al. Comparative, prospective, case-control study of open versus laparoscopic pyeloplasty in children with ureteropelvic junction obstruction: long-term results. *Front Pediatr.* (2017) 5:10. doi: 10.3389/fped.2017.00010
- Bansal P, Gupta A, Mongha R, Narayan S, Das RK, Bera M, et al. Laparoscopic versus open pyeloplasty: comparison of two surgical approaches- a single centre experience of three years. *Indian J Surg.* (2011) 73:264–7. doi: 10.1007/s12262-011-0237-2
- Braga LHP, Lorenzo AJ, Skeldon S, Dave S, Bagli DJ, Khoury AE, et al. Failed pyeloplasty in children: comparative analysis of retrograde endopyelotomy versus redo pyeloplasty. *J Urol.* (2007) 178:2571–5. doi: 10.1016/j.juro.2007.08.050
- Autorino R, Eden C, El-Ghoneimi A, Guazzoni G, Buffi N, Peters CA, et al. Robot-assisted and laparoscopic repair of ureteropelvic junction obstruction: a systematic review and meta-analysis. *Eur Urol.* (2014) 65:430–52. doi: 10.1016/j.eururo.2013.06.053
- Basiri A, Behjati S, Zand S, Moghaddam SMH. Laparoscopic pyeloplasty in secondary ureteropelvic junction obstruction after failed open surgery. *J Endourol.* (2007) 21:1045–51. doi: 10.1089/end.2006.0414
- Blanc T, Muller C, Abdoul H, Peev S, Paye-Jaouen A, Peycelon M, et al. Retroperitoneal laparoscopic pyeloplasty in children: long-term outcome and critical analysis of 10-year experience in a teaching center. *Eur Urol.* (2013) 63:565–72. doi: 10.1016/j.eururo.2012.07.051
- Abdel-Karim AM, Fahmy A, Moussa A, Rashad H, Elbadry M, Badawy H, et al. Laparoscopic pyeloplasty versus open pyeloplasty for recurrent ureteropelvic junction obstruction in children. *J Pediatr Urol.* (2016) 12:401.e1–6. doi: 10.1016/j.jpuro.2016.06.010
- Moscardi PRM, Barbosa JABA, Andrade HS, Mello MF, Cezarino BN, Oliveira LM, et al. Reoperative laparoscopic ureteropelvic junction obstruction repair in children: safety and efficacy of the technique. *J Urol.* (2017) 197:798–804. doi: 10.1016/j.juro.2016.10.062
- Eden C, Gianduzzo T, Chang C, Thiruchelvam N, Jones A. Extraperitoneal laparoscopic pyeloplasty for primary and secondary ureteropelvic junction obstruction. *J Urol.* (2004) 172:2308–11. doi: 10.1097/01.ju.0000143904.17666.0b
- Kapoor A, Allard CB. Laparoscopic pyeloplasty: the standard of care for ureteropelvic junction obstruction. *Can Urol Assoc J.* (2011) 5:136–8. doi: 10.5489/cuaj.11036
- Kojima Y, Sasaki S, Mizuno K, Tozawa K, Hayashi Y, Kohri K. Laparoscopic dismembered pyeloplasty for ureteropelvic junction obstruction in children. *Int J Urol.* (2009) 16:472–6. doi: 10.1111/j.1442-2042.2009.02282.x
- Song SH, Lee C, Jung J, Kim SJ, Park S, Park H, et al. A comparative study of pediatric open pyeloplasty, laparoscopy-assisted extracorporeal pyeloplasty, and robot-assisted laparoscopic pyeloplasty. *PLoS ONE.* (2017) 12:e0175026. doi: 10.1371/journal.pone.0175026
- Perez-Brayfield MR, Kirsch AJ, Jones RA, Grattan-Smith JD. A prospective study comparing ultrasound, nuclear scintigraphy and dynamic contrast enhanced magnetic resonance imaging in the evaluation of hydronephrosis. *J Urol.* (2003) 170:1330–4. doi: 10.1097/01.ju.0000086775.66329.00
- Claudon M, Durand E, Grenier N, Prigent A, Balvay D, Chaumet-Riffaud P, et al. Chronic urinary obstruction: evaluation of dynamic contrast-enhanced MR urography for measurement of split renal function. *Radiology.* (2014) 273:801–12. doi: 10.1148/radiol.14131819
- El-Ghoneimi A, Sauty L, Maintenant J, Macher MA, Lottmann H, Aigrain Y. Laparoscopic retroperitoneal nephrectomy in high risk children. *J Urol.* (2000) 164:1076–9. doi: 10.1097/00005392-200009020-00039
- Bonnard A, Fouquet V, Carricaburu E, Aigrain Y, El-Ghoneimi A. Retroperitoneal laparoscopic versus open pyeloplasty in children. *J Urol.* (2005) 173:1710–3. doi: 10.1097/01.ju.0000154169.74458.32
- Blanc T, Koulouris E, Botto N, Paye-Jaouen A, El-Ghoneimi A. Laparoscopic pyeloplasty in children with horseshoe kidney. *J Urol.* (2014) 191:1097–103. doi: 10.1016/j.juro.2013.10.059
- Blanc T, Muller C, Pons M, Pashootan P, Paye-Jaouen A, El Ghoneimi A. Laparoscopic mitrofanoff procedure in children: critical analysis of difficulties and benefits. *J Pediatr Urol.* (2015) 11:28.e1–8. doi: 10.1016/j.jpuro.2014.07.013
- Peycelon M, Rembeyo G, Tanase A, Muller CO, Blanc T, Alhazmi H, et al. Laparoscopic retroperitoneal approach for retrocaval ureter in children. *World J Urol.* (2019) 38:2055–62. doi: 10.1007/s00345-019-02849-w

Conflict of Interest: The authors declare that the research was conducted in the absence of any commercial or financial relationships that could be construed as a potential conflict of interest.

Copyright © 2020 Al-Hazmi, Peycelon, Carricaburu, Manzoni, Neel, Ali, Grapin, Paye-Jaouen and El-Ghoneimi. This is an open-access article distributed under the terms of the Creative Commons Attribution License (CC BY). The use, distribution or reproduction in other forums is permitted, provided the original author(s) and the copyright owner(s) are credited and that the original publication in this journal is cited, in accordance with accepted academic practice. No use, distribution or reproduction is permitted which does not comply with these terms.



Early Robotic-Assisted Laparoscopic Pyeloplasty for Infants Under 3 Months With Severe Ureteropelvic Junction Obstruction

Pin Li^{1†}, Huixia Zhou^{1,2*†}, Hualin Cao^{1,3†}, Tao Guo⁴, Weiwei Zhu⁴, Yang Zhao^{4,5}, Tian Tao¹, Xiaoguang Zhou¹, Lifei Ma¹, Yunjie Yang^{2,6} and Zhichun Feng¹

¹ Department of Pediatric Urology, Bayi Children's Hospital, Affiliated of the Seventh Medical Center of People's Liberation Army General Hospital, Beijing, China, ² The Second School of Clinical Medicine, Southern Medical University, Guangzhou, China, ³ Department of Urology, Nan Xi Shan Hospital of Guangxi Zhuang Autonomous Region, Guilin, China, ⁴ Medical School of Chinese People's Liberation Army, Beijing, China, ⁵ Department of Pediatrics, The Third Medical Center of People's Liberation Army General Hospital, Beijing, China, ⁶ Department of Urology, The Affiliated Nanhai Hospital of the Southern Medical University, Foshan, China

OPEN ACCESS

Edited by:

Venkata R. Jayanthi,
Nationwide Children's Hospital,
United States

Reviewed by:

Juan Manuel Moldes,
Italian Hospital of Buenos
Aires, Argentina
Mohan S. Gundeti,
University of Chicago, United States
Aseem Ravindra Shukla,
Children's Hospital of Philadelphia,
United States

*Correspondence:

Huixia Zhou
huixia99999@163.com

[†]These authors have contributed
equally to this work

Specialty section:

This article was submitted to
Pediatric Urology,
a section of the journal
Frontiers in Pediatrics

Received: 03 August 2020

Accepted: 04 February 2021

Published: 10 March 2021

Citation:

Li P, Zhou H, Cao H, Guo T, Zhu W,
Zhao Y, Tao T, Zhou X, Ma L, Yang Y
and Feng Z (2021) Early
Robotic-Assisted Laparoscopic
Pyeloplasty for Infants Under 3
Months With Severe Ureteropelvic
Junction Obstruction.
Front. Pediatr. 9:590865.
doi: 10.3389/fped.2021.590865

Objective: To present our primary experience of robotic-assisted laparoscopic pyeloplasty (RALP) for severe ureteropelvis junction obstruction (UPJO) infants under 3 months.

Methods: We performed a retrospective study of 9 infants under 3 months who underwent RALP for severe UPJO between April 2017 and March 2019 in our center. The severe UPJO was defined as infants with severe hydronephrosis (Society of Fetal Urology grades III or IV, anteroposterior diameter >3 cm or split renal function <40% or T 1/2 >20 min) involving bilateral, solitary kidney, or contralateral renal hypoplasia UPJO at the same time. All clinical, perioperative, and postoperative information was collected.

Results: There were four bilateral UPJO cases, two solitary kidney UPJO cases and three unilateral UPJO with contralateral renal hypoplasia cases included. One single surgeon performed RALP on all of the infants. The mean age of the infants was 1.62 ± 0.54 months. The mean operative time was 109.55 ± 10.47 min. The mean estimated blood loss was 19.29 ± 3.19 ml, and the mean length of hospital stay was 5.57 ± 0.73 days. According to the ultrasonography results, all patients had a significant recovery of renal function at 12 months after the operation.

Conclusions: To maximize the protection of renal function, early RALP is a safe and feasible option for the treatment of severe UPJO in infants under 3 months.

Keywords: robotic-assisted laparoscopic pyeloplasty, infant, hydronephrosis, ureteropelvic junction obstruction, RALP

INTRODUCTION

Ureteropelvic junction obstruction (UPJO) is one of the major causes of infant hydronephrosis (1). The management of UPJO has evolved from open pyeloplasty (OP), laparoscopic pyeloplasty (LP), and robotic-assisted laparoscopic pyeloplasty (RALP) (2, 3). Well-established evidence has demonstrated that LP or RALP not only has success rates equal to those of OP

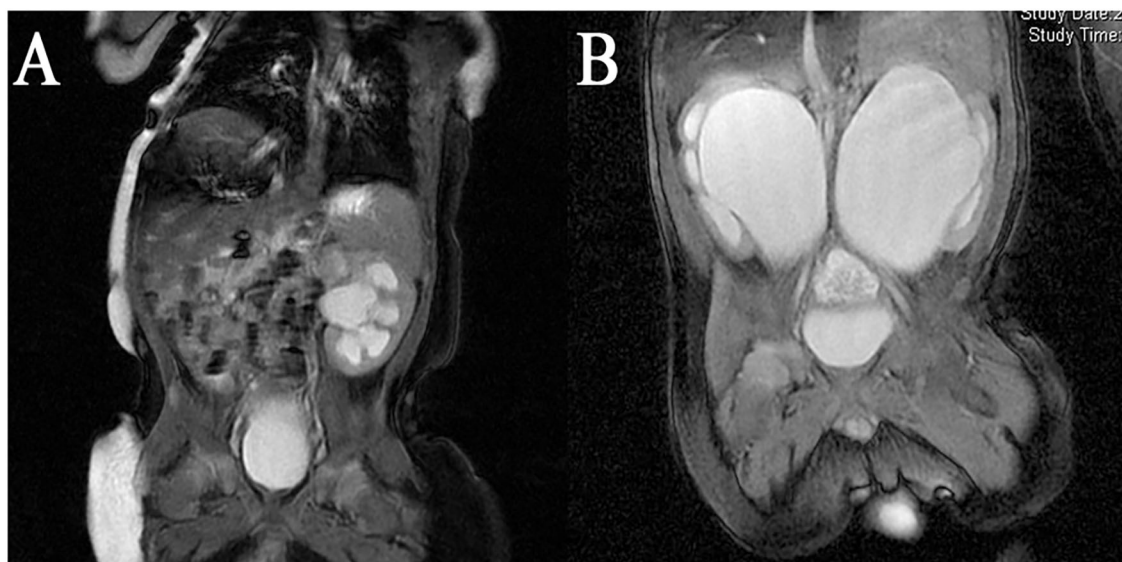


FIGURE 1 | MRI result of a **(A)** Unilateral UPJO with contralateral renal dysplasia; **(B)** bilateral severe UPJO.

but also has the advantages of minimal invasiveness, better cosmesis, less post-operative pain, decreased length of hospital stay, and early recovery¹ (4, 5). In general, the management of hydronephrosis included conservative observation and surgical intervention. The clinical decision making usually depends on the rate of hydronephrosis severity. There is still no consensus on the optimal intervention time to perform the surgery, however; whether through conservative or surgical treatment, the ultimate goal is to maximally protect renal function.

Severe UPJO generally refers to bilateral UPJO, a solitary kidney with UPJO, or UPJO with contralateral renal dysplasia. In these complex situations, the selection of conservative observation, conservative nephrostomy, or early minimal invasive pyeloplasty is a problem, especially for very young children under 3 months of age. It is widely acknowledged that pyeloplasty for an infant under 1 year of age or under 10 kg of weight is a challenging procedure that requires more elaborate techniques to decrease the number of complications and lessen operating time to reduce the negative effect of anesthesia (6, 7). In this retrospective study, we summarize our initial experience with conducting RALP on nine severe UPJO infants under 3 months of age.

METHODS AND MATERIALS

Patients

Nine infants 0.8–2.6 months old (mean age 1.62 months) presented with severe UPJO confirmed by ultrasonography screening and were referred to our center from April 2017 to March 2019. The inclusion criteria of this study included age

<3 months, severe hydronephrosis defined as grade III and IV dilation as defined by the Society for Fetal Urology (SFU), anteroposterior diameter (APD) more than 3 cm, impaired split renal function <40%, along with one of the following three conditions: bilateral UPJO, solitary kidney UPJO, or unilateral severe UPJO with contralateral renal dysplasia. Exclusion criteria were UPJO with megaureters, vesicoureteral reflux, posterior urethral valve, or the existence of other structural anomalies. The diagnosis was based on ultrasonography, magnetic resonance urography (MRU) (**Figure 1**), voiding cystourethrography (VCUG), radionuclide, and ^{99m}Tc-mercaptoacetyltriglycine (MAG3) diuretic renography results. Perioperative demographic information was also recorded. All patients underwent robotic-assisted laparoscopic pyeloplasty (RALP) with one single surgeon. The Clavien-Dindo classification system was used to evaluate the postoperative complications. This study was undertaken with the approval of the Seventh Medical Center of PLA General Hospital Institutional Ethics Committee. All patients' parents have signed the written consent forms.

Surgical Technique

After routine preoperative preparation and anesthesia, pneumoperitoneum was established and maintained at 6–8 mmHg pressure. All ports were placed under direct vision included one 8.5 mm camera trocar, one 8-mm trocar and one 5-mm trocar. One or two additional assistant 3-mm trocars were placed at the lateral 3 cm of the midpoint of the Pfannenstiel line, to improve the efficiency of the suture (**Figure 2**). For left side cases, the transmesenteric approach was adopted while the dilated renal pelvis was located at the inside of the descending colon. For right side cases, we selected the paracolic sulci approach. Then we carefully dissected the proximal ureter and renal pelvis while preserving the ureteral blood supply. The

¹The laparoscopic pyeloplasty: is there a role in the age of robotics? Accessed May 6, 2020. <https://www.ncbi.nlm.nih.gov/pubmed/25455171>

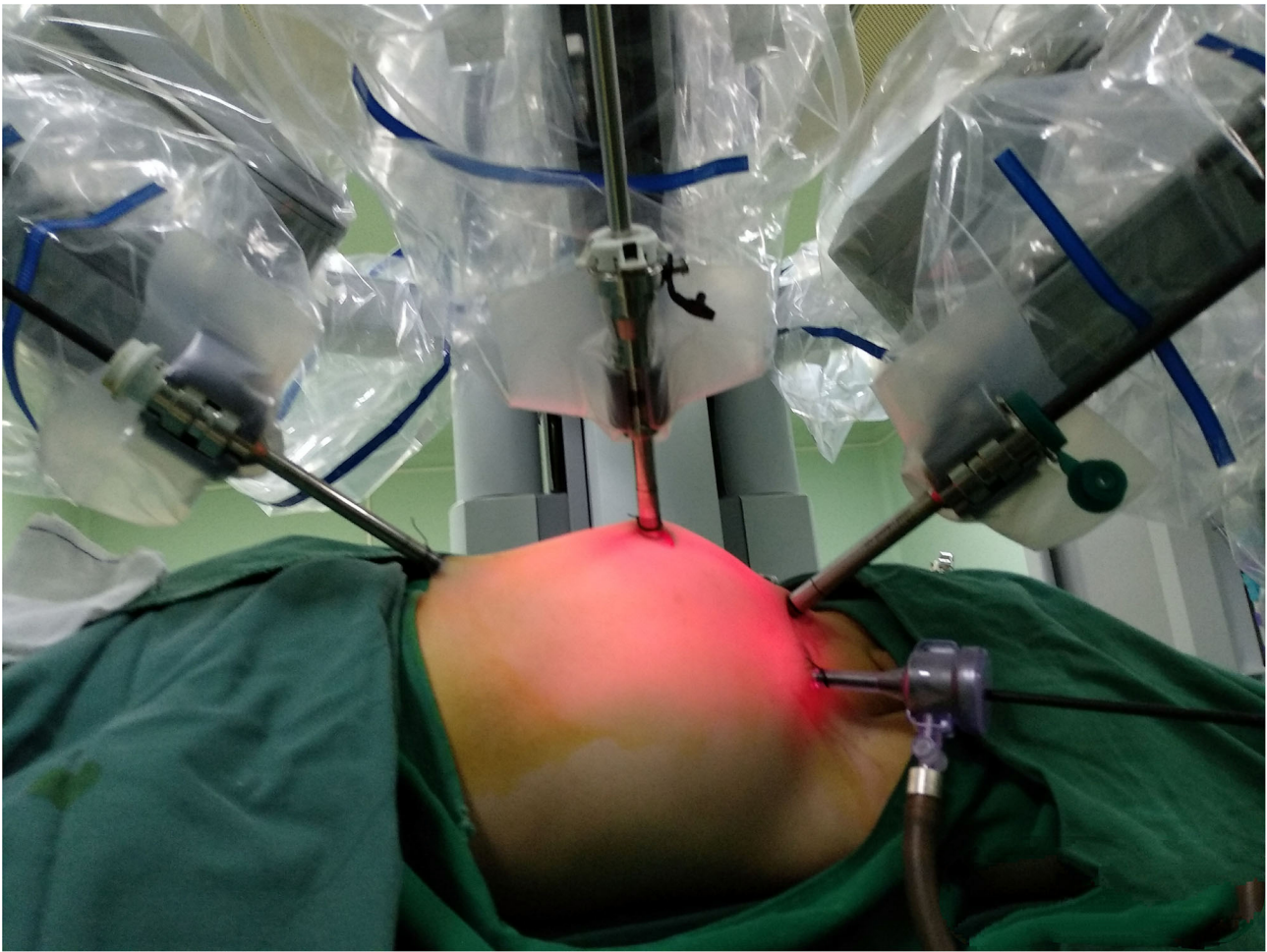


FIGURE 2 | Trocar position appearance.

pelvis was cut above the obstruction tissue and trimmed by a percutaneous hitch stitch to stabilize it and facilitated the anastomosis. After spatulated the distal ureter after excision of the obstruction segment, we sutured the lowest point of the aperistaltic ureteral segment and the pelvis end with a running 6-0 PDS-II. Then the posterior wall of the ureter was closed through continuous suture. Before the anterior anastomoses were started with a second running 6-0 PDS II suture, a double-J ureteral stent (COOK, USI-512, Ireland) was placed antegrade. At last, we closed the mesentery or peritoneum with a 5-0 absorbing suture. For the bilateral pyeloplasty infants, we performed one sided RALP and nephrostomy for the other side. After 1 week interval, we performed RALP for the contralateral UPJO in the same way.

Postoperative Management

The infants restarted general oral feeding after they had recovered from anesthesia. The double-J stent was removed under general anesthesia 6–8 weeks after the operation

by cystoscopy. Ultrasonography, radionuclide, and diuretic renography examinations were repeated the 6th and 12th months after surgery.

Statistical Analysis

Continuous data were presented as the mean \pm STD and range. Functional outcomes were compared using the Student *t*-test or chi-square test. All statistical analyses were performed in the R software environment (version 3.6.3; <http://r-project.org/>), and $p < 0.05$ was considered significant in all statistical analyses.

RESULTS

The baseline clinical data of the nine infants were shown in **Table 1**. All operations were performed successfully without conversion to open surgery. No serious intraoperative complication happened. The perioperative findings were summarized in **Table 2**. Two patients with postoperative infection (Clavien-Dindo Grade II Complications) were

TABLE 1 | Patient characteristics.

Description	No.
Patient	9
Age at surgery, month, mean \pm SD (range)	1.62 \pm 0.54 (0.8–2.6)
Gender, No. male/female	6/3
Diagnosis	
Solitary kidney with UPJO	2
UPJO with contralateral renal dysplasia	3
Bilateral UPJO	4
APD (mm), mean \pm SD(range)	4.06 \pm 0.73(3.4–5.3)
SFU Grade III/IV	4/9
Split renal function	0.36 \pm 0.04
Renography T1/2 >20 min	8

TABLE 2 | Perioperative outcomes.

Description	No.
Estimated blood loss	19.29 \pm 3.19(15–30)
Operation time	109.55 \pm 10.47(92–138)
Conversion to open surgery	0
Foley catheter indwelling days	1.86 \pm 0.64
Length of hospital stay	5.57 \pm 0.73
Complications Clavien-Dindo	
I and II	2
III and IV	0

TABLE 3 | Preoperative and follow-up characteristics.

Description	Pre-operation	6th month	12th month	p-value
APD (mm)	4.06 \pm 0.73	0.97 \pm 0.16	0.86 \pm 0.12	<0.01
Split renal function	0.36 \pm 0.04	0.53 \pm 0.05	0.58 \pm 0.04	<0.01
Renography T1/2 <10 min	0	8	9	<0.01

managed conservatively by intravenous antibiotics. No patient suffered Clavien III or IV complications. The mean time for Foley catheter removal was 1.86 ± 0.64 days.

According to the follow-up data listed in **Table 3**, the renal pelvis APD decreased to 0.97 ± 0.16 cm in the 6th month after surgery, which was significantly smaller than perioperative APD ($p < 0.01$). Radionuclide renography results showed that the split renal function had a great improvement in 6 months and slightly increased in 12 months. Diuretic renography revealed that 8 out of 9 patients have a T 1/2 time <10 min in the 6th month after surgery. In the 12th month examination, all of the 9 patients' T 1/2 times were <10 min.

DISCUSSION

Open dismembered pyeloplasty has been the gold standard treatment for UPJO for decades with overall success rates of more than 90% (8). Since first reported in 1993, laparoscopic pyeloplasty has been demonstrated as a safe and effective treatment for UPJO (9). Two years later, pediatric laparoscopic

pyeloplasty was introduced by Peters et al. (10). While limited by the small space for instrument movement and trocar placement, the use of laparoscopic and robotic-assisted laparoscopic is well-described (11, 12). Recently, more and more literature has proved that laparoscopic pyeloplasty or robotic-assisted laparoscopic pyeloplasty has not only the same success rate as open pyeloplasty, but also shorter hospitalization stay, faster recovery time, and better cosmetic appearance (13–16).

Meanwhile, the management of hydronephrosis in children has greatly changed during the last 20 years. In the 1990s, Ransley et al. (17) reported that early pyeloplasty may not be of greater benefit than observed or delayed surgery. After radiological imaging studies had become available for clinical evaluation, the value of split renal function and T1/2 was greatly improved for deciding the optimal time for surgical treatment (18). According to the results of a study conducted by Onen et al., (19) they only recommended surgical intervention for renal deterioration (decreased split renal function or progressive hydronephrosis). However, Tabari et al. (20) revealed that early pyeloplasty could benefit infants <1 year old suffering from severe but asymptomatic hydronephrosis better than conservative management through a prospective interventional study. In their study, they compared the functional outcomes of open pyeloplasty on a group of infants and conservative management of infants. They found that the group of infants who had early surgery have lower SFU grade and larger cortical thickness than the conservative group. According to the EAU Guidelines 2020, increased APD, SFU grade III or IV, split renal function <40%, or decrease >10% in follow-up and poor drainage function could be indications for asymptomatic UPJO.

For infants under 1 year old or even under 3 months, there are numerous challenges for surgical intervention so that whether to perform surgery is controversial. In 2006, Kutikov et al. (21) reported that transperitoneal laparoscopic pyeloplasty for UPJO in eight infants under 6 months old is technically possible. Zamfir Snykers et al. (22) also draw a similar conclusion in their research. Simforoosh et al. (14) compared the surgical outcomes of standard and minilaparoscopic pyeloplasty in children younger than 1 year of age. They believed that both of these approaches had the same effect while the minilaparoscopic technique could be more cosmetically pleasing and less invasive (14). In a retrospectively study, Turner et al. (23) assessed the effect of laparoscopic pyeloplasty performed in 29 infants 2–11 months old. Their experience revealed a success rate with minimal morbidity (23). In a multi-institutional trial, Daniel et al. (16) collected perioperative data of 60 patients underwent RALP by six surgeons and described an excellence success rate and a low complication rate in this cohort. Shukla et al. (24) summarized their experience about RALP and compared outcomes between infants aged <1 year and older children. They found that there were no significant differences in length of hospital stay and complications or failure rates in infants compared to older children, and they called for the adaptation of RALP for the entire pediatric patient population. Andolfi et al. (6) conducted a systematic review to compare whether

RALP is superior to conventional LP. They selected 19 original articles and 5 meta-analyses and concluded that RALP could decrease operative times, shorten the length of hospital stay, and reduce the complication rates while having the same success rates comparable to LP.

Conventional laparoscopy has a significant learning curve and is technically challenging for many surgeons compared to robot-assisted laparoscopy. Undoubtedly, the robotic-assisted technique can facilitate a shorter learning curve and act as a bridge between the open and endoscopic approaches. In these years, pediatric RALP has become a viable minimally invasive surgical option for UPJO children with some reports on its efficacy, safety, and cosmetic effect (15, 25, 26). Our team has also presented our experiences of transumbilical multi-stab laparoscopic pyeloplasty for infants younger than 3 months. On this basis, we performed RALP for these severe hydronephrosis patients under 3 months in this cohort.

This study included nine infants (thirteen sides) ranging from 0.8 to 2.6 months old who underwent transperitoneal RALP. All of the patients were diagnosed prenatally and had regular examinations after birth. As the hydronephrosis lasted and became even worse, we decided to intervene early with these patients because of our previous experience with the children who had undergone RALP. For the infants who were sensitive to the CO₂ pressure, we usually selected 6–8 mmHg to establish the existence of pneumoperitoneum. To expand the operating space as much as possible, we lifted and fixed robotic arm numbers 1 and 2. We have also explored several port positions for infants and finally selected the strategy described in this article as it could provide the most operating space and the least skin wounds. To reduce the incidence of anastomosis obstruction and improve success rates, several techniques were applied in RALP, including the way to identify the axis of renal calyx as the kidney axis and started the anastomosis at the lowest point of the renal pelvis and ureter, which was also described in our previously published literature (27). For the bilateral UPJO cases, we performed two RALPs at one-week intervals, but not side by side, as bilateral RALP had longer operating time and higher stent blockage risk. During the hospitalizations, no anesthesia complications were observed. Our clinical experience indicated that these techniques are important to facilitate RALP and improve success rates and decrease postoperative complications (27). According to follow-up data from the 6th and 12th months after operation, the primary outcomes were positive. T1/2 results showed no obstruction of the ureter after 12 months. The cosmetic appearance was also satisfactory although in our study the quantitative evaluation was not. Compared with our previous published study about our early experience of using LP for infants younger than 3 months (28), RALP (including docking time) has a longer operation time (109.55 vs. 75 min), same length of stay (5.57 vs. 6 d) and the same success rate. LP has a litter advantage on the cosmetic effect, but the learning curve of RALP is significantly decreased.

The limitations of this study include its retrospective nature, lack of randomization and design with no control group, small patient sample size, use of a single center, the lack of more than one surgeon with experience with RALP, and the focus only on primary outcomes within 1 year. These factors limit us from drawing more conclusions on the management of severe hydronephrosis. Despite the existence of these limitations, we believe that our study provides new insight into the application of the robotic technique in infant surgery. It confirms that RALP has the advantage of being minimally invasive and could be used to protect the renal function of severe UPJO patients under 3 months as early as possible.

CONCLUSION

Early RALP is a safe and feasible option for the treatment of severe UPJO infants under 3 months. However, further controlled prospective study is still necessary to determine the ultimate role of RALP in the management of young infants with UPJO.

DATA AVAILABILITY STATEMENT

The raw data supporting the conclusions of this article will be made available by the authors, without undue reservation.

ETHICS STATEMENT

The studies involving human participants were reviewed and approved by the Seventh Medical Center of PLA General Hospital Institutional Ethics Committee. Written informed consent to participate in this study was provided by the participants' legal guardian/next of kin.

AUTHOR CONTRIBUTIONS

Conceptualization: PL and HZ. Data curation and Investigation: PL and HC. Formal analysis: PL and TG. Funding acquisition and Project administration: HZ. Methodology: LM. Resources: TT, XZ, and LM. Software: WZ and YZ. Supervision: ZF and HZ. Validation: YY. Visualization: PL, HC, and TG. Writing—original draft: PL and HC. Writing—review and editing: HZ. All authors contributed to the article and approved the submitted version.

FUNDING

This work was supported by the Military Family Planning Fund (No. 18JS001), Beijing Municipal Science and Technology Plan (No. Z181100001718008), National Public Welfare Industry Research Projects (No. 201402007), and Capital Health Development Research Fund (No. 2016-2-5091).

REFERENCES

- Hashim H, Woodhouse CRJ. Ureteropelvic junction obstruction. *Eur. Urol. Suppl.* (2012) 11:25–32. doi: 10.1016/j.eursup.2012.01.004
- Mufarrrij PW, Woods M, Shah OD, Palese MA, Berger AD, Thomas R, et al. Robotic dismembered pyeloplasty: a 6-year, multi-institutional experience. *J. Urol.* (2008) 180:1391–6. doi: 10.1016/j.juro.2008.06.024
- Shah KK, Louie M, Thaly RK, Patel VR. Robot assisted laparoscopic pyeloplasty: a review of the current status. *Int. J. Med. Rob. Comp. Assist. Surg.* (2007) 3:35–40. doi: 10.1002/rcs.122
- Huang Y, Wu Y, Shan W, Zeng L, Huang L. An updated meta-analysis of laparoscopic versus open pyeloplasty for ureteropelvic junction obstruction in children. *Int. J. Clin. Exp. Med.* (2015) 8:4922–31.
- Tasian GE, Casale P. The robotic-assisted laparoscopic pyeloplasty: gateway to advanced reconstruction. *Urol. Clin. North Am.* (2015) 42:89–97. doi: 10.1016/j.ucl.2014.09.008
- Andolfi C, Adamic B, Oommen J, Gundeti MS. Robot-assisted laparoscopic pyeloplasty in infants and children: is it superior to conventional laparoscopy? *World J. Urol.* (2020) 38:1827–33. doi: 10.1007/s00345-019-02943-z
- He Y, Song H, Liu P, Sun N, Tian J, Li M, et al. Primary laparoscopic pyeloplasty in children: a single-center experience of 279 patients and analysis of possible factors affecting complications. *J. Pediatr. Urol.* (2020) 16:331.e1–e11. doi: 10.1016/j.jpuro.2020.03.028
- Siqueira Jr TM, Nadu A, Kuo RL, Paterson RF, Lingeman JE, Shalhav AL. Laparoscopic treatment for ureteropelvic junction obstruction. *Urology.* (2002) 60:973–8. doi: 10.1016/S0090-4295(02)02072-1
- Schuessler WW, Grune MT, Tecuanhuey LV, Preminger GM. Laparoscopic dismembered pyeloplasty. *J. Urol.* (1993) 150:1795–9. doi: 10.1016/S0022-5347(17)35898-6
- Peters CA, Schluskel RN, Retik AB. Pediatric laparoscopic dismembered pyeloplasty. *J. Urol.* (1995) 153:1962–5. doi: 10.1016/S0022-5347(01)67378-6
- Tasian GE, Wiebe DJ, Casale P. Learning curve of robotic assisted pyeloplasty for pediatric urology fellows. *J. Urol.* (2013) 190:1622–7. doi: 10.1016/j.juro.2013.02.009
- Atug F, Woods M, Burgess SV, Castle EP, Thomas R. Robotic assisted laparoscopic pyeloplasty in children. *J. Urol.* (2005) 174(4 Part 1):1440–2. doi: 10.1097/01.ju.0000173131.64558.c9
- Dangle PP, Kearns J, Anderson B, Gundeti MS. Outcomes of infants undergoing robot-assisted laparoscopic pyeloplasty compared to open repair. *J. Urol.* (2013) 190:2221–7. doi: 10.1016/j.juro.2013.07.063
- Simforoosh N, Abedi A, Hosseini Sharifi SH, Nk MP, Rezaeetalab GH, Obayd K, et al. Comparison of surgical outcomes and cosmetic results between standard and mini laparoscopic pyeloplasty in children younger than 1 year of age. *J. Pediatr. Urol.* (2014) 10:819–23. doi: 10.1016/j.jpuro.2014.01.026
- Barbosa JA, Kowal A, Onal B, Gouveia E, Walters M, Newcomer J, et al. Comparative evaluation of the resolution of hydronephrosis in children who underwent open and robotic-assisted laparoscopic pyeloplasty. *J. Pediatr. Urol.* (2013) 9:199–205. doi: 10.1016/j.jpuro.2012.02.002
- Avery DI, Herbst KW, Lendvay TS, Noh PH, Dangle P, Gundeti MS, et al. Robot-assisted laparoscopic pyeloplasty: multi-institutional experience in infants. *J. Pediatr. Urol.* (2015) 11:139.e1–e5. doi: 10.1016/j.jpuro.2014.11.025
- Ransley PG, Dhillon HK, Gordon I, Duffy PG, Dillon MJ, Barratt TM. The postnatal management of hydronephrosis diagnosed by prenatal ultrasound. *J. Urol.* (1990) 144(2 Part 2):584–7. doi: 10.1016/S0022-5347(17)39528-9
- Ross SS, Kardos S, Krill A, Bourland J, Sprague B, Majd M, et al. Observation of infants with SFU grades 3–4 hydronephrosis: worsening drainage with serial diuresis renography indicates surgical intervention and helps prevent loss of renal function. *J. Pediatr. Urol.* (2011) 7:266–71. doi: 10.1016/j.jpuro.2011.03.001
- Onen A, Jayanthi V, Koff S. Long-term followup of prenatally detected severe bilateral newborn hydronephrosis initially managed nonoperatively. *J. Urol.* (2002) 168:1118–20. doi: 10.1016/S0022-5347(05)64604-6
- Tabari AK, Atqiaee K, Mohajerzadeh L, Rouzrokh M, Ghoroubi J, Alam A, et al. Early pyeloplasty versus conservative management of severe ureteropelvic junction obstruction in asymptomatic infants. *J. Pediatr. Surg.* 55:1936–40. doi: 10.1016/j.jpedsurg.2019.08.006
- Kutikov A, Resnick M, Casale P. Laparoscopic pyeloplasty in the infant younger than 6 months—is it technically possible? *J. Urol.* (2006) 175:1477–9. doi: 10.1016/S0022-5347(05)00673-7
- Zamfir Snykers C, De Plaen E, Vermersch S, Lopez M, Khelif K, Luyckx S, et al. Is laparoscopic pyeloplasty for ureteropelvic junction obstruction in infants under 1 year of age a good option? *Front. Pediatr.* (2019) 7:352. doi: 10.3389/fped.2019.00352
- Turner RM, Fox JA, Tomaszewski JJ, Schneck FX, Docimo SG, Ost MC. Laparoscopic pyeloplasty for ureteropelvic junction obstruction in infants. *J. Urol.* (2013) 189:1503–7. doi: 10.1016/j.juro.2012.10.067
- Kawal T, Srinivasan AK, Shrivastava D, Chu DI, Van Batavia J, Weiss D, et al. Pediatric robotic-assisted laparoscopic pyeloplasty: does age matter? *J. Pediatr. Urol.* (2018) 14:540.e1–e6. doi: 10.1016/j.jpuro.2018.04.023
- Sukumar S, Roghmann F, Sood A, Abdo AA, Menon M, Sammon JD, et al. Correction of ureteropelvic junction obstruction in children: national trends and comparative effectiveness in operative outcomes. *J. Endourol.* (2014) 28:592–8. doi: 10.1089/end.2013.0618
- Cundy TP, Harling L, Hughes-Hallett A, Mayer EK, Najmaldin AS, Athanasiou T, et al. Meta-analysis of robot-assisted vs conventional laparoscopic and open pyeloplasty in children. *BJU Int.* (2014) 114:582–94. doi: 10.1111/bju.12683
- Liu D, Zhou H, Ma L, Zhou X, Cao H, Tao T, et al. Comparison of laparoscopic approaches for dismembered pyeloplasty in children with ureteropelvic junction obstruction: critical analysis of 11-year experiences in a single surgeon. *Urology.* (2017) 101:50–5. doi: 10.1016/j.urol.2016.10.007
- Zhou H, Liu X, Xie H, Ma L, Zhou X, Tao T, et al. Early experience of using transumbilical multi-stab laparoscopic pyeloplasty for infants younger than 3 months. *J. Pediatr. Urol.* (2014) 10:854–8. doi: 10.1016/j.jpuro.2013.12.025

Conflict of Interest: The authors declare that the research was conducted in the absence of any commercial or financial relationships that could be construed as a potential conflict of interest.

Copyright © 2021 Li, Zhou, Cao, Guo, Zhu, Zhao, Tao, Zhou, Ma, Yang and Feng. This is an open-access article distributed under the terms of the Creative Commons Attribution License (CC BY). The use, distribution or reproduction in other forums is permitted, provided the original author(s) and the copyright owner(s) are credited and that the original publication in this journal is cited, in accordance with accepted academic practice. No use, distribution or reproduction is permitted which does not comply with these terms.



Hydronephrosis Classifications: Has UTD Overtaken APD and SFU? A Worldwide Survey

Santiago Vallasciani^{1*}, Anna Bujons Tur², John Gatti³, Marcos Machado⁴, Christopher S. Cooper⁵, Marie Claire Farrugia⁶, Huixia Zhou⁷, Mohammed El Anbari⁸ and Pedro-José Lopez^{9,10}

¹ Division of Urology, Department of Surgery, Sidra Medicine, Doha, Qatar, ² Division of Pediatric Urology, Puigvert Foundation, Barcelona, Spain, ³ Division of Pediatric Urology, Children's Mercy Hospital, Kansas City, MO, United States, ⁴ Division of Pediatric Urology, University of São Paulo, São Paulo, Brazil, ⁵ Department of Urology, University of Iowa Hospitals and Clinics, Iowa City, IA, United States, ⁶ Division of Pediatric Urology, Chelsea and Westminster Hospital NHS Foundation Trust, London, United Kingdom, ⁷ Department of Pediatric Urology, Bayi Children's Hospital, Affiliated of the Seventh Medical Center of PLA General Hospital, Beijing, China, ⁸ Division of Clinical Informatics, Sidra Medicine, Doha, Qatar, ⁹ Hospital Exequiel Gonzalez Cortes & Clinica Alemana, Santiago, Chile, ¹⁰ University of Chile, Santiago, Chile

OPEN ACCESS

Edited by:

Venkata R. Jayanthi,
Nationwide Children's Hospital,
United States

Reviewed by:

Onur Telli,
Istanbul Kartal Dr. Lutfi Kirdar
Education and Research
Hospital, Turkey
John Samuel Wiener,
Duke University, United States

*Correspondence:

Santiago Vallasciani
santiago.vallasciani@gmail.com

Specialty section:

This article was submitted to
Pediatric Urology,
a section of the journal
Frontiers in Pediatrics

Received: 27 December 2020

Accepted: 23 February 2021

Published: 12 April 2021

Citation:

Vallasciani S, Bujons Tur A, Gatti J, Machado M, Cooper CS, Farrugia MK, Zhou H, El Anbari M and Lopez P-J (2021) Hydronephrosis Classifications: Has UTD Overtaken APD and SFU? A Worldwide Survey. *Front. Pediatr.* 9:646517. doi: 10.3389/fped.2021.646517

Objective: To collect baseline information on the ultrasonographic reporting preferences.

Method: A 13-multiple choice questionnaire was designed and distributed worldwide among pediatric urologists, pediatric surgeons, and urologists. The statistical analysis of the survey data consisted of 3 steps: a univariate analysis, a bivariate and a multivariate analysis.

Results: Three hundred eighty participants responded from all the continents. The bivariate analysis showed the significant differences in the geographical area, the years of experience and the volume of cases. Most of the physicians prefer the SFU and APD systems because of familiarity and simplicity (37 and 34%, respectively). Respondents noted that their imaging providers most often report findings utilizing the mild-moderate-severe system or the APD measurements (28 and 39%, respectively) except for North America (SFU in 50%). Multivariate analysis did not provide significant differences.

Conclusion: Our study evaluates the opinions regarding the various pediatric hydronephrosis classification systems from a large number of specialists and demonstrates that there is no single preferred grading system. The greatest reported shortcoming of all the systems was the lack of universal utilization. The observations taken from this study may serve as basis for the construction of a common worldwide system. As APD and SFU are the preferred systems and the UTD a newer combination of both, it is possible that with time, UTD may become the universal language for reporting hydronephrosis. This time, based on the result of this survey, seems not arrived yet.

Keywords: hydronephrosis, classification, survey, pediatric urology, ultrasound, pediatric radiology

INTRODUCTION

Ultrasound reports serve as an instrument to communicate anatomic findings to health care providers permitting the patient's physician to make therapeutic decisions and counsel families. In the specific case of hydronephrosis, the report can be generated from the maternal-fetal specialist in the prenatal period or the pediatric radiologist postnatally. To communicate the results of the ultrasound study reliably and accurately, several classifications have been developed. Initially the anterior-posterior diameter of the renal pelvis (APD) was developed. Subsequently, additional systems that included other anatomical details regarding the calyces, renal parenchyma, ureters, and/or bladder were developed. These classification systems included the Society of Fetal Urology (SFU), Onen, UTD (Urinary Tract Dilatation), and European Society of Pediatric Radiology system (ESPR).

To date, there is no clear consensus on which of these systems offer better categorization of the dilatations, the best inter/intra-rater reliability, or the best prognostic value at the time of its assessment in cases of suspected or diagnosed urinary tract obstruction or vesicoureteric reflux. Even among pediatric urologists and surgeons, the individuals who will utilize these reports to make therapeutic and surgical decisions, no apparent consensus exists on which system is preferable. To advance communication and subsequent research in this area, a clear consensus among pediatric urologists regarding the preferable system for categorization and reporting of hydronephrosis is needed.

We hypothesize that there is no single preferred hydronephrosis grading system among pediatric surgeons and urologists. The aim of this study was to collect baseline information on the ultrasonographic reporting preferences among pediatric urologists and surgeons evaluating hydronephrosis and correlate it with the reporting system utilized in their localities.

MATERIALS AND METHODS

A 13-multiple choice questionnaire was designed by the authors (Appendix 1 in **Supplementary Material**). It was comprised of 4 questions on surgical specialty and type of practice, 4 on classification preferences, 3 related to communication with report providers, and 2 on future perspectives (Appendix 1 in **Supplementary Material**).

Institutional Review Board of the Institution of the first author waived the review by them as considered not a requirement for the present research. The participation of the responders was voluntary and considered as consent. The responders were also able to decide whether to provide their names and email contact or remain anonymous.

From November 2018 to February 2019, the questionnaire was accessible online through GoogleForm(R) platform and publicized through mailing lists (peds-urology@lists.it.uab.edu, novo-uroped@googlegroups.com, European Society for Pediatric Urology roster members database) and social media groups

(Sociedad Iberoamericana de Urologia Pediatrica, Argentinian, Chilean, and Brazilian Society for Pediatric Urology). The Society for Fetal Urology advertised it through their members. Colleagues in China had an alternative link to the same survey through SurveyMonkey(R). Duplicate respondents were avoided as these survey platforms identify the respondent before allowing them to submit the survey. A secondary assessment of potential duplicated responses was performed manually by the authors reviewing case by case the answers.

The statistical analysis of the survey data consists of 3 steps: a univariate analysis by providing the frequencies and representing graphically each variable alone; a bivariate analysis by measuring dependence of each variable from a first group with each variable from a second group, this is done using a G-test which is more general than a chi-square test; and a multivariate analysis using Multiple Correspondence Analysis (MCA) to form groups of the surveyed people depending on their answers to all the questions. All the statistical analyses are performed using the R statistical software version 3.5.0.

RESULTS

Three hundred and eighty physicians participated to the questionnaire. The univariate analysis results are depicted in the **Figures 1, 2**.

Globally, the two most preferred systems were the SFU system and the renal Pelvic AP diameter with 37 and 34%, respectively (140/380 and 129/380). The more recently developed UTD system ranked third in terms of overall preference with 18% choosing it as their preference. A minority of participants (8%) choose the mild-moderate-severe system and only 1% chose the Onen or the ESPR system (**Figure 2**, right).

The classification systems most utilized by providers was based on an open question (question 11) that permitted the participant to choose more than one classification system. Globally there were 601 responses to this question, averaging nearly 2 study systems per respondent. This resulted in an increase of the popularity of the mild-moderate-severe (28%) and a net reduction on SFU and UTD (25 and 7). The Pelvic AP diameter was slightly increased (39%) while the Onen and ESPR remained uncommon (0.3 and 1%) (**Figure 2**, left).

The bivariate analysis (**Table 1**) showed significant differences in the type of responses. Three main variables affected these differences: The geographical area for favorite classification system, communication with providers, system used by providers and attempt to build a common system, the years of experience attempting to build a common system and willingness to change the preferred system, and the volume of cases per provider.

There were significant differences in preferred grading system related to the geographical area (**Supplementary Table 1**). Asia, Europe and Oceania prefer the Pelvic AP diameter (47, 45, and 57%) whereas Middle East/North Africa and North America prefer the SFU system (63 and 59%). South America did not show a marked difference among the Pelvic AP diameter and SFU (38 and 30%). Within geographic areas, there were major differences in communication with providers. The majority of

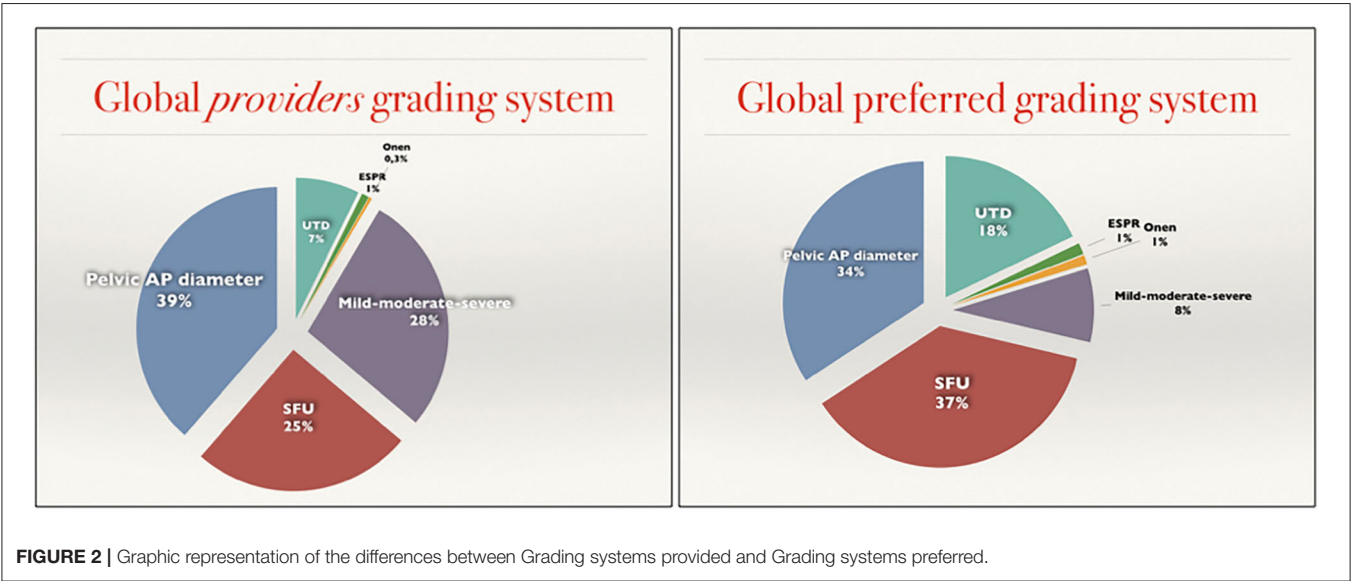
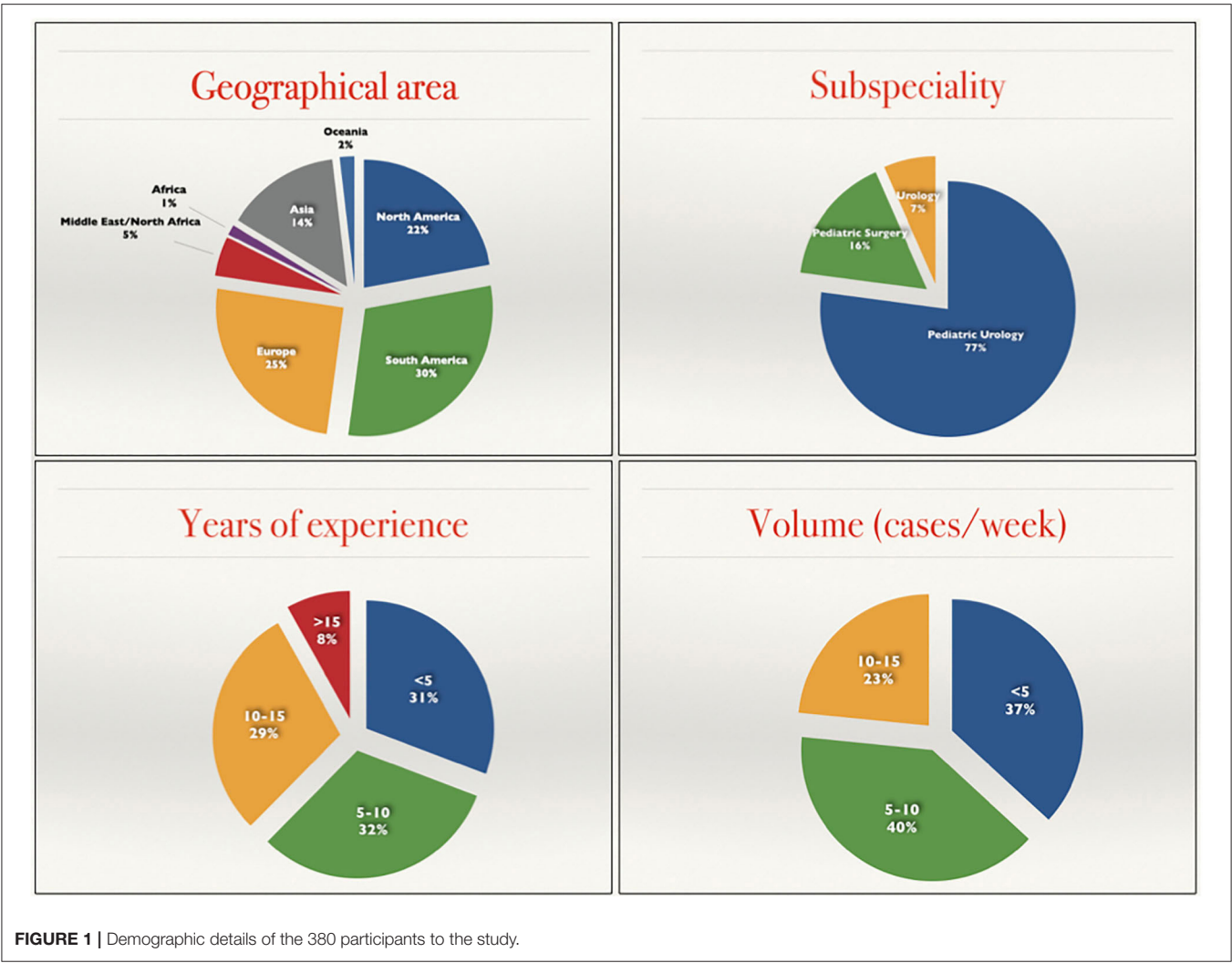


TABLE 1 | *P*-values corresponding to a G-test of independence between the variables Q5, Q7, Q8, ...Q13 and the demographic variables Q1, ..., Q4.

	Q1. What is your subspecialty?	Q2. What is your geographical area?	Q3. Years of experience in Pediatric Urology	Q4. How many cases of hydronephrosis you manage in a typical week?
Q5. When you deal with a case of hydronephrosis, which is your favorite classification system?	0.05201	0.00000007	0.3287	1.955e-06
Q7. Why do you prefer the system you use? (you can choose more than one)	0.4818	0.07535	0.7218	0.2789
Q8. What are the shortcomings of the system you use? (you can choose more than one)	0.9644	0.3354	0.6167	0.6515
Q9. Do you have direct communication with your radiology report providers?	0.3372	0.001802	0.1221	0.1835
Q10. If yes, how often?	0.4125	0.00004	0.938	0.257
Q11. Which is the most frequently used classification system you see in your practice (the one most used by your providers)? (you can choose more than one)	0.9974	0.0000005	0.2386	0.0004758
Q12. Did you attempt to build a common language for description of hydronephrosis among your own team?	0.1706	0.001403	0.008423	0.4134
Q13. Are you available to change your preference in case the majority of Pediatric Urologist prefers another grading system?	0.586	0.1987	0.0403	0.6104

We see that the responses to question Q5 depend on the demographic variables Q2 and Q4. Q9 is dependent on Q2. Q10 depends on Q2. The answers to Q11 depend on Q2 and Q4 while the answers to Q12 are associated with Q2 and Q3. Finally, the categories taken by Q13 depends on the categories taken by Q3. Bolded *P* values < 0.005.

the participants described direct communication to varying degrees (**Supplementary Table 2**). In Europe, North America and Oceania this is more common than in the rest of the world. The frequency of this contact is also different with the higher frequency in Europe and Oceania. The grading system used by providers also varied geographically (**Supplementary Table 3**). In all the regions except North America the most utilized system by the providers is the Pelvic AP diameter. In North America, the SFU system is the most frequently used. In most areas, there was an attempt to build a common system, but more common in Europe, South America, and Oceania (**Figure 3** and **Supplementary Table 4**).

Years of experience was associated with an increased attempt to build a common system (**Supplementary Table 5**). The willingness to change the preferred system (91%, range 88–98) revealed that those who most willing are the group with middle experience (10–15 years) (**Supplementary Table 6**).

The volume of cases also had an impact on the preferred grading system (**Supplementary Table 7**). SFU and UTD preference grew with increasing patient volume. In contrast, the low volume responders preferred the Pelvic AP diameter system (**Figure 3**). The system used by providers (**Supplementary Table 8**) was similar to the preferred grading system. Higher volumes correlated with preference for SFU and UTD and lower volumes with the mild-moderate-severe system.

The multivariate analysis revealed no statistically significant correlations between all the variables studied (two-dimensional correspondence analysis plot of the questionnaire data using the

package *ade4* in R with data points labeled by continents is available in the complementary documents of this manuscript).

The participants were able to express their opinions regarding the utility of each system by grading it from “very useful” to “useless” (question 6). This was also an open question permitting multiple responses. Scores were given according to the number of responses in each category except for “not known” which was not scored. In order to assign a numeric value to this answer, each category had a weighted multiplying factor as shown in **Table 2**. The highest scores for utility were obtained by the Pelvic AP diameter and the SFU systems. The systems categorized as “not known” by most of the participants were the ESPR and the Onen (112 and 127, respectively).

Participants were invited to express their opinion regarding the strengths of their preferred systems. Points of strength for mild-moderate-severe, Pelvic AP diameter, and SFU systems was “Familiarity” and “Simplicity.” In addition, “Good prognostic value” was a strength reported for the SFU and UTD systems. The most frequent shortcomings noted were principally that the system was “Not used universally.”

DISCUSSION

Prenatal and postnatal hydronephrosis is a very common condition affecting approximately 1% of pregnancies. In many countries/areas the role of pre and postnatal counseling and care for hydronephrosis is provided by Pediatric Urologist or by either Pediatric Surgeons or Adult Urologists dedicated to pediatric

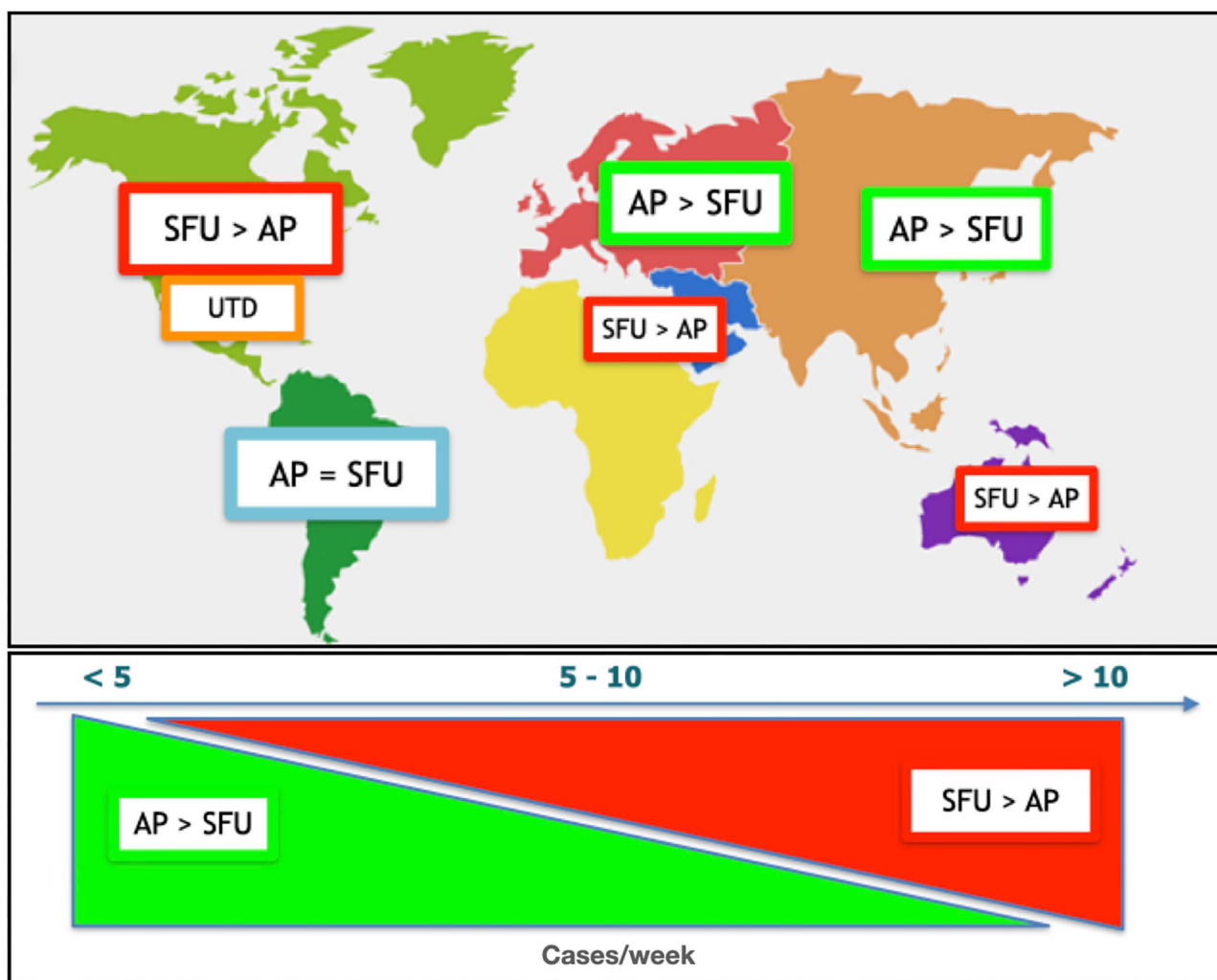


FIGURE 3 | Difference of preferences based on geographical provenience (Top) and cases per week volume (Bottom).

patients. The goal of a common and objective language in the description of the degree and characteristics of hydronephrosis along with prognostic clinical correlation has been attempted since the wide use of ultrasound as first line investigation in both the prenatal and postnatal period. Dhillon et al. published a detailed report correlating the degree of dilatation with the clinical outcome in terms of need for surgical intervention (5). Although many experienced physicians prefer to independently assess the radiological images rather than rely on reports, the images are not always available adding delays in management decision and timing of intervention.

Grading systems have evolved in complexity over time beginning with the simpler, classic “mild-moderate-severe” system (6) and the anterior-posterior diameter (7). In 1993 the Society for Fetal Urology proposed the SFU classification system for postnatal hydronephrosis (1), followed by the European Society for Pediatric Radiology which proposed its modified system by adding the anterior-posterior diameter (2). In 2007,

Onen presented his individual experience with a modified system aimed to better stratify the ultrasound characteristics of the hydronephrotic kidney and its clinical significance (3). Finally, a consensus among several societies of Pediatric Urology, Nephrology and Radiology was accomplished in 2014 and resulted in the Urinary Tract Dilatation system (4). This system introduced additional characteristics of the urinary tract not considered in the previous systems including ureteric dilation and bladder abnormalities and can be considered an integration of the SFU and anterior-posterior diameter systems.

The evolution of classification systems has attempted to improve prognostic ability by combining additional sonographic findings. The use of multiple different classification systems makes communication and translation of research findings difficult. Over the last 30 years, multiple studies have been done evaluating the strengths and challenges of the various classification systems. Considering multiple specialities, Zanetta et al. (8) demonstrated lack of agreement within different

TABLE 2 | Opinion of the responders of each system.

	Very useful (x4)	Somewhat useful (x3)	Minimally useful (x2)	Useless (x1)	SCORE	Not known
Mild-moderate-severe system	46 (184)	125 (375)	129 (258)	53	870	5
Pelvic AP Diameter measurements	184 (736)	137 (411)	31 (62)	4	1,213	2
Society of Fetal Urology system (1)	191 (764)	125 (375)	24 (48)	2	1,189	8
ESPR Pediatric Uroradiology Working Group grading (2)	29 (116)	138 (276)	63 (126)	10	528	112
Onen grading system (3)	22 (88)	120 (360)	64 (128)	17	593	127
Urinary Tract Dilation (UTD) classification system (4)	113 (452)	142 (426)	51 (102)	4	984	44

Bolded values of higher significance.

specialities involved in the management of hydronephrosis both in grading system and management. Our study uniquely evaluates opinions regarding the various pediatric hydronephrosis classification systems from a large number of surgical specialists from throughout the world.

Our study supports our hypothesis that there is no single preferred hydronephrosis grading system among pediatric surgeons and urologists. The geographical differences were subtle in some areas while particularly marked in others. This may reflect agreement between regional societies or presence of leadership opinions that influence preferences toward a particular system.

Our study is not without limitation. Although we had 380 respondents, it is not known how representative this group is of the global census of physicians that manage fetal and pediatric hydronephrosis. Currently there is no estimation of the number of physicians (pediatric urologists, pediatric surgeons) practicing worldwide. Based on the organization with the highest number of physicians dedicated to Pediatric Urology, the European Society for Pediatric Urology whose roster is of 790 members from different areas of the world (www.espu.org website) plus another 450 certified by SPU and SFU, it can be hypothesized that the number of respondents to the present survey represents a significant portion of the physicians managing cases of children with hydronephrosis. The utilization of multiple sources of engagement and repetition of the invitations was a strategy to enhance inclusion and representation as recommended by Ponto in the paper on surveys as a research tool (9).

The heterogeneity in “years of experience,” “subspecialty,” and “geographic area” are also limitations of the study. The lack of an overriding organization for physicians treating hydronephrosis necessitated broad solicitation of voluntary participation by physicians of differing backgrounds. Another limitation is that the opinions were expressed anonymously [although 284/380 (73%) participants voluntarily disclosed their identity] making it impossible to assess the validity of all responses.

CONCLUSION

The present survey demonstrates that there is no single preferred hydronephrosis grading system among pediatric surgeons and urologists. Despite a clear favorite, even with regional variations,

most of the physicians charged with the management of pediatric hydronephrosis prefer the SFU and APD systems because of familiarity and simplicity with these systems (37 and 34%, respectively). Respondents noted that their imaging providers most often report findings utilizing the mild-moderate-severe system or the APD measurements (28 and 39%, respectively) except for North America where the SFU system is more seen (50%). The greatest reported shortcoming of all the systems was the lack of universal utilization. Nearly all respondents were optimistic that if a consensus regarding a classification system was determined, they would be able to have this new system implemented at their institution. The observations taken from this study may serve as basis for the construction of a common worldwide system among physicians managing hydronephrosis and imaging providers. As APD and SFU are the preferred systems and the UTD a newer combination of both, it is possible that with time, UTD may become the universal language for reporting hydronephrosis. The result of this survey, however, shows that this time has not come yet.

DATA AVAILABILITY STATEMENT

The raw data supporting the conclusions of this article will be made available by the authors, without undue reservation.

AUTHOR CONTRIBUTIONS

SV, AB, JG, MM, CC, and P-JL: conception and design. SV, AB, JG, MM, CC, MF, HZ, and P-JL: acquisition of data. SV and ME: analysis and interpretation of data. SV, ME, JG, and CC: drafting of the manuscript. JG, CC, MF, and P-JL: critical revision of the manuscript for important intellectual content. ME: statistical analysis. All authors contributed to the article and approved the submitted version.

SUPPLEMENTARY MATERIAL

The Supplementary Material for this article can be found online at: <https://www.frontiersin.org/articles/10.3389/fped.2021.646517/full#supplementary-material>

Supplementary Figure 1 | Two-dimensional correspondence analysis plot of the questionnaire data using the package *ade4* in R. The data points are labeled by continents.

Supplementary Table 1 | Preferred system by geographical area.

Supplementary Table 2 | Communication with providers by geographical area.

Supplementary Table 3 | System by providers by geographical area.

Supplementary Table 4 | Attempt to build a common system by geographical area.

Supplementary Table 5 | Attempt to build a common system by years of experience.

Supplementary Table 6 | Availability to change the preferred system by years of experience.

Supplementary Table 7 | Preferred system by number of cases seen by week.

Supplementary Table 8 | System by providers by number of cases seen by week.

REFERENCES

1. Fernbach SK, Maizels M, Conway JJ. Ultrasound grading of hydronephrosis: introduction to the system used by the Society for Fetal Urology. *Pediatr Radiol.* (1993) 23:478–80.
2. Riccabona M, Avni FE, Blickman JG, Dacher JN, Darge K, Lobo ML, et al. Imaging recommendations in paediatric urology: minutes of the ESPR workgroup session on urinary tract infection, fetal hydronephrosis, urinary tract ultrasonography and voiding cystourethrography, Barcelona, Spain, June 2007. *Pediatr Radiol.* (2008) 38:138–45. doi: 10.1007/s00247-007-0695-7
3. Onen A. An alternative grading system to refine the criteria for severity of hydronephrosis and optimal treatment guidelines in neonates with primary UPJ-type hydronephrosis. *J Pediatr Urol.* (2007) 3:200–5. doi: 10.1016/j.jpuro.2006.08.002
4. Nguyen HT, Benson CB, Bromley B, Campbell JB, Chow J, Coleman B, et al. Multidisciplinary consensus on the classification of prenatal and postnatal urinary tract dilation (UTD classification system). *J Pediatr Urol.* (2014) 10:982–98. doi: 10.1016/j.jpuro.2014.10.002
5. Dhillon HK. Prenatally diagnosed hydronephrosis: the Great Ormond Street experience. *Br J Urol.* (1998) 81(Suppl. 2):39–44.
6. Ellenbogen PH, Scheible FW, Talner LB, Leopold GR. Sensitivity of gray scale ultrasound in detecting urinary tract obstruction. *Am J Roentgenol.* (1978) 130:731–3.
7. Grignon A, Filion R, Filiatrault D, Robitaille P, Homsy Y, Boutin H, et al. Urinary tract dilatation *in utero*: classification and clinical applications. *Radiology.* (1986) 160:645–7.
8. Zanetta VC, Rosman BM, Bromley B, Shipp TD, Chow JS, Campbell JB, et al. Variations in management of mild prenatal hydronephrosis among maternal-fetal medicine obstetricians, and pediatric urologists and radiologists. *J Urol.* (2012) 188:1935–9. doi: 10.1016/j.juro.2012.07.011
9. Ponto J. Understanding and evaluating survey research. *J Adv Pract Oncol.* (2015) 6:168–71.

Conflict of Interest: The authors declare that the research was conducted in the absence of any commercial or financial relationships that could be construed as a potential conflict of interest.

Copyright © 2021 Vallasciani, Bujons Tur, Gatti, Machado, Cooper, Farrugia, Zhou, El Anbari and Lopez. This is an open-access article distributed under the terms of the Creative Commons Attribution License (CC BY). The use, distribution or reproduction in other forums is permitted, provided the original author(s) and the copyright owner(s) are credited and that the original publication in this journal is cited, in accordance with accepted academic practice. No use, distribution or reproduction is permitted which does not comply with these terms.



Comparing Robot-Assisted Laparoscopic Pyeloplasty vs. Laparoscopic Pyeloplasty in Infants Aged 12 Months or Less

Yuenshan Sammi Wong, Kristine Kit Yi Pang and Yuk Him Tam*

Division of Paediatric Surgery and Paediatric Urology, Department of Surgery, Prince of Wales Hospital, The Chinese University of Hong Kong, Shatin, Hong Kong

OPEN ACCESS

Edited by:

Venkata R. Jayanthi,
Nationwide Children's Hospital,
United States

Reviewed by:

Baran Tokar,
Eskişehir Osmangazi University, Turkey
Andres Gomez Fraile,
University Hospital October 12, Spain
Alfredo Berrettini,
IRCCS Ca' Granda Foundation
Maggiore Policlinico Hospital, Italy
John Samuel Wiener,
Duke University, United States

*Correspondence:

Yuk Him Tam
pyhtam@surgery.cuhk.edu.hk

Specialty section:

This article was submitted to
Pediatric Urology,
a section of the journal
Frontiers in Pediatrics

Received: 29 December 2020

Accepted: 21 May 2021

Published: 14 June 2021

Citation:

Wong YS, Pang KKY and Tam YH
(2021) Comparing Robot-Assisted
Laparoscopic Pyeloplasty vs.
Laparoscopic Pyeloplasty in Infants
Aged 12 Months or Less.
Front. Pediatr. 9:647139.
doi: 10.3389/fped.2021.647139

Objective: To investigate the outcomes of minimally invasive approach to infants with ureteropelvic junction (UPJ) obstruction by comparing the two surgical modalities of robot-assisted laparoscopic pyeloplasty (RALP) and laparoscopic pyeloplasty (LP).

Methods: We conducted a retrospective review of all consecutive infants aged ≤ 12 months who underwent either LP or RALP in a single institution over the period of 2008–Jul 2020. We included primary pyeloplasty cases that were performed by or under the supervision of the same surgeon.

Results: Forty-six infants (LP = 22; RALP = 24) were included with medians of age and body weight at 6 months (2–12 months) and 8.0 kg (5.4–10 kg), respectively. There was no difference between the two groups in the patients' demographics and pre-operative characteristics. All infants underwent LP or RALP successfully without conversion to open surgery. None had intraoperative complications. Operative time (OT) was 242 min (SD = 59) in LP, compared with 225 min (SD = 39) of RALP ($p = 0.25$). Linear regression analysis showed a significant trend of decrease in OT with increasing case experience of RALP ($p = 0.005$). No difference was noted in the post-operative analgesic requirement. RALP was associated with a shorter hospital length of stay than LP (3 vs. 3.8 days; $p = 0.009$). 4/22 (18%) LP and 3/24 (13%) RALP developed post-operative complications ($p = 0.59$), mostly minor and stent-related. The success rates were 20/22 (91%) in LP and 23/24 (96%) in RALP ($p = 0.49$).

Conclusions: Pyeloplasty by minimally invasive approach is safe and effective in the infant population. RALP may have superiority over LP in infants with its faster recovery and a more manageable learning curve to acquire the skills.

Keywords: ureteropelvic junction obstruction, infant, standard laparoscopy, pyeloplasty in infants, robot assisted laparoscopy

INTRODUCTION

Previous studies of meta-analysis have shown that both laparoscopic pyeloplasty (LP) and robot-assisted laparoscopic pyeloplasty (RALP) are viable options to treat ureteropelvic junction (UPJ) obstruction in children with the benefits of shorter hospital stay and decreased morbidity while maintaining a success rate comparable to open pyeloplasty (OP) (1–3).

The contemporary evidence of performing pyeloplasty by minimally invasive approach in the infant population, however, are less robust than in older children as there are few comparative studies ever published (4–6).

The expanding interest in minimally invasive pyeloplasty in children is mainly brought by the momentum of the robotic technology. National trends study in the United States between 2003 and 2015 showed that LP decreased annually by a rate of 12% while RALP grew by 29% annually (7). By 2015, RALP accounted for 40% of total cases and comprised 84% of cases among adolescents (7). A big contrast, however, was noted in the infant population in which 85% of cases were OP while RALP and LP accounted for 10 and 5%, respectively in 2015 (7). Adoption of minimally invasive approach in infants has been slow due to the perceived technical challenges associated with the anatomical and physiological constraints of infants and the high success rate by OP (5, 6, 8). Infants were excluded in some of the comparative studies (9, 10).

Our institution has adopted the minimally invasive approach for correction of UPJ obstruction across the entire pediatric age groups for two decades (11). LP had been our standard until Jan 2014 when it was replaced by RALP. In this study we aimed to compare the outcomes of the two minimally invasive modalities in infants. We hypothesized that RALP has superiority over LP in infants.

MATERIALS AND METHODS

After getting the approval of the clinical research ethics committee of our institution, we retrospectively reviewed the medical records of all consecutive infants aged 12 months or less who underwent either LP or RALP for UPJ obstruction in our institution over the period of 2008–July 2020. We included those primary pyeloplasties which were performed by or under the supervision of the senior author of this study using standardized surgical techniques, and similar pre- and post-operative management protocols. Re-operative pyeloplasty was excluded. All the LP cases were recruited before Jan 2014, and since then all the infant pyeloplasties had been performed by the robotic approach.

Before surgery, all patients had ultrasound (US) and MAG3 scan which showed Society of Fetal Urology (SFU) grade 3 or 4 hydronephrosis, and obstructed drainage with diuretic *t*-half > 20 min of the affected kidney. Indications for surgery included progressive worsening of hydronephrosis in serial US, drop in split renal function <45% in the initial or repeat MAG3, giant hydronephrosis with mass effect requiring percutaneous nephrostomy (PCN) decompression in neonatal period, and urosepsis.

All patients had double-J stent inserted at the time of pyeloplasty and was removed in 3–4 weeks. Routine post-operative evaluation included both US and MAG3 scan in 2–3 months after double-J stent removal. US was then repeated in 6 months and then yearly if the initial post-operative investigations suggested successful pyeloplasty. Success of surgery was defined by absence of repeat intervention plus 1 or more of the

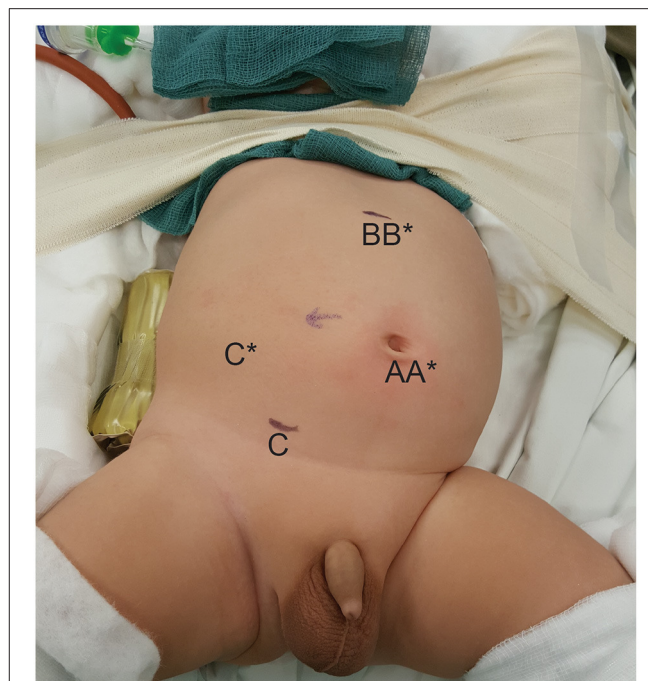


FIGURE 1 | Positions of the ports in a 3-month-old infant who underwent right-sided RALP. A, B, and C, positions of the ports in RALP; A*, B*, and C*, positions of the ports if the procedure were LP.

following radiological criteria: (i) resolution of hydronephrosis with anteroposterior diameter (APD) of renal pelvis <10 mm in US, (ii) improved drainage in MAG3 scan with diuretic *t*-half < 20 min, (iii) reduction in hydronephrosis with stable split renal function in MAG3 scan.

We collected data on patients' demographics, clinical characteristics at baseline, post-operative radiological findings, operative details, complications, analgesic requirement, length of hospital stay (LOS), and follow-up period. Operative time (OT) was defined by the time interval from the first skin incision to completion of wound closure. Post-operative complications were graded according to the Clavien classification (12).

We have previously described our technique of LP and RALP (13). Transperitoneal approach was used in both LP and RALP. The surgical steps of the two approaches were almost identical. Only three ports were used in both approaches with a single transabdominal hitching suture to lift and stabilize the renal pelvis. No accessory port was used in RALP. We used 3-mm instruments in LP and 8-mm instruments in RALP. The initial cases of RALP were performed by the da Vinci S model (Intuitive Surgical, Sunnyvale, CA) which was subsequently replaced by the Xi model. In RALP, we placed a purse-string suture to tighten the musculofascial defect around the camera port at the umbilicus and the suture was further tied onto the short rubber latex tube placed around the port. The two working ports were placed at sub-xiphoid and suprainguinal region just lateral to the inferior epigastric vessels under the laparoscopic view (**Figure 1**). A double-J stent was routinely inserted by antegrade method

TABLE 1 | Summary of the baseline characteristics of the two groups.

	LP; <i>n</i> = 22	RALP; <i>n</i> = 24	<i>p</i> -values
Median age in months at the time of surgery (range)	6 (3–12)	5.5 (2–12)	0.97
Median body weight in kg at the time of surgery (range)	8.5 (5.4–10)	7.9 (5.7–10)	0.56
Gender: male/female	17/5	20/4	0.61
Laterality: left/right	16/6	13/11	0.19
Antenatal diagnosis	22/22	24/24	NA
Temporary PCN before surgery	3/22	6/24	0.33
Pre-operative imaging:			
APD in US	31 ± 12 mm	32 ± 12 mm	0.89
SRF in MAG3	44.8 ± 6.5%	45.6 ± 9.5%	0.74

LP, laparoscopic pyeloplasty; RALP, robot-assisted laparoscopic pyeloplasty; US, ultrasound; APD, anteroposterior diameter; SRF, split renal function; PCN, percutaneous nephrostomy; NA, not applicable.

over guidewire introduced transabdominally. Cystoscopy would be used if difficulty was encountered in passing the double-J stent into bladder by antegrade method. Intraoperative fluoroscopy was used in every case to confirm the position of the distal end of double-J stent.

Comparative analysis was performed between the two groups. Primary outcome was success of surgery. Secondary outcomes were other perioperative parameters. Categorical data were compared using chi-square or Fisher exact test. Continuous data were expressed as median with range or mean with standard deviation (SD). Continuous data were compared by Student *t* test or Mann-Whitney test as appropriate. Linear regression was used to investigate the trend of OT against increasing case experience. A *p*-value of < 0.05 was considered to be significant.

RESULTS

A total of 46 infants (LP = 22; RALP = 24) were included in this study. The medians of age and body weight were 6 months (2–12 months) and 8.0 kg (5.4–10 kg), respectively. There was no difference between the two groups in the patients' demographics and clinical characteristics at baseline (Table 1). No OP was performed for infants during the study period.

All infants underwent LP or RALP successfully without conversion to open surgery or requirement of additional ports. None of the patients had intraoperative complications such as vascular or bowel injury, and none required blood transfusion. The estimated blood loss recorded was minimal with 5 ml or less.

Table 2 summarized the perioperative parameters and post-pyeloplasty outcomes. OT was 242 min (SD = 59) in LP, compared with 225 min (SD = 39) of RALP (*p* = 0.25). Linear regression analysis showed a significant trend of decrease in OT with increasing case experience of RALP (*p* = 0.005) (Figure 2).

No difference was noted in the post-operative analgesic requirement. RALP was associated with a shorter LOS of 3

TABLE 2 | Summary of the perioperative parameters and surgical success of the two groups.

	LP; <i>n</i> = 22	RALP; <i>n</i> = 24	<i>p</i> -values
OT in minutes	242 ± 59	225 ± 39	0.25
Intraoperative cystoscopy	2/22	2/24	0.93
Aberrant crossing vessels	0/22	3/24	0.09
Participation of surgeon-in-training	7/22	12/24	0.21
Conversion to open or placement of additional ports	Nil	Nil	NA
Intraoperative complications or blood transfusion	Nil	Nil	NA
Mean number of doses of oral acetaminophen per patient	3.8 ± 2.5	4.3 ± 3.2	0.55
Mean number of doses of intramuscular narcotics per patient	0.15 ± 0.50	0.04 ± 0.20	0.31
LOS in days	3.8 ± 1.3	3.0 ± 0.3	0.009
Post-operative complications (%)	4/22 (18)	3/24 (13)	0.59
Clavien Grade I – II	Prolonged ileus = 1 Stent-related UTI = 3	Stent-related UTI = 2	
Clavien Grade IIIb		Proximal migration of Double-J stent = 1	
Operative success (%)	20/22 (91)	23/24 (96)	0.49
Mean follow-up in months	40 ± 16	23 ± 12	<0.001

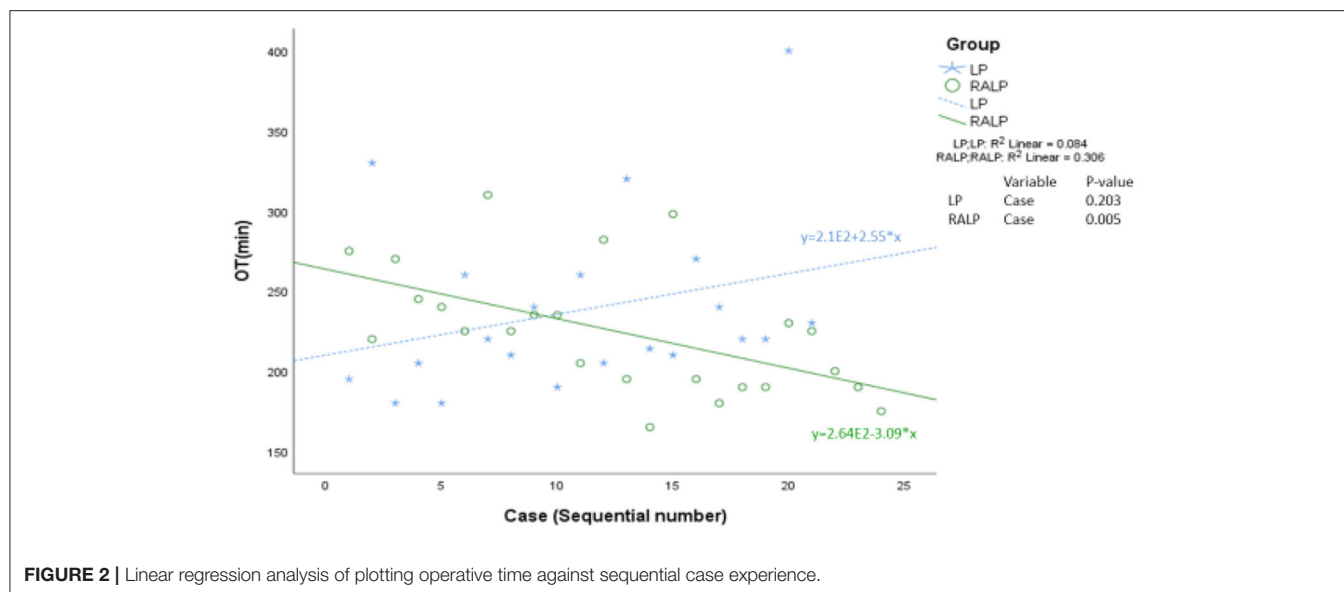
LP, laparoscopic pyeloplasty; RALP, robot-assisted laparoscopic pyeloplasty; OT, operative time; LOS, length of stay; UTI, urinary tract infection; NA, not applicable.

days (SD = 0.3) compared with 3.8 days (SD = 1.3) of LP (*p* = 0.009). 4/22(18%) LP and 3/24(13%) RALP developed post-operative complications (*p* = 0.59). All but one of the complications were minor of Clavien grade I-II (prolonged ileus = 1; stent-related urinary tract infection = 5). The only Clavien grade III complication happened in the RALP group due to proximal migration of the double-J stent which was removed cystoscopically by a Fr 4 Amplatz Gooseneck snare catheter.

The success rates were 20/22(91%) in LP and 23/24(96%) in RALP (*p* = 0.49). The two failures in LP underwent redo-LP as they occurred before the introduction of RALP in our institution, and the single failure in RALP was treated by redo-RALP. All three redo-pyeloplasties were successful.

DISCUSSION

The existing data of minimally invasive pyeloplasty in infants are derived from case series (14, 15), comparative studies with OP (16, 17), and comparative studies with older children (18, 19). To the best of our knowledge, the present study is the first single-institution study to compare LP vs. RALP in infants. Others



have reported their findings by comparing two cohorts of infants who underwent LP and RALP in two different institutions (20). Our study design of recruiting patients managed by the same surgeon may reduce the confounding effects caused by variations in surgical techniques, post-operative protocols, and in-patient practices which happened in multi-institutional studies (15, 20).

Our finding of 91% success rate of LP is similar to 92% reported by previous studies (14, 20) in infants. Concern has been raised whether the failure rate of LP could be higher in infants than in older children (21). A recent systematic review found an average success rate of 96.9% for LP in children (4). The authors, however, reported that there were very few studies targeted at infants (4). Failures of LP in infants may have been underreported, and the world-wide declining interest in LP has hampered further studies in infants for whom few surgeons perform LP (7).

The largest published series of RALP in infants was from a multi-institutional study which recruited 60 patients and reported 91% success rate (15). Two recent single-institution studies reported 93.8 and 94.1% success rates of RALP in 16 and 34 infants, respectively (18, 19). In both studies the authors did not note any difference in success rates between infants and older children (18, 19).

The latest meta-analysis performed by Taktak et al. included eight more studies comparing RALP vs. LP in pediatric populations (22) than the previous meta-analysis by Cundy et al. (1). The authors found a significantly higher success rate and shorter LOS in RALP than LP in children (22). Our findings of 96% success rate in RALP did not reach significant difference when compared with the 91% of LP. Further studies are warranted to investigate whether the potential superiority of pediatric RALP over LP in treatment success can be expanded to the infant population.

A bi-institutional study reported a significantly shorter LOS of RALP than LP in infants (1 vs. 7 days) (20). The authors, however, explained the finding by the difference in the healthcare systems

and hospitalization policies of the two institutions where LP and RALP were separately performed (20). We found a statistically significant but small difference in LOS in favor of RALP (3 vs. 3.8 days). Our finding, however, needs to be interpreted with caution. The clinical significance of a difference in LOS of <1 day is questionable. Given the small number in either group, any outliers might have significant effect in the statistical analysis. Although all our study subjects were under the care of the same surgeon over the entire study period, we cannot exclude the possibility of a slight change in discharge criteria over time which might have disadvantaged the LP group in LOS. Nevertheless, it is our subjective experience that the robotic technology enhances the precision in tissue approximation and suturing, and thus has the potential to promote a faster recovery by allowing better tissue healing with less subclinical urine leakage.

It is debatable whether 5- or 8-mm instruments should be used in infant RALP. Use of 5-mm instruments allows a smaller incision at the cost of requiring a longer intracorporeal length for articulation due to its pulley system, which is the concern raised by some surgeons (8, 15). Proponents of 5-mm instruments, however, have reported the safety and similarly high success rates in infant and non-infant pediatric populations (18, 19). We have had no experience in using 5-mm instruments which are not supported by the current da Vinci Xi platform. Our findings of the post-operative analgesic requirement do not suggest any significant negative effects associated with the use of 8-mm ports in RALP when compared with LP using 5- and 3-mm ports. Nevertheless, we fully echo with others the need of the development of miniaturized robotic instruments specific for infants and small children (23).

Our OT of 225 min in infant RALP is much longer than the 115 and 144 min reported by master surgeons working at high-volume centers (16, 18), but similar to the 232 min reported by a multi-institutional study involving teaching hospitals with fellowship or residency training programs (15). Given our small case volume, we are still at a distance from achieving mastery in

infant RALP. Our OT also included the time spent on undocking and redocking for fluoroscopy, and some cases involved training of surgeons who had not attained competency in pediatric RALP. We did not detect any difference in OT between the two groups of LP and RALP. However, the additional time spent on docking in RALP might suggest a faster procedure in RALP than LP, particularly during the intracorporeal suturing which the robotic platform alleviates much of the technical difficulty. The linear regression analysis demonstrated a significant trend of decrease in OT with increasing experience in RALP, and a trend of OT in favor of RALP after the first 10 cases. Given the two groups were comparable in other study variables, our finding suggests a faster learning curve of RALP than LP in infants.

Despite our long history of performing pediatric pyeloplasty by minimally invasive approach, our institution had only one surgeon left who was competent to perform LP in 2013. Since the adoption of RALP in 2014, there are currently three surgeons in our institution who are competent to perform pediatric RALP. We agree with others that the robotic technology offers the advantage of creating a more manageable learning curve for minimally invasive pyeloplasty, thus making it more accessible particularly to the infant population in which application of LP is even more challenging than older children (4).

We followed the technical tricks in infant RALP as described before with some modifications. Air leakage at the port site is more of a concern in infants than older children given the thin abdominal wall and its laxity in infants. We prevent air leakage by placing a purse-string suture to tighten the musculo-fascial defect around the camera port at the umbilicus and the suture was further tied onto the short rubber latex tube placed around the port to prevent it from accidentally slipping out. We did not anchor the two working ports to skin by sutures, and we made the incisions precisely such that the wounds were not any bigger than the trocars. Creating an adequate working space both intracorporeally and extracorporeally is critical to success in performing RALP in infants. Our ports positioning allows adequate distance to prevent trocar collision while avoiding the risk of bladder injury if the ports are all placed in midline as preferred by some surgeons (8, 15, 18). Elevation of the ports against the abdominal wall, and keeping a minimal depth of working ports inside the peritoneal cavity are both pivotal in maximizing the intracorporeal working space for small infants. It should be emphasized that excessive force in traction or grasping tissues may go unnoticed due to lack of tactile feedback of the robotic instruments, and extra caution must be exercised in infants whose tissues are more fragile than older children.

We acknowledged the limitations of our study including the retrospective nature, small case numbers over a long review period, lack of breakdown of OT, difference in follow-up periods, and lack of details of participation of surgeon-in-training. Patients were assigned the surgical approach chronologically without any randomization, and all the RALP cases were recruited after we had stopped performing LP. The prior acquisition of skills in LP may have given advantage in subsequent RALP. Our study findings did not allow estimation of the number of cases required to complete the learning phase of either technique. The generalizability of our data from a single

institution is questionable, although some of the potential bias may be reduced by the standardized surgical techniques and management protocols. It was beyond the scope of the present study to investigate and compare the costs of the two procedures. The public healthcare service in our society is heavily subsidized by government such that it was almost free of charge for our patients' families whether the procedure was LP or RALP. There are no data in the billing system or from the finance department of our institution that we can retrieve to investigate the costs incurred from each surgical procedure. There is no question that it is a huge investment in purchasing a robotic platform, and the costs for maintenance and the disposable instruments are substantial. Previous single-institution studies have reported no difference in cost when RALP was compared with OP in infants (17), and when RALP was compared with LP in pediatric patients (24). At a national level, pediatric RALP was found to be associated with a higher cost than OP, and the relatively small number of pediatric pyeloplasty even in high-volume children's hospitals remained to be a limiting factor for reducing the cost of RALP (7). The robotic platform in our institution is shared among pediatric and adult patients. The high-volume adult robotic surgeries might give us an advantage in cost-effectiveness of performing pediatric RALP.

Given the paucity of data comparing the two minimally invasive modalities in infants, we believe our findings would contribute to the existing literature with addition evidence despite all the study limitations. Both LP and RALP are safe and effective modalities via a minimally invasive approach for correction of UPJ obstruction in infants. RALP appears to have superiority over LP in infants with its faster recovery, and a more manageable learning curve for skills acquisition. Our findings support the application of RALP across the entire pediatric population including infants.

DATA AVAILABILITY STATEMENT

The datasets presented in this article are not readily available because dataset not allowed to be accessed by outside of our institution. Requests to access the datasets should be directed to Yuk Him Tam, pyhtam@surgery.cuhk.edu.hk.

ETHICS STATEMENT

The studies involving human participants were reviewed and approved by Joint CUHK-NTEC Clinical Research Ethics Committee. Written informed consent from the participants' legal guardian/next of kin was not required to participate in this study in accordance with the national legislation and the institutional requirements.

AUTHOR CONTRIBUTIONS

YW: study design, data collection and analysis, literature review, and draft manuscript. KP: data collection and analysis and literature review. YT: study design, literature review, and revised manuscript. All authors contributed to the article and approved the submitted version.

REFERENCES

- Cundy TP, Harling L, Hughes-Hallett A, Mayer EK, Najmaldin AS, Athanasiou T, et al. Meta-analysis of robot-assisted vs conventional laparoscopic and open pyeloplasty in children. *BJU Int.* (2014) 114:582–94. doi: 10.1111/bju.12683
- Mei H, Pu J, Yang C, Zhang H, Zheng L, Tong Q. Laparoscopic versus open pyeloplasty for ureteropelvic junction obstruction in children: a systematic review and meta-analysis. *J Endourol.* (2011) 25:727–36. doi: 10.1089/end.2010.0544
- Huang Y, Wu Y, Shan W, Zeng L, Huang L. An updated meta-analysis of laparoscopic versus open pyeloplasty for ureteropelvic junction obstruction in children. *Int J Clin Exp Med.* (2015) 8:4922–31.
- Andolfi C, Adamic B, Oommen J, Gundeti MS. Robot-assisted laparoscopic pyeloplasty in infants and children: is it superior to conventional laparoscopy? *World J Urol.* (2020) 38:1827–33. doi: 10.1007/s00345-019-02943-z
- Villanueva J, Killian M, Chaudhry R. Robotic urologic surgery in the infant: a review. *Curr Urol Rep.* (2019) 20:35. doi: 10.1007/s11934-019-0902-8
- Passoni NM, Peters CA. Managing ureteropelvic junction obstruction in the young infant. *Front Pediatr.* (2020) 8:242. doi: 10.3389/fped.2020.00242
- Varda BK, Wang Y, Chung BI, Lee RS, Kurtz MP, Nelson CP, et al. Has the robot caught up? National trends in utilization, perioperative outcomes, and cost for open, laparoscopic, and robotic pediatric pyeloplasty in the United States from 2003 to 2015. *J Pediatr Urol.* (2018) 14:336.e1–8. doi: 10.1016/j.jpuro.2017.12.010
- Boysen WR, Gundeti MS. Robot-assisted laparoscopic pyeloplasty in the pediatric population: a review of technique, outcomes, complications, and special considerations in infants. *Pediatr Surg Int.* (2017) 33:925–35. doi: 10.1007/s00383-017-4082-7
- Esposito C, Masieri L, Castagnetti M, Sforza S, Farina A, Cerulo M, et al. Robot-assisted vs laparoscopic pyeloplasty in children with uretero-pelvic junction obstruction (UPJO): technical considerations and results. *J Pediatr Urol.* (2019) 15:667.e1–8. doi: 10.1016/j.jpuro.2019.09.018
- Gatti JM, Amstutz SP, Bowlin PR, Stephany HA, Murphy JP. Laparoscopic vs open pyeloplasty in children: results of a randomized, prospective, controlled trial. *J Urol.* (2017) 197:792–7. doi: 10.1016/j.juro.2016.10.056
- Yeung CK, Tam YH, Sihoe JD, Lee KH, Liu KW. Retroperitoneoscopic dismembered pyeloplasty for pelvi-ureteric junction obstruction in infants and children. *BJU Int.* (2001) 87:509–13. doi: 10.1046/j.1464-410X.2001.00129.x
- Dindo D, Demartines N, Clavien PA. Classification of surgical complications: a new proposal with evaluation in a cohort of 6336 patients and results of a survey. *Ann Surg.* (2004) 240:205–13. doi: 10.1097/01.sla.0000133083.54934.ae
- Tam YH, Pang KKY, Wong YS, Chan KW, Lee KH. From laparoscopic pyeloplasty to robot-assisted laparoscopic pyeloplasty in primary and reoperative repairs for ureteropelvic junction obstruction in children. *J Laparoendosc Adv Surg Tech A.* (2018) 28:1012–8. doi: 10.1089/lap.2017.0561
- Turner RM, II, Fox JA, Tomaszewski JJ, Schneck FX, Docimo SG, Ost MC. Laparoscopic pyeloplasty for ureteropelvic junction obstruction in infants. *J Urol.* (2013) 189:1503–7. doi: 10.1016/j.juro.2012.10.067
- Avery DI, Herbst KW, Lendvay TS, Noh PH, Dangle P, Gundeti MS, et al. Robot-assisted laparoscopic pyeloplasty: multi-institutional experience in infants. *J Pediatr Urol.* (2015) 11:139.e1–5. doi: 10.1016/j.jpuro.2014.11.025
- Bansal D, Cost NG, DeFoor WR, Jr, Reddy PP, Minevich EA, Vanderbrink BA, et al. Infant robotic pyeloplasty: comparison with an open cohort. *J Pediatr Urol.* (2014) 10:380–5. doi: 10.1016/j.jpuro.2013.10.016
- Dangle PP, Kearns J, Anderson B, Gundeti MS. Outcomes of infants undergoing robot-assisted laparoscopic pyeloplasty compared to open repair. *J Urol.* (2013) 190:2221–6. doi: 10.1016/j.juro.2013.07.063
- Baek M, Silay MS, Au JK, Huang GO, Elizondo RA, Puttmann KT, et al. Does the use of 5 mm instruments affect the outcomes of robot-assisted laparoscopic pyeloplasty in smaller working spaces? A comparative analysis of infants and older children. *J Pediatr Urol.* (2018) 14:537.e1–6. doi: 10.1016/j.jpuro.2018.06.010
- Kawal T, Srinivasan AK, Shrivastava D, Chu DI, Van Batavia J, Weiss D, et al. Pediatric robotic-assisted laparoscopic pyeloplasty: does age matter? *J Pediatr Urol.* (2018) 14:540.e1–6. doi: 10.1016/j.jpuro.2018.04.023
- Neheman A, Kord E, Zisman A, Darawsha AE, Noh PH. Comparison of robotic pyeloplasty and standard laparoscopic pyeloplasty in infants: a bi-institutional study. *J Laparoendosc Adv Surg Tech A.* (2018) 28:467–70. doi: 10.1089/lap.2017.0262
- Farhat WA. Editorial comment on “Laparoscopic pyeloplasty for ureteropelvic junction obstruction in infants”. *J Urol.* (2013) 189:1506–7. doi: 10.1016/j.juro.2012.10.134
- Taktak S, Llewellyn O, Aboelsoud M, Hajibandeh S, Hajibandeh S. Robot-assisted laparoscopic pyeloplasty versus laparoscopic pyeloplasty for pelvi-ureteric junction obstruction in the paediatric population: a systematic review and meta-analysis. *Ther Adv Urol.* (2019) 11:1756287219835704. doi: 10.1177/1756287219835704
- Kawal T, Sahadev R, Srinivasan A, Chu D, Weiss D, Long C, et al. Robotic surgery in infants and children: an argument for smaller and fewer incisions. *World J Urol.* (2020) 38:1835–40. doi: 10.1007/s00345-019-02765-z
- Casella DP, Fox JA, Schneck FX, Cannon GM, Ost MC. Cost analysis of pediatric robot-assisted and laparoscopic pyeloplasty. *J Urol.* (2013) 189:1083–6. doi: 10.1016/j.juro.2012.08.259

Conflict of Interest: The authors declare that the research was conducted in the absence of any commercial or financial relationships that could be construed as a potential conflict of interest.

Copyright © 2021 Wong, Pang and Tam. This is an open-access article distributed under the terms of the Creative Commons Attribution License (CC BY). The use, distribution or reproduction in other forums is permitted, provided the original author(s) and the copyright owner(s) are credited and that the original publication in this journal is cited, in accordance with accepted academic practice. No use, distribution or reproduction is permitted which does not comply with these terms.



Variations in the Density and Distribution of Cajal Like Cells Associated With the Pathogenesis of Ureteropelvic Junction Obstruction: A Systematic Review and Meta-Analysis

U. M. J. E. Samaranayake^{1,2}, Y. Mathangasinghe^{2,3*}, U. A. Liyanage², M. V. C. de Silva⁴, M. C. Samarasinghe⁵, S. Abeygunasekera⁶, A. K. Lamaheewage⁶ and A. P. Malalasekera²

¹ Department of Anatomy, Faculty of Medicine, Sabaragamuwa University of Sri Lanka, Ratnapura, Sri Lanka, ² Department of Anatomy, Faculty of Medicine, University of Colombo, Colombo, Sri Lanka, ³ Proteostasis and Neurodegeneration Laboratory, Australian Regenerative Medicine Institute, Monash University, Clayton, VIC, Australia, ⁴ Department of Pathology, Faculty of Medicine, University of Colombo, Colombo, Sri Lanka, ⁵ Department of Surgery, Faculty of Medicine, University of Colombo, Colombo, Sri Lanka, ⁶ Lady Ridgeway Hospital for Children, Colombo, Sri Lanka

OPEN ACCESS

Edited by:

Abdurrahman Onen,
Onen Pediatric Urology Center, Turkey

Reviewed by:

Roberto Iglesias Lopes,
Hospital for Sick Children, Canada
Ali Avanoğlu,
Ege University, Turkey

*Correspondence:

Y. Mathangasinghe
yasith@anat.cmb.ac.lk

Specialty section:

This article was submitted to
Pediatric Urology,
a section of the journal
Frontiers in Surgery

Received: 06 June 2021

Accepted: 30 June 2021

Published: 28 July 2021

Citation:

Samaranayake UMJE, Mathangasinghe Y, Liyanage UA, de Silva MVC, Samarasinghe MC, Abeygunasekera S, Lamaheewage AK and Malalasekera AP (2021) Variations in the Density and Distribution of Cajal Like Cells Associated With the Pathogenesis of Ureteropelvic Junction Obstruction: A Systematic Review and Meta-Analysis. *Front. Surg.* 8:721143. doi: 10.3389/fsurg.2021.721143

Introduction: Cajal like cells (CLCs) in the upper urinary tract have an ability to generate coordinated spontaneous action potentials and are hypothesized to help propel urine from renal pelvis into the ureter. The objective of this review was to describe the variations in the density and distribution of CLCs associated with ureteropelvic junction obstruction (UPJO).

Materials and Methods: Studies comparing the density and distribution of CLCs in the human upper urinary tract in patients with UPJO and healthy controls were included in this systematic review. We searched online electronic databases; Ovid MEDLINE, Scopus, PubMed and Cochrane reviews for the studies published before October 31, 2020. A meta-analysis was conducted to compare the density of CLCs at the ureteropelvic junction (UPJ) in patients with UPJO and matched controls.

Results: We included 20 and seven studies in the qualitative and quantitative synthesis, respectively. In majority (55%) CLCs were located between the muscle layers of the upper urinary tract. The CLC density in the UPJ gradually increased with aging in both healthy subjects and patients with UPJO. The pooled analysis revealed that the density of CLCs at the UPJ was significantly low in patients with UPJO compared to the controls (SMD = -3.00, 95% CI = -3.89 to -2.11, $p < 0.01$).

Conclusions: The reduction in CLC density at the UPJ in patients with UPJO suggests a contribution from CLCs in the pathogenesis of UPJO. Since age positively correlates with CLC density, it is imperative to carefully match age when conducting case control studies comparing the CLC density and distribution.

Protocol Registration Number: CRD42020219882.

Keywords: interstitial cells of Cajal, Cajal like cells, ureteropelvic junction obstruction, density, aging

INTRODUCTION

Primary ureteropelvic junction obstruction (UPJO) is the most common congenital abnormality causing hydronephrosis in children (1) which affects 1 in 750–1,500 newborns annually (2–4). Structurally, the UPJO is characterized by a narrowed segment of the ureteropelvic junction (UPJ) containing atrophied smooth muscles and a hypertrophied segment proximal to the obstruction with increased collagen deposition (5). The widely accepted theory for the pathogenesis of UPJO is the disruption of coordinated unidirectional smooth muscle contractions, leading to dampening of peristaltic waves that propels urine downward from the renal pelvis to the ureter (6). Nevertheless, the exact mechanism of how these unidirectional contractions are coordinated in healthy ureteropelvic junction remains a mystery. Nearly a century ago Santiago Ramón y Cajal discovered a cell, later named in his honor, which has a regulatory role in smooth muscle contractility. These cells form a plexus that runs between the gut muscle layers, with processes extending from the ganglion cells of Auerbach plexus and nerve terminals residing on the plasmalemma of smooth muscle cells (7). These cells express c-kit (CD177) encoding receptor tyrosine kinase in their cytoplasmic membrane, which allow visualization of them using immunostaining (8). Reduction in the density of intestinal Cajal cells was later found to be associated with motility disorders of the gastrointestinal system such as congenital pyloric stenosis, achalasia cardia, Hirschsprung's disease and chronic intestinal pseudo obstruction (9–12).

Huizinga and Faussone-Pellegrini (13) reported the presence of different subtypes of Cajal cells, termed Cajal like cells (CLCs), outside the gastrointestinal tract with unique ultrastructural characteristics that help distinguish them from other cell types expressing c-kit such as mast cells, glial cells and melanocytes. The CLCs in the urinary tract have a stellate shape or a fusiform cell body with two distinct dendrites (14, 15). Subsequently, CLCs were identified in many organs including urinary tract, vagina, blood vessels and glands (13, 16, 17). The CLCs in the upper urinary tract in guinea pigs generate and amplify action potentials both in the renal pelvis and the ureter (18, 19), suggesting a unique role of CLCs in maintaining a unidirectional flow of urine at the UPJ (20, 21). With the discovery of an intrinsic motility action of the human UPJ (20), the CLCs were considered to be the pacemaker regulating the expulsion of urine at the UPJ. Nonetheless, the postulated role of CLCs in the pathogenesis of UPJO was challenged since the early studies failed to demonstrate a consistent decrease in the density of the CLCs at the UPJ in patients with UPJO (22, 23). These contradicting results led to further studies that primarily focused on the functions of the CLCs which generated clues on the pathogenesis of UPJO.

Despite decades of research, the exact pathogenic mechanism (s) of primary UPJO remains enigmatic. In this review, we provide a comprehensive analysis of the density and distribution of CLCs in the upper urinary tract associated with the UPJO and mechanistic insights to the pathophysiology of this disease. Moreover, we critically evaluate the methodological inaccuracies of certain studies which may have led to false assumptions

regarding the association of the density of the CLCs at the UPJ with the UPJO.

MATERIALS AND METHODS

Protocol and Registration

We conducted a systematic review and meta-analysis according to the Preferred Reporting Items for Systematic Reviews and Meta-Analyses (PRISMA) guidelines (24). The study protocol was documented in advance in the International Prospective Register of Systematic Reviews (PROSPERO) online database (protocol registration number: CRD42020219882).

Eligibility Criteria

Studies comparing the density and/or distribution of CLCs in the human upper urinary tract in patients with UPJO and controls were included in this systematic review. Only the studies comparing the density of CLCs at the UPJ in patients with UPJO and matched controls were included in the quantitative synthesis. Case reports and animal studies on CLCs were excluded.

Information Sources and Search Strategy

We searched online electronic databases; Ovid MEDLINE (Medical Literature Analysis and Retrieval System), Scopus, PubMed and Cochrane reviews. To obtain additional information, we conducted a manual search of the reference list of the selected articles. The online search strategy was generated by YM. The search comprised of studies listed up to October 31, 2020. We did not set search limits. The PubMed search strategy is provided in **Table 1**.

Study Selection

Two independent reviewers (US and YM) assessed the eligibility in an unbiased standardized manner. A third reviewer (AM) was involved in case of any disagreements. We screened the total hits obtained by reading “title” and “abstract.” We excluded studies that failed to satisfy the inclusion criteria at this stage. Next, we read the full text of each selected paper to extract data. All relevant articles published in languages other than English were translated into English language before screening. The reviewers determined the final group of articles to be included in the review after an iterative consensus process.

Data Collection Process

We developed a data extraction sheet, pilot-tested it on three randomly selected studies that were consistent with the inclusion criteria and revised it accordingly. One reviewer (US) extracted data from the included studies using this standardized form and another reviewer (YM) checked for the accuracy of data extraction. We extracted the following data from each study: (a) study details (author, country and year published), (b) sample characteristics (age of the study population and sample size), (c) methods (detection and/or quantification of CLC distribution and density) and (d) results (distribution of CLCs in a cross section and along the upper urinary tract and the density of CLCs with its association with disease status (UPJO vs. healthy subjects), age and postoperative outcomes).

TABLE 1 | The PubMed search strategy.

	Search string
1	Ureteropelvic
2	Pelviureteric
3	Pyeloureteric
4	Kidney
5	Urology*
6	Disease, urinary tract*
7	Ureter
8	Ureteral obstruction*
9	Interstitial cell of Cajal like cell*
10	Interstitial Cells of Cajal*
11	Telocytes*
12	1 or 2 or 3 or 4 or 5 or 6 or 7 or 8
13	9 or 10 or 11
14	12 and 13

MeSH terms are indicated by asterisks (*).

Ureteropelvic junction was defined as the junction between the renal pelvis and the ureter (20). Despite no clear external feature to locate the UPJ (20, 25), the internal appearance of crowding of mucosal folds forming characteristic “mucosal rosettes” allows its precise localization (20), whereas pathological UPJs in patients with UPJO is visualized intra-operatively as a valve-like appearance (26) preceding a narrowed segment with interrupted development of circular muscle fibers (27). Distribution of CLCs was defined as the location of the CLCs in different layers in the cross section of the ureter or along the upper urinary tract (UPJ, renal pelvis, or ureter). Density was defined as the total number of CLCs per high power field of an optical microscope. We resolved discrepancies in the extracted data by discussion, involving a third reviewer (AM) when necessary. We contacted the corresponding authors of the published manuscripts to obtain additional data such as the age distribution of their study populations and data sets of the measurements.

Risk of Bias in Individual Studies

The methodological quality and the risk of bias of the included studies were assessed independently by two authors (US and YM) using Joanna Briggs Institute (JBI) Critical Appraisal Tool (28). Each criterion was evaluated as “Yes,” “No,” or “Other” (unclear/not applicable). Overall rating was provided for each study based on the items rated with an affirmative answer and accordingly, the quality score was determined by the range 67–100 (good), 34–66 (average), and 0–33 (bad). The studies meeting the “good” scores were selected for the review.

Quantitative Analysis

We conducted a meta-analysis of studies comparing the density of CLCs at the UPJ in patients with UPJO and matched control. A random effects model was used for the comparisons. Heterogeneity was assessed using the χ^2 test on Cochran's Q statistic and by I^2 statistic. The I^2 statistic

was interpreted as follows: 0–40% might not be important; 30–60% may represent moderate heterogeneity; 50–90% may represent substantial heterogeneity; and 75–100% may represent considerable heterogeneity (29). When appropriate, sensitivity analyses were performed based on the sample size and the age distribution of the study samples to explore the sources of heterogeneity. Data were analyzed using RevMan version 5.4.1 (30). $p < 0.05$ was considered statistically significant in all analyses.

RESULTS

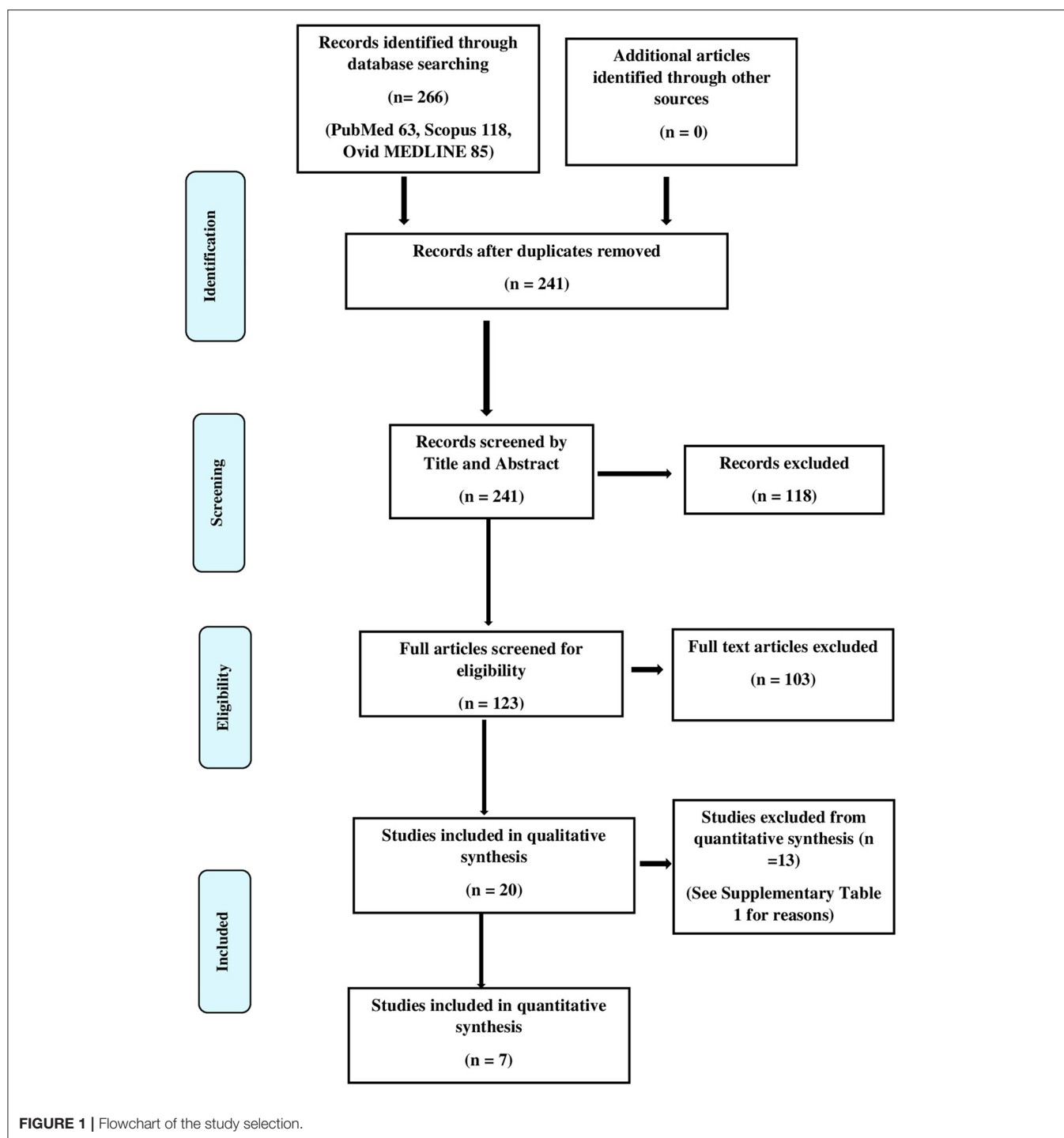
We found a total of 266 hits in the initial literature search, and after 50 duplicates were removed, 241 articles remained. We did not find additional articles after manual screening. We obtained full texts that had potential for the final review and included twenty of these studies in the final qualitative synthesis. **Figure 1** illustrates the PRISMA flow diagram of the search. The results of the qualitative synthesis are summarized in **Table 2**. Of them, five studies presented the density of CLC as an ordinal variable (e.g., low, medium, and high density) as opposed to a continuous variable *viz.*, the absolute number of CLCs per high power field, hence were subsequently excluded from the quantitative synthesis. The reasons of excluding articles from the quantitative synthesis are provided in the **Supplementary Table 1**. The risk of bias assessment is provided in the **Supplementary Tables 2, 3**. Of the studies included in the qualitative synthesis, eleven were conducted exclusively among children, while eight pooled results of adults and children. One study did not provide the age distribution of the subjects. The studies were conducted in Turkey, Poland, India, Egypt, Belgium, Germany, Korea, Singapore, Iran, Romania, Ireland, and China.

Distribution of Cajal-Like Cells

Majority (11/20, 55%) of the studies found CLCs between the inner longitudinal and outer circular muscle layers or in close proximity to the muscle layers (7/20, 35%), while others found these cells to be present both in the lamina propria and serosal layers (1/20, 5%) in addition to the muscle layers (**Supplementary Table 4**).

The reported distribution of the CLCs in different parts of the upper urinary system were controversial. Wishahi et al. (44) reported that the CLC density gradually increased from renal pelvis to proximal ureter in healthy subjects, while two studies found a decrease in CLC density from UPJ to distal ureter (37, 41). Conversely, Metzger et al. (39) reported that the CLC density gradually increased from the pelvis to the intermediate ureter, and then reduced at the distal ureter, while Ven Der Aa et al. (14) could not find a statistically significant difference in CLC density between upper, mid and distal thirds of the ureter.

Most studies (31–33, 42, 45) reported a lower density of CLCs in the UPJ of the patients with UPJO compared to the controls (**Table 2**). On the contrary, Koleda et al. (23), and Kuvel et al. (22) found a comparatively higher density of CLCs at the UPJ in patients. How et al. (34) found no statistically significant difference between the CLC density in the UPJ between the cases and controls. Apoznanski et al. (1) explored the density of CLCs



in affected patients with UPJO by quantifying the density of CLCs in adjacent high-power fields of the UPJ and calculated the gradient of CLCs. They found no significant differences of the CLC gradient between cases and controls (1).

Age Related Changes in Cajal-Like Cells

The CLC density increases in the UPJ with the advancement of the gestational age of the fetal ureter (31). Nevertheless

according to Koleda et al. (23) the density gradually decrease as the age advanced into childhood. Based on the studies included in the quantitative synthesis, a line diagram was drawn to illustrate the CLC density at the UPJ and we found an increase in CLC density with age in both healthy and those affected with UPJO (31, 32, 36, 42) (**Figure 2**). Further, the affected subjects consistently had a low CLC density compared to the healthy controls.

TABLE 2 | Summary of the studies included in the qualitative synthesis.

	Number of cases: control	Mean (\pm SD or range) age of cases: controls	Method of identification of CLCs	Area of CLCs distribution in ureter/UPJ	CLC density or distribution in cases	CLC density or distribution in controls	Conclusion of the study
Apozanski et al., Poland (1)	7: 5	2.2 (0.7–5.2) years: 2.3 (0.2–7.4) years	CLC gradient at the UPJ in patients with UPJO and controls was compared using IHC. Eleven adjacent HPFs (400X magnification) were examined to determine the CLC gradient. Gradient was defined as a difference of cell number per HPF greater than one in adjacent fields. Gradient was analyzed in relation to the patient's age.	Inner border of muscle layer	CLC gradient at UPJ = 19 ($P = 0.087$, $r = -0.3927$)	CLCs gradient at UPJ = 10 ($P = 0.3753$, $r = 0.1689$)	No statistically significant difference in CLC distribution between cases and controls. No correlation between age of cases and the distribution of CLCs.
Babu et al., India (15)	31: 31	2.9 (± 0.6) years	The difference of CLC density of the UPJ and the anastomotic end of ureter in children with UPJO undergoing pyeloplasty was analyzed. Association between post-operative outcome of the patients and the CLC density using IHC in 10 HPF (400X magnification) under light microscope was explored.	Not available	CLC density was significantly lower in the UPJ (mean = 5.3, SD = 2.3) compared to the anastomosed end of the ureter (mean = 12.4; SD = 5.1).		UPJ had a lower density of CLCs compared to the anastomotic end of the ureter in children with UPJO undergoing pyeloplasty. Resected ureter end with mean CLC density more than 10 per HPF had a better surgical outcome.
Babu et al., India (31)	31: 20	2.9 (± 3.1) years: 4.9 (± 4.1) years	CLC density at the narrowed segment in patients with UPJO and controls (UPJ segments obtained from patients undergoing nephrectomy) was compared using IHC (400X magnification). The correlation between CLC density at the UPJ of the normal fetuses (aborted due to maternal conditions or intrauterine death) and gestational age was explored.	Not available	Median CLC density of the narrowed UPJO segment per HPF was 5.1 (SD = 2.3).	Median CLC density of the normal ureter per HPF was 16.1 (SD = 8.3) Median CLC density of the fetal ureter per HPF was 5.0 (SD = 2.3)	CLC density at the narrowed segment in patients with UPJO was lower than that of the normal ureter. A positive correlation was found between the increasing gestational age and the CLC density ($r = 0.83$; $P < 0.001$) in the fetal ureter.
Balikci et al., Turkey (32)	63: 30	43.5 (2–72) years: 58.6 (38–82) years	Samples were obtained from multiple areas of the urinary tract in patients with hydronephroureter due to ureteric obstruction and controls. The CLC density was studied using IHC (400X magnification) at: renal pelvis lamina propria (RPLP), renal pelvis muscularis propria (RPMP), proximal ureter lamina propria (PULP), proximal ureter muscularis propria (PUMP).	Lamina propria and muscularis propria	CLCs density in; RPLP = 22(14–28) RPMP = 26(15–36) PULP = 12(9–20) PUMP = 17(10–23)	CLCs density in; RPLP = 32(26–42) RPMP = 42(34–64) PULP = 24(20–26) PUMP = 29(25–32)	CLC density in the renal pelvis and proximal ureter in cases was significantly low ($P < 0.001$) compared to the controls.
Eken et al., Turkey (33)	35: 7	3 (0.25–18) years: 29 (10–40) years (for light microscope)	CLC density at the UPJ in patients with UPJO and controls was compared using IHC and electron microscopy. CLC density per HPF (400X magnification) was graded as: 0–3 cells/HPF = sparse 4–8 cells/HPF = few >8 cells/HPF = many	Lamina propria and muscular layer	CLC density; Sparse = 8 (22.9%) Few = 26 (74.3%) Many = 1 (2.9%)	CLC density; Sparse = 0 Few = 0 Many = 7 (100%)	CLC density was significantly higher in the controls compared to cases ($P < 0.001$). CLCs of patients with UPJO had decreased number of mitochondria and caveolae compared to controls.
How et al., Singapore (34)	38: 20	2.1 (0.2–14) years: 4.0 (0.1–16) years	Level of CD117 staining was at the UPJ in patients with UPJO and controls was compared (400X and 100X magnifications)	Not available	Difference between cases and controls with CD117 staining; No difference in cases 30 (78.9%), Increased staining in cases 8 (21.1%), Decreased staining in cases 0 (0%).		There was no statistically significant difference of CD117 staining between cases and controls.

(Continued)

TABLE 2 | Continued

	Number of cases: control	Mean \pm SD or (range) age of cases: controls	Method of identification of CLCs	Area of CLCs distribution in ureter/UPJ	CLC density or distribution in cases	CLC density or distribution in controls	Conclusion of the study
Inugala et al., India (35)	23: 2	1.1 (0.04–4) years: 0.6 years	The association between outcome of Anderson-Hynes pyeloplasty and CLC density in resected margin was assessed. CLC density per HPF (400X magnification) was graded as: 0–1 cell/HPF = negative 2–5 cells/HPF = + 6–10 cells/HPF = ++ >11 cells/HPF = +++	Not available	CLC density at the UPJ in patients with good surgical outcomes: 0–1 cells = 12 (52.2%) 2–5 cells = 2 (8.7%) 6–10 cells = 7 (30.4%) >11 cells = 2 (8.7%) CLC density at the UPJ in patients with poor surgical outcomes: 0–1 cells = 1 (50%) 2–5 cells = 1 (50%) 6–10 cells = 0 >11 cells = 0		Having a high density of CLCs at the resection margin was associated with good surgical outcomes ($p = 0.001$).
Kart et al., Turkey (36)	11: 7	3.9 (± 2.6) years: 3.6 (± 3.8) years	CLC density at the UPJ in patients with UPJO and controls was compared using IHC (400X magnification)	Between Muscle layers	CLC density in cases per HPF was 1.75 (SD = 1.14)	CLC density in controls per HPF was 5.76 (SD = 2.99)	CLC density was significantly lower in cases compared to controls ($P < 0.01$).
Koleda et al., Poland (23)	20: 5	8.1 (0.7–16.8) years: 2.3 (0.2–7.4) years	CLC density at the UPJ in patients with UPJO and controls was compared using IHC. CLC density per HPF (400X magnification) was graded as: few (0 to 1), moderate (2 to 3), many (4 to 8) cells. The correlation between CLC density and age of the patients was explored.	Not available	Number of fields with few CLCs was significantly lower in cases than in controls ($P = 0.0122$). The number of fields with many CLCs was significantly higher in cases than in controls ($P = 0.0004$).		CLC density was significantly higher in cases compared to controls. CLC density of patients with UPJO decreased with aging ($r = -0.6167$, $P = 0.0038$).
Kuvel et al., Turkey (22)	32: 30	Not available	CLC density at the UPJ in patients with UPJO and controls was compared using IHC (400X magnification) Cases were classified according to location of sample obtained from the UPJ; Group Ia (proximal) Group Ib (intermediate) Group Ic (distal) segments	lamina propria (LP), muscularis propria (MP), and serosa (S) layers	CLC density in Group Ia was higher than Group Ib for LP, MP and for S layers. Group Ic had increased CLCs in LP and MP.	CLCs density in Group Ia was increased compared to controls for LP ($p < 0.05$) and S ($p < 0.01$). In intrinsic UPJO, CLCs were located more in LP and S compared to chronic UPJO.	An increased density of CLCs was observed in proximal segments of UPJ in intrinsic UPJO compared to normal subjects and chronic UPJO.
Lee et al., Korea (37)	8: 8	37 to 54 years age range	Two groups of specimens were studied: proximal group ≤ 5 cm from the UPJ, distal group ≥ 5 cm from UPJ. IHC was performed on the obtained tissues and observed under 400X magnification. Contractility was assessed based on the dose dependent response of acetylcholine and norepinephrine.	Between inner longitudinal muscles and interface between inner longitudinal and outer circular muscle layers	CLCs were found abundantly in the proximal group. There were spontaneous contractions (3 to 4 contractions within 5 min) in the proximal group. Distal sections did not show any spontaneous contractions.	No CLCs were found in the distal group.	Spontaneous contractions in human ureter could be generated by CLCs in the proximal region. This action might be regulated by cholinergic and/or adrenergic systems.
Mehrazma et al., Iran (38)	25: 19	1.7 (0.1 to 8) years	CLC density at the UPJ in patients with UPJO and controls was compared using IHC (400X magnification)	Between the muscle layers	Mean CLC density per HPF was 14.5 (SD = 5.6)	Mean CLC density per HPF was 32.8 (SD = 11.9)	CLCs density was significantly low in cases compared to controls ($P < 0.001$).

(Continued)

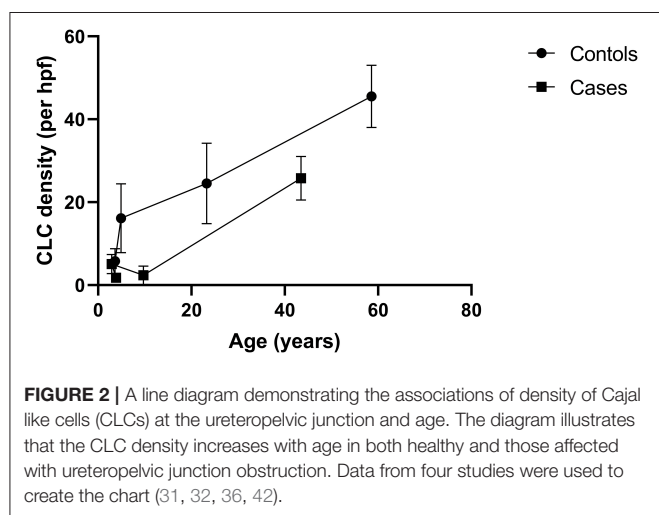
TABLE 2 | Continued

	Number of cases: control	Mean \pm SD or (range) age of cases: controls	Method of identification of CLCs	Area of CLCs distribution in ureter/UPJ	CLC density or distribution in cases	CLC density or distribution in controls	Conclusion of the study
Metzger et al., Germany (39)	56 ureter samples	Cadavers aged 54 (24–82) years and patients with renal tumours aged 49 (42–64) years	Samples were obtained from renal pelvis, and proximal, intermediate, and distal ureter. CLC density was assessed following IHC per HPF (200X magnification).	Lamina propria and muscularis propria	CLC density per HPF were: pelvis 13 (range 0.33 to 3.66) proximal ureter 10 (range 0 to 3.00) intermediate ureter 32 (range 0 to 6.66) distal ureter 22 (range 0.33 to 7.66).		CLC density was lower in the proximal ureter compared to the renal pelvis. The CLC density increased from proximal to intermediate ureter, and then decreased at the distal ureter.
Pande et al., India (40)	30: 7	0.7 (0.2–8) years: 2 (0.7–5) years	CLC density at the UPJ in patients with UPJO and controls was compared using IHC (under 400X magnification). Surgical outcome was assessed using ultrasonographs at 6-month post-operatively.	Not available	CLC density in cases per HPF was 4.86 (SD = 0.76)	CLC density in controls per HPF was 11.74 (SD = 0.86)	CLC density was significantly low in cases compared to controls ($p = 0.04$).
Prisca et al., Romania (41)	13	0.6 to 83 years	Samples were obtained from multiple areas of the urinary tract from the deceased with no evidence of UPJO. The obtained samples were categorized into following levels: upper urinary tract: 1st level- Kidney, 2nd level- Calyces, 3rd level- Pylon, 4th level- UPJ, 5th level- Proximal ureter, 6th level- Middle ureter, 7th level- Distal ureter. IHC was performed and observed under HPF (400X magnification)	Between muscle layers	Median CLC density per HPF at levels; 2nd level- 6 (4 to 9) 3rd level- 5 (2 to 8) 4th level- 4 (2 to 7) 5th level- 3 (1 to 6) 6th level- 2 (1 to 5) 7th level- 2 (0 to 5)		In normal individuals, CLC density was high in the calyces and pylon, while CLCs were scanty in the mid and distal ureter.
Senol et al., Turkey (42)	19: 12	116 \pm 116 months: 279 \pm 312 months	CLC density at the UPJ in patients with UPJO and controls was compared using IHC. CLC density per HPF (400X magnification) was graded as: very few (0 to 3), few (4 to 6) and many (>7) cells.	Closer to the inner longitudinal layer	CLC density in cases per HPF is 2.37 (SD = 2.19) Many – 1 (5.3%) Few – 5 (26.3%) Very few – 13 (68.4%)	CLC density in controls per HPF is 24.5 (SD = 9.73) All individuals had >7 CLCs per HPF.	Compared to controls cases had either no or few CLCs ($p < 0.0001$).
Solaris et al., Ireland (43)	19: 7	2.3 (0.2–12) years: 4.5 (0.9–9) years	CLC density at the UPJ in patients with UPJO and controls was compared using IHC. CLC density per HPF (400X magnification) was graded as: sparse (0 to 1), few (2 to 3), moderate (4 to 8), and many (>8).	Inner border of circular muscle layer	CLCs were sparse or absent (<2 per HPF).	CLC density was >8 per HPF (Grading: "many").	Patients with UPJO have a lower density of CLCs in the UPJ and renal pelvis compared to controls ($p < 0.05$).
Ven der Aa et al., Belgium (14)	44 (65 tissue samples)	39.7 (1–78) years in males, 16 (1–50) years in females	Tissue samples were obtained from renal pelvis, upper, middle, and lower ureter, vesicoureteral junction, bladder dome, bladder neck and urethra. IHC was performed and observed under HPF (400X and 200X magnifications).	Beneath urothelium and between muscle layers	Values not available	Values not available	CLC density was greater in pylon compared to ureter. No significant difference in the CLC density was observed between upper, mid, and lower thirds of the ureter or between the longitudinal and circular muscle layers of the ureter.
Wishahi et al., Egypt (44)	7: 5	28 \pm 10 years :52 \pm 7 years	CLC density at the UPJ, PU and RP in patients with UPJO and controls were compared using IHC and transmission electron microscopy.	Between Muscular layers	CLC density was high in PU, moderate in RP, scanty or absent in UPJ.	CLC density was high in the PU, excess in RP, and moderate in the UPJ.	Patients with UPJO have a lower density of CLCs in the UPJ and renal pelvis compared to controls ($p < 0.05$).

(Continued)

TABLE 2 | Continued

	Number of cases: control	Mean \pm SD or (range) age of cases: controls	Method of identification of CLCs	Area of CLCs distribution in ureter/UPJ	CLC density or distribution in cases	CLC density or distribution in controls	Conclusion of the study
Yang et al., China (45)	24: 21	0.25 to 12 years	CLC density at the UPJ in patients with UPJO and controls was compared using IHC (400X magnification)	Between muscle layers	Density of CLCs per HPF in cases was 0.207 (SD = 0.020).	Density of CLCs per HPF in controls was 0.262 (SD = 0.026).	CLC density at the UPJ was significantly lower in the cases compared to the controls ($p < 0.05$).



Cajal-Like Cell Contribution to Post-operative Outcome

Two studies exploring the association between the post-operative outcome of Anderson-Hynes pyeloplasty and the CLC density at the resected margin of ureter, showed that patients with a higher density of CLCs had a better surgical functional outcome (15, 35). Nevertheless, Pande et al. (40) found no correlation between the CLC density and the post-operative functional outcome.

Meta-Analysis

Seven studies reporting the mean difference of the density of CLC in the UPJ per high power field in patient with UPJO and controls were included in the meta-analysis. In the pooled analysis, the density of CLCs was significantly low in patients with UPJO (standardized mean difference = -3.00 , 95% confidence interval = -3.89 to -2.11 , $p < 0.01$) (Figure 3). The funnel plot of the selected studies is provided in the Supplementary Figure 1. We detected a considerable heterogeneity in this comparison ($\chi^2 = 41.03$, $I^2 = 85\%$, $df = 6$, $p < 0.01$). We performed a sensitivity analysis by including studies conducted on children only (aged <14 years) ($n = 5$) (31, 36, 38, 40, 45). The studies including both children (<2 years) and elders (>70 years) were excluded (32, 42). Nonetheless, the sensitivity analysis found a

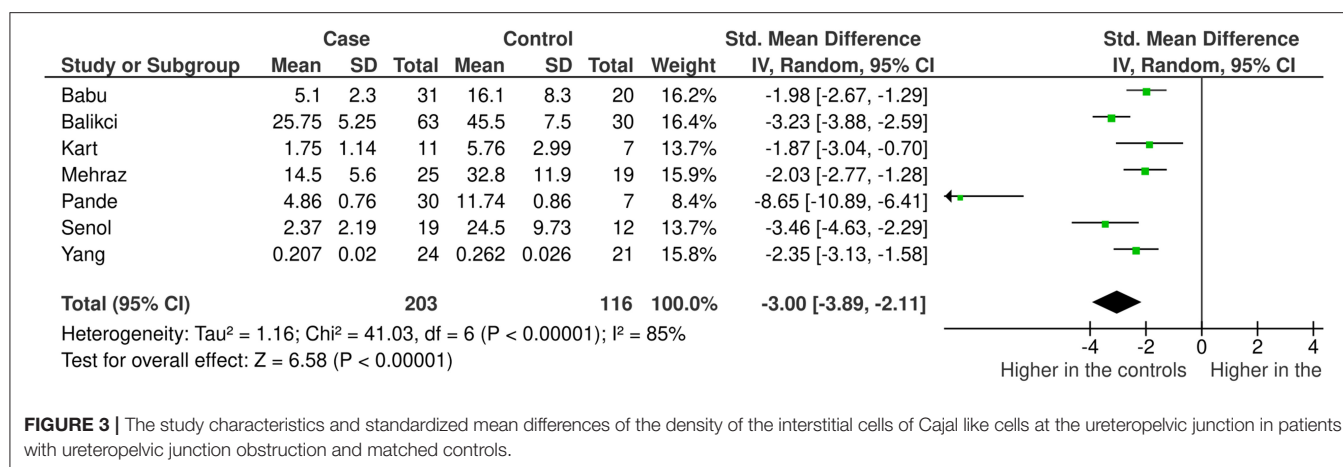
standardized mean difference of -2.93 (95% CI = -4.14 to -1.73) with a considerable heterogeneity ($\chi^2 = 32.71$, $I^2 = 88\%$, $df = 4$, $p < 0.01$) (Supplementary Figure 2). We were unable to perform a subgroup analysis comparing pediatric and adult populations since none of the included studies had a homogeneous adult population. To explore the effect of sample sizes, we performed another sensitivity analysis after including studies with at least 10 samples per group ($n = 5$) (31, 32, 38, 42, 45). The results showed a standardized mean difference of -2.56 (95% CI = -3.14 to -1.97) with a substantial heterogeneity ($\chi^2 = 11.40$, $I^2 = 65\%$, $df = 4$, $p < 0.01$) (Supplementary Figure 3). Subsequently, we combined the two sensitivity analyses by including studies of children with a large sample size (as defined above) ($n = 3$) (31, 38). In this analysis we found a standardized mean difference of -2.11 (95% CI = -2.53 to -1.68) with no heterogeneity ($\chi^2 = 0.56$, $I^2 = 0\%$, $df = 2$, $p < 0.01$) (Supplementary Figure 4).

DISCUSSION

UPJO is the partial or intermittent blockage of urinary flow from the renal pelvis into the ureter, governed by either an anatomical derangement or in most instances a functional disturbance (5, 26, 46–48). About a decade ago, dilemma on the pathophysiology of UPJO brought myogenic theory to light, which suggests that uncoordinated muscular contractions at the UPJ leads to a functional obstruction of antegrade urine flow (49). The discovery of CLCs in the upper urinary tract which could propagate action potentials in the UPJ, intrigued researchers to investigate into their role in UPJO (49).

Cajal Like Cells in the Upper Urinary Tract

Ureteric wall consists of a transitional epithelium, lamina propria, inner longitudinal, and outer circular muscle layers and a serosa. In most studies, CLCs were located between the inner longitudinal and outer circular muscle layers (Supplementary Table 4). Few studies found CLCs in the lamina propria (14, 22, 39), while a single study detected CLCs in the serosa (22). Cajal cells in the intestines, are located near the myenteric plexus and submucosal plexus, between longitudinal and circular muscle layers, between inner and outer circular muscle layers and within interlamellar connective tissues of circular muscles (50). They are, however not often observed



in serosa. Similarly, in ureter, CLCs are not readily located in the serosa in most instances but are present considerably more in the lamina propria. These cells are believed to play a coordinator role of impulse transmission between the sensory nerve endings and smooth muscle cells (18, 19), hence are located in areas richly innervated by sensory nerves. Ureteric innervation is to the muscular and subepithelial layers (51) where the nerve endings reside, therefore the deficiency in CLCs in serosal layer could be due to the lack of sensory nerve endings in the serosa.

Majority of the studies suggest that the overall CLC density at UPJ is reduced in individuals with UPJO compared to controls (33, 38, 40, 42, 45), which is consistent with the results of our quantitative synthesis. A constellation of gastrointestinal motility diseases including achalasia cardia (52) and Hirschsprung's disease (53) are associated with depletion of Cajal cells, while reduction of Cajal cell density in small intestinal segments of inflammation or obstruction significantly improves when treating the pathology causing inflammation or removal of obstruction (54, 55). Abstracting from this knowledge, a theory was postulated on the lack of CLCs in the UPJ as a contributor of failed peristaltic wave propagation across the UPJ in UPJO. However, the observational nature of these studies lacked the ability to derive a direct causation, but only an association. This putative role of CLCs was projected to doubt by Koleda et al. (23) and Kuvel et al. (22) with their description of an increase in the CLC density in the UPJ in affected individuals. Interestingly, in Koleda et al. (23) study, the age of the cases was markedly higher compared to the controls which could have contributed to the rising CLCs in cases, since there is a gradual increase of the CLC density with age in normal individuals as well as in patients with UPJO (Figure 2). Similarly, data was lacking on the age of the subjects in Kuvel et al. (22) study. Due to this reason, it may not be prudent to derive meaningful comparisons of the CLC density in cases and controls from the latter two studies. Although CLC density increases in the urinary tract with aging (Figure 2), the Cajal cell number and volume reduces steadily in colon and stomach (56). Furthermore, Cajal

cell loss and aging increases slow waves conduction velocity in the stomach (57) resulting in delayed gastric emptying. Nevertheless it is possible that other syncytial factors have an interdependent role with Cajal cells giving rise to slow wave velocity changes (57).

Though immunohistochemical studies have failed to establish differences of the expression levels of neuronal markers in UPJO (34), it is suggested that a defective innervation at the UPJ in intrinsic obstruction could contribute to increase in CLC density causing increased peristaltic activity as a result of an attempt to overcome peristaltic failure (22). In chronic UPJO from tumors or ureteric stones up-regulation of c-kit expression is not observed to overcome the obstruction (22). The excitatory impulses are generated from a single site of origin propelling urine into the ureter (58). However, when more than one impulse generator sites are present, they block the conduction of waves of excitation (58). This suggests that if there is a change in distribution of impulse generating CLCs in UPJ, it may contribute to alteration of impulse generation leading to intrinsic UPJO. This hypothesis is supported by a study conducted on rabbits where increased frequency of spontaneous mechanical activity of the UPJ was observed during obstruction (59). Researchers pondered on the distributional changes in CLCs in the pathogenesis of UPJO, to which Apoznanski et al. (1) answered by demonstrating no distributional gradient changes in the CLCs in UPJO compared to the age of the affected. However, this study included only seven cases. In addition, we noted that there is a marked deficiency in studies that embark on the distributive changes in the CLCs in affected and healthy UPJ.

CLCs do not possess a primary action potential generation ability in animals, but form a conduit for transmission of signals (60) (Animal study findings related to CLCs are summarized in **Supplementary Table 5**). Guinea pig renal system, which resembles similar anatomy to humans, shows pacemaker oscillations at the pelvicalyceal junction and UPJ, while oscillations are absent in the ureter (19). When the proximal pacemaker drive is blocked either by pharmacological

means or by transection, the distal regions take over the waves of excitation (61), suggesting the presence of pacemaker potential generation mechanism in the mid and distal ureter. These findings corroborate the results of the human studies where CLCs, the potential pacemakers of the renal tract, are not restricted to the renal pelvis and UPJ, but also found in the mid and distal ureter to coordinate unidirectional peristaltic activity.

LIMITATIONS

Few studies (23, 33, 34, 43) could not be incorporated in the quantitative synthesis when the CLC density was not presented as a continuous variable with means and standard deviations as summary statistics. The marked variability of the study designs, especially the wide range of age and limited sample sizes contributed to the high heterogeneity of the quantitative synthesis.

QUALITY OF EVIDENCE

This systematic review followed the standard recommended methodology set out by PRISMA guidelines. Two reviewers independently assessed the studies for potential sources of bias and a standard approach of data extraction was employed, thus reducing the risk of performance bias in the review and data extraction errors. PRISMA checklist of the review is presented in **Supplementary Table 6**.

CONCLUSIONS

Cajal like cells are predominantly distributed between the muscle layers of the upper urinary tract. However, the distribution of CLCs along the urinary tract from the renal pelvis toward the lower ureter is subjected to controversy. The CLC density at

the UPJ is significantly low in patients with UPJO compared to the controls, suggesting a pivotal contribution by CLCs in the pathogenesis of UPJO. The CLC density gradually increases with aging in both healthy subjects and patients with UPJO, which could potentially bias the results of the anatomical studies when age is not strictly matched in cases and controls. Careful matching of age in cases and controls, avoiding large age ranges and using an adequate sample size are necessary when performing future studies.

DATA AVAILABILITY STATEMENT

The original contributions presented in the study are included in the article/**Supplementary Material**, further inquiries can be directed to the corresponding authors.

AUTHOR CONTRIBUTIONS

US conceptualized the study. YM developed the search strategy. US, YM, and AM extracted data. YM conducted the meta-analysis. US, YM, UL, and AM wrote the first draft of the manuscript. All authors were involved in drafting and commenting on the paper and have approved the final version.

ACKNOWLEDGMENTS

Authors thank the Faculty of Medicine, University of Colombo.

SUPPLEMENTARY MATERIAL

The Supplementary Material for this article can be found online at: <https://www.frontiersin.org/articles/10.3389/fsurg.2021.721143/full#supplementary-material>

REFERENCES

1. Apoznanski W, Koleda P, Wozniak Z, Rusiecki L, Szydelko T, Kalka D, et al. The distribution of interstitial cells of Cajal in congenital ureteropelvic junction obstruction. *Int Urol Nephrol.* (2013) 45:607–12. doi: 10.1007/s11255-013-0454-7
2. Degheili JA, Termos S, Moussa M, Aoun B. Ureteropelvic junction obstruction: diagnosis, treatment and prognosis. In: *Advances in Medicine and Biology*. New York, NY: Nova Medicine and Health (2020). p. 75–7.
3. Nguyen HT, Benson CB, Bromley B, Campbell JB, Chow J, Coleman B, et al. Multidisciplinary consensus on the classification of prenatal and postnatal urinary tract dilation (UTD classification system). *J Pediatric Urol.* (2014) 10:982–98. doi: 10.1016/j.jpuro.2014.10.002
4. Gopal M, Peycelon M, Caldamone A, Chrzan R, El-Ghoneimi A, Olsen H, et al. Management of ureteropelvic junction obstruction in children—a roundtable discussion. *J Pediatric Urol.* (2019) 15:322–29. doi: 10.1016/j.jpuro.2019.05.010
5. Pinter A, Horvath A, Hrabovszky Z. The relationship of smooth muscle damage to age, severity of pre-operative hydronephrosis and post-operative outcome in obstructive uropathies. *Br J Urol.* (1997) 80:227–33. doi: 10.1046/j.1464-410X.1997.00311.x
6. Murnaghan G. The dynamics of the renal pelvis and ureter with reference to congenital hydronephrosis. *Br J Urol.* (1958) 30:321. doi: 10.1111/j.1464-410X.1958.tb03525.x
7. Cajal R. *Histologie du système nerveux de l'Homme et des Vertébrés*. Grand sympathique. Paris, Maloine (1911). p. 2.
8. Miliaras D, Karasavvidou F, Papanikolaou A, Sioutopoulou D. KIT expression in fetal, normal adult, and neoplastic renal tissues. *J Clin Pathol.* (2004) 57:463–6. doi: 10.1136/jcp.2003.013532
9. Huizinga JD, Thuneberg L, Vanderwinden JM, Rumessen JJ. Interstitial cells of Cajal as targets for pharmacological intervention in gastrointestinal motor disorders. *Trends Pharmacol Sci.* (1997) 18:393–403. doi: 10.1016/S0165-6147(97)90668-4
10. Sanders KM, Ördög T, Koh S, Torihashi S, Ward S. Development and plasticity of interstitial cells of Cajal. *Neurogastroenterol Motil.* (1999) 11:311–38. doi: 10.1046/j.1365-2982.1999.00164.x
11. Vanderwinden JM, Rumessen JJ. Interstitial cells of Cajal in human gut and gastrointestinal disease. *Microsc Res Tech.* (1999) 47:344–60. doi: 10.1002/(SICI)1097-0029(19991201)47:5<344::AID-JEMT6>3.0.CO;2-1
12. Wedel T, Spiegler J, Soellner S, Roblick UJ, Schiedeck TH, Bruch HP, et al. Enteric nerves and interstitial cells of Cajal are altered in patients with slow-transit constipation and megacolon.

- Gastroenterology*. (2002) 123:1459–67. doi: 10.1053/gast.2002.36600
13. Huizinga JD, Faussone-Pellegrini MS. About the presence of interstitial cells of Cajal outside the musculature of the gastrointestinal tract. *J Cell Mol Med*. (2005) 9:468–73. doi: 10.1111/j.1582-4934.2005.tb00372.x
 14. Van Der Aa F, Roskams T, Blyweert W, Ost D, Bogaert G, De Ridder D. Identification of kit positive cells in the human urinary tract. *J Urol*. (2004) 171:2492–6. doi: 10.1097/01.ju.0000125097.25475.17
 15. Babu R, Vittalraj P, Sundaram S, Manjusha MP, Ramanan V, Sai V. Comparison of different pathological markers in predicting pyeloplasty outcomes in children. *J Pediatric Surg*. (2020) 55:1616–20. doi: 10.1016/j.jpedsurg.2019.08.015
 16. Shafik A, El-Sibai O, Shafik I, Shafik AA. Immunohistochemical identification of the pacemaker cajal cells in the normal human vagina. *Arch Gynecol Obstet*. (2005) 272:13–6. doi: 10.1007/s00404-005-0725-3
 17. Gherghiceanu M, Hinescu M, Andrei F, Mandache E, Macarie C, Faussone-Pellegrini MS, et al. Interstitial Cajal-like cells (ICLC) in myocardial sleeves of human pulmonary veins. *J Cell Mol Med*. (2008) 12:1777–81. doi: 10.1111/j.1582-4934.2008.00444.x
 18. Constantinou C, Silvert M, Gosling J. Pacemaker system in the control of ureteral peristaltic rate in the multicystic kidney of the pig. *Investig Urol*. (1977) 14:440.
 19. Klemm MF, Exintaris B, Lang RJ. Identification of the cells underlying pacemaker activity in the guinea-pig upper urinary tract. *J Physiol*. (1999) 519:867–84. doi: 10.1111/j.1469-7793.1999.0867n.x
 20. Shafik A, Al-Sherif AM. Ureteropelvic junction: a study of its anatomical structure and function. *Eur Urol*. (1999) 36:150–7. doi: 10.1159/000067987
 21. Lang RJ, Tonta MA, Zoltkowski BZ, Meeker WF, Wendt I, Parkington HC. Pyeloureteric peristalsis: role of atypical smooth muscle cells and interstitial cells of Cajal-like cells as pacemakers. *J Physiol*. (2006) 576:695–705. doi: 10.1113/jphysiol.2006.116855
 22. Kuvel M, Canguven O, Murtazaoglu M, Albayrak S. Distribution of Cajal like cells and innervation in intrinsic ureteropelvic junction obstruction. *Arch Ital Urol Androl*. (2011) 83:128–32.
 23. Koleda P, Apoznanski W, Wozniak Z, Rusiecki L, Szydelko T, Pilecki W, et al. Changes in interstitial cell of Cajal-like cells density in congenital ureteropelvic junction obstruction. *Int Urol Nephrol*. (2012) 44:7–12. doi: 10.1007/s11255-011-9970-5
 24. Moher D, Liberati A, Tetzlaff J, Altman DG, Group P. Preferred reporting items for systematic reviews and meta-analyses: the PRISMA statement. *PLoS Med*. (2009) 6:e1000097. doi: 10.1371/journal.pmed.1000097
 25. Standring S. *Gray's Anatomy: The Anatomical Basis of Clinical Practice*. Philadelphia: Elsevier (2020).
 26. Foote J, Blennerhassett J, Wiglesworth F, Mackinnon K. Observations on the ureteropelvic junction. *J Urol*. (1970) 104:252–7. doi: 10.1016/S0022-5347(17)61710-5
 27. Wein AJ, Kavoussi LR, Dmochowski R, Partin AW, Peters CA. *Campbell-Walsh Urology*. North York, ON: Elsevier (2020).
 28. Moola S, Munn Z, Tufanaru C, Aromataris E, Sears K, Sfetcu R, et al. Chapter 7: systematic reviews of etiology and risk. *Joanna Briggs Institute Reviewer's Manual*. The Joanna Briggs Institute. (2017). p. 2019–05. doi: 10.46658/JBIRM-17-06
 29. Higgins JP, Thomas J, Chandler J, Cumpston M, Li T, Page MJ, et al. *Cochrane Handbook for Systematic Reviews of Interventions*. John Wiley and Sons (2019). doi: 10.1002/9781119536604
 30. The Cochrane Collaboration. *Review Manager (Revman)* [Computer Program]. Version 5.4.1 (2020).
 31. Babu R, Vittalraj P, Sundaram S, Shalini S. Pathological changes in ureterovesical and ureteropelvic junction obstruction explained by fetal ureter histology. *J Pediatric Urol*. (2019) 15:e247. doi: 10.1016/j.jpuro.2019.02.001
 32. Balıkcı Ö, Turunç T, Bal N, Çelik H, Özkardeş H. Comparison of Cajal-like cells in pelvis and proximal ureter of kidney with and without hydronephrosis. *Int Braz J Urol*. (2015) 41:1178–84. doi: 10.1590/S1677-5538.IBJU.2014.0427
 33. Eken A, Erdogan S, Kuyucu Y, Seydaoglu G, Polat S, Satar N. Immunohistochemical and electron microscopic examination of Cajal cells in ureteropelvic junction obstruction. *Can Urol Assoc J*. (2013) 7:E311–6. doi: 10.5489/cuaj.1247
 34. How GY, Chang KTE, Jacobsen AS, Yap TL, Ong CCP, Low Y, et al. Neuronal defects an etiological factor in congenital pelviureteric junction obstruction? *J Pediatric Urol*. (2018) 14:e57. doi: 10.1016/j.jpuro.2017.07.014
 35. Inugala A, Reddy RK, Rao BN, Reddy SP, Othuluru R, Kannian L, et al. Immunohistochemistry in ureteropelvic junction obstruction and its correlation to postoperative outcome. *J Indian Assoc Pediatric Surg*. (2017) 22:129–33. doi: 10.4103/jiaps.JIAPS_254_16
 36. Kart Y, Karakuş OZ, Ateş O, Hakgüder G, Olguner M, Akgür FM. Altered expression of interstitial cells of Cajal in primary obstructive megaureter. *J Pediatric Urol*. (2013) 9:1028–31. doi: 10.1016/j.jpuro.2013.02.003
 37. Lee HW, Baak CH, Lee MY, Kim YC. Spontaneous contractions augmented by cholinergic and adrenergic systems in the human ureter. *Korean J Physiol Pharmacol*. (2011) 15:37–41. doi: 10.4196/kjpp.2011.15.1.37
 38. Mehrazma M, Tanzifi P, Rakhshani N. Changes in structure, interstitial Cajal-like cells and apoptosis of smooth muscle cells in congenital ureteropelvic junction obstruction. *Iran J Pediatr*. (2014) 24:105–10. doi: 10.1097/01.PAT.0000454556.77877.27
 39. Metzger R, Schuster T, Till H, Stehr M, Franke FE, Dietz HG, et al. Cajal-like cells in the human upper urinary tract. *J Urol*. (2004) 172:769–72. doi: 10.1097/01.ju.0000130571.15243.59
 40. Pande T, Dey SK, Chand K, Kinra P. Influence of interstitial cells of cajal in congenital ureteropelvic junction obstruction. *J Indian Assoc Pediatric Surg*. (2020) 25:231–5. doi: 10.4103/jiaps.JIAPS_115_19
 41. Prişcă RA, Loghin A, Gozar HG, Moldovan C, Moso T, Derzsi Z, et al. Morphological aspects and distribution of interstitial cells of Cajal in the human upper urinary tract. *Turk Patoloji Derg*. (2014) 30:100–4. doi: 10.5146/tjpath.2014.01242
 42. Senol C, Onaran M, Gurocak S, Gonul II, Tan MO. Changes in Cajal cell density in ureteropelvic junction obstruction in children. *J Pediatric Urol*. (2016) 12:e85. doi: 10.1016/j.jpuro.2015.08.010
 43. Solari V, Piotrowska AP, Puri P. Altered expression of interstitial cells of Cajal in congenital ureteropelvic junction obstruction. *J Urol*. (2003) 170:2420–2. doi: 10.1097/01.ju.0000097401.03293.f0
 44. Wishahi M, Mehena A, Elganzoury H, Badawy M, Hafiz E, El-Leithy T. Telocytes and Cajal cells distribution in renal pelvis, ureteropelvic junction (UPJ), and proximal ureter in normal upper urinary tract and UPJ obstruction: reappraisal of the etiology of UPJ obstruction. *Folia Morphol*. (2020). doi: 10.5603/FM.a2020.0119
 45. Yang X, Zhang Y, Hu J. The expression of Cajal cells at the obstruction site of congenital pelviureteric junction obstruction and quantitative image analysis. *J Pediatric Surg*. (2009) 44:2339–42. doi: 10.1016/j.jpedsurg.2009.07.061
 46. Murakumo M, Nonomura K, Yamashita T, Ushiki T, Abe K, Koyanagi T. Structural changes of collagen components and diminution of nerves in congenital ureteropelvic junction obstruction. *J Urol*. (1997) 157:1963–8. doi: 10.1016/S0022-5347(01)64910-3
 47. Sui G, Rothery S, Dupont E, Fry C, Severs N. Gap junctions and connexin expression in human suburothelial interstitial cells. *BJU Int*. (2002) 90:118–29. doi: 10.1046/j.1464-410X.2002.02834.x
 48. Mut T, Acar Ö, Oktar T, Kiliçaslan I, Esen T, Ander H, et al. Intraoperative inspection of the ureteropelvic junction during pyeloplasty is not sufficient to distinguish between extrinsic and intrinsic causes of obstruction: correlation with histological analysis. *J Pediatric Urol*. (2016) 12:223.e221–223. e226. doi: 10.1016/j.jpuro.2016.02.016
 49. Lang RJ, Hashitani H. Pacemaker mechanisms driving pyeloureteric peristalsis: modulatory role of interstitial cells. *Adv Exp Med Biol*. (2019) 1124:77–101. doi: 10.1007/978-981-13-5895-1_3
 50. Veress B, Ohlsson B. Spatial relationship between telocytes, interstitial cells of Cajal and the enteric nervous system in the human ileum and colon. *J Cell Mol Med*. (2020) 24:3399–406. doi: 10.1111/jcmm.15013

51. Schulman C, Duarte-Escalante O, Boyarsky S. The autonomic innervation of the ureter and ureterovesical junction. In: Lutzeyer W, Melchior H, editors. *Urodynamics*. Berlin: Springer-Verlag (1973). p.90–7. doi: 10.1007/978-3-642-65640-8_14
52. Gockel I, Bohl JR, Eckardt VF, Junginger T. Reduction of interstitial cells of Cajal (ICC) associated with neuronal nitric oxide synthase (n-NOS) in patients with achalasia. *Am J Gastroenterol*. (2008) 103:856–64. doi: 10.1111/j.1572-0241.2007.01667.x
53. Wang H, Zhang Y, Liu W, Wu R, Chen X, Gu L, et al. Interstitial cells of Cajal reduce in number in recto-sigmoid Hirschsprung's disease and total colonic aganglionosis. *Neurosci Lett*. (2009) 451:208–11. doi: 10.1016/j.neulet.2009.01.015
54. Der T, Bercik P, Donnelly G, Jackson T, Berezin I, Collins SM, et al. Interstitial cells of Cajal and inflammation-induced motor dysfunction in the mouse small intestine. *Gastroenterology*. (2000) 119:1590–9. doi: 10.1053/gast.2000.20221
55. Chang IY, Glasgow NJ, Takayama I, Horiguchi K, Sanders KM, et al. Loss of interstitial cells of Cajal and development of electrical dysfunction in murine small bowel obstruction. *J Physiol*. (2001) 536:555. doi: 10.1111/j.1469-7793.2001.0555c.x
56. Gomez-Pinilla PJ, Gibbons SJ, Sarr MG, Kendrick ML, Robert Shen K, Cima RR, et al. Changes in interstitial cells of cajal with age in the human stomach and colon. *Neurogastroenterol Motil*. (2011) 23:36–44. doi: 10.1111/j.1365-2982.2010.01590.x
57. Wang THH, Angeli TR, Ishida S, Du P, Gharibans A, Paskaranandavadivel N, et al. The influence of interstitial cells of Cajal loss and aging on slow wave conduction velocity in the human stomach. *Physiol Rep*. (2021) 8:e14659. doi: 10.14814/phy2.14659
58. Lammers W, Ahmad H, Arafat K. Spatial and temporal variations in pacemaking and conduction in the isolated renal pelvis. *Am J Physiol*. (1996) 270:F567–74. doi: 10.1152/ajprenal.1996.270.4.F567
59. Ekinici S, Ertunc M, Ciftci A, Senocak M, Buyukpamukcu N, Onur R. Evaluation of Pelvic contractility in ureteropelvic junction obstruction: an experimental study. *Eur J Pediatric Surg*. (2004) 14:93–9. doi: 10.1055/s-2004-815854
60. McCloskey KD. Interstitial cells of Cajal in the urinary tract. *Handb Exp Pharmacol*. (2011) 2:233–54. doi: 10.1007/978-3-642-16499-6_11
61. Hurtado R, Bub G, Herzlinger D. The pelvis–kidney junction contains HCN3, a hyperpolarization-activated cation channel that triggers ureter peristalsis. *Kidney Int*. (2010) 77:500–8. doi: 10.1038/ki.2009.483

Conflict of Interest: The authors declare that the research was conducted in the absence of any commercial or financial relationships that could be construed as a potential conflict of interest.

Publisher's Note: All claims expressed in this article are solely those of the authors and do not necessarily represent those of their affiliated organizations, or those of the publisher, the editors and the reviewers. Any product that may be evaluated in this article, or claim that may be made by its manufacturer, is not guaranteed or endorsed by the publisher.

Copyright © 2021 Samaranayake, Mathangasinghe, Liyanage, de Silva, Samarasinghe, Abeygunasekera, Lamahewage and Malalasekera. This is an open-access article distributed under the terms of the Creative Commons Attribution License (CC BY). The use, distribution or reproduction in other forums is permitted, provided the original author(s) and the copyright owner(s) are credited and that the original publication in this journal is cited, in accordance with accepted academic practice. No use, distribution or reproduction is permitted which does not comply with these terms.



Meta-Analysis of the Efficacy of Laparoscopic Pyeloplasty for Ureteropelvic Junction Obstruction via Retroperitoneal and Transperitoneal Approaches

Fengming Ji[†], Li Chen[†], Chengchuang Wu[†], Jinrong Li, Yu Hang and Bing Yan^{*}

Kunming Children's Hospital, Kunming, China

OPEN ACCESS

Edited by:

Abdurrahman Onen,
Onen Pediatric Urology Center, Turkey

Reviewed by:

Matthieu Peycelon,
Indiana University, United States
Huixia Zhou,
Bayi Children's Hospital, China

*Correspondence:

Bing Yan
yanbing29@q163.com

[†]These authors have contributed
equally to this work

Specialty section:

This article was submitted to
Pediatric Urology,
a section of the journal
Frontiers in Pediatrics

Received: 09 May 2021

Accepted: 24 June 2021

Published: 29 July 2021

Citation:

Ji F, Chen L, Wu C, Li J, Hang Y and
Yan B (2021) Meta-Analysis of the
Efficacy of Laparoscopic Pyeloplasty
for Ureteropelvic Junction Obstruction
via Retroperitoneal and
Transperitoneal Approaches.
Front. Pediatr. 9:707266.
doi: 10.3389/fped.2021.707266

Objective: This study aimed to evaluate the clinical efficacy of laparoscopic pyeloplasty (LP) for ureteropelvic junction obstruction (UPJO) via retroperitoneal and transperitoneal approaches.

Method: A systematic literature search on keywords was undertaken using PubMed, Cochrane Library, Embase, China Nation Knowledge (CNKI), and Wanfang. The eligible literature was screened according to inclusion and exclusion criteria. Meta-analysis was performed by using RevMan 5.0 software.

Results: According to the inclusion and exclusion criteria, 12 studies were identified with a total of 777 patients. Four hundred eight patients were treated with retroperitoneal laparoscopic pyeloplasty (RLP), and 368 patients were treated with transperitoneal laparoscopic pyeloplasty (TLP). The meta-analysis results showed that the two approaches were similar in terms of presence of postoperative hospital stay, postoperative complication, the rate of conversion, and recurrence ($p > 0.05$). The operative time in the TLP group was significantly shorter than the RLP group (MD = 16.6; 95% CI, 3.40–29.80; $p = 0.01$). The duration of drainage was significantly shorter (MD = -1.06; 95% CI, -1.92 to -0.19; $p = 0.02$), and the score of postoperative visual analog score (VAS) was significantly lower in the RLP group than in the TLP group (MD = -0.52; 95% CI, -0.96 to -0.08; $p = 0.02$).

Conclusion: Both approaches have good success rates and low postoperative complication rates. RLP provides a shorter duration of drainage and lower VAS score, but it takes more operative time than TLP.

Keywords: ureteropelvic junction obstruction, laparoscopic, pyeloplasty, retroperitoneal, transperitoneal

BACKGROUND

With the popularity of prenatal ultrasound, the rate of diagnosis of hydronephrosis has increased in fetal and prenatal. There are many causes of hydronephrosis such as ureteropelvic junction obstruction (UPJO), vesicoureteral reflux (VUR), or ureterovesical junction obstruction. Ureteropelvic junction obstruction (UPJO) is the most common cause of congenital hydronephrosis (1). The standard surgical technique is dismembered pyeloplasty (Anderson–Hynes procedure) for UPJO, which was first performed successfully by Anderson and Hynes in 1949. It has the obvious advantages for long stenosis segment, presence of stones, and crossing vessels (2). With the continuous development of modern minimally invasive technology, laparoscopic pyeloplasty (LP) has become a more beneficial choice for the patients with UPJO than open surgery because of the advantages of excellent visualization, minimal trauma, rapid postoperative recovery, good cosmetic result, and a nearly successful rate compared with open pyeloplasty (3, 4). LP can be performed through retroperitoneal and transperitoneal approaches. To compare the advantages and disadvantages of the two approaches, this study consulted relevant literature and performed a meta-analysis.

METHODS

Search Strategy

We searched PubMed, Embase, CNKI, and Wanfang. Studies were restricted to English and Chinese language published before January 1, 2020. The following search terms were used using the Boolean operator terms “AND” and “OR”: “laparoscopic pyeloplasty,” “laparoscopic disconnected pyeloplasty,” “Ureteropelvic junction obstruction,” “UPJO,” “retroperitoneal,” and “transperitoneal.”

Inclusion Criteria and Exclusion Criteria

Inclusion Criteria

(1) Interventions: laparoscopic ureteroplasty was performed through retroperitoneal and transperitoneal approaches. (2) Intervention subjects: unilateral UPJO patients. (3) Outcomes: postoperative time, hospital stay, postoperative complication, duration of drainage, visual analog score (VAS), the rate of conversion, and recurrence. (4) Study types—randomized controlled studies or retrospective studies. (5) For the studies published by the same unit, the latest one would be included.

Exclusion Criteria

(1) Approaches involved only retroperitoneal or transperitoneal. (2) The intervention subjects included patients with bilateral UPJO. (3) Outcome cannot be obtained. (4) Full text is unavailable. (5) The treatment includes robotic-assisted surgery and open surgery. (6) Literature with a quality evaluation result of <7 or low quality according to the Newcastle–Ottawa Scale (NOS) quality evaluation scale (5) and the Cochrane Collaboration’s tool (6).

Study Selection and Quality Evaluation

In selecting studies for inclusion, a review of all relevant article titles and abstracts were conducted before an examination of the full published texts. Two professional reviewers reviewed the articles for eligibility and quality and extracted the data independently. Data were collected on standard collection tables. Extracted data included author’s name, nation, published year, study type, patients’ characteristics, and relevant outcomes. Disagreement was resolved by consensus with the intervention of a third reviewer.

For the quality assessment, the Newcastle–Ottawa Scale (NOS) quality evaluation scale and the Cochrane Collaboration’s tool were used for non-randomized controlled trials and randomized controlled studies, respectively.

Statistical Analysis

All meta-analyses were carried out in RevMan 5.0 software, and $p < 0.05$ meant the difference was statistically significant. The continuous variables were described by standardized mean difference (SMD) and 95% confidence interval (95% CI), and the dichotomous variables were described by odds ratio (OR) and 95% CI. Evaluated by Q-test, heterogeneity was considered if $p > 0.1$ or $I < 50\%$, and the random effect model was adopted. If $p < 0.1$ or $I > 50\%$, it indicates that there was heterogeneity, and the fixed effect model was adopted. For the continuous variables, if only the median and value range were provided in the included studies, the mean and standard deviation were calculated according to the formula of Hozo (7).

RESULT

Study Characteristics

A total of 44 studies were retrieved. According to the inclusion and exclusion criteria, there were 12 studies that were included in the present study, of which 7 studies were in English, and 5 studies were in Chinese. A total of 777 patients were involved among the 12 studies, 408 patients were treated with RLP, and 369 patients were treated with TLP (The basic characteristics of the included studies are shown in Table 1, and the search process of the studies is shown in Figure 1).

Meta-Analysis Results

Operative Time

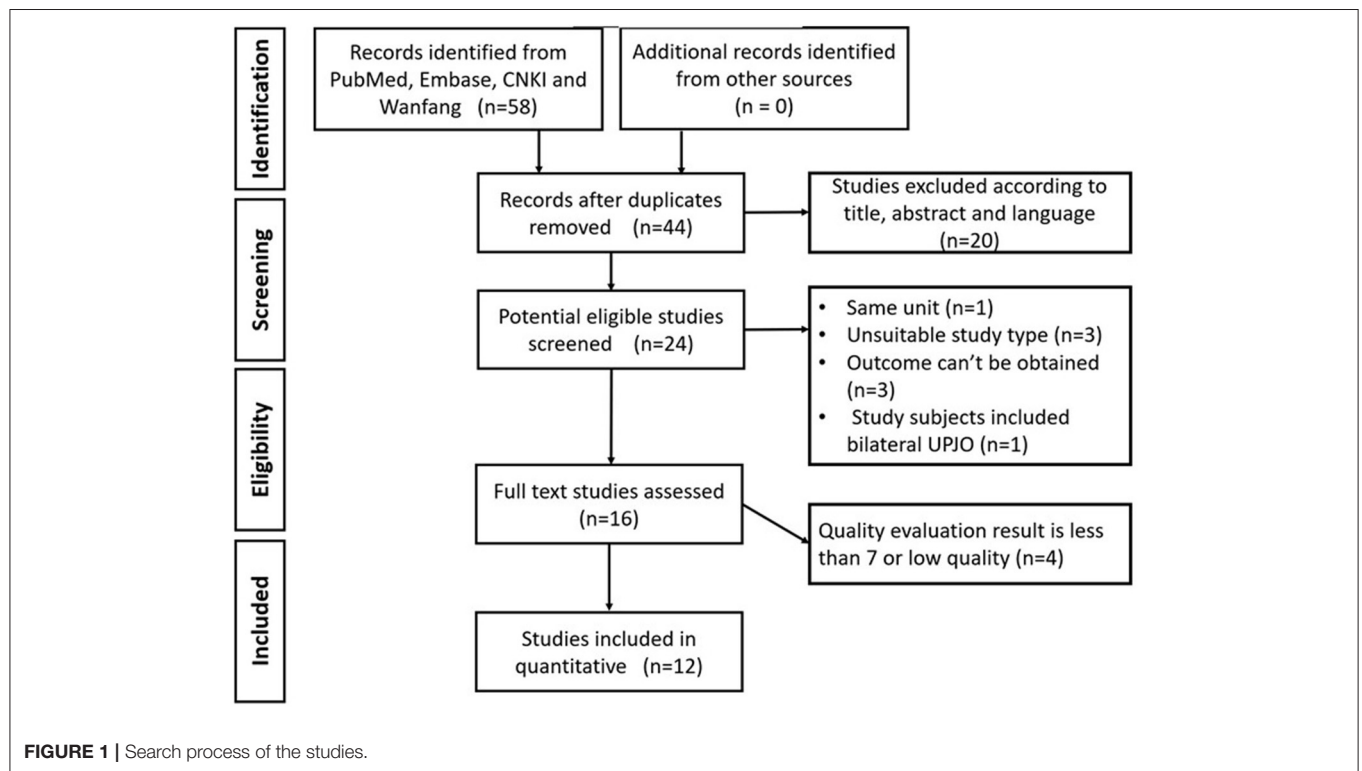
There were 12 studies that reported the operative time of the two groups. The heterogeneity test result was $p < 0.0001$, $I = 94\%$, and the random effect model was adopted. The meta-analysis result showed that there was significant difference in the operative time between the two groups (MD = 16.60; 95% CI, 3.40–29.80; $p = 0.01$) (Figure 2).

Postoperative Hospital Stay

There were 12 studies that reported the postoperative hospital stay of the two groups. The heterogeneity test result was $p < 0.0001$, $I = 91\%$, and the random effect model was adopted. The meta-analysis result showed that there was no significant difference in hospital stay between the two groups (MD = -0.21 ; 95% CI, -0.54 – 0.12 ; $p = 0.21$).

TABLE 1 | The basic characteristics of the included literature.

References	Nation	Year	Study type	RLP/TLP				
				Side: eft/right	Sex: male/female	Age:	Mean follow-up period	Quality evaluation
Abunaz et al. (8)	France	1999/10–2008/10	RS	14:17/16:18	12:19/15:19	36.94 ± 17.92/37.11 ± 16.75	48.9	8
Badawy et al. (9)	Egypt	2010/06–2012/09	RCT	/	11:8/14:5	/	10	High
Hemal et al. (10)	India	1999/10–2002/03	RS	4:8/7:5	8:4/9:3	26.3 ± 10.46/22.9 ± 9.87	11	9
Liu (11)	China	2012/09–2017/09	RS	20:8/21:9	17:11/18:12	27.12 ± 4.56/28.43 ± 3.25	/	9
Qadri and Khan (12)	India	2000/01–2009/08	RS	16:19/5:7	25:10/8:4	27.3 ± 11/32 ± 10.18	22/48	9
Shen et al. (13)	China	2012/04–2017/03	RCT	26:17/23:20	29:14/31:12	38.18 ± 3.05/39.11 ± 3.01	/	High
Shoma et al. (14)	Egypt	2002/02–2006/01	RCT	14:6/11:9	10:10/11:9	34 ± 15/29 ± 13	20/23	High
Singh et al. (15)	India	2008/01–2012/12	RCT	31:25/30:26	32:24/30:26	24.93 ± 3.94/24.79 ± 3.96	31	High
Xu and Li (16)	China	2013/01–2015/01	RCT	/	27:13/26:14	26.45 ± 4.45/26.34 ± 4.35	20	High
Zhai et al. (17)	China	2011/06–2015/05	NRCT	31:25/27:15	34:22/28:14	30.8 ± 12.8/27.2 ± 11.9	26/24	9
Zhang (18)	China	2010/01–2012/12	RS	22:18/24:16	22:18/28:12	22.41 ± 5.18/26.67 ± 4.59	18	7
Zhu et al. (19)	China	2009–2011	RS	16:12/13:9	16:12/9:13	30.6 ± 13.5/37.5 ± 8.25	11/10	8

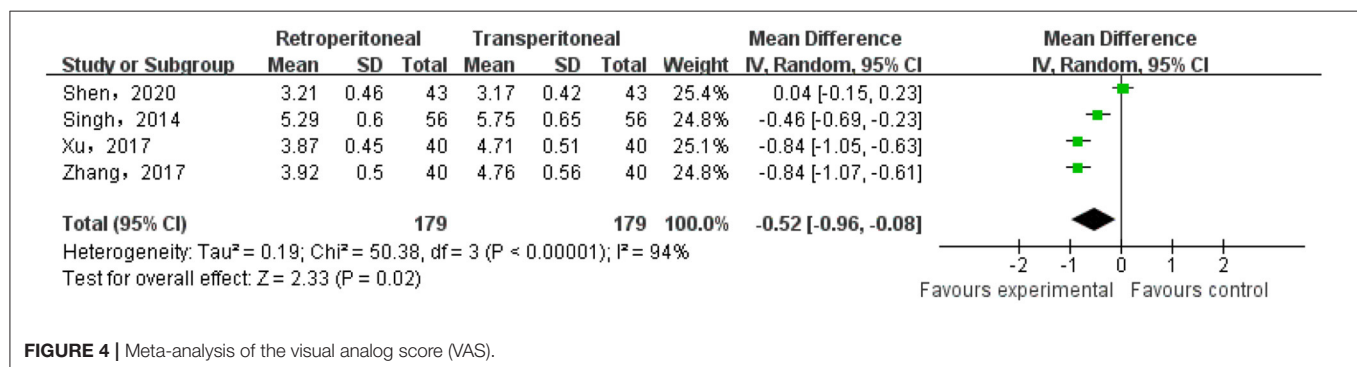
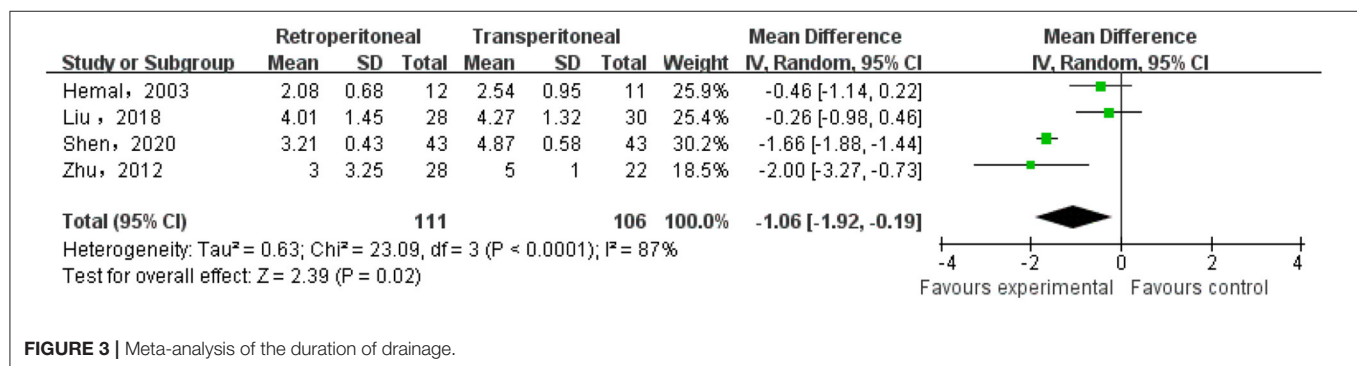
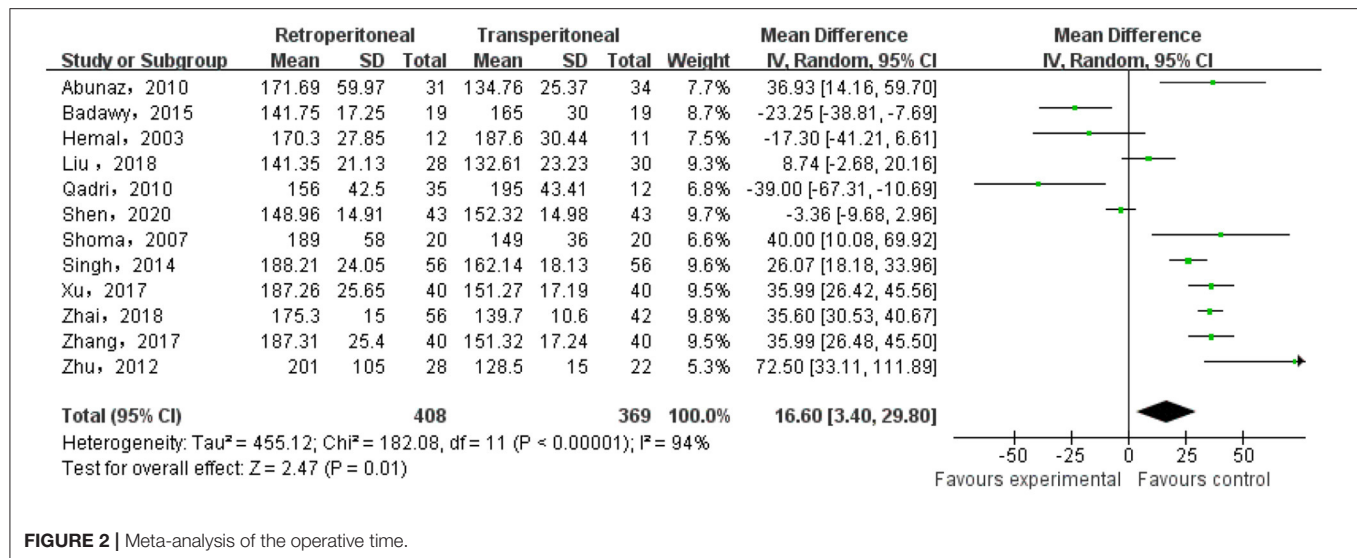


Duration of Drainage

There were four studies reported the duration of drainage of the two groups. The heterogeneity test result was $p < 0.0001$, $I^2 = 87\%$, and the random effect model was adopted. The meta-analysis result showed that there was significant difference in the duration of drainage between the two groups (MD = -1.06 ; 95% CI, -1.92 to -0.19 ; $p = 0.02$) (Figure 3).

Visual Analog Score

There were four studies that reported the VAS of the two groups. The heterogeneity test result was $p < 0.0001$, $I^2 = 94\%$, and the random effect model was adopted. The meta-analysis result showed that there was a significant difference in the VAS between the two groups (MD = -0.52 ; 95% CI, -0.96 to -0.08 ; $p = 0.02$) (Figure 4).



Postoperative Complication

There were seven studies that reported the postoperative complication of the two groups. The heterogeneity test result was $p = 0.51$, $I^2 = 0\%$, and the fixed effect model was adopted. The meta-analysis result showed that there was no significant difference in the postoperative complication between the two groups (OR = 1.19; 95% CI, 0.62–2.28; $p = 0.60$).

Conversion Rate

There were six studies that reported the conversion rate of the two groups. The heterogeneity test result was $p = 0.36$, $I^2 = 7\%$, and the fixed effect model was adopted. The meta-analysis result showed that there was no significant difference in the conversion rate between the two groups (OR = 1.86; 95% CI, 0.67–5.16; $p = 0.23$).

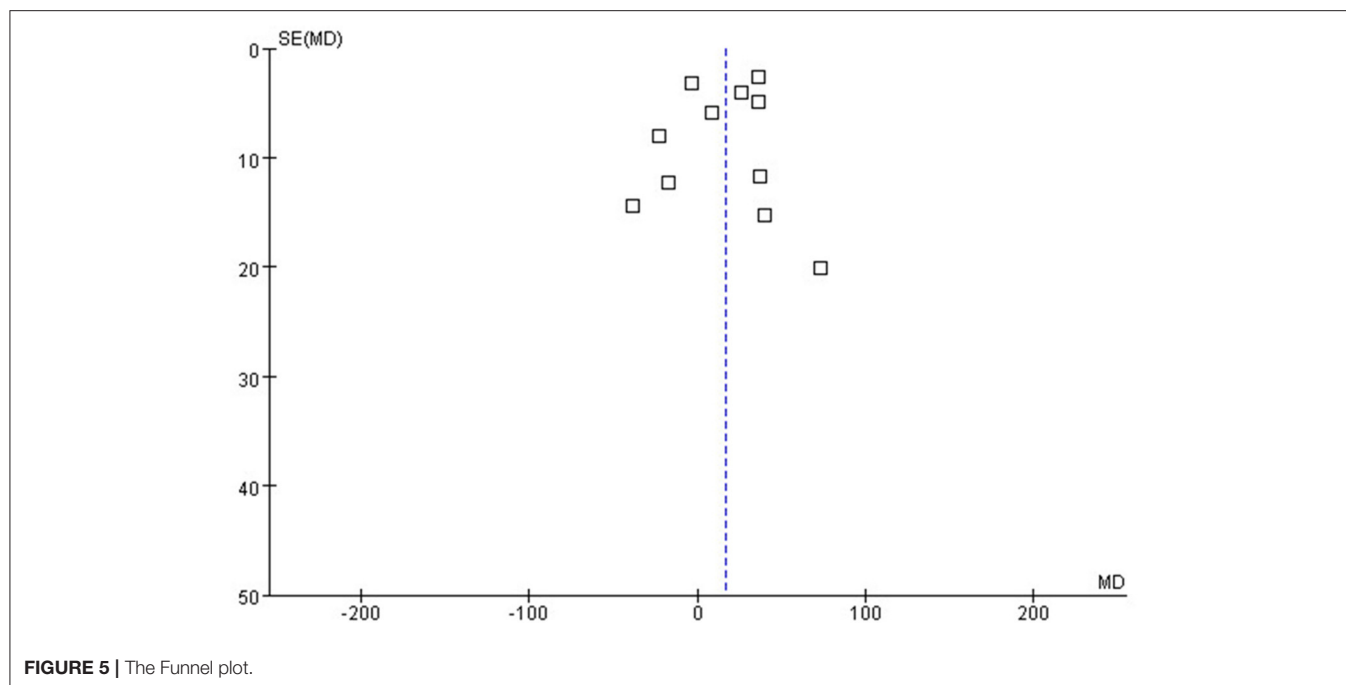


FIGURE 5 | The Funnel plot.

Recurrence

There were six studies that reported the recurrence of the two groups. The heterogeneity test result was $p = 0.99$, $I = 0\%$, and the fixed effect model was adopted. The meta-analysis result showed that there was no significant difference in the recurrence between the two groups ($OR = 1.23$; 95% CI, 0.55–2.74; $p = 0.62$).

Publication Bias

In the bias analysis, the effect index SMD was used as the abscissa axis and SE (SMD) as the vertical axis to draw an inverted funnel plot (see **Figure 5**). The results showed that the funnel plot was not completely symmetrical on the left and right, suggesting that there might be publication bias in the included literatures in this study.

DISCUSSION

UPJO is a common disease in pediatric urology with an incidence of about 1/2,000 in newborns, and the ratio of the men to women is 2~3:1 (20). UPJO usually reduces the free flow of urine from the renal pelvis to the ureter, causing dilation of the renal pelvis and calyces and hydronephrosis (21). Ureteropelvic junction stenosis, crossing vessel, and ureteropelvic junction valve and stone are also important causes of UPJO. Ureteropelvic junction stenosis is the most important cause of congenital UPJO in newborns, which can impair renal function and eventually lead to renal parenchymal atrophy (22). Lack of smooth muscle, collagen deposition, increased connective tissue, and decrease in the proportion of interstitial cells of the Cajal are the pathological characteristics of ureteropelvic junction stenosis. According to the study of Bady et al. (23), the stenosis segment is related to the increase in acetylcholinesterase activity and norepinephrine response.

Surgical intervention for UPJO is aimed at removing of obstruction segment, relieving of pain, and preserving of renal function (4, 24). There are many indices that have been used to identify the need for surgery, such as SFU grade 3 or 4, continued expansion of the renal pelvis collection system, a renal cortex <5 mm, a single kidney with decrease in GFR, and symptom of pain (25, 26). Regrettably, there has been no reliable criterion that could be used in risk stratification and decision making with UPJO. Most researches support that the reduction in cortical thickness and increased severity of hydronephrosis are important signs of fibrosis of renal parenchyma and reduced glomerular numbers (27); however, in the study of Huang et al., (28) it was pointed out that the degree of hydronephrosis did not significantly correlate with the number of affected glomeruli. Mercapto-acetyl-triglycine and dimercaptosuccinic acid can objectively reflect the degree of kidney damage, but they usually need sedation and repeated evaluation in infants or younger children. Pavlaki et al. (29) proved that the level of urinary NGAL and serum cystatin C are remarkably decreased from the preoperative to the postoperative period, and they could be reliable biomarkers to distinguish the kidney condition among patients with severe and mild hydronephrosis.

There are many methods for treating UPJO, including endopyeloplasty, endopyelotomy, and pyeloplasty, but pyeloplasty is the most reliable, which is currently recognized as the gold standard for the treatment of UPJO (30). Up to now, the overall success rate of the open pyeloplasty is over 90%, and the recurrence of postoperative hydronephrosis usually occurs within 2 years after the operation. Chow et al. (24) pointed out that preoperative renal function <30%, history of endopyelotomy, and early urinary leakage were the risk factors for surgical failure.

According to the results of the meta-analysis, there were no significant difference between the two approaches on postoperative hospital stay, complications, conversion rate, and recurrence. RLP took more operative time than TLP, and the difference was statistically significant ($MD = 16.60$; 95% CI, 3.40–29.80; $p = 0.01$). Since the transperitoneal approach requires to cut the mesentery through the medial or lateral colon to enter the retroperitoneal cavity, it takes more time to expose the pelvis. Wu et al. (31) believed that the retroperitoneal approach will be more conducive to shortening the operative time with the familiarity of the surgeon with the anatomy of the retroperitoneal cavity. According to the results of the present study, RLP can significantly shorten the time of postoperative drainage and reduce the score of postoperative VAS ($MD = -1.06$; 95% CI, -1.92 to -0.19 ; $p = 0.02$; $MD = -0.52$; 95% CI, -0.96 to -0.08 ; $p = 0.02$), which may be related to the shorter route of retroperitoneal approach, with less interference to abdominal organs, faster recovery of gastrointestinal function, and low incidence of intestinal obstruction.

Open pyeloplasty has been widely accepted as the prior choice for UPJO, with a success rate of >90% in most reports (32). Since the LP in adults and children were first successfully performed in 1993 and 1995, respectively, it has gradually replaced open pyeloplasty as the preferred option for UPJO (33, 34). Most researchers support that LP is beneficial and advantageous to old patients, but for infants younger than 6 months, opinions are different (35, 36).

Nowadays, the application of laparoscopy in pediatric urology has been developed for 30 years. Laparoscopy seems to be an established technique for children. LP may be applied with transperitoneal and retroperitoneal approach. TLP can provide a larger space for free movement of instruments and intraoperative suturing. Meanwhile, the anatomical marks are easier to identify for surgeons. However, due to the stimulation of urine to the intestinal and the disturbed abdominal cavity, the rate of bowel-related complications, including abdominal organ injury and postoperative intestinal obstruction, is increased (1). Which surgical method is better is still controversial; some scholars argued that if the renal pelvis dilated more than 6 cm, with large or multiple renal stones, pelvic kidney, or horseshoe kidney, TLP was easier and safer than RLP (37). Because the infants have a high sensitivity at CO_2 effects, theoretically, increased intra-abdominal pressure and hypothermia, TLP seems to be safer for infants to decrease the intra-abdominal pressure and hypothermia through shortening of the operative time (36, 38). Unfortunately, postoperative hypercapnia was not reported in the literature included in the study.

In terms of TLP, the surgical approach remains controversial too. TLP included paracolic sulci approach and mesentery

approach, and the option of surgical procedure usually depends on the location of the lesion. Due to the right renal pelvis and ureter, which are often located at the right colic flexure, UPJO on the right is recommended with the optimal paracolic sulci approach. During the operation, only the peritoneum of the lateral side of the right colon is cut, and the right colon is pushed medially to expose the renal pelvis and ureter. Due to the left colic flexure position, which is higher, covering the kidney, and the mesenteric just covering the left UPJ, the left mesentery approach is not only helpful in identifying the renal pelvis but also can avoid excessive dissection and dissociation of the left descending colon and perirenal fascia, shorten the operation time, relieve surgical trauma, relieve postoperative pain, and accelerate postoperative recovery (39, 40).

There were some limitations to this study that should be noted. On the one hand, not all of the studies included were RCT; it caused an inevitable selection bias in the study. On the other hand, there was limited documentation of follow-up; of the 10 studies assessed, 2 studies gave no length of follow-up and 3 studies published on a follow-up of <12 months. It affected the outcome of the long-term postoperative complications.

CONCLUSION

RLP and TLP have the same results in postoperative complications, conversion rate, and recurrence, but RLP has potential benefit to make the patients recover faster after the operation as it can reduce the time of postoperative drainage and postoperative VAS. It is hard to say which approach is better because RLP takes more operative time and needs a longer learning curve, so the surgeon should choose the appropriate operation according to personal preference and experience during the early practice. For experienced surgeons, RLP seems to be a more beneficial choice for patients.

DATA AVAILABILITY STATEMENT

The original contributions presented in the study are included in the article/supplementary material, further inquiries can be directed to the corresponding author/s.

AUTHOR CONTRIBUTIONS

FJ collected and analyzed data and drafted the original manuscript. LC collected data and participated in to amend the manuscript. CW collected and analyzed data. JL collected data. YH analyzed data. BY designed present study and amended the manuscript. All authors contributed to the article and approved the submitted version.

REFERENCES

1. Zhang S, Li J, Li C, Xie X, Ling F, Liang Y, et al. Evaluation of the clinical value of retroperitoneal laparoscopic pyeloplasty

in the treatment of ureteropelvic junction obstruction in infants: a single-center experience involving 22 consecutive patients. *Medicine*. (2019) 98:e17308. doi: 10.1097/MD.00000000000017308

2. Villemagne T, Fourcade L, Camby C, Szwarc C, Lardy H, Leclair M. Long-term results with the laparoscopic transposition of renal lower pole crossing vessels. *J Pediatr Urol.* (2015) 11:174.e1–7. doi: 10.1016/j.jpuro.2015.04.023
3. Piaggio LA, Corbetta JP, Weller S, Dingevan RA, Duran V, Ruiz J, et al. Comparative, prospective, case-control study of open versus laparoscopic pyeloplasty in children with ureteropelvic junction obstruction: long-term results. *Front Pediatr.* (2017) 5:10. doi: 10.3389/fped.2017.00010
4. Chen JC, Zhang QL, Wang YJ, Cui X, Chen L, Zhang JQ, et al. Laparoscopic disconnected pyeloplasty to treat ureteropelvic junction obstruction (UPJO) in children. *Med Sci Monit.* (2019) 25:9131–7. doi: 10.12659/MSM.918164
5. Stang A. Critical evaluation of the newcastle-Ottawa scale for the assessment of the quality of nonrandomized studies in meta-analyses. *Eur J Epidemiol.* (2010) 25:603–5. doi: 10.1007/s10654-010-9491-z
6. Cumpston M, Li T, Page MJ, Chandler J, Welch VA, Higgins JP, et al. Updated guidance for trusted systematic reviews: a new edition of the cochrane handbook for systematic reviews of interventions. *Cochrane Database Syst Rev.* (2019) 10:ED000142. doi: 10.1002/14651858.ED000142
7. Hozo SP, Djulbegovic B, Hozo I. Estimating the mean and variance from the median, range, and the size of a sample. *BMC Med Res Methodol.* (2005) 5:13. doi: 10.1186/1471-2288-5-13
8. Abuanz S, Gamé X, Roche JB, Guillotreau J, Mouzin M, Sallusto F, et al. Laparoscopic pyeloplasty: comparison between retroperitoneoscopic and transperitoneal approach. *Urology.* (2010) 76:877–81. doi: 10.1016/j.urol.2009.11.062
9. Badawy H, Zoaier A, Ghoneim T, Hanno A. Transperitoneal versus retroperitoneal laparoscopic pyeloplasty in children: randomized clinical trial. *J Pediatr Urol.* (2015) 11:122.e1–6. doi: 10.1016/j.jpuro.2014.11.019
10. Hemal AK, Goel R, Goel A. Cost-effective laparoscopic pyeloplasty: single center experience. *Int J Urol.* (2003) 10:563–8. doi: 10.1046/j.1442-2042.2003.00706.x
11. Liu SK. A comparison of the clinical effects of different approaches to laparoscopic pyeloplasty for ureteropelvic junction obstruction. (2018). doi: 10.13188/2380-0585.1000021
12. Qadri SJ, Khan M. Retroperitoneal versus transperitoneal laparoscopic pyeloplasty: our experience. *Urol Int.* (2010) 85:309–13. doi: 10.1159/000319395
13. Shen HF, Dong Y, Liu XZ, Huang W, Qin ZC. Clinical effect of transperitoneal and retroperitoneal laparoscopic pyeloplasty on the treatment of ureteropelvic junction obstruction. *J Clin Urology.* (2020) 117–20.
14. Shoma AM, El Nahas AR, Bazeed MA. Laparoscopic pyeloplasty: a prospective randomized comparison between the transperitoneal approach and retroperitoneoscopy. *J Urol.* (2007) 178:2020–4; discussion 2024. doi: 10.1016/j.juro.2007.07.025
15. Singh V, Sinha RJ, Gupta DK, Kumar V, Pandey M, Akhtar A. Prospective randomized comparison between transperitoneal laparoscopic pyeloplasty and retroperitoneoscopic pyeloplasty for primary ureteropelvic junction obstruction. *JSLs.* (2014) 18. doi: 10.4293/JSLs.2014.00366
16. Xu W, Li YX. Effect study of transperitoneal vesus retroperitoneal laparoscopic pyeloplasty for ureteropelvic junction obstruction1. *Chin Prac Med.* (2017) 46–7.
17. Zhai ZZ, Shang PF, Zhang X, Yue ZJ, Wang JJ, Wang ZZ, et al. Comparison of laparoscopic retroperitoneal and peritoneal approaches in the treatment of ureteropelvic junction obstruction. *Chin J Min Inv Sur.* (2018) 405–8.
18. Zhang H. Comparison between transperitoneal laparoscopic pyeloplasty and retroperitoneoscopic pyeloplasty for ureteropelvic junction obstruction. *Chin Med Eng.* (2017) 36–39.
19. Zhu H, Shen C, Li X, Xiao X, Chen X, Zhang Q, et al. Laparoscopic pyeloplasty: a comparison between the transperitoneal and retroperitoneal approach during the learning curve. *Urol Int.* (2013) 90:130–5. doi: 10.1159/000343989
20. Kohno M, Ogawa T, Kojima Y, Sakoda A, Johnin K, Sugita Y, et al. Pediatric congenital hydronephrosis (ureteropelvic junction obstruction): medical management guide. *Int J Urol.* (2020) 27:369–76. doi: 10.1111/iju.14207
21. Zhu H, Wang J, Deng Y, Huang L, Zhu X, Dong J, et al. Use of double-J ureteric stents post-laparoscopic pyeloplasty to treat ureteropelvic junction obstruction in hydronephrosis for pediatric patients: a single-center experience. *J Int Med Res.* (2020) 48:1–8. doi: 10.1177/0300060520918781
22. Li XD, Wu YP, Wei Y, Chen SH, Zheng QS, Cai H, et al. Predictors of recoverability of renal function after pyeloplasty in adults with ureteropelvic junction obstruction. *Urol Int.* (2018) 100:209–15. doi: 10.1159/000486425
23. Babu R, Vittalraj P, Sundaram S, Shalini S. Pathological changes in ureterovesical and ureteropelvic junction obstruction explained by fetal ureter histology. *J Pediatr Urol.* (2019) 15:240.e1–240.e7. doi: 10.1016/j.jpuro.2019.02.001
24. Chow AK, Rosenberg BJ, Capoccia EM, Cherullo EE. Risk factors and management options for the adult failed ureteropelvic junction obstruction repair in the era of minimally invasive and robotic approaches: a comprehensive literature review. *J Endourol.* (2020). doi: 10.1089/end.2019.0737
25. Weitz M, Portz S, Laube GF, Meerpohl JJ, Bassler D. Surgery versus non-surgical management for unilateral ureteric-pelvic junction obstruction in newborns and infants less than two years of age. *Cochrane Database Syst Rev.* (2016) 7:CD010716. doi: 10.1002/14651858.CD010716.pub2
26. Tabari AK, Atqiaee K, Mohajerzadeh L, Rouzrokh M, Ghoroubi J, Alam A, et al. Early pyeloplasty versus conservative management of severe ureteropelvic junction obstruction in asymptomatic infants. *J Pediatr Surg.* (2020) 55:1936–40. doi: 10.1016/j.jpedsurg.2019.08.006
27. Passoni NM, Peters CA. Managing ureteropelvic junction obstruction in the young infant. *Front Pediatr.* (2020) 8:242. doi: 10.3389/fped.2020.00242
28. Huang WY, Peters CA, Zurakowski D, Borer JG, Diamond DA, Bauer SB, et al. Renal biopsy in congenital ureteropelvic junction obstruction: evidence for parenchymal maldevelopment. *Kidney Int.* (2006) 69:137–43. doi: 10.1038/sj.ki.5000004
29. Pavlaki A, Printza N, Farmaki E, Stabouli S, Taparkou A, Sterpi M, et al. The role of urinary NGAL and serum cystatin C in assessing the severity of ureteropelvic junction obstruction in infants. *Pediatr Nephrol.* (2020) 35:163–70. doi: 10.1007/s00467-019-04349-w
30. Desai MM, Desai MR, Gill IS. Endopyeloplasty versus endopyelotomy versus laparoscopic pyeloplasty for primary ureteropelvic junction obstruction. *Urology.* (2004) 64:16–21; discussion 21. doi: 10.1016/j.urol.2004.02.031
31. Wu Y, Dong Q, Han P, Liu L, Wang L, Wei Q. Meta-analysis of transperitoneal versus retroperitoneal approaches of laparoscopic pyeloplasty for ureteropelvic junction obstruction. *J Laparoendosc Adv Surg Tech A.* (2012) 22:658–62. doi: 10.1089/lap.2011.0508
32. Gatti JM, Amstutz SP, Bowlin PR, Stephany HA, Murphy JP. Laparoscopic vs. open pyeloplasty in children: results of a randomized, prospective, controlled trial. *J Urol.* (2017) 197:792–7. doi: 10.1016/j.juro.2016.10.056
33. Schuessler WW, Grune MT, Tecuanhuey LV, Preminger GM. Laparoscopic dismembered pyeloplasty. *J Urol.* (1993) 150:1795–9. doi: 10.1016/S0022-5347(17)35898-6
34. Peters CA, Schluskel RN, Retik AB. Pediatric laparoscopic dismembered pyeloplasty. *J Urol.* (1995) 153:1962–5. doi: 10.1097/00005392-199506000-00079
35. Fuchs J, Luthle T, Warmann SW, Haber P, Blumenstock G, Szavay P. Laparoscopic surgery on upper urinary tract in children younger than 1 year: technical aspects and functional outcome. *J Urol.* (2009) 182:1561–8. doi: 10.1016/j.juro.2009.06.063
36. Erol I, Karamik K, Islamoglu ME, Ateş M, Savaş M. Outcomes of infants undergoing laparoscopic pyeloplasty: a single-center experience. *Urologia.* (2019) 86:27–31. doi: 10.1177/0391560318802165

37. Khoder WY, Waidelich R, Ghamdi A, Schulz T, Becker A, Stief CG. A prospective randomised comparison between the transperitoneal and retroperitoneoscopic approaches for robotic-assisted pyeloplasty in a single surgeon, single centre study. *J Robot Surg.* (2018) 12:131–7. doi: 10.1007/s11701-017-0707-z
38. Zamfir Snykers C, De Plaen E, Vermersch S, Lopez M, Khelif K, Luyckx S, et al. Is laparoscopic pyeloplasty for ureteropelvic junction obstruction in infants under 1 year of age a good option. *Front Pediatr.* (2019) 7:352. doi: 10.3389/fped.2019.00352
39. Gupta NP, Mukherjee S, Nayyar R, Hemal AK, Kumar R. Transmesocolic robot-assisted pyeloplasty: single center experience. *J Endourol.* (2009) 23:945–8. doi: 10.1089/end.2008.0430
40. Zacchero M, Volpe A, Billia M, Tarabuzzi R, Varvello F, Angelis PD. Transmesenteric approach for left transperitoneal renal surgery: technique and experience. *J Laparoendosc Adv Surg Tech A.* (2012) 22:176–9. doi: 10.1089/lap.2011.0395

Conflict of Interest: The authors declare that the research was conducted in the absence of any commercial or financial relationships that could be construed as a potential conflict of interest.

Publisher's Note: All claims expressed in this article are solely those of the authors and do not necessarily represent those of their affiliated organizations, or those of the publisher, the editors and the reviewers. Any product that may be evaluated in this article, or claim that may be made by its manufacturer, is not guaranteed or endorsed by the publisher.

Copyright © 2021 Ji, Chen, Wu, Li, Hang and Yan. This is an open-access article distributed under the terms of the Creative Commons Attribution License (CC BY). The use, distribution or reproduction in other forums is permitted, provided the original author(s) and the copyright owner(s) are credited and that the original publication in this journal is cited, in accordance with accepted academic practice. No use, distribution or reproduction is permitted which does not comply with these terms.



Comparison of Drainage Methods After Pyeloplasty in Children: A 14-Year Study

Xiangpan Kong^{1,2}, Zhenpeng Li^{1,2}, Mujie Li^{1,2}, Xing Liu^{1,2} and Dawei He^{1,2*}

¹ Department of Urology, Children's Hospital of Chongqing Medical University, Chongqing, China, ² Ministry of Education Key Laboratory of Child Development and Disorders, International Science and Technology Cooperation Base of Child Development and Critical Disorders, National Clinical Research Center for Child Health and Disorders, Chongqing Key Laboratory of Pediatrics, Chongqing Key Laboratory of Children Urogenital Development and Tissue Engineering, Chongqing, China

OPEN ACCESS

Edited by:

Abdurrahman Onen,
Onen Pediatric Urology Center, Turkey

Reviewed by:

Andres Gomez Fraile,
University Hospital October 12, Spain
Santiago Vallasciani,
Sidra Medicine, Qatar

*Correspondence:

Dawei He
hedawei@hospital.cqmu.edu.cn

Specialty section:

This article was submitted to
Pediatric Urology,
a section of the journal
Frontiers in Pediatrics

Received: 19 September 2021

Accepted: 11 November 2021

Published: 13 December 2021

Citation:

Kong X, Li Z, Li M, Liu X and He D
(2021) Comparison of Drainage
Methods After Pyeloplasty in Children:
A 14-Year Study.
Front. Pediatr. 9:779614.
doi: 10.3389/fped.2021.779614

Objective: To summarize our experiences with drainage methods after laparoscopic pyeloplasty with a 14-year study.

Methods: We reviewed the data of the 838 children operated on for hydronephrosis due to congenital ureteropelvic junction obstruction (UPJO) between July 2007 and July 2020. Patients' demographics, perioperative details, postoperative drainage stents [including double-J stent, percutaneous trans-anastomotic (PU) stent, and trans-ureterocystic external urethral stent (TEUS)], complications, hospital stay, and long-term follow-up outcomes were analyzed. Long-term follow-up was performed by outpatient visits and telephone follow-up. Moreover, we reviewed the details of nine cases of recurrence after laparoscopic pyeloplasty.

Results: Comparison of preoperative general data among the three groups indicated that there was no statistical difference in age, gender, and surgical side of the three groups. Statistical differences were found in the incidence of postoperative complications from the three postoperative drainage method groups, especially the incidence of reoperations ($p < 0.01$): there were six cases (3.19%) of recurrences in the TEUS group, two cases (0.36%) in the DJ group, and one case (0.93%) in the PU group. In the six recurrent cases from the TEUS group, four cases (44.4%) were found to have stenosis, and two cases (22.2%) have iatrogenic valvular formation.

Conclusion: Not all three types of drainage methods are suitable for drainage after pyeloplasty. Based on our findings, TEUS is not recommended.

Keywords: pyeloplasty, hydronephrosis, ureteropelvic junction obstruction, drainage methods, outcomes

INTRODUCTION

Congenital ureteropelvic junction obstruction (UPJO) is one of the most commonly encountered abnormalities that are responsible for persistent hydronephrosis in children (1). The classic option of treatment for UPJO is pyeloplasty. Since the first descriptions of laparoscopic pyeloplasty (LP) in 1993 by Schluskel (2) and in 1995 by Peters (3), LP has become the gold standard in the treatment

of UPJO, with its safety and minimal invasiveness. Usually, surgeons will choose to use a drainage stent after pyeloplasty; however, which drainage method is the best choice is still quite controversial (4, 5).

After LP, the choice of stent type has always been the focus of debate. For now, double-J (DJ) stent and percutaneous trans-anastomotic (PU) are widely used due to their reliable efficacy, but their disadvantages are also obvious, such as displacement and secondary anesthesia in the DJ stent (5–8) and urine leakage, kinks, and obstruction in the PU stent (5, 9, 10). Therefore, the ideal drainage method should be effective while being minimally invasive and safe. We used the trans-uretero-cystic external urethral stent (TEUS) approach to solve the problems caused by the DJ stent and PU stent; in the previous research (11), we proved it to be safe and effective by comparing it with the DJ stent, but there is a lack of verification of long-term follow-up results in the study.

After a long-term postoperative follow-up work, we found some abnormal results (postoperative recurrence rates were higher in children treated with TEUS than other drainage methods), which made us question the safety of this new drainage method. Therefore, we conducted this study to answer the question, summarize the relevant experience and findings, and share them with other scholars.

MATERIALS AND METHODS

Patients and Data

We retrospectively reviewed 838 patients with congenital UPJO without other urinary system deformities between July 2007 and June 2020 in the Children's Hospital of Chongqing Medical University. All patients underwent standard LP according to Anderson-Hynes technique (12); surgeries were performed by three senior surgeons with extensive experience in pediatric urology surgery. Patients' demographics, data of preoperative and postoperative exams, perioperative details, complications, hospital stay, and regular postoperatively follow-up results were collected (the occurrence of long-term complications).

Surgical Method and Follow Up

Stenting is selected by the surgeon according to the preoperative or intraoperative situation. The TEUS stent was placed by a cystoscope preoperatively; a Fr3 or Fr4 stent was inserted in a retrograde fashion into the ureter via cystoscopy, with a Foley catheter placed in the bladder. The other stents were used intraoperatively (**Figure 1**). Seven to 10 days after surgery, the PU stent and TEUS stent were removed, while the DJ stent was removed about 1–4 weeks after surgery.

Follow-up included outpatient follow-up at 3 and 6 months and once a year after surgery. Patients who were followed up for <1 year or were lost to follow-up were excluded.

Abbreviations: UPJO, ureteropelvic junction obstruction; LP, laparoscopic pyeloplasty; DJ, double-J; PU, percutaneous trans-anastomotic; TEUS, trans-uretero-cystic external urethral stent.

Statistical Analysis

Postoperative complications were analyzed by the Clavien-Dindo system (13). Analyses were performed using SPSS®, version 25.0 (IBM Corp., Armonk, NY, USA). Qualitative or categorical variables were expressed as numbers and compared using the χ^2 or Fisher's exact test, as appropriate. Data were compared between groups using Students' *t*-test or chi-square test. Data that did not comply with a normal distribution were expressed as median range and compared between groups using the Mann-Whitney test. All statistical tests were two-sided and performed with a significance level set at $p < 0.05$.

Ethics Approval

We obtained ethical approval for this study from the local institutional research ethics board. Written informed consent for participation was signed by the guardian of the child when hospitalized.

RESULTS

This study included a total of 838 children who underwent LP. The demographics data (gender, age, and surgical side) of the three groups were not statistically significant ($p > 0.05$). From the comparison of the operative duration, intraoperative blood loss, and hospitalization duration of patients in the three groups, statistically significant differences were found between groups. The operative duration was significantly different between the DJ group and the other two groups ($p < 0.05$). Bleeding volume in the PU group was significantly different from that of the other two groups ($p < 0.05$). Hospitalization duration was statistically different among the three groups. Among them, compared with the other two groups, the DJ group had the shortest hospitalization duration and the shortest operation duration; the PU group had the most blood loss; and the TEUS group had the longest operation duration (**Table 1**).

We calculated the time of the stent removal and postoperative complications in the three groups. The time of the stent removal of the three groups was 28.5 ± 12.2 , 7.4 ± 1.8 , and 10.9 ± 8.2 days, which was significantly different between groups. Meanwhile, the overall complication rate in the three groups was significantly different too. They are 24 (4.42%) cases, 23 (12.23%), and nine (8.41%) cases; especially, the incidence of reoperation in Group B (six cases) was significantly higher than in other groups (**Table 2**).

At last, we collected clinical data from the nine children (six boys and three girls) who underwent reoperation; all developed severe hydronephrosis before the first surgery. After the first operation, five children had a recent complication (two cases of urinary tract infection (UTI), two cases of anastomotic obstruction, and one case of persistent hematuria). In the choice of postoperative drainage stent, we used TEUS in six children, the DJ stent in two children, and the PU stent in one child. During the reoperation, surprisingly, four cases showed that the ureteropelvic junction still had scar stenosis, and two cases showed iatrogenic valve; it is worth noting that TEUS was used in all these six children. In the remaining three reoperation cases, two cases were found to have surrounding tissues adhering to the stent, ureteropelvic junction did not have obvious stenosis, and

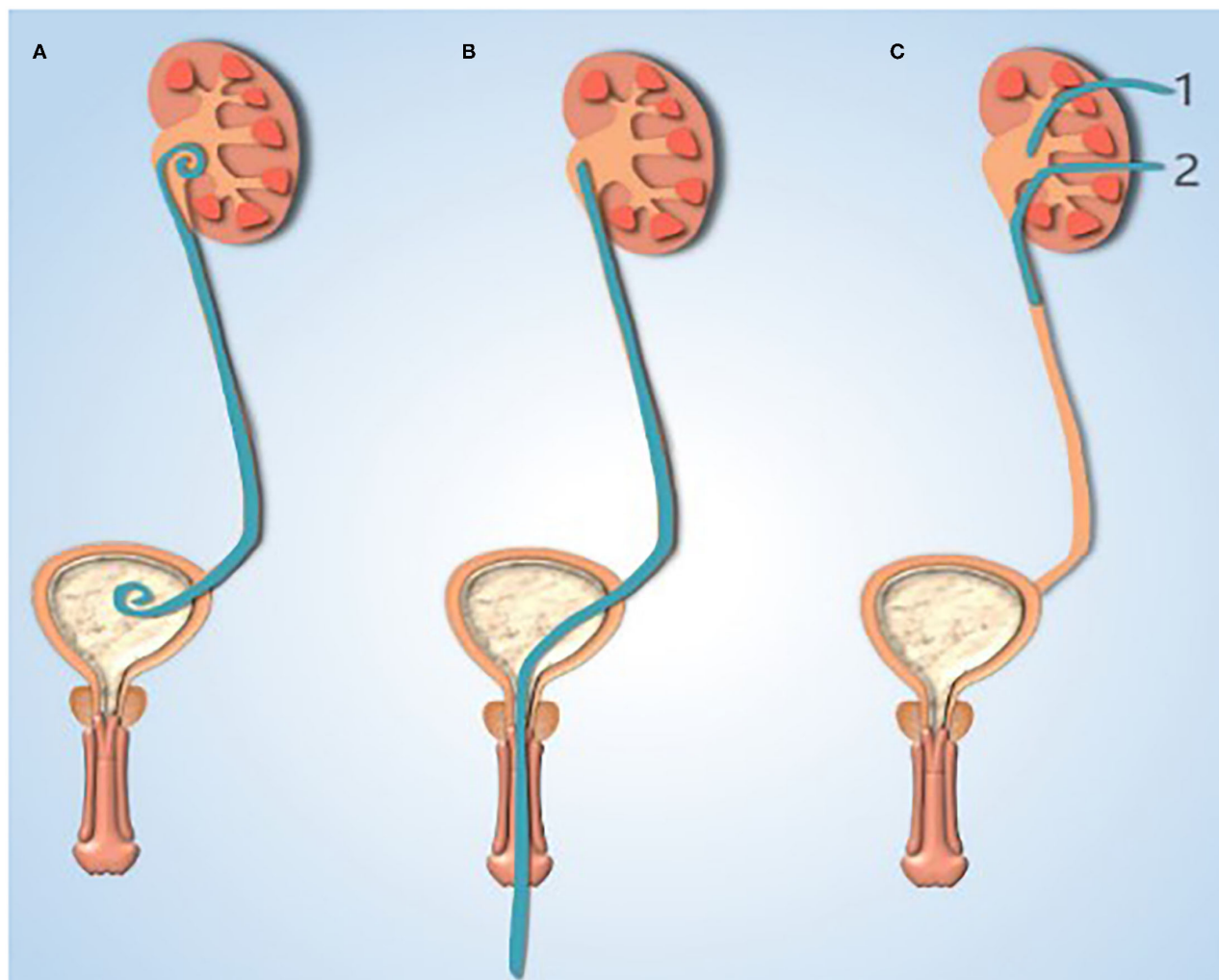


FIGURE 1 | Schematic diagram of three types of postoperative drainage stents. **(A)** DJ stent. **(B)** TEUS. **(C)** PU stent: 1, drainage stent; 2, stent. DJ, double-J stent; TEUS, trans-uretero-cystic external urethral stent; PU, percutaneous trans-anastomotic.

these patients had UTI after the first surgery. The last case had angulation distortion.

DISCUSSION

More than 30 years ago, open pyeloplasty (OP) was the gold standard for the treatment of UPJO. The first LP was reported in 1993 (2), which is safe, reliable, and minimally invasive. LP has gradually become the standard method for the treatment of UPJO in children. However, due to the peculiarities of children, which type of drainage method is the best choice has been controversial after pyeloplasty.

Should a stent be used after LP, and if a stent is used, which stent is the most ideal?

At present, there are two kinds of stent tubes widely used: the DJ stent and PU stent. Recently, Sarhan et al. (5) reported a multicenter study of the efficacy of drainage methods in 175

children between the two groups, which showed no significant difference in the incidence of postoperative complications or long-term outcomes. DJ stent insertion provides a shorter hospital stay, but a second operating room visit and anesthesia for removal are unavoidable. Similarly, in the study of Irene et al. (8), they also compared the costs incurred by the two drainage methods, and they believed that the DJ and PU stents were equivalent in terms of overall complications and success rate. Moreover, PU stents can avoid the need for additional general anesthesia and reduce overall hospital costs. Therefore, the advantages of the DJ stent are that it is minimally invasive, safe, and reliable, but it requires reoperation to remove the stent. The PU stent has the advantages of convenient stent removal and precise curative effect and the disadvantages of more trauma.

Since some catheter-related complications are inevitable with all types of drainage methods, what is the efficacy of stentless pyeloplasty? Bayne et al. (14) proved that the incidence

TABLE 1 | Patients' demographics and data of operation.

	DJ group	TEUS group	PU group	p-Value
Number, <i>n</i>	543	188	107	-
Male, gender, <i>n</i> (%)	445 (82.0)	147 (78.2)	79 (73.8)	0.285
Age, months, median (IQR)	57 (14–91)	30 (11–83)	48 (13–83)	0.064
Side, left, <i>n</i> (%)	427 (78.6)	146 (77.7)	77 (72.0)	0.285
• Operative duration, min	100 (79–130)	120 (95–155)	115 (90–140)	0.000*
• Median (IQR)				
• Bleeding volume, ml	10 (5–10)	10 (5–10)	10 (5–15)	0.000*
• Median (IQR)				
• Hospitalization duration, days	12 (10–15)	15 (14–18)	18 (16–20)	0.000*
• Median (IQR)				

DJ, double-J stent; TEUS, trans-uretero-cystic external urethral stent; PU, percutaneous trans-anastomotic; IQR, interquartile range.

*Significant.

TABLE 2 | The three drainage stents' removal time and complications.

	DJ group (<i>n</i> = 543)	TEUS group (<i>n</i> = 188)	PU group (<i>n</i> = 107)	p-Value
Stent removal time, day (mean ± SD)	28.5 ± 12.2	7.4 ± 1.8	10.9 ± 8.2	0.000*
Complications, <i>n</i> (%)	24	23	9	0.001*
UTI (CDG II)	12 (50)	6 (26.1)	3 (33.3)	0.715
Urine leakage (CDG II)	10 (41.7)	6 (26.1)	4 (44.4)	0.299
Stent drop (CDG II)	0 (0)	3 (13.0)	1 (11.1)	-
Omental hernia (CDG II)	0 (0)	1 (4.35)	0 (0)	-
Paralytic intestinal obstruction (CDG IIIb)	0 (0)	1 (4.35)	0 (0)	-
Recurrence (CDG IIIb)	2 (8.3)	6 (26.1)	1 (11.1)	0.007*

DJ, double-J stent; TEUS, trans-uretero-cystic external urethral stent; PU, percutaneous trans-anastomotic; UTI, urinary tract infection; CDG, clavien-dindo grading.

*Significant.

of postoperative urinary leakage was significantly higher in the stent-free group than in the stent-less group in their study. And in another meta-analysis reported by Liu (9) to evaluate the efficacy and safety of the DJ stent, PU stent, and stent-less pyeloplasty in pediatric pyeloplasty, the network meta-analysis (NMA) results showed that there were no significant differences between the three groups in surgical duration, surgical success rate, length of hospital stay, improvement in renal function, overall complications, and recurrence rates. Compared with the stent-less group, the incidence of postoperative pain was higher for the DJ stent and PU stent. The urine leakage rate of the DJ stent was lower than that of the PU stent and stent-less pyeloplasty. No significant differences were observed in other types of complications such as UTI, stent displacement, and postoperative recurrence. This is consistent with other similar studies (15, 16), so the cost of stent-less pyeloplasty is an unavoidable high incidence of urinary leakage. Unfortunately, almost all postoperative urine leakage needs to be treated by intubation; it means that reoperation is conducted within a short period of time after the first surgery, which is unacceptable for children and their parents, and it may cause doctor-patient conflict and bring great challenges to clinical work.

Combined with the above discussions, we find that stent-less pyeloplasty is the most minimally invasive, but it has a high

incidence of urinary leakage. Combined with the results of the other studies (5, 6, 10, 15–17), we found that the advantages of the DJ stent are that it is safe, reliable, effective, and more minimally invasive, while the removal time of the PU stent is shorter, which can reduce the occurrence of catheter-related complications. And the disadvantages are obvious too, such as issues with anesthesia during DJ stent removal and the high risk of urine leakage associated with the PU stent. In order to solve these problems, we tried a new drainage stent, TEUS. This drainage stent through the natural cavity solves not only the problem of DJ stent removal difficulty but also the problem of PU stent urine leakage around the catheter. Is this drainage method safe and effective? In an early short-term retrospective study, we compared the efficacy of the TEUS stent and DJ stent, and we found that in addition to the operation duration of the TEUS group, which was longer than that of the DJ group ($p < 0.05$), there was no difference in intraoperative blood loss, length of hospital stay, and incidence of complications [10 cases (22.2%) and eight cases (20%) of catheter-related complications in the DJ group and TEUS group, respectively ($p > 0.05$)] ($p > 0.05$). However, this study on the safety of TEUS lacked long-term follow-up results.

With the increased time of follow-up, we compared the removal time of stents and incidence/types of postoperative complications of 884 patients in the LP group who respectively

used the DJ stent, TEUS, and PU stent for drainage. One unexpected finding was the extent to which the removal time of stents and overall complication rate of the three groups were statistically different, and the average catheter duration of the three groups was as follows: DJ group (28.5 days), TEUS group (7.4 days), and PU group (10.9 days). The incidence of postoperative complications in the three groups was as follows: 24 cases (4.42%) in the DJ group, 23 cases (12.23%) in the TEUS group, and nine cases (8.41%) in the PU group; especially, the incidence of reoperation in the TEUS group (six cases, 26.1%) was significantly higher than that in the other groups (two cases, 8.3%; one case, 1.1%). The finding that the incidence of postoperative complications was significantly different among the three groups was seriously inconsistent with the previous conclusion. Then what causes the postoperative recurrence rate of the TEUS group to be significantly higher than that of the other groups?

Current studies suggest that stenting and drainage after pyeloplasty are necessary to facilitate anastomotic healing and reduce urinary leakage (18). Both the DJ and PU stents have this function, but the TEUS stent had no supporting effect due to its special structure. In addition, TEUS is placed prior to pyeloplasty, which means that the renal pelvis will be emptied before pyeloplasty begins, and it may affect the judgment of the length of the stenosis, which may lead to residual stenosis. Moreover, the TEUS was inserted before surgery, which interferes with the surgical field during surgery, which is also not conducive to complete resection and suture of the stenosis and may eventually lead to residual stenosis and inaccurate suture. These hypotheses were also confirmed by pathological findings during reoperation (four cases with residual stenosis and two cases with close adhesion to surrounding tissues). And to further test this hypothesis, we are now conducting further experimental studies. Now, we do not recommend the use of TEUS stents, and we suggest that other scholars should not ignore our findings when trying new stents.

Compared with other reported literature (5, 8, 13–16), the advantages of our study lie in the long follow-up time and importantly in the number of patients. To our knowledge, this is the first long-term follow-up of TEUS and study of the results.

The limitations of this study are that the data were retrospectively analyzed, the study group was not randomized, and the study was a single-center observation.

In summary, not all three types of drainage methods are suitable for pyeloplasty. We suggest that the use of the TEUS stent should be performed carefully, and we suggest that other scholars should not ignore our findings when trying new stents.

DATA AVAILABILITY STATEMENT

The raw data supporting the conclusions of this article will be made available by the authors, without undue reservation.

ETHICS STATEMENT

Written informed consent was obtained from the individual(s), and minor(s)' legal guardian/next of kin, for the publication of any potentially identifiable images or data included in this article.

AUTHOR CONTRIBUTIONS

XL and DH contributed to conception and design. DH contributed to administrative support. XK, ZL, and ML contributed to collection and assembly of data. XK contributed to manuscript writing. All authors contributed to manuscript revision, read, and approved the submitted version.

FUNDING

This study was funded by the Special Key Project of Chongqing Technology Innovation and Application Development (No. Cstc2019jscx-tjsbX0003).

ACKNOWLEDGMENTS

We would like to thank the parents and children who enrolled in the study. And we thank Dr. Wang Quan (Department of Cardiothoracic Surgery) for his valuable advice on the manuscript revision.

REFERENCES

- Jiang D, Tang B, Xu M, Lin H, Jin L, He L, et al. Functional and morphological outcomes of pyeloplasty at different ages in prenatally diagnosed society of fetal urology grades 3-4 ureteropelvic junction obstruction: is it safe to wait? *Urology*. (2017) 101:45–9. doi: 10.1016/j.urology.2016.10.004
- Schuessler WW, Grune MT, Tecuanhuey LV, Preminger GM. Laparoscopic dismembered pyeloplasty. *J Urol*. (1993) 150:1795–9. doi: 10.1016/S0022-5347(17)35898-6
- Peters CA, Schluskel RN, Retik AB. Pediatric laparoscopic dismembered pyeloplasty. *J Urol*. (1995) 153:1962–5. doi: 10.1016/S0022-5347(01)67378-6
- Ludwikowski BM, Botländer M, González R. The BULT method for pediatric mini laparoscopic pyeloplasty in infants: technique and results. *Front Pediatr*. (2016) 4:54. doi: 10.3389/fped.2016.00054
- Sarhan O, Al Awwad A, Al Otaay A, Al Faddagh A, El Helaly A, Al Ghanbar M, et al. Comparison between internal double J and external pyeloureteral stents in open pediatric pyeloplasty: a multicenter study. *J Pediatr Urol*. (2021) 17:511.e1. doi: 10.1016/j.jpuro.2021.03.027
- Ates KM, Vaizer RP, Newton DC, Hao S, Mahoney K, Morgans BA. Rare case: ureteropelvic junction complication presenting with bilateral labial abscesses and urosepsis requiring nephrectomy. *Urol Case Rep*. (2021) 37:101705. doi: 10.1016/j.eur.2021.101705
- Abadi AR, Dargahi M, Hosseini SJ. Misplacement of DJ stent into inferior vena cava in a patient with retroperitoneal fibrosis, a case report. *Urol Case Rep*. (2021) 38:101650. doi: 10.1016/j.eur.2021.101650
- Paraboschi I, Jannello L, Mantica G, Roberts L, Olubajo S, Paul A, et al. Outcomes and costs analysis of externalized pyeloureteral versus internal double-j ureteral stents after paediatric laparoscopic Anderson-Hynes pyeloplasty. *J Pediatr Urol*. (2021) 17:232.e1–e7. doi: 10.1016/j.jpuro.2020.12.006
- Liu X, Huang C, Guo Y, Yue Y, Hong J. Comparison of DJ stented, external stented and stent-less procedures for pediatric pyeloplasty: a network meta-analysis. *Int J Surg*. (2019) 68:126–33. doi: 10.1016/j.ijsu.2019.07.001

10. Chu DI, Shrivastava D, Van Batavia JP, Bowen DK, Tong CC, Long CJ, et al. Outcomes of externalized pyeloureteral versus internal ureteral stent in pediatric robotic-assisted laparoscopic pyeloplasty. *J Pediatr Urol.* (2018) 14:450.e1–450.e6. doi: 10.1016/j.jpuro.2018.04.012
11. Dong JJ, Wen S, Liu X, Lin T, Liu F, Wei GH. Trans-uretero-cystic external urethral stent for urinary diversion in pediatric laparoscopic pyeloplasty: a novel approach. *Medicine.* (2020) 99:e22135. doi: 10.1097/MD.00000000000022135
12. Anderson JC, Hynes W. Retrocaval ureter; a case diagnosed pre-operatively and treated successfully by a plastic operation. *Br J Urol.* (1949) 21:209–14. doi: 10.1111/j.1464-410X.1949.tb10773.x
13. Clavien PA, Barkun J, de Oliveira ML, Vauthey JN, Dindo D, Schulick RD, et al. The Clavien–Dindo classification of surgical complications: five-year experience. *Ann Surg.* (2009) 250:187–96. doi: 10.1097/SLA.0b013e3181b13ca2
14. Bayne AP, Lee KA, Nelson ED, Cisek LJ, Gonzales ET Jr, Roth DR. The impact of surgical approach and urinary diversion on patient outcomes in pediatric pyeloplasty. *J Urol.* (2011) 186(4 Suppl):1693–98. doi: 10.1016/j.juro.2011.03.103
15. Lombardo Alyssa., Toni Tiffany., Andolfi Ciro., Gundeti Mohan S. Comparative outcomes of double-J and cutaneous pyeloureteral stents in pediatric robot-assisted laparoscopic pyeloplasty. *J Endourol.* (2021) 35:1616–22. doi: 10.1089/end.2020.1115
16. Zhu H, Wang J, Deng Y, Huang L, Zhu X, Dong J, et al. Use of double-J ureteric stents post-laparoscopic pyeloplasty to treat ureteropelvic junction obstruction in hydronephrosis for pediatric patients: a single-center experience. *J Int Med Res.* (2020) 48:300060520918781. doi: 10.1177/0300060520918781
17. Braga LH, Lorenzo AJ, Farhat WA, Bağli DJ, Khoury AE, Pippi Salle JL. Outcome analysis and cost comparison between externalized pyeloureteral and standard stents in 470 consecutive open pyeloplasties. *J Urol.* (2008) 180(4 Suppl):1693–8. doi: 10.1016/j.juro.2008.05.084
18. Elmalik K, Chowdhury MM, Capps SN. Ureteric stents in pyeloplasty: a help or a hindrance? *J Pediatr Urol.* (2008) 4:275–9. doi: 10.1016/j.jpuro.2008.01.205

Conflict of Interest: The authors declare that the research was conducted in the absence of any commercial or financial relationships that could be construed as a potential conflict of interest.

Publisher's Note: All claims expressed in this article are solely those of the authors and do not necessarily represent those of their affiliated organizations, or those of the publisher, the editors and the reviewers. Any product that may be evaluated in this article, or claim that may be made by its manufacturer, is not guaranteed or endorsed by the publisher.

Copyright © 2021 Kong, Li, Li, Liu and He. This is an open-access article distributed under the terms of the Creative Commons Attribution License (CC BY). The use, distribution or reproduction in other forums is permitted, provided the original author(s) and the copyright owner(s) are credited and that the original publication in this journal is cited, in accordance with accepted academic practice. No use, distribution or reproduction is permitted which does not comply with these terms.

Advantages of publishing in Frontiers



OPEN ACCESS

Articles are free to read
for greatest visibility
and readership



FAST PUBLICATION

Around 90 days
from submission
to decision



HIGH QUALITY PEER-REVIEW

Rigorous, collaborative,
and constructive
peer-review



TRANSPARENT PEER-REVIEW

Editors and reviewers
acknowledged by name
on published articles

Frontiers

Avenue du Tribunal-Fédéral 34
1005 Lausanne | Switzerland

Visit us: www.frontiersin.org

Contact us: frontiersin.org/about/contact



REPRODUCIBILITY OF RESEARCH

Support open data
and methods to enhance
research reproducibility



DIGITAL PUBLISHING

Articles designed
for optimal readership
across devices



FOLLOW US

@frontiersin



IMPACT METRICS

Advanced article metrics
track visibility across
digital media



EXTENSIVE PROMOTION

Marketing
and promotion
of impactful research



LOOP RESEARCH NETWORK

Our network
increases your
article's readership