

Oral mucosal immunity: Homeostasis and inflammation

Edited by

Dunfang Zhang, Junji Xu, Hiroko Nakatsukasa
and Zhi Wang

Published in

Frontiers in Immunology



FRONTIERS EBOOK COPYRIGHT STATEMENT

The copyright in the text of individual articles in this ebook is the property of their respective authors or their respective institutions or funders. The copyright in graphics and images within each article may be subject to copyright of other parties. In both cases this is subject to a license granted to Frontiers.

The compilation of articles constituting this ebook is the property of Frontiers.

Each article within this ebook, and the ebook itself, are published under the most recent version of the Creative Commons CC-BY licence. The version current at the date of publication of this ebook is CC-BY 4.0. If the CC-BY licence is updated, the licence granted by Frontiers is automatically updated to the new version.

When exercising any right under the CC-BY licence, Frontiers must be attributed as the original publisher of the article or ebook, as applicable.

Authors have the responsibility of ensuring that any graphics or other materials which are the property of others may be included in the CC-BY licence, but this should be checked before relying on the CC-BY licence to reproduce those materials. Any copyright notices relating to those materials must be complied with.

Copyright and source acknowledgement notices may not be removed and must be displayed in any copy, derivative work or partial copy which includes the elements in question.

All copyright, and all rights therein, are protected by national and international copyright laws. The above represents a summary only. For further information please read Frontiers' Conditions for Website Use and Copyright Statement, and the applicable CC-BY licence.

ISSN 1664-8714
ISBN 978-2-8325-2788-7
DOI 10.3389/978-2-8325-2788-7

About Frontiers

Frontiers is more than just an open access publisher of scholarly articles: it is a pioneering approach to the world of academia, radically improving the way scholarly research is managed. The grand vision of Frontiers is a world where all people have an equal opportunity to seek, share and generate knowledge. Frontiers provides immediate and permanent online open access to all its publications, but this alone is not enough to realize our grand goals.

Frontiers journal series

The Frontiers journal series is a multi-tier and interdisciplinary set of open-access, online journals, promising a paradigm shift from the current review, selection and dissemination processes in academic publishing. All Frontiers journals are driven by researchers for researchers; therefore, they constitute a service to the scholarly community. At the same time, the *Frontiers journal series* operates on a revolutionary invention, the tiered publishing system, initially addressing specific communities of scholars, and gradually climbing up to broader public understanding, thus serving the interests of the lay society, too.

Dedication to quality

Each Frontiers article is a landmark of the highest quality, thanks to genuinely collaborative interactions between authors and review editors, who include some of the world's best academicians. Research must be certified by peers before entering a stream of knowledge that may eventually reach the public - and shape society; therefore, Frontiers only applies the most rigorous and unbiased reviews. Frontiers revolutionizes research publishing by freely delivering the most outstanding research, evaluated with no bias from both the academic and social point of view. By applying the most advanced information technologies, Frontiers is catapulting scholarly publishing into a new generation.

What are Frontiers Research Topics?

Frontiers Research Topics are very popular trademarks of the *Frontiers journals series*: they are collections of at least ten articles, all centered on a particular subject. With their unique mix of varied contributions from Original Research to Review Articles, Frontiers Research Topics unify the most influential researchers, the latest key findings and historical advances in a hot research area.

Find out more on how to host your own Frontiers Research Topic or contribute to one as an author by contacting the Frontiers editorial office: frontiersin.org/about/contact

Oral mucosal immunity: Homeostasis and inflammation

Topic editors

Dunfang Zhang — Sichuan University, China

Junji Xu — Capital Medical University, China

Hiroko Nakatsukasa — Chiba University, Japan

Zhi Wang — Sun Yat-sen University, China

Citation

Zhang, D., Xu, J., Nakatsukasa, H., Wang, Z., eds. (2023). *Oral mucosal immunity: Homeostasis and inflammation*. Lausanne: Frontiers Media SA.
doi: 10.3389/978-2-8325-2788-7

Table of contents

05	Editorial: Oral mucosal immunity: homeostasis and inflammation Dunfang Zhang, Junji Xu, Zhi Wang and Hiroko Nakatsukasa
08	Automatic Detection of Image-Based Features for Immunosuppressive Therapy Response Prediction in Oral Lichen Planus Ziang Xu, Qi Han, Dan Yang, Yijun Li, Qianhui Shang, Jiaxin Liu, Weiqi Li, Hao Xu and Qianming Chen
20	A genome-wide association analysis: m6A-SNP related to the onset of oral ulcers Zhuoxuan Wu, Weimin Lin, Quan Yuan and Mingyue Lyu
30	Differential genotypes of TNF-α and IL-10 for immunological diagnosis in discoid lupus erythematosus and oral lichen planus: A narrative review Ruochong Wang, Xuefeng Zhang and Siyu Wang
41	Association of Hashimoto's thyroiditis and anti-thyroid antibodies with oral lichen planus: A cross-sectional study Tianyu Zhang, Feifei Hou, Dan Liu, Hangfan Zhou, Yutong Sun, Xiaoting Deng, Yiming Xu, Yanxuan Xiao, Xianwen Wang, Chuanji Wu, Yang Meng, Peiyang Yuan, Xuemei Qiu, Lu Ye, Yuye Liang, Wei Wei and Lu Jiang
49	Multi-omics analysis reveals the effects of microbiota on oral homeostasis Huiqing Long, Li Yan, Juncai Pu, Yiyun Liu, Xiaogang Zhong, Haiyang Wang, Lu Yang, Fangzhi Lou, Shihong Luo, Yingying Zhang, Yang Liu, Peng Xie, Ping Ji and Xin Jin
60	Oral manifestations serve as potential signs of ulcerative colitis: A review Chunyu Li, Yuqi Wu, Yulang Xie, You Zhang, Sixin Jiang, Jiongke Wang, Xiaobo Luo and Qianming Chen
73	Senescence-associated secretory phenotype and its impact on oral immune homeostasis Ziqi Yue, Lulingxiao Nie, Pengfei Zhao, Ning Ji, Ga Liao and Qi Wang
87	A metagenome-wide association study of the gut microbiota in recurrent aphthous ulcer and regulation by thalidomide Xiang Wang, Kexu Xiong, Fan Huang, Jinqun Huang, Qin Liu, Ning Duan, Huanhuan Ruan, Hongliu Jiang, Yanan Zhu, Lin Lin, Yuefeng Song, Maomao Zhao, Lichun Zheng, Pei Ye, Yajie Qian, Qingang Hu, Fuhua Yan and Wenmei Wang
101	Aging envisage imbalance of the periodontium: A keystone in oral disease and systemic health Verónica Villalobos, Mauricio Garrido, Antonia Reyes, Christian Fernández, Catalina Diaz, Vicente A. Torres, Pablo A. González and Mónica Cáceres

- 109 **Regulatory T cell therapy suppresses inflammation of oral mucosa**
Ningning Xue, Ying Wang, Hao Cheng, Hantian Liang, Xinzou Fan, Fengqiong Zuo, Xin Zeng, Ning Ji and Qianming Chen
- 118 **Type-2 epithelial-mesenchymal transition in oral mucosal nonneoplastic diseases**
Zhaosong Meng, Tianle Yang and Dayong Liu
- 127 **Orofacial clefts lead to increased pro-inflammatory cytokine levels on neonatal oral mucosa**
Corinna L. Seidel, Elena Percivalle, Marco Tschaftari, Matthias Weider, Karin Strobel, Ines Willershausen, Christoph Unertl, Helga M. Schmetzer, Manuel Weber, Michael Schneider, Benjamin Frey, Udo S. Gaipf, Matthias W. Beckmann and Lina Götz
- 146 **Pathogenesis and treatment of Sjogren's syndrome: Review and update**
Qipeng Zhan, Jianan Zhang, Yubin Lin, Wenjing Chen, Xinzou Fan and Dunfang Zhang



OPEN ACCESS

EDITED AND REVIEWED BY
Diana Boraschi,
Chinese Academy of Science (CAS), China

*CORRESPONDENCE

Dunfang Zhang
✉ izdf@163.com
Hiroko Nakatsukasa
✉ nakatsukasa@chiba-u.jp

RECEIVED 30 April 2023
ACCEPTED 30 May 2023
PUBLISHED 06 June 2023

CITATION

Zhang D, Xu J, Wang Z and Nakatsukasa H (2023) Editorial: Oral mucosal immunity: homeostasis and inflammation. *Front. Immunol.* 14:1214926. doi: 10.3389/fimmu.2023.1214926

COPYRIGHT

© 2023 Zhang, Xu, Wang and Nakatsukasa. This is an open-access article distributed under the terms of the [Creative Commons Attribution License \(CC BY\)](#). The use, distribution or reproduction in other forums is permitted, provided the original author(s) and the copyright owner(s) are credited and that the original publication in this journal is cited, in accordance with accepted academic practice. No use, distribution or reproduction is permitted which does not comply with these terms.

Editorial: Oral mucosal immunity: homeostasis and inflammation

Dunfang Zhang^{1*}, Junji Xu^{2,3}, Zhi Wang⁴ and Hiroko Nakatsukasa^{5*}

¹Department of Biotherapy, State Key Laboratory of Biotherapy and Cancer Center, Collaborative Innovation Center of Biotherapy, West China Hospital, Sichuan University, Chengdu, Sichuan, China,

²Laboratory of Tissue Regeneration and Immunology and Department of Periodontics, Beijing Key Laboratory of Tooth Regeneration and Function Reconstruction, School of Stomatology, Capital Medical University, Beijing, China, ³Immunology Research Center for Oral and Systemic Health, Beijing Friendship Hospital, Capital Medical University, Beijing, China, ⁴Hospital of Stomatology, Guanghua School of Stomatology, Guangdong Provincial Key Laboratory of Stomatology, and Zhongshan School of Medicine, Sun Yat-Sen University, Guangzhou, Guangdong, China, ⁵Laboratory of Microbiology and Immunology, Graduate School of Pharmaceutical Sciences, Chiba University, Chiba, Japan

KEYWORDS

oral immunity, immune homeostasis, oral mucosa, oral inflammatory disorder, oral inflammation

Editorial on the Research Topic

Oral mucosal immunity: homeostasis and inflammation

As the opening of the digestive tract, the on-going mechanical damage caused by chewing leads to continual inflammatory challenges and sustained immune responses to oral microorganisms and food (1). Oral mucosal inflammatory diseases, including infectious diseases (e.g. gingivitis, oral candidiasis, and oral herpes) and non-infectious inflammatory diseases (e.g. oral lichen planus (OLP) and recurrent aphthous ulcer (RAU)) are common and frequently occurring diseases of oral mucosa and may seriously affect our oral health. Besides, many systemic inflammatory diseases have typical oral inflammation phenotypes. During the past decade, a number of key progresses have been made in the study of oral mucosal immune homeostasis and diseases (2). By now, it has been well proven that oral mucosal immunity could affect the immune responses in the gastric intestinal tract and throughout the whole body (3). Thus, the goal of this Research Topic is to collect the latest research advances regarding the regulation of oral mucosal immunity in health and disease. To this end, we hosted 13 original research articles, review articles, and mini reviews.

Oral ulcer is the most common inflammatory disease in the oral cavity. To investigate whether N6-methyladenosine (m6A)-related single nucleotide polymorphisms (m6A-SNPs) are involved in the pathogenesis of oral ulcers, Wu et al. analyzed genome-wide association studies (GWAS) database and identified 11 m6A-SNPs that were related to oral ulcers, showing m6A RNA transcription modification may be involved in the development of oral ulcers.

OLP is a chronic inflammatory disorder of the oral mucosa (4). The clinical symptoms of OLP and discoid lupus erythematosus (DLE) are very similar. Wang R. et al. summarized

the significant differences in the expression levels and genotype polymorphism of two cytokines, TNF- α and IL-10, in OLP and DLE. They concluded that differential genotypes of TNF- α and IL-10 could be an immunological diagnosis for these two diseases.

Currently, the treatment of OLP mainly relies on immunosuppressive drugs (5). It has been proven that the response of OLP patients to the common immunosuppressive therapy is heterogeneous (6). To predicate the effectiveness of immunosuppressive therapy in OLP, Xu et al. developed a workflow by acquiring image-based features in OLP. They found that the best performance prediction model built by logistic regression showed an accuracy of 90%. This model could provide a valuable reference for the choice of medication for the OLP clinical treatment. Besides traditional immunosuppressive drugs, novel immunotherapy approaches are gaining traction. Xue et al. found that regulatory T cell (Treg cell) therapy may be an effective new treatment strategy for oral inflammatory diseases such as OLP.

The oral cavity has a rich symbiotic microbiome, second only to that of the gut (3). Long et al. revealed that the microbiota might maintain oral homeostasis by reshaping the structure of the oral epithelial barrier and changing the function of molecular biology. Wang X. et al. investigated the association between gut microbiota alterations and recurrent aphthous ulcer (RAU), and they indicated that gut dysbacteriosis, microbial dysfunction and immune imbalance occurred in RAU patients.

The incidences of oral mucosal inflammatory diseases are associated with a variety of systemic diseases (7). Zhang et al. found that the prevalence of Hashimoto's thyroiditis (HT) in OLP patients, especially in female OLP patients, is significantly higher than that in the general population. Li et al. reviewed the findings between oral mucosal inflammation and ulcerative colitis (UC), and they concluded that pyostomatitis vegetans, RAU and periodontitis, could not only be used to be risk factors for disease occurrence of UC, but also could be used to predict disease severity of UC. More than that, Seidel et al. investigated levels of inflammatory factors in newborns with orofacial clefts (OFC), and found that the expression of several inflammatory factors was increased than that of the healthy controls, suggesting that these children were at risk for oral mucosal inflammation.

So far, the pathogenesis of various oral mucosal inflammatory diseases is still unclear. Epithelial-mesenchymal transition (EMT) is a crucial biological process in the pathogenesis of oral mucosal disorders. Meng et al. provided a comprehensive evaluation of type-2 EMT in chronically inflammatory oral mucosal disorders, and they believe that targeting EMT could be a promising novel strategy to treat oral mucosal disorders in the future. Besides EMT, cellular senescence caused tissue aging is also thought to be a key factor in oral inflammation. Villalobos et al. summarized the effects of aging on periodontal tissues, and concluded that it could cause the imbalance of the periodontium and periodontitis. Yue et al. summarized the studies of the senescence-associated secretory phenotype (SASP) in oral immunity, and they found that SASP might play a pleiotropic role in the pathogenesis of oral immunity.

In addition to oral mucosa, the immune homeostasis of oral secretory glands such as salivary glands is also very important for health. Sjogren's syndrome (SS) is a chronic autoimmune disorder

that seriously affects the quality of life of patients (8). Zhan et al. reviewed the pathogenesis and treatment of SS, and they emphasized that targeted drugs, low-side-effect drugs, and combination therapies should be the focus of future research.

In summary, this Research Topic collected the current advances regarding the oral mucosal immune regulation, oral mucosal inflammatory disease pathogenesis and novel therapy strategies. More and more evidence shows that oral mucosal immune homeostasis is not only indispensable for health of the oral cavity, but also important for systemic health. Future studies should focus on two aspects: one is to explore the relationship between oral mucosal immune homeostasis and systemic immune homeostasis; the other is to study how to apply the findings of oral mucosal immunopathogenesis and novel therapy strategies to clinical treatment.

Author contributions

DZ and HN wrote the manuscript. All authors reviewed and edited the manuscript, and approved it for publication.

Funding

DZ is supported by the National Natural Science Foundation of China (No. 81600876, 82171829), the Key Project of the Science and Technology Department of Sichuan Province (No. 22GJHZ0141), the 1-3-5 Project for Disciplines of Excellence, West China Hospital, Sichuan University (No. ZYYC21012), and the Fundamental Research Funds for the Central Universities (1082204112F26).

Acknowledgments

DZ sincerely wants to commemorate Dr. Sang-A Park, who passed away suddenly in a car accident on January 22, 2018.

Conflict of interest

The authors declare that the research was conducted in the absence of any commercial or financial relationships that could be construed as a potential conflict of interest.

Publisher's note

All claims expressed in this article are solely those of the authors and do not necessarily represent those of their affiliated organizations, or those of the publisher, the editors and the reviewers. Any product that may be evaluated in this article, or claim that may be made by its manufacturer, is not guaranteed or endorsed by the publisher.

References

1. Dutzan N, Abusleme L, Bridgeman H, Greenwell-Wild T, Zangerle-Murray T, Fife ME, et al. On-going mechanical damage from mastication drives homeostatic Th17 cell responses at the oral barrier. *Immunity* (2017) 46(1):133–47. doi: 10.1016/j.immuni.2016.12.010
2. Williams DW, Hajishengallis G, Moutsopoulos NM. Regional specification of oral mucosal immunity. *Sci Immunol* (2022) 7(72):eabp8632. doi: 10.1126/sciimmunolabp8632
3. Kitamoto S, Nagao-Kitamoto H, Hein R, Schmidt TM, Kamada N. The bacterial connection between the oral cavity and the gut diseases. *J Dent Res* (2020) 99(9):1021–9. doi: 10.1177/0022034520924633
4. Wang H, Zhang D, Han Q, Zhao X, Zeng X, Xu Y, et al. Role of distinct CD4(+) T helper subset in pathogenesis of oral lichen planus. *J Oral Pathol Med* (2016) 45(6):385–93. doi: 10.1111/jop.12405
5. Zhang D, Wang J, Li Z, Zhou M, Chen Q, Zeng X, et al. The activation of NF- κ B in infiltrated mononuclear cells negatively correlates with treg cell frequency in oral lichen planus. *Inflammation* (2015) 38(4):1683–9. doi: 10.1007/s10753-015-0145-x
6. Chamani G, Rad M, Zarei MR, Lotfi S, Sadeghi M, Ahmadi Z. Efficacy of tacrolimus and clobetasol in the treatment of oral lichen planus: a systematic review and meta-analysis. *Int J Dermatol* (2015) 54(9):996–1004. doi: 10.1111/ijd.12925
7. Kleinstein SE, Nelson KE, Freire M. Inflammatory networks linking oral microbiome with systemic health and disease. *J Dent Res* (2020) 99(10):1131–9. doi: 10.1177/0022034520926126
8. Xu J, Wang D, Liu D, Fan Z, Zhang H, Liu O, et al. Allogeneic mesenchymal stem cell treatment alleviates experimental and clinical sjogren syndrome. *Blood* (2012) 120(15):3142–51. doi: 10.1182/blood-2011-11-391144



Automatic Detection of Image-Based Features for Immunosuppressive Therapy Response Prediction in Oral Lichen Planus

Ziang Xu^{1†}, Qi Han^{1†}, Dan Yang¹, Yijun Li¹, Qianhui Shang¹, Jiaxin Liu¹, Weiqi Li¹, Hao Xu^{1*} and Qianming Chen^{1,2*}

OPEN ACCESS

Edited by:

Junji Xu,
Capital Medical University, China

Reviewed by:

Jiajia Han,
Chinese Academy of Medical
Sciences and Peking Union Medical
College, China
Lu Jia,
Capital Medical University, China

*Correspondence:

Hao Xu
hao.xu@scu.edu.cn
Qianming Chen
qmchen@scu.edu.cn

[†]These authors have contributed
equally to this work

Specialty section:

This article was submitted to
Mucosal Immunity,
a section of the journal
Frontiers in Immunology

Received: 13 May 2022

Accepted: 26 May 2022

Published: 23 June 2022

Citation:

Xu Z, Han Q, Yang D, Li Y,
Shang Q, Liu J, Li W, Xu H
and Chen Q (2022) Automatic
Detection of Image-Based
Features for Immunosuppressive
Therapy Response Prediction
in Oral Lichen Planus.
Front. Immunol. 13:942945.
doi: 10.3389/fimmu.2022.942945

¹ State Key Laboratory of Oral Diseases, National Clinical Research Center for Oral Diseases, Chinese Academy of Medical Sciences Research Unit of Oral Carcinogenesis and Management, West China Hospital of Stomatology, Sichuan University, Chengdu, China, ² Key Laboratory of Oral Biomedical Research of Zhejiang Province, Affiliated Stomatology Hospital, Zhejiang University School of Stomatology, Hangzhou, China

Oral lichen planus (OLP) is a chronic inflammatory disease, and the common management focuses on controlling inflammation with immunosuppressive therapy. While the response to the immunosuppressive therapy is heterogeneous, exploring the mechanism and prediction of the response gain greater importance. Here, we developed a workflow for prediction of immunosuppressive therapy response prediction in OLP, which could automatically acquire image-based features. First, 38 features were acquired from 208 OLP pathological images, and 6 features were subsequently obtained which had a significant impact on the effect of OLP immunosuppressive therapy. By observing microscopic structure and integrated with the corresponding transcriptome, the biological implications of the 6 features were uncovered. Though the pathway enrichment analysis, three image-based features which advantageous to therapy indicated the different lymphocytes infiltration, and the other three image-based features which bad for therapy respectively indicated the nicotinamide adenine dinucleotide (NADH) metabolic pathway, response to potassium ion pathway and adenosine monophosphate (AMP) activated protein kinase pathway. In addition, prediction models for the response to immunosuppressive therapy, were constructed with above image-based features. The best performance prediction model built by logistic regression showed an accuracy of 90% and the area under the receiver operating characteristic curve (AUROC) reached 0.947. This study provided a novel approach to automatically obtain biological meaningful image-based features from unannotated pathological images, which could indicate the immunosuppressive therapy in OLP. Besides, the novel and accurate prediction model may be useful for the OLP clinical management.

Keywords: oral lichen planus, immunosuppressive therapy, image-based feature, prediction, oral mucosa

INTRODUCTION

Oral lichen planus (OLP) is a common chronic inflammatory disease of the oral mucosa with a prevalence of 0.5% to 2.0% in the general population (1). OLP mainly affects the middle-aged population (50–60 years old), more commonly women (2). OLP can manifest clinically as reticular, popular, plaquelike, erosive, atrophic, and bullous subtypes (3). Oral lesions in the form of atrophic erosions of OLP can cause symptoms ranging from a burning sensation to severe pain that interferes with speech, eating and swallowing (4). It has been known that T cell-mediated cytotoxicity is involved in pathogenesis of OLP (5). Therefore, immunosuppression is commonly used to treat OLP (6, 7). However, not all patients show positive response to immunosuppressive therapy. The commonly used therapeutic agents are corticosteroids, calcineurin inhibitors, which mainly work by inhibiting immunity and inhibiting lymphocytes (8). Pathological images can reveal many immune-related changes. With the help of pathological images, we can discover the factors that affect the treatment effect.

With the recent advent of cost-effective digital scanners for full slides, tissue slides can be digitized and stored as digital images (9). Digital pathology has made the computerized quantitative analysis of histopathological images possible. Deep learning (DL) is increasingly being used in medical images, including diagnosing and grading tumors (10–12), prognosis and prediction of metastasis (13, 14). However, deep learning requires a large amount of annotated data for training (15), including pixel-level annotated datasets and labeled datasets. These deep learning practices have met with varying degrees of success, and Google has also announced the development of microscopes based on deep learning algorithms to assist pathologists in diagnosis (16). These deep learning practices have better performance in the field of pathological images and can achieve an accuracy up to 97.51% in the classification of tumor differentiation grade (17).

However, due to the uninterpretability of DL algorithms, the opacity of artificial intelligence (AI) decisions is one of the most significant challenges to their regulatory approval and clinical implementation (18). Despite of the high accuracy rates that can be achieved by algorithms, their credibility is still questionable for practical clinical applications. Especially in oncology issues, the adoption of unexplained AI systems may raise severe legal and ethical challenges, including regulatory difficulties and confusion over the allocation of responsibilities (19). In addition, although deep learning algorithms can be trained to explore features that are difficult for pathologists to find, we do not know exactly what these features are. Therefore, it is risky to make clinical decision just rely on deep learning algorithms (20).

Autoencoder is an unsupervised feature extraction method (21). This method can be used for dimensionality reduction representation of high-dimensional images (22, 23). Generally, autoencoders can be considered as neural network models with a multilayer structure, consisting of two parts: encoding and decoding. The encoder encodes the input image data, while the decoder decodes the expressions in the hidden layer to reconstruct the input data. Thus, the data in the hidden layer

contains the core information of an image (24). By clustering the hidden layer data of a large number of images can discover potential correlations between images (25). We can group images with similar features into one class by compressing and clustering the image information. If most of the images within a feature are from patients who achieve great clinical efficacy with immunosuppressive treatment, it means that the feature may be relevant to immunosuppressive treatment.

Based on the above issues, we developed a method to obtain interpretable knowledge from unlabeled pathological images and applied our method to obtain features that have positive/negative effects on the immunosuppressive treatment of OLP. Further, we determined the significance of these features by analyzing the biological phenotype and RNA-seq of these features. Finally, we constructed a model to predict the efficacy of immunosuppressive treatment for OLP. The pathological features identified in our study may be informative for clinical treatment.

MATERIALS AND METHODS

Study Participants

This hospital-based cohort consisted of OLP patients who attended the mucosal unit at West China Dental Hospital, Sichuan University from September 2019 to September 2021. Participants all signed written consent to participate in the study. The study was approved by the Ethics Committee of West China Dental Hospital of Sichuan University (WCHSIRB-D-2017-021).

Patients attending the study were screened for inclusion criteria. The detailed criteria are shown in **Table 1**.

The total number of participants who met the criteria was 56. Immunosuppressive treatments were applied for these participants, including oral hydroxychloroquine sulfate tablets and dexamethasone sodium phosphate injection. We collected complete pathological sections and clinical data from all patients for analysis. The scores were according to the presence of three types of white reticulations/patches, erythema/congestion, and erosions/ulcers. In the 11 parts of the mouth: upper lip, lower lip, left cheek, right cheek, maxillary gum, mandibular gum, left tongue, right tongue, floor of the mouth, hard palate, and soft palate, the score was 0 if it was not present, 1 if it was present but not more than 50% of the area of the part, and 2 if it was more than 50%. The total score was finally calculated. The calculation was weighted 1.5 times for the erythema/congestion score and 2 times for the erosion/ulcer score. We followed up the patient three times, and if the score at the third time was more than 10% lower than the first time, the patient was considered effective for immunosuppressive treatment. Among them, 19 patients were ineffective with immunosuppressive treatment and 37 were effective.

Preparation of Whole-Mount Pathology Images and RNA Sequencing

The tissue sample from patients would be divided into two halves, one for pathology section preparation and the other for RNA-seq. Understanding the gene expression of the

TABLE 1 | The include exclusion criteria.

Inclusion criteria

Signed informed consent.

Age 18-65 years old, Han nationality.

Clinically:

1. There are bilateral lesions with a certain degree of symmetry.

2. There is a lace-like reticulation (reticular type) composed of gray-white lines slightly above the mucosal surface.

3. It can be manifested as erosive, atrophic, bullous and plaque-type lesions, but there must be a reticular type in other parts of the oral mucosa.

Pathologically:

1. Confined to the surface of the connective tissue, a well-defined band-like cell infiltration area, mainly lymphocytes.

2. Basal cell liquefaction degeneration.

3. No epithelial dysplasia.

Exclusion criteria

Pregnant women, lactating women, women of childbearing age who plan to become pregnant within 1 year.

Patients with obvious other oral mucosal diseases or severe periodontitis (periodontal pocket>6mm, attachment loss>5mm, alveolar bone resorption more than 1/2 of the root length)

Patients with major infectious diseases (such as AIDS, syphilis, etc.), or other precancerous lesions or tumors.

Patients with a history of immune system disorders (e.g., systemic lupus erythematosus, rheumatoid arthritis, scleroderma, hyperthyroidism, ulcerative colitis, etc.).

Patients who have received immunotherapy within 3 months.

Abnormal liver function: (ALT elevation greater than 1.5 times the upper limit of normal); renal dysfunction (creatinine and/or blood urea nitrogen or urea elevation greater than 1.5 times the upper limit of normal); hemolytic anemia, thrombocytopenia ($PLT < 60 \times 10^9/L$), white blood cells $< 3 \times 10^9/L$, neutrophils $< 1.5 \times 10^9/L$; central or peripheral nervous system involvement.

Patients with abnormal ophthalmic examinations (including visual acuity, slit lamp examination, ophthalmoscopy, and visual field examination).

Glaucoma and cataract patients.

Those who are allergic to the ingredients of hydroxychloroquine sulfate tablets.

The lesioned mucosa corresponds to those filled with amalgam in the tooth.

Other factors for which the investigator considered subjects unsuitable for participation in this study.

corresponding pathological image is essential to interpreting the functional components of the genome, and revealing the molecular composition of cells and tissues, as well as understanding development and disease. RNA-seq can be used to study the transcriptome (26). The transcriptome is the complete set of transcripts and their number in cells at specific developmental stages or physiological conditions. Understanding the transcriptome is essential for interpreting the functional components of the genome and revealing the molecular composition of cells and tissues, as well as for understanding development and disease. In this study, tissues from 19 patients were sent for RNA-seq to interpret the biological implications of the image-based features.

Preprocessing of Data Set

We divided the 168 whole slide images (WSIs) from 56 patients into the following two groups: 38 WSIs from 38 patients (the images with the largest number of pixels selected for each patient) were used to generate key features using the deep neural network, and the other 130 WSIs were used to validate the prediction model by using these features. We did not provide any information about the patients to the deep neural network during the training process. In addition, the pathologists did not examine or annotate the pathology images. For training and feature extraction of 38 patients, the number of patients with good and poor results for immunosuppressive treatment was the same (n=19).

In this study, we used Python's Openslide (version 1.1.2) to perform the segmentation process on WSIs. The parameters we choose are a magnification of 50x and a patch size of 128*128. We cut the WSIs without gaps into patches of 128*128 pixels

size. 38 WSIs from 38 patients were segmented into the original patches set. During the production of pathology sections and electronic scans, some images showed contamination and distortion, so we performed an additional filtering step on the original patches set. Based on the characteristics of our dataset, our filtering criteria included: a. Blank area $\geq 75\%$ (too little valid content); b. Average brightness of all pixels in the image < 120 or > 250 (image too dark/too bright); c. Variance of RGB values of all pixels in the image < 80 (image with contamination); d. Width or height less than 128 pixels (image at the edge of the slice). After the above screening, patches that are not suitable for training and feature extraction are removed, while the normal patches were reserved.

Autoencoder

Autoencoder consists of two main parts: encoder and decoder. The encoder compresses the input data to obtain low-dimensional data containing key information of the original data (22). The decoder can decode these obtained data and restore them to the original data through the decoding process. The training process consists of three main steps. In the first step, the encoder encodes the unlabeled data samples and obtains the encoding code. In the second step, the decoder decodes the encoded codes and obtains the new data. In the third step, we calculate the information error between these new data and the original data, and then adjust the weight parameters of the encoder and decoder according to the error to minimize the reconstruction error (27). For our encoder, it is possible to downscale an image with 128*128 pixels and three-channel values (RGB values) into a vector of 2048 numbers. The method we used does not require manual annotation or

labeling to pre-classify the image. The entire training process is unsupervised, and Step1 of **Figure 1** provides a flowchart for training the autoencoder network.

Image-Based Feature Generation Method

We used a set of filtered patches ($n=122,705$) to train the autoencoder. A total of 50 epochs were trained, and the vectors in the middle layer were clustered using K-means clustering methods. Clustering includes several machine learning algorithms that attempt to identify similar data instances and group them together (28). Algorithms such as K-means try to group the data around a point (called the center of mass), while other algorithms try to find clusters hierarchically. In total, 38 features (clusters) were generated.

At this point, each patch is assigned a label, and if the treatment effect of the WSI corresponding to the patient is good, then the patch is defined as positive. Otherwise, it is defined as negative. Next, we find the centroids of each feature in the k-means generation process. The scores $u_{i,j,k}$ are calculated based on the distances $d_{i,j,k}$ (the distance from the j th patch of the i th patient to the k th feature) between this vector and each centroid, which we define using the following simple method (25):

$$u_{i,j,k} = 1 \text{ if } \operatorname{argmin} d_{i,j,k} \text{ and } 0 \text{ otherwise} \quad (1)$$

$$(k = 1, 2, 3, \dots, 38)$$

The positive and negative degrees of each feature are defined as follows, $+u_{i,j,k}$ and $-u_{i,j,k}$ refers to the number of positive and negative patches in the feature, n_+ and n_- . The number of positive and negative patches among all the patches involved in clustering.

$$r_{+,k} = \frac{\sum +u_{i,j,k}}{n_+} \quad (k = 1, 2, 3, \dots, 38) \quad (2)$$

$$r_{-,k} = \frac{\sum -u_{i,j,k}}{n_-} \quad (k = 1, 2, 3, \dots, 38) \quad (3)$$

Finally, we define the impact score I_k of the k th feature as:

$$I_k = \frac{r_{+,k}}{r_{+,k} + r_{-,k}} \quad (4)$$

The value of I_k ranges from 0 to 1, and the contribution of different features to the prediction results varies when constructing the prediction model. We define the weight of the k th feature as

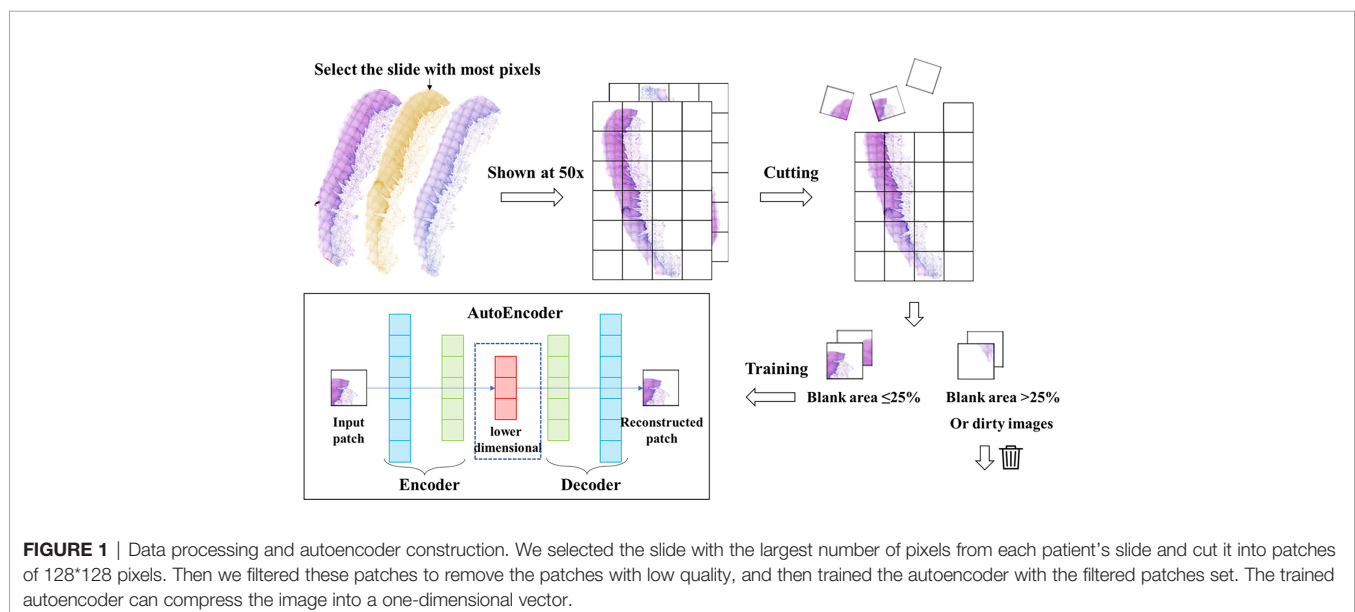
$$W_k = 1 + |0.5 - I_k| \quad (5)$$

At the end of clustering, we identify the biological phenotypes of all features and filter out the features that contribute significantly to the treatment effect, called key features.

Construction of Predictive Models

The clustering is performed by K-means to obtain 38 clustering results, each with a centroid K_1, \dots, K_{38} . After the input of the slide to be predicted, we cut and filter it (in “key feature generation method”) to obtain the patches set. The trained encoder encodes the patches into a vector X_i and calculates the Euclidean distance from the vector to the centroid of each cluster. The cluster with the smallest distance is the class of the patches.

We mainly used two methods, logistic regression and SVM, to build prediction models to evaluate the value of using 38 features to predict the treatment effect. SVM is a powerful method to build classifiers. It aims to create a decision boundary between two categories so that labels can be predicted from one or more feature vectors (29). This decision boundary is called the hyperplane, and it is oriented as far as possible from the nearest data points in each class. These closest points are called support vectors.



To evaluate our method, we used 38 features generated by deep learning to predict cancer recurrence. To address the fact that feature values are unevenly distributed between patients with and without cancer recurrence, we multiplied each feature value by W_k (see the Methods section for key feature generation methods), which enhanced the predictive power of the model (25). Due to the small sample size used for validation, we adopted 10-fold cross validation. A data set is first randomly divided into 10 disjoint folds that have approximately the same number of instances. Then every fold in turn plays the role for testing the model induced from the other 9 folds. Since the partition is random, the variance of the accuracy estimates can be large for statistical inference (30). We use Receiver Operating Characteristic (ROC) and accuracy to compare models generated by deep learning (31). The area under the receiver operating characteristic (AUROC) curves is the most commonly used metric for comparing classifier performance and takes values from 0 to 1. The higher the AUC, the better the performance of model (32).

Pathway Enrichment Analysis

Using the median number of generated key feature k present in all pathology sections of the training set as the session, all pathology sections of the training set were divided into feature k high expression and low expression groups. We performed gene set variation analysis (GSVA) using raw counts to identify signaling pathways and functions that were significantly enriched using in each group. The input for the GSVA algorithm is a gene expression matrix in the form of RNA-seq counts and a database of gene sets. The output of the algorithm is a matrix containing pathway enrichment scores for each gene set and sample (33).

Statistical Analysis

We used Python (version 3.8) for data processing and model training, OpenSlide package (version 1.1.2) and OpenCV-Python package (version 4.3.0.36) for processing and cutting of WSIs, and TensorFlow (version 2.3.0), NumPy (version 1.18.4) and PIL (version 8.2.0) for training of deep autoencoders and processing of intermediate layers. NumPy (version 1.18.4) and PIL (version 8.2.0). The clustering and pathway analysis of the intermediate layer data were performed by using R, including e1071 (version 1.7.0), GSVA (version 1.20.0). All packages are available. All tests were two-tailed and considered statistically significant if the p -value < 0.05.

RESULT

Deep Autoencoder

We developed a method for automatic feature generation based on autoencoders. This method used an unsupervised neural network. No direct information about the cancer was provided to the deep neural network. The encoder can downscale an image of 128*128 pixels into a vector containing 2048 numbers. The workflow of data processing and auto-encoder was shown in **Figure 1**. The decoder can recover the vector into an image. The

recovered image is basically the same as the original image. We used the encoder to encode 122,705 patches of the filtered patches set into a vector set

Clustering Workflow and Features Analysis

The vector set was clustered by K-means method. A total of 38 clusters were generated, which we called features. We calculated the I_k value of each feature and evaluated the role of each feature in the effect of immunosuppressive therapy. The features were classified into positive and negative features based on the proportion of positive patches. There were 25 positive features and 13 negative features in total. Then we observed and analyzed the patches in each feature. The clustering and analysis process is shown in **Figure 2**.

Generation of Key Feature

We evaluated patches of 38 features by 3 experts, and the characteristics of all features were showed in **Table 2**. Overall, these features were divided into two classes *via* image shape-based classification and tissue morphology-based classification. Consequently, 13 features were clustered by shape and 25 features were clustered by histology.

We calculated the I_k value of each feature. When I_k is equal to 0.5, it means that the feature contains the same number of positive and negative patches, indicating no special effect on the treatment effect. If the value is greater than 0.5, the presence of the feature is considered as positive for treatment and is called positive feature; if the value is less than 0.5, the feature is considered as negative feature. We assigned all center points to different shades of color according to the value of I_k (**Figure 3A**). The darker the color is, the more importance the feature means. **Figure 3B** shows the histological morphology of the features. The features of muscle and connective tissue were distributed in the same area. Features clustered by shape were distributed around. Epithelial and lymphocyte-dominated features' centers were also close to each other.

Figure 4A showed the weight W_k of each feature. Among the 8 features exceeding 1.1, two features were classified by shape, so the remaining 6 features were defined as key features. In addition, we found that the features dominated by connective tissue and muscle tissue, whose W_k were almost all less than 1.1, meant that the structure of muscle and connective tissue was of little significance for Immunosuppressive therapy.

Histological Appearance of Key Features

Three of the six key features were positive and three were negative. The morphology of the features was shown in **Figure 4**. Two of the positive features (**Figure 4B**) were both mainly lymphocyte-infiltrated lamina propria, which also contained a small amount of basal cell layer and spiny layer (**Figures 4Ba, b**). The other positive feature containing mainly lymphocytes and epithelium. (**Figure 4Bc**). Of the negative features (**Figure 4C**), one feature mainly contained patches with the presence of blood vessels (**Figure 4Cd**); one feature was loose connective tissue (**Figure 4Ce**); and one feature was the lamina propria, which contained part of the epithelial layer but did not include lymphocyte-rich areas (**Figure 4Cf**).

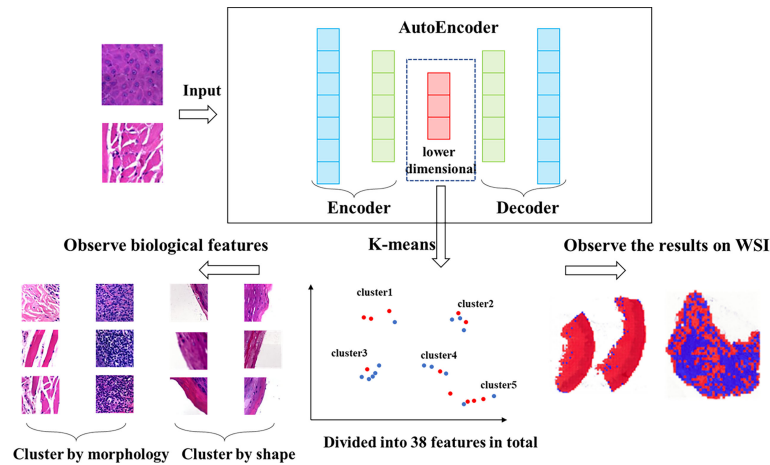


FIGURE 2 | Workflow of clustering. We clustered the data, which was encoded by autoencoder, obtained 38 features via K-means method. The higher the proportion of positive patches contained in feature, the greater the positive significance of the effect of immunosuppressive treatment. The higher the proportion of negative patches, the greater the negative significance of the treatment effect.

TABLE 2 | 38 features and their patch numbers, histological morphology.

features	lk	size	histological morphology
33	0.792793	1407	lymphocyte infiltration
15	0.652546	1348	lymphocyte infiltration and epithelium
9	0.626349	1542	epithelium and a little lymphocyte infiltration
35	0.588725	213	shape
10	0.57435	2209	muscle and connective tissue
23	0.570966	264	shape
19	0.568363	613	muscle and connective tissue
38	0.568304	694	muscle and connective tissue
26	0.565786	1605	muscle and light-colored connective tissue
1	0.563333	165	shape
18	0.55593	614	muscle and connective tissue
24	0.551183	369	shape
32	0.549619	169	shape
28	0.544116	706	shape
29	0.541248	1078	basal layer (excluding lymphocyte-rich areas)
16	0.53363	238	shape
36	0.528598	813	muscle and loose connective tissue
22	0.526346	1078	light-colored
37	0.524113	1783	muscle and loose connective tissue
5	0.517068	791	muscle and keratinized tissue
6	0.514626	165	keratinized layer
11	0.513952	2218	muscle and connective tissue
14	0.513298	1715	spinous and granular layers
8	0.507854	780	Muscle, adipose and connective tissue
25	0.503648	705	muscle and connective tissue
20	0.496371	719	muscle and connective tissue
3	0.491524	954	Muscle, adipose and connective tissue
12	0.464026	621	muscle and connective tissue
7	0.448971	156	shape
4	0.446255	1748	Muscle, adipose and connective tissue
34	0.430969	221	shape
13	0.429933	217	shape
21	0.416876	212	shape
17	0.364027	149	shape
31	0.361109	177	shape
2	0.299376	1938	areas containing blood vessels
27	0.241073	2144	loose connective tissue
30	0.237406	1289	epithelium and lamina propria (excluding lymphocyte-rich areas)

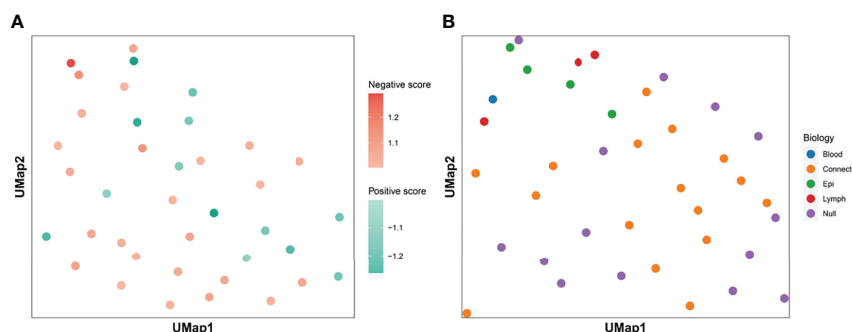


FIGURE 3 | Clustering centroids. We showed the centroids of the 38 features. Panel (A) shows the effect of all features on the treatment effect. Darker red means that the feature has a greater significance of having a positive effect on immunosuppressive treatment. The darker the blue color, the greater the significance that the feature plays a negative role. Panel (B) shows the biological significance of all the features. The features dominated by muscle and connective tissue are distributed in the same area. Features which were clustered by shape were distributed in the periphery. The centers of epithelial and lymphocyte-dominated features were also close to each other.

Key Features and Pathway Enrichment Analysis

We used GSVA to determine the signaling pathways and functions, which were shown in **Figure 5**. Feature 30 was concentrated in the epithelium and lamina propria, and in the

feature 30 high expression group, the kinase related pathway was enriched, and kinase expression was elevated. Kinases play important roles in current inflammatory and autoimmune diseases (34). Kinases can transduce signals from many cytokine receptors, inhibiting the effects of immunosuppressive

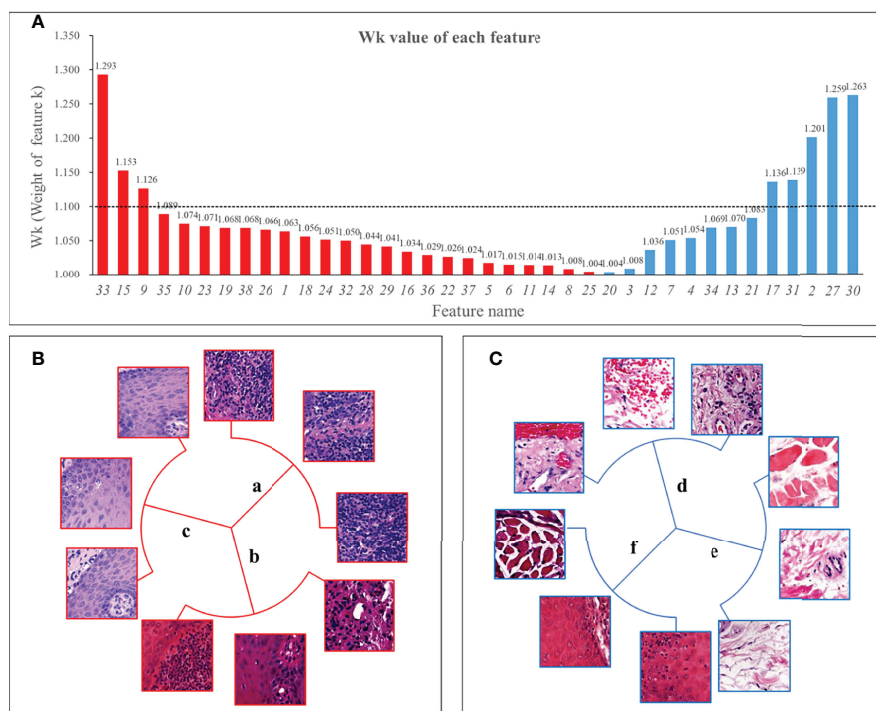


FIGURE 4 | W_k (Weight of feature k) of all features and 6 key features. Panel (A) showed the W_k values of all features with the vertical axis taking the value of 1 to 1.35. The higher the value, the greater the impact on immunosuppressive treatment's efficacy. We used 1.1 as the threshold and defined features with W_k higher than 1.1 as key features. Panel (B) shows 3 positive features, 2 of which were mainly lymphocyte-infiltrated lamina propria and additionally contain a small amount of basal cell layer and spiny layer (B.a, B.b). There was also a positive feature containing mainly the epithelial layer and, in addition, an infiltration of lymphocytes (B.c). Among the negative features, one feature contained patches with the blood vessels (C.d); one feature was loose connective tissue (C.e); and one feature was the lamina propria, which contained part of the epithelial layer but not lymphocyte-rich areas (C.f).

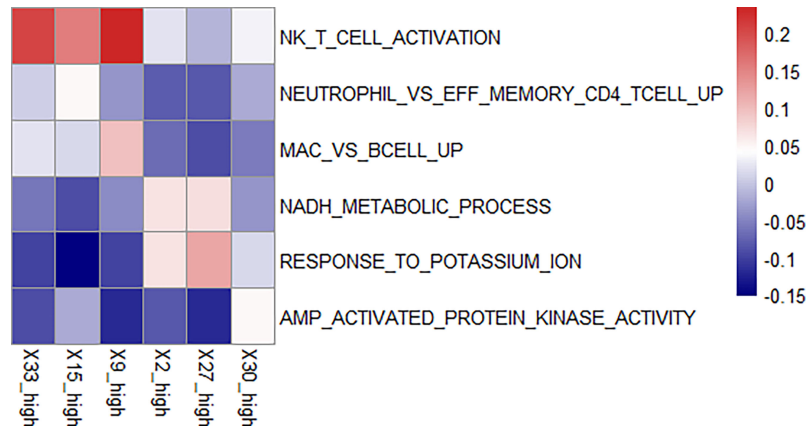


FIGURE 5 | Enriched pathways in each feature. We found enriched pathways in the high expression group of each feature. Features 33, 15, and 9 all had lymphocyte-enriched pathways, but the types of lymphocyte were different, which may explain the lymphocyte infiltration group was divided into three features. Because of the enrichment of immune cells, immunosuppressive therapy has a good effect on the group with high expression of these three features. The biological phenotype of feature 2 was associated with the morphology of blood vessels, and the enrichment of NADH biochemical metabolic pathways was seen in the group with high expression. Feature 27 was associated with loose connective tissue, and its high expression group was enriched for the pathway of potassium ion overexpression. Feature 30 was enriched for kinase-related pathways in the high expression group. The presence of these three features has a suppressive effect on immunosuppressive treatment.

treatments. Feature 27 contains the loose connective tissue. In the feature 27 high expression group, we found an enrichment in the potassium ion expression pathway. High levels of potassium maintain the “stem cell properties” of anti-cancer T cells, which have the ability to replicate themselves, but they cannot “grow” into killer immune cells (35). By keeping the T cells in this state, the tumor can avoid being attacked and continue to grow (36). Therefore, immunosuppressive therapy is ineffective when this pathway is highly expressed. In the characteristic 2 high expression group, the nicotinamide adenine dinucleotide (NADH) related pathway was enriched. The effect of immunosuppression may be reduced due to altered metabolism (37).

There was an enrichment of lymphocyte-related pathways in the three positive features. Feature 33 high expression group had enrichment of Natural killer T (NKT) cell, feature 15 high expression group had enrichment of neutrophil and T cell related pathway, and feature 9 high expression group had enrichment of B cell related pathway. The enrichment of immune cells resulted in increased efficacy of immunosuppressive treatment.

Differential Pathway Enrichments of High and Low Expression Groups

The difference of pathway enrichment was significant in high and low expression groups, for all key features (all *P* value less than 0.05). The result was shown in **Figure 6**. This implied that the key features we identified had a significant correlation between their histological manifestations and pathway enrichment.

Predictive Models

We calculated the accuracy of the logistics regression models using the ten-fold validation method. The average model accuracy was 68.53%, with a maximum accuracy of 92.31%

and a minimum accuracy of 38.46%. the average AUC reached 0.722 (95% CI: 0.697-0.747).

We also compared the performance of SVMs. The average accuracy of the SVM model with 38 features was 76.68%, with the highest accuracy reaching 100% and the lowest 50%. the average AUC was 0.645 (95% CI: 0.637-0.652). the accuracy of the SVM was higher than the logistics regression overall, but the AUC value was lower because the results were categorical variables.

For the ten-fold validation, we obtained different models. We tested the entire validation set using the best performing model, and the Logistic regression model achieved an accuracy of 90% with an AUC of 0.947. the SVM model had an accuracy of 88.46% with an AUC of 0.786. as shown in **Figure 7B**.

Based on the logistic regression model, we constructed a visual prediction system that could display the feature to which each patch belongs and the W_k value of that feature, as shown in **Figure 7A**.

DISCUSSION

Our study implemented unsupervised learning from unlabeled pathological images, and we clustered and obtained features that can be interpreted. These features indicated the effect of OLP immunosuppression therapy. The size of the patch we used was sufficient for observed the content of patches. In addition to the features clustered by shape, each feature contained more than 500 patches, which makes it easy to summarize characteristics of the features. The key features contained histological features that were understandable to humans, which facilitates the selection of treatment regimens and the prediction of treatment effects. Features extracted by deep neural networks included not only human-identified findings, but also contain features that have

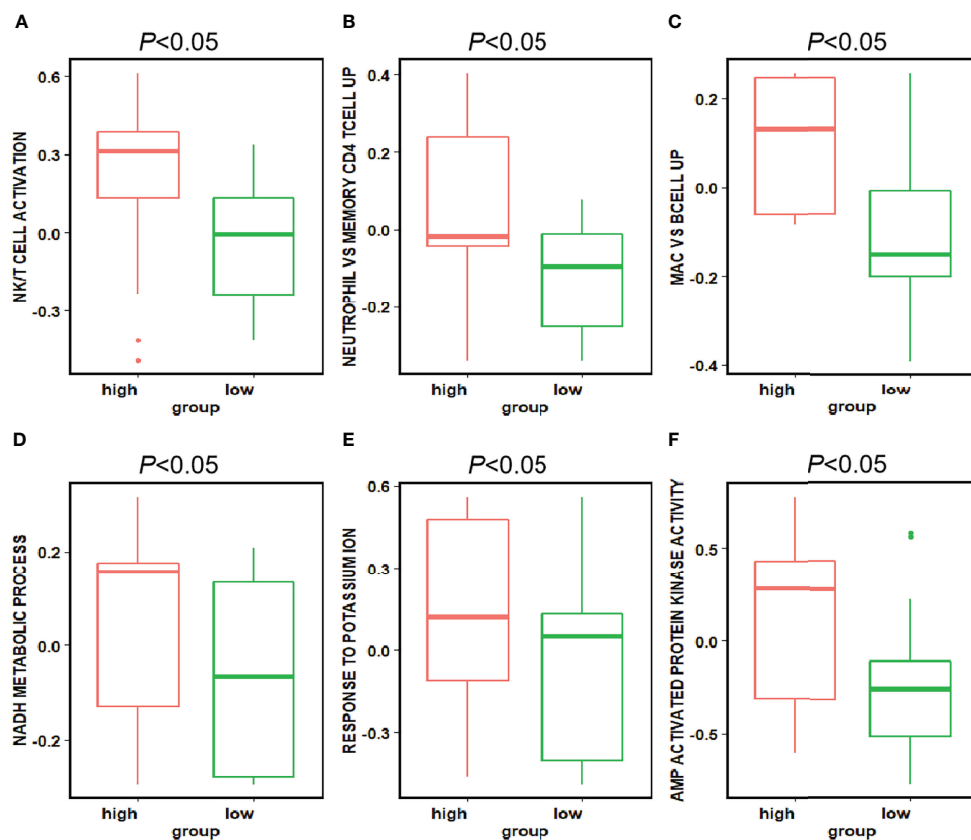


FIGURE 6 | Differences in the pathways corresponding to the high and low expression groups of each feature. Panels (A–F) showed the differences in expression in the high and low expression groups of each feature in Figure 5 for the pathways enriched in the high and low expression groups of that feature, respectively. The P -value for the differences in pathway enrichment in the high and low expression groups for each feature is less than 0.05.

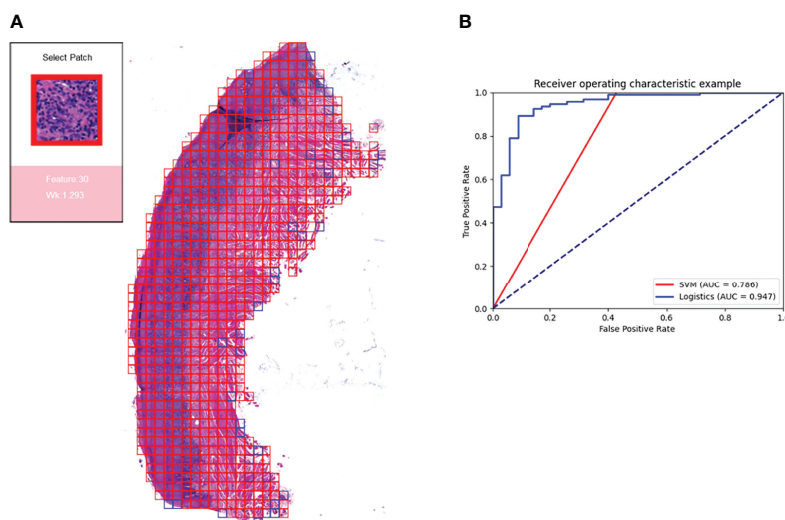


FIGURE 7 | Prediction model and visualization results. We developed a model to predict the efficacy of immunosuppressive treatment based on a logistic regression model. Panel (A) shows the visualization of the prediction results. The patches belonging to positive features were added with red border, and those belonging to negative features are added with blue border. The box on the right shows the magnified morphology of the patch, the feature to which the patch belongs, and the W_k value of the category. Panel (B) shows the ROC curves for the SVM model and the logistic regression model. Logistic regression has a higher AUC of 0.947.

not been noticed or discovered. Convolutional Neural Networks (CNNs) have been found to derive information from features that are undetectable by humans, such as determining patient age from X images of paranasal sinuses (38), predicting protein function from amino acid sequences (39).

The number of clusters was 38, which was exactly the number of WSIs as trained set. It could be a good solution for features extracted (25). A total of 38 histological features were obtained, these features can be classified into two main classes: one is classified by morphology. The patches of these features have common characteristics: they all contain blank areas, and the shape of the non-blank areas is uniform, rectangular, or triangular. The number of patches of these features is small, mostly less than 500, so they have little effect on the prediction results. The other is classified by histology. In this class, there were many features with muscle and connective tissue, and their W_k were all in the range of 1 to 1.1, implying that such features had little effect on the treatment outcome. There were three key positive features, all of them contained lymphocyte-infiltrated lamina propria. Three negative features for treatment were blood vessels, loose connective tissue, and epithelial tissue separately. By analyzing the expression of relevant pathways, we confirmed the relationship between above features and their biological phenotype.

In this study, key features identified by deep neural network could be reasonable. We demonstrated a well-performing algorithm based on deep autoencoders (22) and with no need for manual labels information. In addition, our research has identified some of the features relevant to immunosuppressive therapy, and our findings were confirmed by pathway analysis. We also constructed a model to predict the effect of OLP immunosuppression treatment based on 38 features, and the logistics regression model achieved an accuracy of 90% with an AUC of 0.947. The model constructed based on our theory has a high accuracy for the prediction of treatment effect. However, the parameters we selected in the deep learning model were manually determined, which may not be the best choice. Changing the parameters or clustering methods may reveal more features. The prediction models we chose were the classic SVM and logistic regression. In future research, we will try to explore more potential models in prediction of diseases, such as neuralnet (40), and improve this tool to play a greater role in clinical diagnosis and treatment.

CONCLUSION

OLP is a common disease of the oral mucosa. Immunosuppressive therapy is commonly used clinically, but patients have different response to treatment. There is a lack of in-depth clinical research on the reasons for the differences in efficacy. We obtained 38 features by training autoencoders to slice and data downscaling and clustering of pathology images. Through our analysis of biological phenotypes and pathways, we obtained 6 features that have a significant impact on efficacy. We also built a model to

predict the efficacy of OLP immunosuppressive treatment based on these features. We did more than simply using WSI for classification and outcome prediction. More importantly, we acquired knowledge that can be interpreted and learned. This may be instructive for future research. Our study automatically obtains human interpretable features from pathological images, which could be an important reference for the clinical immunosuppressive treatment of OLP.

DATA AVAILABILITY STATEMENT

The datasets presented in this study can be found in online repositories. The names of the repository/repositories and accession number(s) can be found below: NCBI GEO, accession no: GSE204663.

ETHICS STATEMENT

The studies involving human participants were reviewed and approved by Ethics Committee of West China Dental Hospital of Sichuan University. The patients/participants provided their written informed consent to participate in this study.

AUTHOR CONTRIBUTIONS

HX, QC, ZX, and QH contributed to conception and design of the study. QH and QC organized the database. ZX, DY, and JL performed the statistical analysis. ZX and QH wrote the first draft of the manuscript. QH, DY, QS, JL, and WL wrote sections of the manuscript. All authors contributed to manuscript revision, read, and approved the submitted version.

FUNDING

This study was supported by grants from the National Natural Science Foundation of China (81730030) and Research funding for talents developing, West China Hospital of Stomatology, Sichuan University (RCDWJS2020-22).

ACKNOWLEDGMENTS

The authors would like to thank the oral pathology department of West China School of Stomatology, where all slide crafting and diagnostic tasks were completed.

REFERENCES

- Dusek JJ, Frick WG. Lichen Planus: Oral Manifestations and Suggested Treatments. *J Oral Maxillofac Surg* (1982) 40(4):240–4. doi: 10.1016/0278-2391(82)90321-4
- Eisen D, Carrozzo M, Bagan Sebastian JV, Thongprasom K, Number V. Oral Lichen Planus: Clinical Features and Management. *Oral Disease* (2005) 11(6):338–49. doi: 10.1111/j.1601-0825.2005.01142.x
- Scully C, Carrozzo M. Oral Mucosal Disease: Lichen Planus. *Br J Oral Maxillofac Surg* (2008) 46(1):15–21. doi: 10.1016/j.bjoms.2007.07.199
- Eisen D. The Clinical Features, Malignant Potential, and Systemic Associations of Oral Lichen Planus: A Study of 723 Patients. *J Am Acad Dermatol* (2002) 46(2):207–14. doi: 10.1067/mjd.2002.120452
- Lodi G, Scully C, Carrozzo M, Griffiths M, Sugerman PB, Thongprasom K. Current Controversies in Oral Lichen Planus: Report of an International Consensus Meeting. Part 1. Viral Infections and Etiopathogenesis. *Oral Surg Oral Med Oral Pathol Oral Radiol Endodontology* (2005) 100(1):40–51. doi: 10.1016/j.tripleo.2004.06.077
- Chamani G, Rad M, Zarei MR, Lotfi S, Sadeghi M, Ahmadi Z. Efficacy of Tacrolimus and Clobetasol in the Treatment of Oral Lichen Planus: A Systematic Review and Meta-Analysis. *Int J Dermatol* (2015) 54(9):996–1004. doi: 10.1111/ijd.12925
- Georgaki M, Piperi E, Theofilou VI, Pettas E, Stoufi E, Nikitakis NG. A Randomized Clinical Trial of Topical Dexamethasone vs. *Cyclosporin* Treat Oral Lich Plan Med Oral Patol Oral Y Cirugia Bucal (2022) 27(2):e113. doi: 10.4317/medoral.25040
- Lavanya N, Jayanthi P, Rao UK, Ranganathan K. Oral Lichen Planus: An Update on Pathogenesis and Treatment. *J Oral Maxillofac Pathol: JOMFP* (2011) 15(2):127. doi: 10.4103/0973-029X.84474
- Gurcan MN, Boucheron LE, Can A, Madabhushi A, Rajpoot NM, Yener B. Histopathological Image Analysis: A Review. *IEEE Rev Biomed Engin* (2009) 2:147–71. doi: 10.1109/RBME.2009.2034865
- Levine AB, Schlosser C, Grewal J, Coope R, Jones SJ, Yip S. Rise of the Machines: Advances in Deep Learning for Cancer Diagnosis. *Trends Canc* (2019) 5(3):157–69. doi: 10.1016/j.trecan.2019.02.002
- Ardila D, Kiraly AP, Bharadwaj S, Choi B, Reicher JJ, Peng L, et al. End-To-End Lung Cancer Screening With Three-Dimensional Deep Learning on Low-Dose Chest Computed Tomography. *Nat Med* (2019) 25(6):954–61. doi: 10.1038/s41591-019-0447-x
- Asuntha A, Srinivasan A. Deep Learning for Lung Cancer Detection and Classification. *Multimed Tools App* (2020) 79(11):7731–62. doi: 10.1007/s11042-019-08394-3
- Bychkov D, Linder N, Turkki R, Nordling S, Kovanen PE, Verrill C, et al. Deep Learning Based Tissue Analysis Predicts Outcome in Colorectal Cancer. *Sci Rep* (2018) 8(1):1–11. doi: 10.1038/s41598-018-21758-3
- Bejnordi BE, Veta M, Van Diest PJ, Van Ginneken B, Karssemeijer N, Litjens G, et al. Diagnostic Assessment of Deep Learning Algorithms for Detection of Lymph Node Metastases in Women With Breast Cancer. *Jama* (2017) 318(22):2199–210. doi: 10.1001/jama.2017.14580
- Cho J, Lee K, Shin E, Choy G, Do S. How Much Data Is Needed to Train a Medical Image Deep Learning System to Achieve Necessary High Accuracy? (2015). Available at: <https://arxiv.org/abs/1511.06348> (Accessed April 2, 2022).
- Chen P-HC, Gadepalli K, MacDonald R, Liu Y, Kadowaki S, Nagpal K, et al. An Augmented Reality Microscope With Real-Time Artificial Intelligence Integration for Cancer Diagnosis. *Nat Med* (2019) 25(9):1453–7. doi: 10.1038/s41591-019-0539-7
- Das N, Hussain E, Mahanta LB. Automated Classification of Cells Into Multiple Classes in Epithelial Tissue of Oral Squamous Cell Carcinoma Using Transfer Learning and Convolutional Neural Network. *Neural Net* (2020) 128:47–60. doi: 10.1016/j.neunet.2020.05.003
- Price I, Nicholson W. *Artificial Intelligence in Health Care: Applications and Legal Issues*. (2017). Available at: <https://repository.law.umich.edu/articles/1932/>. (Accessed April 2, 2022).
- Lang M, Bernier A, Knoppers BM. AI in Cardiovascular Imaging: “Unexplainable” Legal and Ethical Challenges? *Can J Cardiol* (2022) 38(2):225–33. doi: 10.1016/j.cjca.2021.10.009
- Grote T, Berens P. On the Ethics of Algorithmic Decision-Making in Healthcare. *J Med Ethic* (2020) 46(3):205–11. doi: 10.1136/medethics-2019-105586
- Shimobaba T, Endo Y, Hirayama R, Nagahama Y, Takahashi T, Nishitsuji T, et al. Autoencoder-Based Holographic Image Restoration. *Appl Optic* (2017) 56(13):F27–30. doi: 10.1364/AO.56.000F27
- Hinton GE, Salakhutdinov RR. Reducing the Dimensionality of Data With Neural Networks. *Science* (2006) 313(5786):504–7. doi: 10.1126/science.1127647
- Bengio Y, Courville A, Vincent P. Representation Learning: A Review and New Perspectives. *IEEE Trans Pattern Anal Mach Intell* (2013) 35(8):1798–828. doi: 10.1109/TPAMI.2013.50
- Hou L, Nguyen V, Kanevsky AB, Samaras D, Kurc TM, Zhao T, et al. Sparse Autoencoder for Unsupervised Nucleus Detection and Representation in Histopathology Images. *Pattern Recognit* (2019) 86:188–200. doi: 10.1016/j.patcog.2018.09.007
- Yamamoto Y, Tsuzuki T, Akatsuka J, Ueki M, Morikawa H, Numata Y, et al. Automated Acquisition of Explainable Knowledge From Unannotated Histopathology Images. *Nat Commun* (2019) 10(1):1–9. doi: 10.1038/s41467-019-13647-8
- Wang Z, Gerstein M, Snyder M. RNA-Seq: A Revolutionary Tool for Transcriptomics. *Nat Rev Genet* (2009) 10(1):57–63. doi: 10.1038/nrg2484
- Zhou C, Paffenroth RC. Anomaly Detection With Robust Deep Autoencoders. In: *Proceedings of the 23rd ACM SIGKDD International Conference on Knowledge Discovery and Data Mining* (2017), 665–74. doi: 10.1145/3097983.3098052
- Géron A. Hands-On Machine Learning With Scikit-Learn, Keras, and TensorFlow: Concepts, Tools, and Techniques to Build Intelligent Systems. In: *O'Reilly Media, Inc.* (2019).
- Noble WS. What Is a Support Vector Machine? *Nat Biotechnol* (2006) 24(12):1565–7. doi: 10.1038/nbt1206-1565
- Breiman L. Heuristics of Instability and Stabilization in Model Selection. *Ann Stat* (1996) 24(6):2350–83. doi: 10.1214/aos/1032181158
- Huang S, Cai N, Pacheco PP, Narrandes S, Wang Y, Xu W. Applications of Support Vector Machine (SVM) Learning in Cancer Genomics. *Cancer Genomics Proteom* (2018) 15(1):41–51. doi: 10.21873/cgp.20063
- Bradley AP. The Use of the Area Under the ROC Curve in the Evaluation of Machine Learning Algorithms. *Pattern Recognit* (1997) 30(7):1145–59. doi: 10.1016/S0031-3203(96)00142-2
- Hänzelmann S, Castelo R, Guinney J. GSEA: Gene Set Variation Analysis for Microarray and RNA-Seq Data. *BMC Bioinf* (2013) 14(1):1–15. doi: 10.1186/1471-2105-14-7
- Zarrin AA, Bao K, Lupardus P, Vucic D. Kinase Inhibition in Autoimmunity and Inflammation. *Nat Rev Drug Discover* (2021) 20(1):39–63. doi: 10.1038/s41573-020-0082-8
- Siddiqui I, Schaeuble K, Chennupati V, Marraco SAF, Calderon-Copete S, Ferreira DP, et al. Intratumoral Tcf1+ PD-1+ CD8+ T Cells With Stem-Like Properties Promote Tumor Control in Response to Vaccination and Checkpoint Blockade Immunotherapy. *Immunity* (2019) 50(1):195–211.e10. doi: 10.1016/j.immuni.2018.12.021
- Vodnala SK, Eil R, Kishton RJ, Sukumar M, Yamamoto TN, Ha N-H, et al. T Cell Stemness and Dysfunction in Tumors Are Triggered by a Common Mechanism. *Science* (2019) 363(6434):eaau0135. doi: 10.1126/science.aau0135
- Artyomov MN, Van den Bossche J. Immunometabolism in the Single-Cell Era. *Cell Metab* (2020) 32(5):710–25. doi: 10.1016/j.cmet.2020.09.013
- Kim D-K, Cho B-J, Lee M-J, Kim JH. Prediction of Age and Sex From Paranasal Sinus Images Using a Deep Learning Network. *Medicine* (2021) 100(7):e24756. doi: 10.1097/MD.00000000000024756
- Elhaj-Abdou ME, El-Dib H, El-Helw A, El-Habrouk M. Deep_CNN_LSTM_GO: Protein Function Prediction From Amino-Acid Sequences. *Comput Biol Chem* (2021) 95:107584. doi: 10.1016/j.compbiolchem.2021.107584
- Beck MW. NeuralNetTools: Visualization and Analysis Tools for Neural Networks. *J Stat Software* (2018) 85(11):1. doi: 10.18637/jss.v085.i11

Conflict of Interest: The authors declare that the research was conducted in the absence of any commercial or financial relationships that could be construed as a potential conflict of interest.

Publisher's Note: All claims expressed in this article are solely those of the authors and do not necessarily represent those of their affiliated organizations, or those of the publisher, the editors and the reviewers. Any product that may be evaluated in

this article, or claim that may be made by its manufacturer, is not guaranteed or endorsed by the publisher.

Copyright © 2022 Xu, Han, Yang, Li, Shang, Liu, Li, Xu and Chen. This is an open-access article distributed under the terms of the Creative Commons Attribution

License (CC BY). The use, distribution or reproduction in other forums is permitted, provided the original author(s) and the copyright owner(s) are credited and that the original publication in this journal is cited, in accordance with accepted academic practice. No use, distribution or reproduction is permitted which does not comply with these terms.



OPEN ACCESS

EDITED BY

Junji Xu,
Capital Medical University, China

REVIEWED BY

Shengbin Huang,
Wenzhou Medical University, China
Lei Hu,
Beijing Stomatological Hospital,
Capital Medical University, China
Jiao Kai,
Fourth Military Medical University,
China

*CORRESPONDENCE

Mingyue Lyu
lvmingyue9292@163.com

SPECIALTY SECTION

This article was submitted to
Mucosal Immunity,
a section of the journal
Frontiers in Immunology

RECEIVED 29 April 2022

ACCEPTED 04 July 2022

PUBLISHED 25 July 2022

CITATION

Wu Z, Lin W, Yuan Q and Lyu M (2022)
A genome-wide association analysis:
m6A-SNP related to the onset of
oral ulcers.
Front. Immunol. 13:931408.
doi: 10.3389/fimmu.2022.931408

COPYRIGHT

© 2022 Wu, Lin, Yuan and Lyu. This is
an open-access article distributed under
the terms of the [Creative Commons
Attribution License \(CC BY\)](#). The use,
distribution or reproduction in other
forums is permitted, provided the
original author(s) and the copyright
owner(s) are credited and that the
original publication in this journal is
cited, in accordance with accepted
academic practice. No use,
distribution or reproduction is
permitted which does not comply with
these terms.

A genome-wide association analysis: m6A-SNP related to the onset of oral ulcers

Zhuoxuan Wu¹, Weimin Lin^{1,2}, Quan Yuan^{1,2}
and Mingyue Lyu^{1,2*}

¹State Key Laboratory of Oral Diseases & National Clinical Research Center for Oral Diseases, West China School of Stomatology, Sichuan University, Chengdu, China, ²State Key Laboratory of Oral Diseases & National Clinical Research Center for Oral Diseases, Department of Oral Implantology, West China Hospital of Stomatology, Sichuan University, Chengdu, China

Oral ulcers are one of the most common inflammatory diseases on oral mucosa that have obvious impacts on patients. Studies have shown that N6-methyladenosine (m6A) RNA transcription modification may be involved in the development of various inflammatory responses, and whether the pathogenesis of oral ulcers is related to m6A is unclear. This study aims to identify how m6A-related single nucleotide polymorphisms (m6A-SNPs) may affect oral ulcers. The UKBB dataset containing 10,599,054 SNPs was obtained from the GWAS database using the keyword "oral ulcer" and compared with the M6AVar database containing 13,703 m6A-SNPs. With 7,490 m6A-SNPs associated with oral ulcers identified, HaploReg and RegulomeDB were used for further functional validation and differential gene analysis was performed using the GEO database dataset GSE37265. A total of 7490 m6A-SNPs were detected in this study, 11 of which were related to oral ulcers ($p < 5 \times 10^{-8}$), and all of these SNPs showed eQTL signals. The SNP rs11266744 ($p = 2.00 \times 10^{-27}$) may regulate the expression of the local gene CCRL2, thereby participating in the pathogenesis of oral ulcers. In summary, by analyzing genome-wide association studies, this study showed that m6A modification may be involved in the pathogenesis of oral ulcers and CCRL2 may be the targeted gene.

KEYWORDS

GWAS, m6A, oral ulcers, CCRL2, pathogenesis

Introduction

Oral ulcers are one of the most common inflammatory diseases on oral mucosa, particularly affecting adolescents and young adults (1–3), and the incidence in the general population has reached about 1.8–5% (4–7). Severe aphthous ulcers are difficult to heal, greatly affecting patients' daily diet and mental state. The causes of oral ulcers may

include infection, local trauma, changes in hormone levels, vitamin deficiencies and genetics (8, 9). According to many studies, genetic factors were associated with oral ulcers (10, 11). A questionnaire survey of 684 patients with oral ulcers reported that 66% of patients have a history of oral ulcers in family members (10). Another retrospective study on 1,160 parents and their children showed that the variation of the latent phenotype in the incidence of oral ulcers was caused by an additive genetic factor (64%), a common environmental factor (26%) and a specific environmental factor (10%) (11). In addition to clinical studies, *in vitro* studies also showed that C677T mutations in the MTHFR gene were associated with the development and severity of oral ulcers (12).

N6-methyladenosine (m6A) refers to the methylation of the sixth N atom on the adenine base. As one of the most abundant chemical modifications on mammalian mRNA and non-coding RNA, it is involved in many biological activities including inflammatory responses (13, 14). Oral ulcers are featured in inflammatory responses stimulated by a variety of inflammatory cells, metabolic enzymes and cytokines (15). Studies showed that approximately 0.1% to 0.4% of adenosines in mRNA were modified by m6A, with an average of 2-3 m6A modification sites per transcript (16, 17). By recruiting specific protein complexes at the m6A modification site on RNA, the structure, function and stability of mRNA can be regulated, thereby regulating gene expression or splicing (16, 18). Proteins such as cofactor Wilms tumor 1 related protein (WTAP) (19), obesity-related protein (FTO) (20), and cytoplasmic YTH domain-containing family member 1 (YTHDF2) (21) can be involved in the regulation of inflammatory responses by altering m6A modifications (22, 23). And dysregulation of local inflammatory response in the oral mucosa can disrupt normal mucosal structures and induce oral ulcers. In addition, m6A-SNP affects m6A methylation and related biological processes by changing the RNA sequence of the target site or key flanking nucleotides (24).

Based on the current analysis of the m6A-SNP list and published GWAS data, m6A-SNPs were found to be associated with diseases with inflammatory responses such as periodontitis (25), type 2 diabetes (26, 27) and obesity (28). On the other hand, oral ulcers are characterized by inflammatory responses, so it is worthwhile to further explore the relationship between m6A-SNPs and oral ulcers. Genome-wide association studies (GWAS) assess the association between SNPs and traits by analyzing multiple genetic variants in individuals with different phenotypes (29). Previous studies determined oral ulcer susceptibility loci located in the protein-coding region by GWAS, such as coding key cytokines (tumor necrosis factor- α , interleukin-1 α , interleukin-10 and interleukin-12) gene region variation (9, 30). In addition to the SNPs mentioned above, a large number of SNPs are located in non-protein-coding regions. Specifically, studies showed that SNPs located in the untranslated region (UTR) could also affect RNA secondary

structure or RNA-protein interactions (31). Moreover, these SNPs could also alter enhancers or silencers during exon splicing (32).

Above all, oral ulcer is an inflammatory disease closely associated with genetic factors, and m6A-SNP directly affects gene expression involved in the development of inflammatory responses. Since whether m6A-SNP is involved in the pathogenesis of oral ulcers is still unclear and GWAS help to fully reveal the genes associated with oral ulcers development, exploring how m6A-SNPs related to oral ulcers may provide a new perspective on the genetic mechanism of oral ulcers. Therefore, this study aims to explore the role of m6A-SNP in the occurrence and development of oral ulcers by analyzing the original data of the published oral ulcer GWAS and the list of m6A-SNPs in the M6Avar database.

Methods

Identification of oral ulcers-associated m6A-SNPs

Firstly, we downloaded the GWAS summary data on oral ulcers in UKBB (the oral ulcer, 39439 cases and 345587 controls). In order to ascertain the m6A-SNPs that might have an effect on the methylation of m6A, we downloaded the list of m6A-SNPs from the publicly available M6AVar database and compared it with the comprehensive statistics of oral ulcers (33). Currently, the M6AVar database contains 13,703 high confidence levels (miCLIP/PA-m6A-seq experiments), 54,222 medium confidence levels (MERIP-Seq experiments), and 245,076 low confidence levels (random based on the random forest algorithm) of human m6A-SNP genome prediction (33). In the following analysis, $p < 0.05$ was designed as the threshold for statistical significance.

Expression quantitative trait loci analysis of oral ulcers-associated m6A-SNPs

One of the ways that m6A modification exerts a biological effect is to affect the regulation of local genes. After identifying the m6A-SNPs associated with oral ulcers, online tools were used to annotate them to explore the mechanism of their biological functions. The HaploReg browser (<http://archive.broadinstitute.org/mammals/haploreg/haploreg.php>) is used to detect whether the eQTL signal of the identified m6A-SNP is displayed, and functional evidence can also be obtained ($p < 0.05$) (34). In addition, through HaploReg and RegulomeDB (<http://regulome.stanford.edu/>), functional verification of the identified m6A-SNPs was performed to determine their possible roles in transcriptional regulation.

Prediction of m6A modification near m6A-SNPs

The m6A-SNPs identified by the analysis above were input into an online m6A modification prediction tool (SRAMP, <http://www.cuilab.cn/sramp/>) for further analysis. It can determine whether m6A-SNP affects surrounding m6A modifications by analyzing input reference sequences and altered sequences (such as genome sequences or cDNA sequences) (35).

Differential expression analysis of local genes

To explore the local gene expression of m6A-SNPs in the pathogenesis of oral ulcers, transcriptomic data from the GEO database of ulcerated and normal mucosa were used for differential gene analysis. In the GEO database (<http://www.ncbi.nlm.nih.gov/geo/>), we downloaded the data set GSE37265 containing standardized oral ulcer-related gene expression signals (14 recurrent aphthous ulcer sites tissue and 14 normal controls). For the average gene expression signals of oral ulcer patients and healthy controls, a t-test method was used to analyze the differential expression. The significance level of $p < 0.05$ was used for differential expression analysis.

Results

Identification of oral ulcers-associated m6A-SNPs

In this study, 10,599,054 SNPs from the GWAS for oral ulcers and 13,703 m6A-SNPs from the M6Avar database were used to perform the analysis, of which 7,490 m6A-SNPs were identified. (Figures 1, 2). By analyzing the GWAS data, there were 259 m6A-SNPs with high confidence levels among the 7490 m6A-SNPs, and the medium and low levels were 1318 and 5913, respectively. Then the genome-wide threshold $p < 5.0 \times 10^{-8}$ (red line) and the recommended threshold $p < 5.0 \times 10^{-5}$ (blue line) were used to screen the association between m6A-SNPs and oral ulcers. Finally, rs11266744 ($p = 2.0 \times 10^{-27}$) reached the highest significance among the 7490 m6A-SNPs. By using the R package “qqman”, a Manhattan plot containing 7490 M6A-SNPs was generated (Figure 2).

eQTL analysis

m6A-SNPs might participate in gene expression regulation by influencing RNA modification, so eQTL analysis was used to investigate whether they were related to local gene expression

levels. A total of 25 m6A-SNPs ($p < 0.05$) associated with oral ulcers showed eQTL signals (Figure 1; Table 1), and most of them were displayed in various tissues or cells. Among them, the unknown functions of the top 20 ($p < 0.01$) m6A-SNPs in the process of transcriptional regulation were explored. Finally, by using the ENCODE transcription factor CHIP-SEQ dataset, a total of 15 m6A-SNPs were found to change the protein binding or regulatory motifs of local genes in different cell types (Table 1) (36).

Differential expression analysis

The appeal analysis found a total of 25 m6A-SNPs showing eQTL signals. In order to analyze the mRNA expression levels of these SNP local genes, we analyzed the difference in gene expression between the ulcer site of patients with recurrent aphthous ulcers and normal control tissues in the GEO database. Through differential expression analysis, 19 m6A-SNPs were detected to form a SNP-gene expression-oral ulcer triad (Figures 1, 3). In Figure 3, mRNA levels of differentially expressed genes between oral ulcer patients and normal controls were shown. Among them, the expression of inflammation-related genes such as CCRL2, HLA-C, GSDMB, HLA-DPB1, and MAPT increased in patients with oral ulcers. Based on this, we speculated that the involvement of these m6A-SNPs in the occurrence of oral ulcers might be accomplished by regulating the expression levels of corresponding genes.

Discussion

m6A modification is one of the most abundant mRNA modifications in higher organisms. It participates in the regulation of biological processes in transcription, including mRNA splicing, translation and stability, and dynamically regulates various physiological and pathological processes (37). In recent years, a large number of studies have focused on the role of RNA modifications in regulating inflammation and anti-inflammatory gene expression. Among them, m6A modification may affect the states of various inflammatory diseases through a variety of mechanisms (38). For example, studies showed that m6A binding protein YTHDF2 could regulate the stability of inflammatory gene mRNA transcripts and participate in the regulation of lipopolysaccharide (LPS)-induced inflammation (39). LPS could damage the oral mucosal barrier and trigger an inflammatory response according to another study, leading to the development of oral ulcers (40).

Genetic variation can affect RNA modification and related biological processes. Studies pointed out that SNPs could affect the RNA secondary structure or the interaction between RNA and protein (31, 41). The important role of SNPs in the development of various diseases has been reported (42, 43),

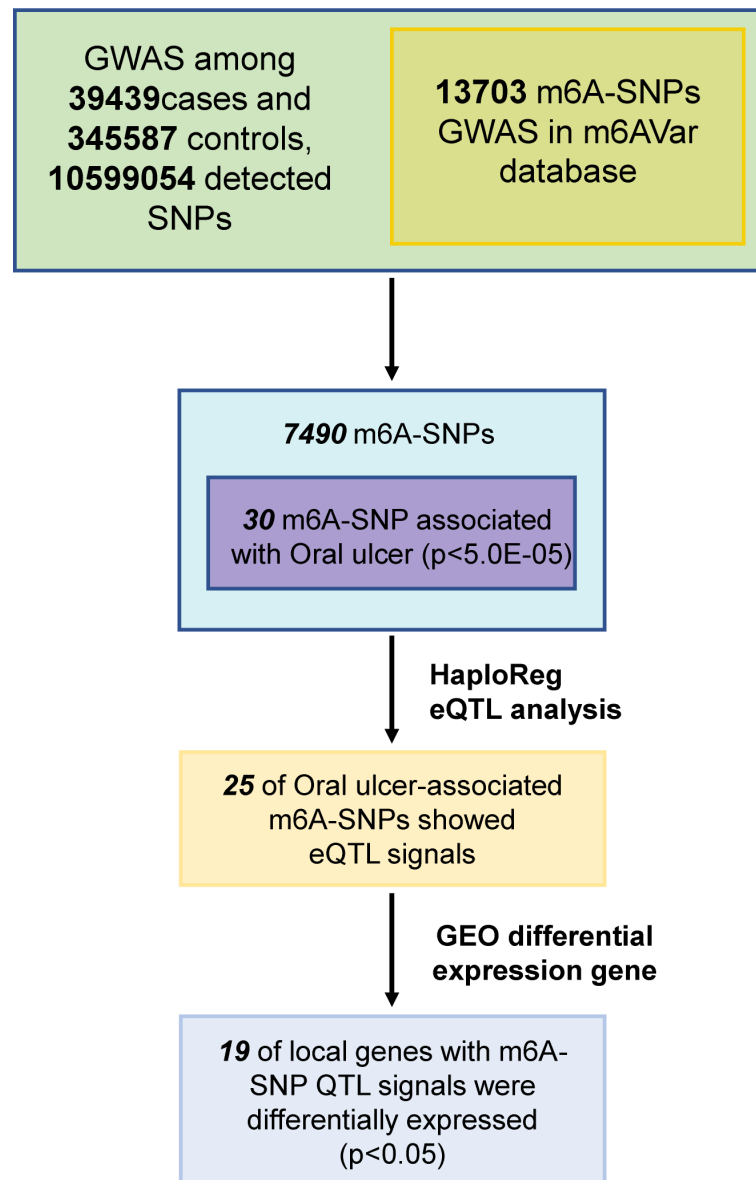


FIGURE 1
Flow chart of research designs and main results.

while how m6A-SNPs affect the pathogenesis of oral ulcers has not been confirmed by studies yet. Based on oral ulcer GWAS data and the analysis of the m6A-SNP list in the M6AVar database, we found a large number of related m6A-SNPs and further verified their local gene expression, which would be helpful for better understanding the relationship between m6A-SNPs and the pathogenesis of oral ulcers. Finally, our study shows that the expression of some relevant genes appears to be altered in patients with mouth ulcer. And m6A modifications targeting these genes may contribute to the incidence of oral ulcers. For example, since the CCRL2 protein is associated with

leukocyte chemotaxis and the HLA-C protein is a ligand for NK cells, the targeting of the CCRL2 and HLA-C genes would help to reduce the local inflammatory response in the oral mucosa.

This study found that the synonymous mutation rs11266744 in the CCRL2 coding region on chromosome 3 could change the motif and approach the DNaseI hypersensitive cluster (Figure 4). Furthermore, a moderately reliable predicted peak of m6A modification appeared near rs11266744 and would disappear with the change of the input sequence (Figure 5). The above evidence indicated that SNP rs11266744 might affect the m6A methylation of mRNA and further change the binding of regulatory

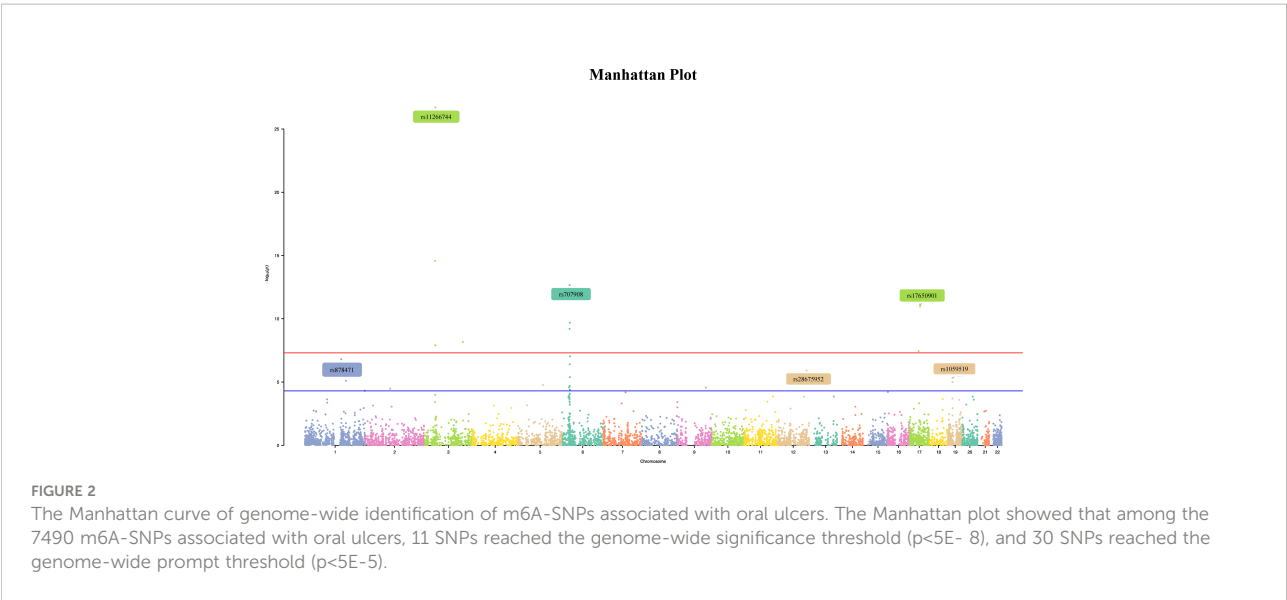

TABLE 1 Top 20 most significant m6A single nucleotide polymorphisms associated with oral ulcers.

Variant	CHR	Position	Mutation type	<i>p</i> value	Gene	DEG	eQTL	Proteins bound	Motifs changed	m6A_ID	m6A_Function
rs11266744	3	46408487	Synonymous	2.00E-27	CCRL2	Yes	No	No	Yes	m6A_ID_157544	Loss
rs1994492	3	45919154	3'-UTR	2.68E-15	FYCO1	Yes	Yes	No	Yes	m6A_ID_157454	Loss
rs707908	6	31270276	Missense	2.17E-13	HLA-C	Yes	Yes	No	No	m6A_ID_190475	Loss
rs17650901	17	45962325	5'-UTR	7.54E-12	MAPT	Yes	Yes	No	No	m6A_ID_309492	Loss
rs1802036	6	32168252	3'-UTR	2.08E-10	AGPAT1	Yes	Yes	Yes	No	m6A_ID_191049	Gain
rs2240803	6	30953180	3'-UTR	6.35E-10	DPCR1	Yes	Yes	No	Yes	m6A_ID_190410	Loss
rs6785881	3	160436201	3'-UTR	6.82E-09	TRIM59	No	Yes	No	Yes	m6A_ID_165133	Loss
rs11720094	3	46518421	3'-UTR	1.24E-08	LRRC2	Yes	Yes	No	Yes	m6A_ID_157583	Gain
rs2305480	17	39905943	Missense	3.54E-08	GSDMB	Yes	Yes	No	Yes	m6A_ID_307505	Gain
rs1042136	6	33080851	Missense	9.27E-08	HLA-DPB1	Yes	Yes	Yes	No	m6A_ID_191338	Loss
rs878471	1	150575271	3'-UTR	1.60E-07	MCL1	Yes	Yes	Yes	Yes	m6A_ID_124174	Loss
rs1046080	6	31628105	Missense	3.97E-07	PRRC2A	No	Yes	Yes	Yes	m6A_ID_13969	Loss
rs28675952	12	122715129	3'-UTR	1.22E-06	HCAR3	No	Yes	No	Yes	m6A_ID_267011	Loss
rs1059519	19	18386214	Missense	4.72E-06	GDF15	No	Yes	Yes	No	m6A_ID_326683	Loss
rs4786	1	169722991	3'-UTR	7.90E-06	SELE	Yes	Yes	Yes	Yes	m6A_ID_128464	Gain
rs6512262	19	18391755	3'-UTR	1.02E-05	LRRC25	Yes	Yes	No	Yes	m6A_ID_326690	Loss

(Continued)

TABLE 1 Continued

Variant	CHR	Position	Mutation type	p value	Gene	DEG	eQTL	Proteins bound	Motifs changed	m6A_ID	m6A_Function
rs180877323	5	102234749	3'-UTR	1.72E-05	SLCO4C1	No	No	No	Yes	m6A_ID_182044	Loss
rs35075694	6	31268757	3'-UTR	2.05E-05	HLA-C	Yes	Yes	Yes	Yes	m6A_ID_190474	Gain
rs853678	6	28329536	Missense	2.65E-05	ZSCAN31	Yes	Yes	Yes	Yes	m6A_ID_71136	Loss
rs3181371	9	114903290	3'-UTR	2.76E-05	TNFSF8	Yes	No	No	Yes	m6A_ID_227454	Loss

motifs, ultimately regulating the expression of gene CCRL2. CCRL2 is a chemokine receptor with seven transmembrane regions, and its only ligand is the non-chemokine chemotactic protein—chemerin (44). When endothelial cells or epithelial cells express CCRL2, the local concentration of chemerin will increase, thereby helping to form a chemotactic gradient for leukocytes expressing CMKLR1 (the functional chemerin receptor) (44). Specifically, the N-terminal of CCRL2 binds chemerin and the C-terminal peptide interacts with CMKLR1, which promotes the aggregation of immune cells expressing CMKLR1 (45, 46). A number of studies proved that CCRL2 was involved in the occurrence and development of inflammatory diseases (47–49). Oral ulcers are characterized by the inflammatory reactions of mucosal epithelial tissues in the oral cavity. During this process, chemokines, chemokine receptors and immune cells will all increase significantly (50, 51). Therefore, the abnormal expression of the gene CCRL2 in mucosal tissues is very likely to trigger inflammation and then induce the occurrence of oral ulcers, and m6A-SNPs play an important role in this process. Further, an

analysis of the relationship between loci in CCRL2 and different diseases showed that rs11266744 was most closely associated with oral ulcers (Supplementary Figure 1). Based on the above analysis, we speculated that SNP rs11266744 could cause oral ulcers by affecting the expression of the local gene CCRL2.

In addition to inflammation-related genes such as CCRL2, the role of non-inflammation-related genes in oral ulcers is also of interest. rs17650901 ($p=7.54E-12$) is located on the gene MAPT, which was differentially expressed in the oral ulcer group. The MAPT gene encodes the Tau protein, a microtubule-associated protein, and abnormalities in the Tau protein often cause a number of neurological disorders such as Alzheimer's disease, frontotemporal dementia and Huntington's disease (52). Tau proteins promote the polymerization of microtubule proteins into microtubules and maintain their stability, which is associated with normal neuronal function (53). A decrease in Tau protein would reduce the transmission of injurious messages such as pain from the peripheral nervous system to the central nervous system (54). In the oral mucosa, the expression of Tau

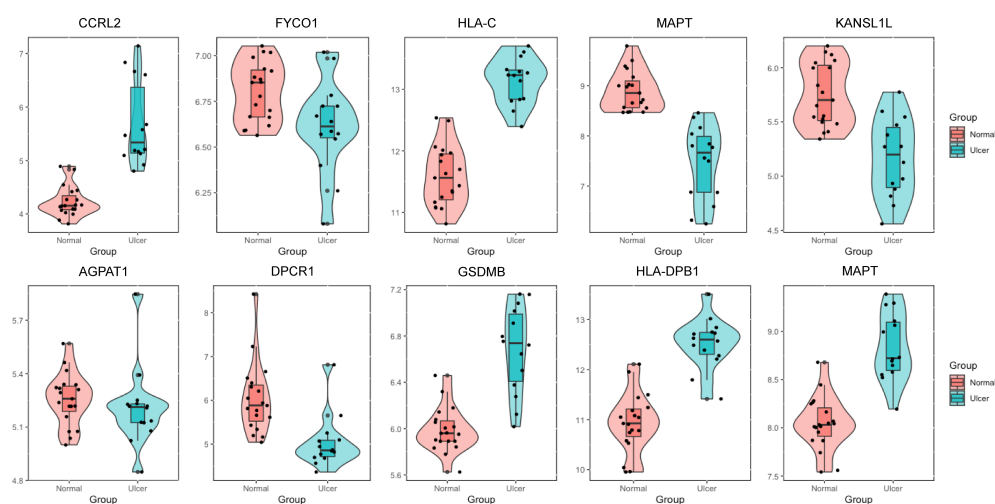


FIGURE 3

The expression levels of selected genes were shown in oral ulcer patients and healthy controls. The expression of genes such as CCRL2, HLA-C, GSDMB, HLA-DPB1 and MAPT were elevated in patients with oral ulcers.

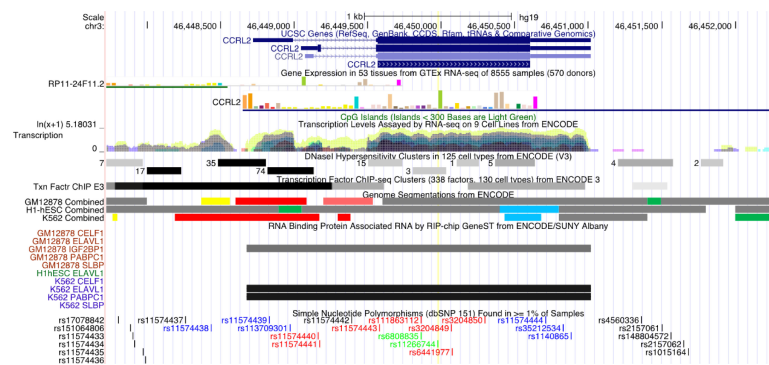
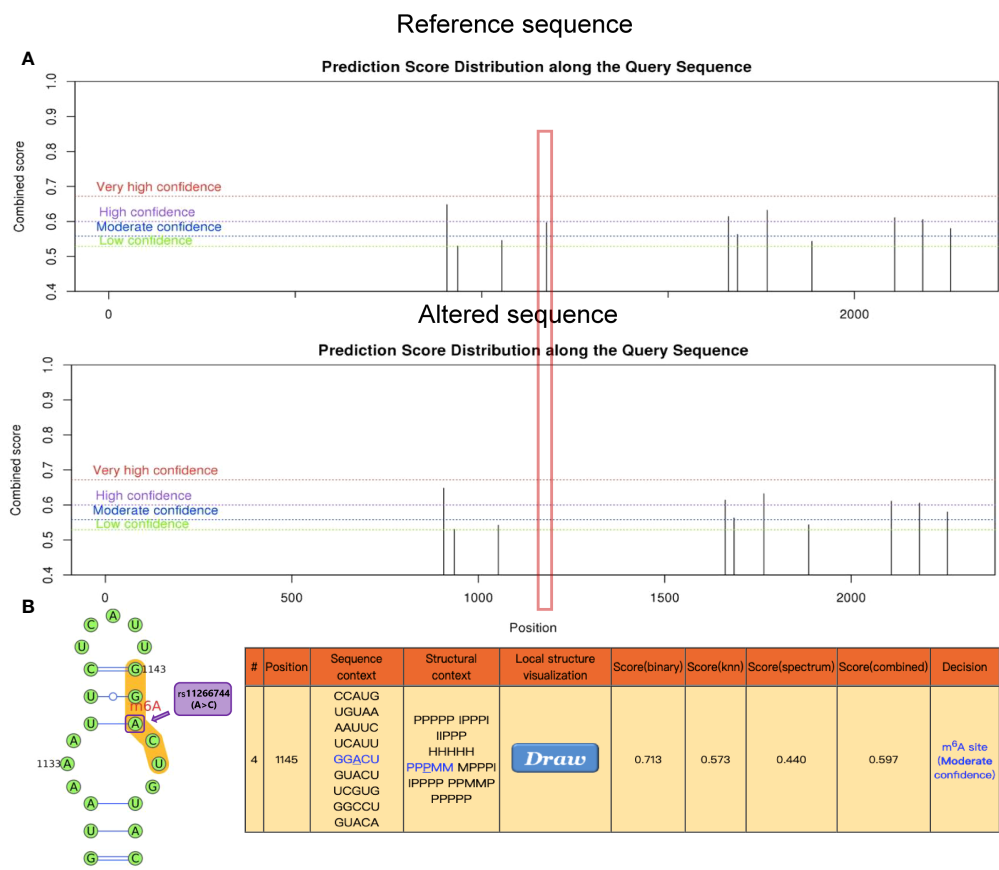


FIGURE 4
The regional association map of the rs11266744 locus. The SNP rs11266744 was located in the CCRL2 protein-coding region. This region showed very high conservation, transcription level and DNase I hypersensitivity.



protein is proved to be associated with cognitive processes such as emotion. Arredondo et al. showed that Tau transcripts were presented at a higher rate in the oral mucosa of cognitively impaired subjects compared to the controls (55). Meanwhile, the expression of MAPT gene was lower in the group of patients with oral ulcers, causing a reduction in Tau protein synthesis. As a result, this reduction reduced the transmission of peripheral injurious stimuli and relieves irritation to the central nervous system, relieving the dysphoria in patients with oral ulcers.

This finding firstly demonstrates that m6A-associated genetic factors are involved in the development of oral ulcers, and there are some shortcomings: (1) lack of publicly available data on relevant proteomic expression profiles, the identified m6A-SNPs have not been validated at the protein expression level. Our study has demonstrated that m6A-SNPs can be involved in the development of oral ulcers by regulating gene expression. More data disclosure of relevant proteomic expression profiles will help to understand the pathogenic mechanisms of m6A-SNPs at the protein expression level; (2) the relationship between the identified m6A-SNP and oral ulcers needs to be verified through case-control studies and electronic replication; (3) whether m6A-SNPs are involved in the development of oral ulcers by affecting gene expression has not been clarified, and how it is involved in the pathogenesis of oral ulcers also remains to be verified.

Conclusion

In summary, this study revealed for the first time that m6A modification may be involved in the pathogenesis of oral ulcers. By bioinformatic analysis, the m6A-SNP rs11266744 was identified to be associated with the m6A modification of the CCRL2 gene. m6A modification affected would be involved in the development of intraoral inflammation by inducing the aggregation of leukocytes expressing CMKLR1.

Data availability statement

The original contributions presented in the study are included in the article/**supplementary material**. Further inquiries can be directed to the corresponding author.

Ethics statement

Written informed consent was obtained from the individual(s) for the publication of any potentially identifiable images or data included in this article.

Author contributions

ML conceived the study. ZW and WL designed the experiments. ZW, WL, and ML performed the experiments. ZW and WL analyzed the data. QY helped with the statistical analysis of the data. ZW and ML wrote the manuscript. All authors contributed to the article and approved the submitted version.

Funding

National Natural Science Foundation of China (NSFC 81900967), Sichuan Science and Technology Program (2020JDRC0023).

Acknowledgments

We appreciate this opportunity to cooperate, and we are grateful for the support from National Natural Science Foundation of China (NSFC 81900967), Sichuan Science and Technology Program (2020JDRC0023) throughout the study.

Conflict of interest

The authors declare that the research was conducted in the absence of any commercial or financial relationships that could be construed as a potential conflict of interest.

Publisher's note

All claims expressed in this article are solely those of the authors and do not necessarily represent those of their affiliated organizations, or those of the publisher, the editors and the reviewers. Any product that may be evaluated in this article, or claim that may be made by its manufacturer, is not guaranteed or endorsed by the publisher.

Supplementary material

The Supplementary Material for this article can be found online at: <https://www.frontiersin.org/articles/10.3389/fimmu.2022.931408/full#supplementary-material>.

References

- Rodsaward P, Prueksrisakul T, Deekajorndech T, Edwards S, Beresford M, Chiewchengchol D. Oral ulcers in juvenile-onset systemic lupus erythematosus: A review of the literature. *Am J Clin Dermatol* (2017) 18(6):755–62. doi: 10.1007/s40257-017-0286-9
- Toche PP, Salinas LJ, Guzmán MM, Afani SA, Jadue AN. [Recurrent oral ulcer: Clinical characteristic and differential diagnosis]. *Rev Chil Infectol* (2007) 24(3):215–9. doi: 10.4067/s0716-10182007000300007
- Slebioda Z, Szponar E, Kowalska A. Recurrent aphthous stomatitis: Genetic aspects of etiology. *Postep Derm Alergol* (2013) 30(2):96–102. doi: 10.5114/pdia.2013.34158
- Yao H, Song Q, Zhang Q, Tang G, Liu M. Prevalence of oral mucosal lesions in children in xiangyun of yunnan, China: A cross-sectional study. *Ital J Pediatr* (2022) 48(1):15. doi: 10.1186/s13052-022-01209-6
- Amadori F, Bardellini E, Conti G, Majorana A. Oral mucosal lesions in teenagers: A cross-sectional study. *Ital J Pediatr* (2017) 43(1):50. doi: 10.1186/s13052-017-0367-7
- Hong C, Dean D, Hull K, Hu S, Sim Y, Nadeau C, et al. World workshop on oral medicine vii: Relative frequency of oral mucosal lesions in children, a scoping review. *Oral Dis* (2019) 25(Suppl 1):193–203. doi: 10.1111/odi.13112
- de Oliveira L, Torriani D, Correa M, Peres M, Peres K, Matijasevich A, et al. Oral mucosal lesions' impact on oral health-related quality of life in preschool children. *Community Dent Oral Epidemiol* (2015) 43(6):578–85. doi: 10.1111/cdoe.12185
- Siu A, Landon K, Ramos D. Differential diagnosis and management of oral ulcers. *Semin Cutan Med Surg* (2015) 34(4):171–7. doi: 10.12788/j.sder.2015.0170
- Dudding T, Haworth S, Lind P, Sathirapongsasuti J, Tung J, Mitchell R, et al. Genome wide analysis for mouth ulcers identifies associations at immune regulatory loci. *Nat Commun* (2019) 10(1):1052. doi: 10.1038/s41467-019-08923-6
- Safadi R. Prevalence of recurrent aphthous ulceration in Jordanian dental patients. *BMC Oral Health* (2009) 9:31. doi: 10.1186/1472-6831-9-31
- Lake R, Thomas S, Martin N. Genetic factors in the aetiology of mouth ulcers. *Genet Epidemiol* (1997) 14(1):17–33. doi: 10.1002/(sici)1098-2272(1997)14:1<17::Aid-gepi2>3.0.Co;2-2
- Kalkan G, Karakus N, Yigit S. Association of mthfr gene C677t mutation with recurrent aphthous stomatitis and number of oral ulcers. *Clin Oral Investig* (2014) 18(2):437–41. doi: 10.1007/s00784-013-0997-0
- Yang G, Sun Z, Zhang N. Reshaping the role of M6a modification in cancer transcriptome: A review. *Cancer Cell Int* (2020) 20:353. doi: 10.1186/s12935-020-01445-y
- Zhang X, Li X, Jia H, An G, Ni J. The M6a methyltransferase Mettl3 modifies pgc-1 α mRNA promoting mitochondrial dysfunction and oxldl-induced inflammation in monocytes. *J Biol Chem* (2021) 297(3):101058. doi: 10.1016/j.jbc.2021.101058
- Liu Y, Ren S, Ji H, Yan D. Study on the inhibition of inflammation by the cyclooxygenase-2 (Cox-2)/Prostaglandin E2 (Pge2) pathway and the promotion of wound healing of oral ulcer of yangyin shengji powder after chemotherapy. *Ann Palliat Med* (2021) 10(12):12716–26. doi: 10.21037/apm-21-3496
- Fu Y, Dominissini D, Rechavi G, He C. Gene expression regulation mediated through reversible M6a rna methylation. *Nat Rev Genet* (2014) 15(5):293–306. doi: 10.1038/nrg3724
- Karthiya R, Khandelia P. M6a rna methylation: Ramifications for gene expression and human health. *Mol Biotechnol* (2020) 62(10):467–84. doi: 10.1007/s12033-020-00269-5
- Schwartz S, Agarwala S, Mumbach M, Jovanovic M, Mertins P, Shishkin A, et al. High-resolution mapping reveals a conserved, widespread, dynamic mRNA methylation program in yeast meiosis. *Cell* (2013) 155(6):1409–21. doi: 10.1016/j.cell.2013.10.047
- He P, He C. M6A rna methylation: From mechanisms to therapeutic potential. *EMBO J* (2021) 40(3):e105977. doi: 10.15252/embj.2020105977
- Li Y, Ge Y, Xu L, Xu Z, Dou Q, Jia R. The potential roles of rna N6-methyladenosine in urological tumors. *Front Cell Dev Biol* (2020) 8:579919. doi: 10.3389/fcell.2020.579919
- Wang J, Lu A. The biological function of M6a reader Ythdf2 and its role in human disease. *Cancer Cell Int* (2021) 21(1):109. doi: 10.1186/s12935-021-01807-0
- Zhu Z, Huo F, Pei D. Function and evolution of rna N6-methyladenosine modification. *Int J Biol Sci* (2020) 16(11):1929–40. doi: 10.7150/ijbs.45231
- Mapperley C, van de Lagemaat L, Lawson H, Tavosanis A, Paris J, Campos J, et al. The mRNA M6a reader Ythdf2 suppresses proinflammatory pathways and sustains hematopoietic stem cell function. *J Exp Med* (2021) 218(3):e20200829. doi: 10.1084/jem.20200829
- Deng X, Su R, Stanford S, Chen J. Critical enzymatic functions of fto in obesity and cancer. *Front Endocrinol (Lausanne)* (2018) 9:396. doi: 10.3389/fendo.2018.00396
- Lin W, Xu H, Wu Y, Wang J, Yuan Q. In silico genome-wide identification of M6a-associated snps as potential functional variants for periodontitis. *J Cell Physiol* (2020) 235(2):900–8. doi: 10.1002/jcp.29005
- Chen M, Lin W, Yi J, Zhao Z. Exploring the epigenetic regulatory role of M6a-associated snps in type 2 diabetes pathogenesis. *Pharmgenom Pers Med* (2021) 14:1369–78. doi: 10.2147/pgpm.S334346
- Prattichizzo F, De Nigris V, Spiga R, Mancuso E, La Sala L, Antonicelli R, et al. Inflammation and metaflammation: The yin and yang of type 2 diabetes. *Ageing Res Rev* (2018) 41:1–17. doi: 10.1016/j.arr.2017.10.003
- Lan N, Lu Y, Zhang Y, Pu S, Xi H, Nie X, et al. Fto - a common genetic basis for obesity and cancer. *Front Genet* (2020) 11:559138. doi: 10.3389/fgene.2020.559138
- Mackey D, Hewitt A. Genome-wide association study success in ophthalmology. *Curr Opin Ophthalmol* (2014) 25(5):386–93. doi: 10.1097/icu.0000000000000090
- Jin X, Wang Y, Zhang X, Zhang W, Wang H, Chen C. Gene mapping and functional annotation of gwas of oral ulcers using fuma software. *Sci Rep* (2020) 10(1):12205. doi: 10.1038/s41598-020-68976-2
- Mao F, Xiao L, Li X, Liang J, Teng H, Cai W, et al. Rbp-var: A database of functional variants involved in regulation mediated by rna-binding proteins. *Nucleic Acids Res* (2016) 44:D154–63. doi: 10.1093/nar/gkv1308
- Wu X, Hurst L. Determinants of the usage of splice-associated cis-motifs predict the distribution of human pathogenic snps. *Mol Biol Evol* (2016) 33(2):518–29. doi: 10.1093/molbev/msv251
- Zheng Y, Nie P, Peng D, He Z, Liu M, Xie Y, et al. M6avar: A database of functional variants involved in M6a modification. *Nucleic Acids Res* (2018) 46:D139–D45. doi: 10.1093/nar/gkx895
- Ward L, Kellis M. Haploreg: A resource for exploring chromatin states, conservation, and regulatory motif alterations within sets of genetically linked variants. *Nucleic Acids Res* (2012) 40:D930–4. doi: 10.1093/nar/gkr917
- Zhou Y, Zeng P, Li Y, Zhang Z, Cui Q. Srampp: Prediction of mammalian N6-methyladenosine (M6a) sites based on sequence-derived features. *Nucleic Acids Res* (2016) 44(10):e91. doi: 10.1093/nar/gkw104
- Kheradpour P, Kellis M. Systematic discovery and characterization of regulatory motifs in encode tf binding experiments. *Nucleic Acids Res* (2014) 42(5):2976–87. doi: 10.1093/nar/gkt1249
- Jiang X, Liu B, Nie Z, Duan L, Xiong Q, Jin Z, et al. The role of M6a modification in the biological functions and diseases. *Signal Transduct Target Ther* (2021) 6(1):74. doi: 10.1038/s41392-020-00450-x
- Luo J, Xu T, Sun K. N6-methyladenosine rna modification in inflammation: Roles, mechanisms, and applications. *Front Cell Dev Biol* (2021) 9:670711. doi: 10.3389/fcell.2021.670711
- Yu R, Li Q, Feng Z, Cai L, Xu Q. M6a reader Ythdf2 regulates lps-induced inflammatory response. *Int J Mol Sci* (2019) 20(6):1323. doi: 10.3390/ijms20061323
- Majumder R, Adhikari L, Dhara M, Sahu J. Evaluation of anti-inflammatory, analgesic and tmf-A inhibition (Upon raw 264.7 cell line) followed by the selection of extract (Leaf and stem) with respect to potency to introduce anti-Oral-Ulcer model obtained from olax psittacorum (Lam.) vahl in addition to gc-Ms illustration. *J Ethnopharmacol* (2020) 263:113146. doi: 10.1016/j.jep.2020.113146
- Ramaswami G, Deng P, Zhang R, Anna Carbone M, Mackay T, Billy Li J. Genetic mapping uncovers cis-regulatory landscape of rna editing. *Nat Commun* (2015) 6:8194. doi: 10.1038/ncomms9194
- Zhu R, Tian D, Zhao Y, Zhang C, Liu X. Genome-wide detection of M6a-associated genetic polymorphisms associated with ischemic stroke. *J Mol Neurosci* (2021) 71(10):2107–15. doi: 10.1007/s12031-021-01805-x
- Lin Y, Wang S, Liu S, Lv S, Wang H, Li F. Identification and verification of molecular subtypes with enhanced immune infiltration based on M6a regulators in cutaneous melanoma. *BioMed Res Int* (2021) 2021:2769689. doi: 10.1155/2021/2769689
- Schioppa T, Sozio F, Barbazza I, Scutera S, Bosio D, Sozzani S, et al. Molecular basis for Ccr12 regulation of leukocyte migration. *Front Cell Dev Biol* (2020) 8:615031. doi: 10.3389/fcell.2020.615031
- Zabel B, Nakae S, Zúñiga L, Kim J, Ohshima T, Alt C, et al. Mast cell-expressed orphan receptor Ccr12 binds chemerin and is required for optimal induction of ige-mediated passive cutaneous anaphylaxis. *J Exp Med* (2008) 205(10):2207–20. doi: 10.1084/jem.20080300
- Tiberio L, Del Prete A, Schioppa T, Sozio F, Bosio D, Sozzani S. Chemokine and chemotactic signals in dendritic cell migration. *Cell Mol Immunol* (2018) 15(4):346–52. doi: 10.1038/s41423-018-0005-3

47. Otero K, Vecchi A, Hirsch E, Kearley J, Vermi W, Del Prete A, et al. Nonredundant role of Ccr12 in lung dendritic cell trafficking. *Blood* (2010) 116(16):2942–9. doi: 10.1182/blood-2009-12-259903
48. Gonzalvo-Feo S, Del Prete A, Pruenster M, Salvi V, Wang L, Sironi M, et al. Endothelial cell-derived chemerin promotes dendritic cell transmigration. *J Immunol* (2014) 192(5):2366–73. doi: 10.4049/jimmunol.1302028
49. Mazzon C, Zanotti L, Wang L, Del Prete A, Fontana E, Salvi V, et al. Ccr12 regulates M1/M2 polarization during eae recovery phase. *J Leukoc Biol* (2016) 99(6):1027–33. doi: 10.1189/jlb.3MA0915-444RR
50. Özcan E, Saygun N, İlkçi R, Karşoğlu Y, Muşabak U, Yeşillik S. Evaluation of chemerin and its receptors, Chemr23 and Ccr12, in gingival tissues with healthy and periodontitis. *Odontology* (2018) 106(1):29–36. doi: 10.1007/s10266-017-0297-2
51. Dalghous A, Freysdottir J, Fortune F. Expression of cytokines, chemokines, and chemokine receptors in oral ulcers of patients with behcet's disease (Bd) and recurrent aphthous stomatitis is Th1-associated, although Th2-association is also observed in patients with bd. *Scand J Rheumatol* (2006) 35(6):472–5. doi: 10.1080/03009740600905380
52. Compta Y, Revesz T. Neuropathological and biomarker findings in parkinson's disease and alzheimer's disease: From protein aggregates to synaptic dysfunction. *J Parkinsons Dis* (2021) 11(1):107–21. doi: 10.3233/jpd-202323
53. Sinsky J, Pichlerova K, Hanes J. Tau protein interaction partners and their roles in alzheimer's disease and other tauopathies. *Int J Mol Sci* (2021) 22(17):9207. doi: 10.3390/ijms22179207
54. Sotiropoulos I, Lopes A, Pinto V, Lopes S, Carlos S, Duarte-Silva S, et al. Selective impact of tau loss on nociceptive primary afferents and pain sensation. *Exp Neurol* (2014) 261:486–93. doi: 10.1016/j.expneurol.2014.07.008
55. Arredondo L, Aranda-Romo S, Rodríguez-Leyva I, Chi-Ahumada E, Saikaly SK, Portales-Pérez DP, et al. Tau protein in oral mucosa and cognitive state: A cross-sectional study. *Front Neurol* (2017) 8:554(554). doi: 10.3389/fneur.2017.00554



OPEN ACCESS

EDITED BY

Junji Xu,
Capital Medical University, China

REVIEWED BY

Wenjun Zhang,
Tianjin Medical University General
Hospital, China
Yasuhiro Mouri,
Tokushima University, Japan

*CORRESPONDENCE

Siyu Wang
graceyuyu@126.com

[†]These authors have contributed
equally to this work

SPECIALTY SECTION

This article was submitted to
Mucosal Immunity,
a section of the journal
Frontiers in Immunology

RECEIVED 12 June 2022

ACCEPTED 18 July 2022

PUBLISHED 05 August 2022

CITATION

Wang R, Zhang X and Wang S (2022)
Differential genotypes of TNF- α and
IL-10 for immunological diagnosis in
discoid lupus erythematosus and oral
lichen planus: A narrative review.
Front. Immunol. 13:967281.
doi: 10.3389/fimmu.2022.967281

COPYRIGHT

© 2022 Wang, Zhang and Wang. This is
an open-access article distributed under
the terms of the [Creative Commons
Attribution License \(CC BY\)](#). The use,
distribution or reproduction in other
forums is permitted, provided the
original author(s) and the copyright
owner(s) are credited and that the
original publication in this journal is
cited, in accordance with accepted
academic practice. No use,
distribution or reproduction is
permitted which does not comply with
these terms.

Differential genotypes of TNF- α and IL-10 for immunological diagnosis in discoid lupus erythematosus and oral lichen planus: A narrative review

Ruochong Wang^{1†}, Xuefeng Zhang^{1†} and Siyu Wang^{2*}

¹Emergency Department, State Key Laboratory of Oral Diseases, National Center of Stomatology, National Clinical Research Center for Oral Diseases, West China Hospital of Stomatology, Sichuan University, Chengdu, China, ²Department of Dermatology, Institute of Dermatology and Venereology, Sichuan Academy of Medical Sciences & Sichuan Provincial People's Hospital, Chengdu, China

Discoid lupus erythematosus and oral lichen planus are chronic systemic immune system-mediated diseases with unclear etiology and pathogenesis. The oral mucosa is the common primary site of pathogenesis in both, whereby innate and adaptive immunity and inflammation play crucial roles. The clinical manifestations of discoid lupus erythematosus on the oral mucosa are very similar to those of oral lichen planus; therefore, its oral lesion is classified under oral lichenoid lesions. In practice, the differential diagnosis of discoid lupus erythematosus and oral lichen planus has always relied on the clinical manifestations, with histopathological examination as an auxiliary diagnostic tool. However, the close resemblance of the clinical manifestations and histopathology proves challenging for accurate differential diagnosis and further treatment. In most cases, dentists and pathologists fail to distinguish between the conditions during the early stages of the lesions. It should be noted that both are considered to be precancerous conditions, highlighting the significance of early diagnosis and treatment. In the context of unknown etiology and pathogenesis, we suggest a serological and genetic diagnostic method based on TNF- α and IL-10. These are the two most common cytokines produced by the innate and adaptive immune systems and they play a fundamental role in maintaining immune homeostasis and modulating inflammation. The prominent variability in their expression levels and gene polymorphism typing in different lesions compensates for the low specificity of current conventional diagnostic protocols. This new diagnostic scheme, starting from the immunity and inflammation of the oral mucosa, enables simultaneous comparison of discoid lupus erythematosus and oral lichen planus. With relevant supportive evidence, this information can enhance physicians' understanding of the two diseases, contribute to precision medicine, and aid in prevention of precancerous conditions.

KEYWORDS

discoid lupus erythematosus, oral lichen planus, TNF- α , IL-10, immune homeostasis

Introduction

Lupus erythematosus is a general term for a group of chronic, recurrent autoimmune diseases that manifests in two main forms: systemic lupus erythematosus (SLE), which involves multiple organs, and cutaneous lupus erythematosus (CLE), which is limited to the skin and mucosae (1). Among CLEs, discoid cutaneous lupus erythematosus (DLE) is most likely to invade the oral mucosa, and the ensuing oral lesions are classified as oral lichenoid lesions (OLLs) (2), due to the close clinical resemblance to oral lichen planus (OLP), characterized by features such as plaques, petechiae, and oral erosions/ulcers. On further histological examination, both DLE and OLPL exhibit incomplete epithelial keratinization, subepithelial lymphocytic infiltration, and the presence of cytoid bodies in the granular and keratinized layers (3). Owing to the tremendous similarities between DLE and OLPL, clinicians experience considerable difficulty in differential diagnosis. Researchers (3, 4) reported that differences in clinical manifestation are almost nonexistent and reliable diagnostic tests are unavailable. Patients with similar symptoms of lichen planus should be referred to hospital for biopsy or other tests to confirm the diagnosis (2). However, it should be noted that both DLE and OLPL possess the potential for malignant transformation, and biopsy of the lesion area could accelerate this process by stimulating precancerous lesions (5, 6). Therefore, a minimally invasive diagnostic method is urgently needed.

Despite the unclear etiology, it is known that DLE and OLPL are regulated by the immune system. Multiple immune factors participate in the pathogenesis of DLE and OLPL. Therefore, to address this clinical dilemma, it is necessary to identify immune factors that are strongly correlated with DLE and OLPL, and to achieve a definite diagnosis by detecting differences among them. During our investigation, we found that a series of prospective studies and reviews highlight genotypes and expression levels of IL10 and TNF- α as characteristic and promising immunologic differentiators. It is expected that more accurate diagnosis will facilitate more precise and timely treatment.

Challenges in identification

OLPL is a common chronic inflammatory disease that manifests with oral mucosal and cutaneous lesions. It is characterized by lacelike white stripes on the oral mucosa with an abnormality of keratinization. The distribution of the lesions is primarily bilateral and symmetrical, particularly in the buccal mucosa. The disease can be classified as reticular, plaque-like, atrophic, bullous, erosive, and popular types according to their morphological characteristics. During the clinical course of the disease, the different types of lesions can transform into each other. After remission of the disease, pigmentation may remain on the mucosa. The pathological hallmarks are liquefied

degeneration of the basal lamina and dense lymphocytic infiltration of the lamina propria with a predominance of T cells. OLLs are a heterogeneous group of diseases with clinical manifestations and histopathology similar to OLPL, also known as oral lichenoid reactions (OLRs). In 2006, at the World Workshop in Oral Medicine IV, OLLs were separated into oral lichenoid contact lesions (OLCL) caused by contact with dental restorative materials, oral lichenoid drug reactions (OLDRLs) caused by certain systemic drugs, and oral lichenoid lesions of graft-vs.-host disease (GVHD) (7). The WHO then elucidated (8) the features of OLL and OLPL in 2007, but the diagnosis of OLL was based on exclusion rather than inclusion. Therefore, the WHO classification was only a descriptive list rather than a clinical guideline. In 2019, researchers (4) concluded that these classifications were outdated and incomplete, and failed to provide clear and reliable clinical and histological criteria; the classification of OLL was eventually expanded to thirteen clinical entities, that included DLE and other disorders. Nevertheless, Lu et al. (9) recently highlighted that to date, a widely acknowledged and accepted OLL classification was still lacking.

Progress regarding the development of OLL classifications has been achieved by the inclusion of more subtypes and the addition of OLL definitions. At present, DLE is classified as a type of OLL because of similarities in clinical and histopathological manifestations, cell kinetics, immune alterations, treatment, and prognosis. First, from an epidemiological perspective, young and middle-aged women are susceptible to both disorders. In terms of clinical manifestations, oral lesions of DLE occur on the buccal mucosa, vermillion, gingiva, dorsal tongue, ventral tongue and palate; whereas for OLPL, any part of the oral mucosa could be affected, with the buccal mucosa being the most common (10). Oral lesions of DLE range from dark red papules to well-circumscribed white lacy plaques with hyperkeratosis, and those with central ulceration possess radiolucent fine and short white lines. A characteristic of DLE lesions is that the lesion area can extend onto the skin beyond the vermillion margin, which can be observed in the early stages. However, after further erosion of the ulcerated surface, it is obscured by the formation of a crust resulting from hemorrhage combined with infection. DLE lesions heal with scarring, atrophy, and peripheral hyper- or hypopigmentation. OLPL manifests as small papules in a linear white pattern with abnormal keratinization. The surrounding mucosa around the white lesions may become congested, ulcerated, and eroded. Pigmentation is retained on the mucosa after regression. A recent comparative analysis (11) revealed that red macules, telangiectasia, and discoid plaques were more common in oral lupus erythematosus (OLE), whereas reticulated patches were more typical in OLPL. Nevertheless, the authors acknowledged that despite this, significant overlap remains between OLE and OLPL. The greatest difference in clinical manifestation between DLE and OLPL may lie in the fact that the former is mainly unilateral and asymmetric in

distribution, but the latter is primarily bilateral and symmetrical (4). However, this evidence is insufficient to support the diagnosis, and the diseases still appear similar, if not identical, in most cases; diagnosis currently relies on laboratory tests. Previous studies demonstrated that histopathological differentiation between DLE and OLP is in most cases equivocal or non-specific (12). Both present as epithelial dyskeratosis with keratin plugging; inflammation in the lamina propria can be a mixed inflammatory cell infiltrate or a lymphocyte-rich infiltrate, ranging from paucicellular to band-like; basal cells are liquefied and degenerated, and the basement membrane is indistinct (13) (Table 1).

Despite consideration of the clinical details, pathologists can only conservatively report the lesion as either OLP or OLL (2). Lu et al. (9) suggested that the term OLL should only be used for provisional diagnosis, and the specific subtype of OLL should be clearly indicated in the final diagnosis. Therefore, given the predicament of histopathology, the current research explores the potential of immunopathological examination and genetic testing.

Opportunity for differential diagnosis

Immunological methods have been widely used as an adjunctive diagnostic tool for OLP and DLE. Unlike pemphigus, pemphigoid, and other oral mucosal autoimmune diseases, DLE and OLP lack specific pathological manifestations. The immunopathological diagnosis mainly relies on observing the distribution and types of various immune factors. In an earlier comparative study (14), it was found that the diagnostic specificity of the immunofluorescence (IF) technique was greater than that of histopathology in both DLE and OLP, and the most discriminatory immunohistochemical features between DLE and

OLP were the incidence and morphological pattern of IgG along the epidermal basement membrane. Subsequently, in cases of DLE, a continuous, thick and thin emerald green fluorescent band at the basement membrane zone (BMZ) was observed using direct immunofluorescence (DIF). In addition to IgG, IgM and C3 were deposited in a granular or shaggy pattern, known as a lupus band (15, 16). Moreover, IgM is considered the most commonly identified immunoreactant in OLE, whereas C3 is more common in other oral lesions (17, 18). Further, statistics show that DIF is positive in approximately 70% of DLE tissue samples, whereas indirect immunofluorescence (IIF) is generally negative and not recommended for the diagnosis of DLE or OLP (13, 19). In OLP cases, DIF displayed granular or shaggy deposits of fibrin, fibrinogen, immunoglobulin, and C3 along the BMZ (14, 20). Although most researchers agreed that the presence of the lupus band observed by DIF would help confirm the diagnosis, Carrozzo et al. (21) contended that the lupus band is neither sufficiently sensitive nor specific to be a reliable diagnostic method. Despite its characteristics, it fails to be pathognomonic of DLE (22). The combination of serological biomarkers and immunohistochemical tests is expected to replace the flawed lupus band test. Unfortunately, since the etiology and pathogenesis remain unclear, no prominent autoantibodies or antigens to OLP or DLE are available for detection in the serum. Current research is directed at exploring some of the marked distinctions among inflammatory molecules typical of the disease.

Heat shock proteins (HSPs) have been implicated as antigenic stimuli of autoimmune diseases, also known as “stress proteins” and “molecular chaperones”. The two subtypes of HSPs, HSP60 and HSP70, are highly competent for T-cell activation, and histological studies demonstrate that OLP is a T-cell mediated disease (23, 24). Meanwhile, multiple case studies have observed significantly higher serum levels as

TABLE 1 Classification and characteristics of OLP and DLE.

Diseases		DLE	OLP
Prevalence		Young and middle-aged women	
Oral mucosal lesions		Unilateral affecting mainly on the hps. may exceed the vermillion and reach the skin; erythema or erosion surrounded by radiolucent fine and short white lines	Bilateral affecting mainly on the buccal area; irregularly shaped pearly white stripes or plaque with or without erosion and ulceration
Cutaneous lesions		Localized to head, face, auricles and sun-exposed areas: telangiectasia; hypopigmentation; butterfly-shaped arythema on the face	Bilateral affecting flexors of the extremities; light purle polygonal flat papules with waxy sheen
Histopathological features		Incomplete keratinization of the epithelium: prominently hyperplasia of the prickle cell layer; liquefied degeneration of the basal lamina; scattered infiltration of lymphocytes of the lamina propria; dense lymphocytic infiltration around the blood vessels, predominantly T cells	Incomplete keratinization of the epithelium; atrophy of the prickle cell layer; liquefied degeneration of the basal lamina; dense lymphocytic infiltration of the lamina propria with a predominance of T cells; little lymphocytic infiltration around the blood vessels
Immunopathological features		DIF: linear emerald green flourescent band or continuous IgG, IgM, IgA, C3 and fibrinogen deposition at BMZ, with or without IgM, IgG-positive cytioids bodies IIF: negative	DIF: granular or shaggy deposit of fibrin, fibrinogen, immunoglobulin, and C3 at BMZ. With or without IgM-positive cytoid bodies IIF: negative
Prognosis		Precancerous conditions	

OLP, oral lichen planus; DLE, discoid lupus erythematosus; DIF, direct immunofluorescence; IIF: indirect immunofluorescence; BMZ, basement membrane zone

well as mRNA overexpression of HSP60 and HSP70 in OLP cases compared to those in healthy controls (25–27). However, other studies revealed no statistically significant differences in HSP70 expression between OLP and normal mucosa (28). The expression of HSP60 is prominent in OLP, but it is not specific and can be seen in other lesions (29). Therefore, Mohtasham et al. (27) noted that upregulation of HSPs is not yet qualified as a diagnostic tool, and immunohistochemical tests or quantitative evaluations of HSPs for all cases of OLP are not recommended. Both the lupus band test and the quantitative evaluations of HSPs are only applicable to one of them, thus automatically excluding the other. A method that allows simultaneous comparison of the two diseases would be more specific and more rigorous.

TNF- α in OLP

TNF- α belongs to the TNF/TNFR cytokine superfamily, and is one of the most important pro-inflammatory cytokines and potent immunomodulators that regulates a wide range of immune-related activities, including inflammation, innate and adaptive immune responses, and autoimmunity (30). TNF- α is secreted by a variety of cells, such as activated monocytes, macrophages, B cells, T cells, mast cells, and fibroblasts (31). The histological evidence has proved that there is increased T-lymphocytic infiltration in OLP. Accordingly, case studies have shown that TNF- α was upregulated in lesional T cells and serum from OLP patients, and lesional T cells contain TNF- α mRNA and express TNF- α cytokines (32–35). In addition to the role of TNF- α produced by T cells, TNF- α is capable of enhancing TCR-dependent activation of CD8+ cytotoxic T cells (36). Histological studies further revealed that most OLP-associated T cells are activated CD8+ cytotoxic T cells (37). This is consistent with the cellular mechanism whereby CD8+ cytotoxic T cells trigger apoptosis of keratinocytes in OLP lesions by releasing TNF- α to bind to TNF- α receptor 1 (TNFR1) on the surface of keratinocytes (38).

The gene for TNF- α is located on chromosome 6q21, which is a highly polymorphic region (39). TNF- α possesses a large number of polymorphisms, reflected by having up to 14 alleles. Those alleles differ from their biallelic single nucleotide polymorphisms (SNPs), which are at different positions relative to the transcription start site and are mainly G to A substitutions. The most investigated polymorphisms in the promoter region of the TNF- α gene are those at positions -308 (rs1800629) and -238 (rs361525) (40). The A allele of SNP-308 promotes TNF- α expression, which is a stronger transcriptional activator than the G allele after *in vitro* lymphocyte stimulation (41, 42). A meta-analysis revealed that the TNF- α -308 G/A polymorphism was a potential genetic marker for OLP (43). The TNF- α gene polymorphisms vary not only between individuals, but also between populations. Bai et al. (44) first demonstrated that the frequencies of the TNF- α -308A allele in

patients with erosive OLP was significantly higher than that in controls in a Chinese Han cohort. Subsequently, a higher proportion of OLP patients with the TNF- α -308 AA genotype (high producer genotype) than with the other genotypes was found in the Thai population; also, the TNF- α -308 AA genotype was associated with an increased risk of developing erosive OLP. The association between the TNF- α promoter region at positions -863 and -238 and the disease was excluded (45). A close relationship between allele A of TNF- α (-308G/A) and OLP was also established in the Arabian OLP community (46). Several genetic studies have suggested a positive relationship between OLP and elevated TNF- α from the incidence in different races, which may be a certain epidemiological pattern. Genetic studies are also consistent with histological studies. Since the TNF- α -308 AA genotype is more predominant in erosive OLP and more keratinocyte apoptosis is observed in patients with erosive OLP, it can be inferred that the TNF- α -308 AA genotype leads to a higher production of TNF- α , which promotes CD8+ cytotoxic T cell-induced apoptosis in keratinocytes in OLP lesions (47).

TNF- α in DLE

On the contrary, Werth et al. found that polymorphism of TNF- α promoter -308A is not associated with DLE (48). In a large genetic study, using allele-specific probes and real time RT-PCR, researchers concluded that the high TNF- α producer group (-308AA or AG) was associated with SLE, while in the low TNF- α producer group (-308GG), the risk and prevalence of DLE was higher (49). Another difference from OLP is that gene expression microarrays and miRNA screenings showed an enrichment of CD4+ T cells in DLE lesions rather than CD8+ T cells that primarily promote TNF- α production (50). From a therapeutic perspective, thalidomide, an effective treatment for DLE, has long been believed to exert its anti-inflammatory effects by targeting the 3'-untranslated region (3'-UTR) of TNF- α mRNA and inhibiting TNF- α production by monocytes (51, 52). This concept is challenged by the above genetic research in addition to a recent review on the efficacy of thalidomide on DLE, which stated that thalidomide could not be considered to treat DLE by inhibiting TNF- α because of conflicting results from some studies (53). Furthermore, several case reports showed that skin symptoms suspected to be DLE or CLE developed after application of infliximab, adalimumab and bevacizumab (TNF- α inhibitors), indicating that TNF- α inhibitors may not be appropriate for the treatment of DLE (54–56). Therefore, the theory that thalidomide acts by inhibiting TNF- α production is questionable, and its anti-inflammatory effect may be exerted by modulating other inflammatory cytokines. In conclusion, differences in TNF- α levels and polymorphisms are a major difference between OLP and DLE. The isolated assessment of the sole cytokine, though of relevance, does not provide a comprehensive understanding of

the impact of inflammation on the disease. To design a more sensitive diagnostic modality, other cytokines with significant differences also need to be identified.

IL-10 in DLE

IL-10 gene maps to the junction of 1q31-q32. Similar to TNF- α , the IL-10 gene promoter is strongly polymorphic. In addition to the two microsatellites, three SNPs located at positions 1082 (G/A) (rs18000896), 819 (C/T) (rs1800871) and 592 (C/A) (rs1800872) generate three haplotypes (GCC, ACC and ATA), which are associated with the transcription rate of IL-10 and variability in IL-10 production (57, 58). IL-10 production levels are elevated in the GCC haplotype, relatively intermediate in the ACC haplotype, and low in the ATA haplotype (57, 59). Patients with the GG genotype at the -1082 position are referred to as the high IL10 producer group, due to the association with high IL-10 transcript levels (49). First, it can be inferred from the low level of TNF- α in DLE that the level of IL-10 expression may be high. It has been reported that IL-10 was constitutively expressed in keratinocytes; its expression was augmented by ultraviolet exposure (60). Continuous irradiation did not only lead to IL-10 stimulation of dermal endothelial cells to produce pro-inflammatory cytokines and chemokines, but also acted as a risk factor for DLE, which linked high IL-10 production to DLE (61). As previously described, gene expression profiling techniques in DLE displayed CD4⁺ T cell-enrichment in which the Th1 response was predominant. Although IL-10 suppresses Th1 cells, Th1 cells are its main source in adaptive immunity (62). As Th1 cells dominate, IL-10 secretion surges. However, local overexpression of IL-10 disrupted the balance and induced inflammation instead of serving as an anti-inflammatory agent. After suggesting the relationship and indivisibility of TNF- α and IL-10, Suárez et al. (49) then launched a genotypic analysis of IL-10 using the same approach as the evaluation of TNF- α and concluded that the highest risk of developing DLE was found in individuals with a combined high IL10/low TNF- α genotype, which more likely resulted from overexpression of IL-10 rather than low production of TNF- α . In addition, cytokine interactions and the presence of a high IL-10/low TNF- α genotype suggest once again that the target of thalidomide for DLE is not TNF- α and that other TNF- α inhibitors are unsuitable for the treatment of DLE. Another study highlighted that thalidomide inhibited regulatory T cell (Treg) activity, which is a cell type in CD4⁺ T cell subsets and a source of IL-10 (63). A reduction of Treg response in DLE lesions would reduce IL-10 production. This may be the potential pharmacological mechanism of thalidomide in DLE.

IL-10 in OLP

An *in vitro* analysis of IL-10 mRNA and expression using 35S-labelled oligonucleotide probes and polymerase chain reaction

showed that cells capable of generating IL-10 mRNA were present in the original lesions of OLP (32). Gene polymorphisms for both TNF- α and IL-10 were included in a survey of a Chinese Han population by Bai et al. The results for TNF- α were as described previously, while similar results to other genetic studies were found for IL-10: the ATA haplotype was correlated with a low serum level of IL-10. More importantly, they identified a possible association between the ATA haplotype and OLP (44). Not coincidentally, haplotype ATA extracted from the 1082G/A, -819C/T, and -592C/A polymorphisms of the IL-10 gene were likewise found to be more prevalent in patients with OLP in the Arab population, with similar findings as in the Han population (46). However, this study was not conducted in the Thai population. Lu et al. demonstrated in their latest work that there was a tendency for decreased serum IL-10 levels in patients with OLP (64). All the above suggest that serum IL-10 levels are low in OLP (Figure 1).

The association between TNF- α and IL-10

Inflammatory cytokines do not act independently, but in a cytokine network. Suárez et al. (49) suggested that the role of cytokines may be profoundly constrained by the presence of other cytokines, particularly in the case of TNF- α and interleukin-10, which have complex and mainly opposing roles. IL-10 is a multi-functional cytokine with prominently anti-inflammatory effects, that inhibits the synthesis of many other cytokines, notably TNF- α (65). Its mechanism is to limit collateral damage to host cells and tissues during the inflammatory response and to maintain the balance between the inflammatory and anti-inflammatory responses (66). It is considered to be an important factor in peripheral tolerance and a major suppressor of inflammation; it is involved in the inactivation of monocytes and macrophages, inhibition of T helper 1 (Th1) cells and promotion of B-cell proliferation and differentiation (67). The most significant of these is the inactivation of monocytes and macrophages, thereby inhibiting TNF- α release from these cells (66). Moreover, to maintain the balance, IL-10 expression can in turn be attenuated or compromised by the cytokines produced by these cells (68). For example, TNF- α modulated the differentiation state and expression of IL-10 in human CD4⁺ T cell subsets, which was proven by IL-10 production enhancement after applying therapeutic antibodies blocking TNF- α (69).

Other indexes and methods for further diagnosis of OLP

Compared to DLE, OLP has received more research attention. In recent years, diagnostic indexes with satisfactory sensitivity and specificity have been frequently reported. OLP is a well-defined precancerous condition. The less irritation to the lesion area, the

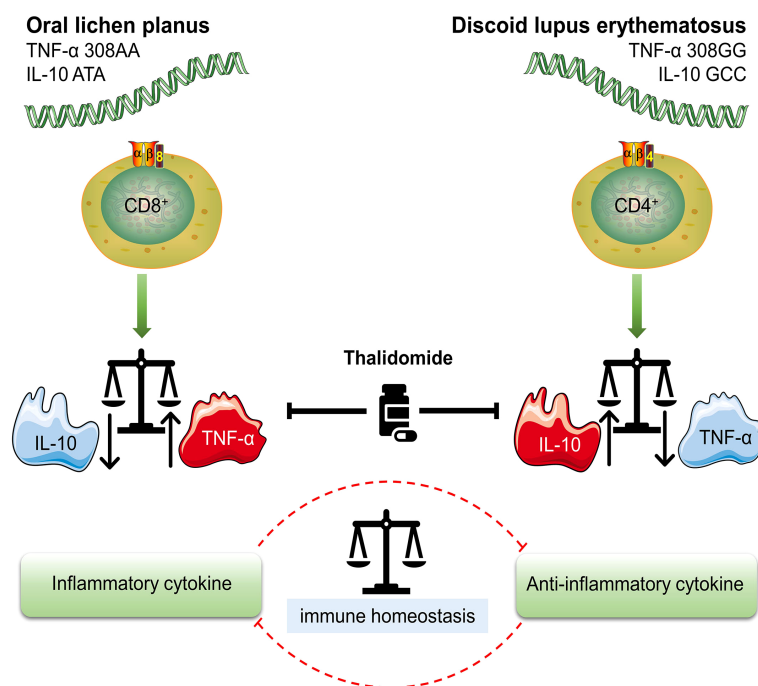


FIGURE 1

Different genotypes of OLP (oral lichen planus) and DLE (discoid lupus erythematosus) High TNF- α (TNF- α 308AA)/low IL-10 (IL-10 ATA) genotype is characterized by a higher production of TNF- α and is more likely to result in OLP. TNF- α is mainly secreted by CD8+ cytotoxic T cells, which are also the most OLP-associated T cells. High IL-10 (IL-10 GCC)/low TNF- α (TNF- α 308GG) genotype suggests increased risk and prevalence of DLE. The overexpression of IL-10 is associated with the enrichment of CD4+ T cell subsets. Treg (regulatory T cell) and Th1 (T helper 1 cell), two typical CD4+ T cell subsets, are sources of IL-10 in DLE. Either an increase or decrease in TNF- α and IL-10 leads to an imbalance in the immune system, which ultimately initiates the onset of disease. Thalidomide is a multi-targeted IMiD (immunomodulatory drug) that inhibits both TNF- α and IL-10. The inhibition of IL-10 may be the underlying pharmacological mechanism in the treatment of DLE.

better the control of disease progression. Therefore, alternative diagnostic methods should avoid direct irritation of the lesion area. In order to achieve a minimally invasive to non-invasive solution, whole saliva can be collected and screened for salivary TNF- α levels by ELISA. There are documented statistics of higher levels of TNF- α in saliva compared to that in the serum in patients with OLP, suggesting that measuring this biomarker in saliva not only does not provoke precancerous lesions but may also be more prominent than in serum (70). Another typical pro-inflammatory cytokine, IL-17, has been found to have a diagnostic role similar to that of TNF- α in the serum and saliva of OLP patients (71, 72). Other researchers have also used saliva samples to identify fibrinogen fragment D, complement component C3c, and cystatin SA as putative biomarkers for the screening and diagnosis of OLP (73). In the recent literature, researchers (74, 75) first concluded that there is an association between serum/saliva levels of multiple pro-inflammatory cytokines and OLP pathogenesis, and then suggested the use of saliva and serum C-Reactive Protein (CRP) and total antioxidant capacity (TAC) in the assessment of OLP development.

In addition, if the diagnosis of OLP is accomplished after the exclusion of DLE, the HSP test can be reintroduced at this time to

corroborate the genetic test result of TNF- α for further evaluation of the disease. The HSP test is mainly valuable in determining the prognosis of the disease and for use in treatment planning. Because HSP60 expression and HSP70 expression were increased in erosive and atrophic subtypes of OLP, which are more prone to carcinogenesis, they are known as the “fingerprints” of a generalized immune response in immune-mediated diseases (27). Therefore, screening of serum levels of HSP60 and HSP70 aids further differentiation and detection of erosive OLP and non-erosive OLP (Table 2).

Discussion

Both OLP and DLE have been identified as precancerous conditions (76, 77). The risk of malignant transformation of OLP to oral squamous cell carcinoma has been estimated to be 1–2% (5). In the recent international consensus report on nomenclature and classification of oral potentially malignant disorders (OPMDs), DLE was also described as an independent disorder in the categories (78). Their malignant potential places high emphasis on early diagnosis and treatment. However, the

TABLE 2 Samples and assay indexes for differential diagnosis.

Disease	Peripheral blood		Whole saliva	
	DLE	OLP	DLE	OLP
TNF- α	↓	↑	\	↑
IL-10	↑	↓	\	\
allele A of TNF- α (-308 A>G) (rs1800629)	\	↑	\	\
allele G of IL-10 (-1082 A>G) (rs18000896)	↑	\	\	\
IL-17	\	↑	\	↑
fibrinogen fragment D	\	\	\	↑
Complement component C3c	\	\	\	↑
cystatin SA	\	\	\	↓
TAC	\	↓	\	↓
CRP	\	↑	\	↑
HSP60	\	↑	\	\
HSP70	\	↑	\	\

↓, down-regulated; ↑, up-regulated; \, no available.

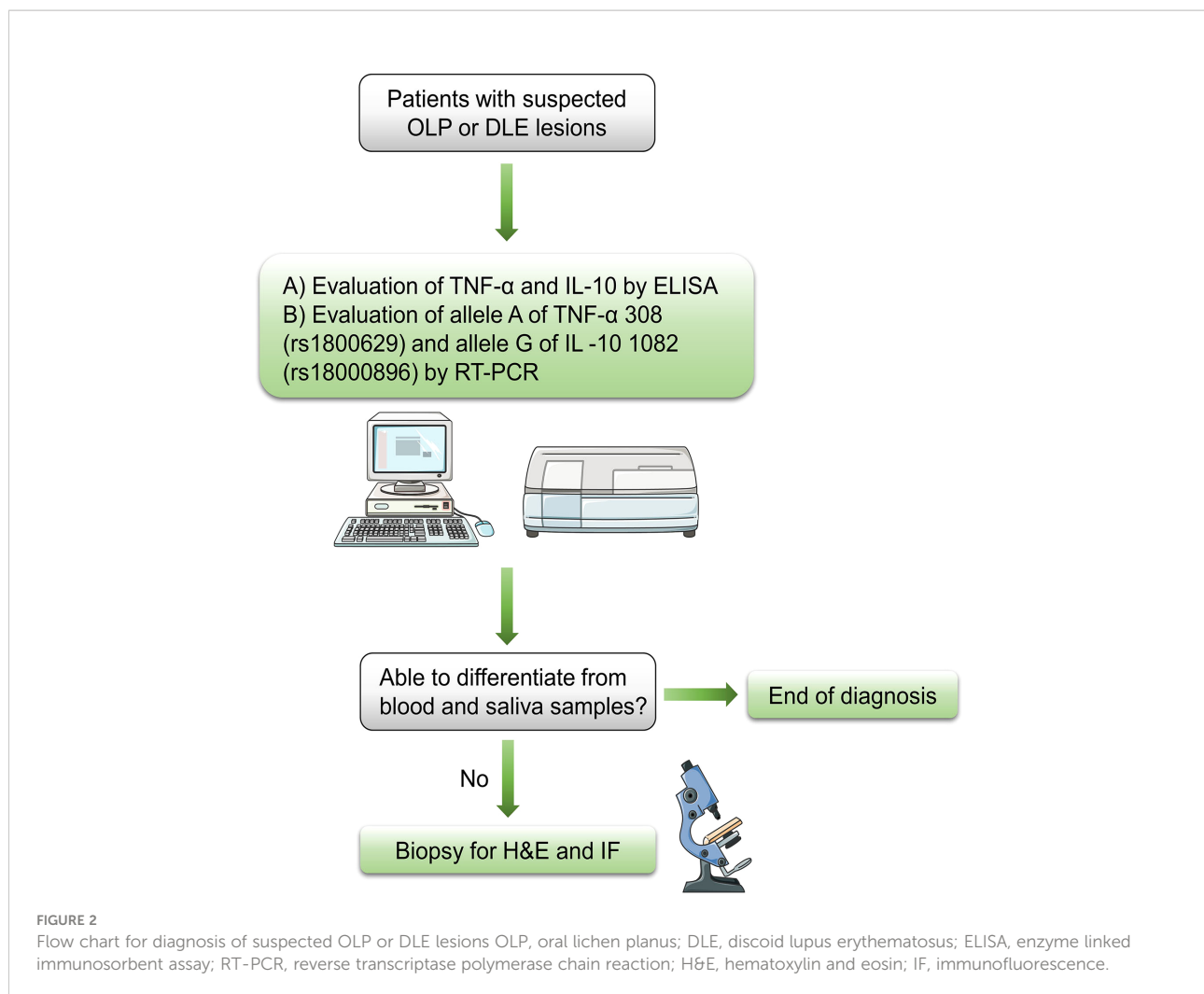
specific genes responsible for OLP or DLE have not yet been identified. Although some studies are probing for genetic susceptibility and biomarkers using bioinformatic approaches, only an approximate range of candidate gene regions and differentially expressed genes have been identified, which cannot yet be applied in clinical practice (79, 80).

Since the clinical manifestations and histopathological features of both diseases are extremely similar, attention has focused on immunological exploration in recent years. Pathologists have adopted DIF as an adjunctive diagnostic tool. Sun et al. (81) suggested that DIF on fresh frozen tissue from the lesion site of OLP or DLE was preferred. The presence of DLE can be determined by observing the lupus band. However, the reliability of the lupus band test is being questioned. It has been found that patients with DLE scarcely fulfill four or more criteria for SLE, with the lupus band test as one of the criteria (82). Nowadays, serologic testing has achieved great progress. The advantages lie in the rapid results and the clear indication of further treatment. Immunohistochemistry of HSPs in OLP is a potential test option, but some researchers question its practicability (27). Again, there is no evidence that serum and mRNA levels of HSPs in DLE show similarly significant changes as observed in OLP. On the other hand, studies at the molecular level have enabled understanding of inflammation to surpass the limitations of type discrimination among inflammatory factors, initiating tools that reflect the nature of inflammation for clinical diagnosis and epidemiological studies.

Because they modulate inflammatory and anti-inflammatory responses, TNF- α and IL-10 play pivotal roles in the pathogenesis of DLE and OLP, both diseases mediated by the immune system. Moreover, because of the simultaneous comparison of the two diseases, which is superior to the characteristic lupus band test for DLE and the HSP test for

OLP, the two cytokines also exhibit considerable potential for differential diagnosis. We believe that the serum level of both cytokines can be evaluated qualitatively by conventional methods such as immunofluorescence and enzyme linked immunosorbent assay (ELISA), and then the frequency of their alleles can be determined qualitatively by typing gene polymorphisms using a polymerase chain reaction (PCR) with sequence specific primers, i.e., allele A of TNF- α (-308 A>G) and allele G of IL-10 (-1082 A>G). This novel diagnostic scheme is expected to facilitate the screening of DLE from the previous histopathological classification of OLLs or, more directly, to confirm suspected cases as DLE or OLP. Therefore, the protocol for the admission of patients is described as below: the initial step is the exclusion of other definable diseases or impairments based on evidence from the initial clinical examination, followed by the above recommended methods for ancillary diagnosis. Given the invasive nature of surgical biopsy and the potentially malignant nature of OLP and DLE, the lesional biopsy is the last diagnostic option to be considered (Figure 2).

Although the findings of this study have a number of important implications for future practice, the generalizability of the novel diagnostic scheme is subject to certain limitations. The expression patterns of inflammatory factors may be extremely diverse due to the induction of other inflammatory mediators and individual genetic predisposition. For instance, it is doubtful whether serum levels of IL-10 are reduced in patients with OLP, since two studies observed elevated serum levels of IL-10 in patients with OLP a decade ago (83, 84). It was also reported that serum levels of IL-10 were lower in patients with DLE than healthy people (85). Therefore, more accurate data from laboratory tests and more extensive evidence from evidence-based medicine are required to assist in the establishment of greater accuracy of the diagnostic scheme in



the future. Until the real pathogenesis of the two diseases is ascertained, research targeting TNF- α and IL-10 will not only facilitate the discovery of the pathogenesis of DLE and OLP, but also serve as an alternative and superior diagnostic option.

Author contributions

XFZ and SYW: Administrative, technical, and material support; study supervision; data acquisition; conceptualization and design of the manuscript. RCW, XFZ and SYW: Manuscript writing, reviewing, and revision. All authors approved the final manuscript and agreed to be accountable for all aspects of the work. Furthermore, all authors ensured that questions related to the accuracy or integrity of any part of the work were appropriately investigated and resolved.

Funding

The National Natural Science Foundation of China (NSFC) (Grant Nos. 82002877) and Young Talent Project of Sichuan Provincial People's Hospital (No. 2016QN15) contributed to the design of the study, the collection, analysis, and interpretation of data, and writing the manuscript.

Conflict of interest

The authors declare that the research was conducted in the absence of any commercial or financial relationships that could be construed as a potential conflict of interest.

Publisher's note

All claims expressed in this article are solely those of the authors and do not necessarily represent those of their affiliated

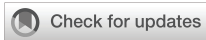organizations, or those of the publisher, the editors and the reviewers. Any product that may be evaluated in this article, or claim that may be made by its manufacturer, is not guaranteed or endorsed by the publisher.

References

- Oke V, Wahren-Herlenius M. Cutaneous lupus erythematosus: clinical aspects and molecular pathogenesis. *J Intern Med* (2013) 273(6):544–54. doi: 10.1111/joim.12057
- McParland H. Oral lichenoid and lichen planus-like lesions. *Prim Dent J* (2016) 5(1):34–9. doi: 10.1177/205016841600500103
- Kamath VV, Setlur K, Yerlagudha K. Oral lichenoid lesions - a review and update. *Indian J Dermatol* (2015) 60(1):102. doi: 10.4103/0019-5154.147830
- Carrozzo M, Porter S, Mercadante V, Fedele S. Oral lichen planus: A disease or a spectrum of tissue reactions? types, causes, diagnostic algorithms, prognosis, management strategies. *Periodontol* (2019) 80(1):105–25. doi: 10.1111/prd.12260
- Gonzalez-Moles MA, Scully C, Gil-Montoya JA. Oral lichen planus: controversies surrounding malignant transformation. *Oral Dis* (2008) 14(3):229–43. doi: 10.1111/j.1601-0825.2008.01441.x
- Dhingra M, Bhalla M, Thami GP, Mittal P. Metastasizing squamous cell carcinoma arising from chronic discoid lupus erythematosus plaque of recent onset. *Indian J Dermatol Venereol Leprol* (2011) 77(5):626. doi: 10.4103/0378-6323.84078
- Al-Hashimi I, Schiffer M, Lockhart PB, Wray D, Brennan M, Migliorati CA, et al. Oral lichen planus and oral lichenoid lesions: diagnostic and therapeutic considerations. *Oral Surg Oral Med Oral Pathol Oral Radiol Endod* (2007) 103 Suppl:S25.e1–12. doi: 10.1016/j.tripleo.2006.11.001
- van der Meij EH, Mast H, van der Waal I. The possible premalignant character of oral lichen planus and oral lichenoid lesions: a prospective five-year follow-up study of 192 patients. *Oral Oncol* (2007) 43(8):742–8. doi: 10.1016/j.oraloncology.2006.09.006
- Lu R, Zhou G. Oral lichenoid lesions: Is it a single disease or a group of diseases? *Oral Oncol* (2021) 117:105188. doi: 10.1016/j.oraloncology.2021.105188
- Scully C, Carrozzo M. Oral mucosal disease: Lichen planus. *Br J Oral Maxillofac Surg* (2008) 46(1):15–21. doi: 10.1016/j.bjoms.2007.07.199
- Chanprapaph K, Pomsong C, Tankunakorn J, Eden C, Suchonwanit P, Rutnin S. Comparative analyses of clinical features, histopathology, and CD123 immunohistochemistry of oral lupus erythematosus, lichen planus, and other lichenoid lesions. *Dermatology* (2022) 238(3):464–75. doi: 10.1159/000517971
- Togliatto M, Carrozzo M, Conrotto D, Pagano M, Gandolfo S. [Oral lupus erythematosus. description and analysis of 11 cases]. *Minerva Stomatol* (2000) 49 (1-2):35–40.
- Müller S. Oral lichenoid lesions: distinguishing the benign from the deadly. *Modern Pathology* (2017) 30(1):S54–67. doi: 10.1038/modpathol.2016.121
- Nieboer C. The reliability of immunofluorescence and histopathology in the diagnosis of discoid lupus erythematosus and lichen planus. *Br J Dermatol* (1987) 116(2):189–98. doi: 10.1111/j.1365-2133.1987.tb05811.x
- Schlosser BJ. Lichen planus and lichenoid reactions of the oral mucosa. *Dermatol Ther* (2010) 23(3):251–67. doi: 10.1111/j.1529-8019.2010.01322.x
- Chiorean R, Mahler M, Sitaru C. Molecular diagnosis of autoimmune skin diseases. *Rom J Morphol Embryol* (2014) 55(3 Suppl):1019–33.
- Lourenço SV, de Carvalho FR, Boggio P, Sotto MN, Vilela MA, Rivitti EA, et al. Lupus erythematosus: clinical and histopathological study of oral manifestations and immunohistochemical profile of the inflammatory infiltrate. *J Cutan Pathol* (2007) 34(7):558–64. doi: 10.1111/j.1600-0560.2006.00652.x
- Schiødt M, Holmstrup P, Dabelsteen E, Ullman S. Deposits of immunoglobulins, complement, and fibrinogen in oral lupus erythematosus, lichen planus, and leukoplakia. *Oral Surg Oral Med Oral Pathol* (1981) 51 (6):603–8. doi: 10.1016/s0030-4220(81)80010-2
- Cheng YS, Gould A, Kurago Z, Fantasia J, Muller S. Diagnosis of oral lichen planus: a position paper of the American academy of oral and maxillofacial pathology. *Oral Surg Oral Med Oral Pathol Oral Radiol* (2016) 122(3):332–54. doi: 10.1016/j.oooo.2016.05.004
- Hashimoto T, Fukuda A, Himejima A, Morita S, Tsuruta D, Koga H, et al. Ten cases of severe oral lichen planus showing granular C3 deposition in oral mucosal basement membrane zone. *Eur J Dermatol* (2015) 25(6):539–47. doi: 10.1684/ejd.2015.2655
- Khudhur AS, Di Zenzo G, Carrozzo M. Oral lichenoid tissue reactions: diagnosis and classification. *Expert Rev Mol Diagn* (2014) 14(2):169–84. doi: 10.1586/14737159.2014.888953
- Hung T, Ian Crawford R, Martinka M. Degree of histologic inflammation in lupus erythematosus and direct immunofluorescence results: red and inflamed lesions do not increase the chances of getting a bright band. *J Cutan Med Surg* (2013) 17(1):22–6. doi: 10.2310/7750.2012.12032
- Lavanya N, Jayanthi P, Rao UK, Ranganathan K. Oral lichen planus: An update on pathogenesis and treatment. *J Oral Maxillofac Pathol* (2011) 15(2):127–32. doi: 10.4103/0973-029X.84474
- Finlayson-Trick E, Connors J, Stadnyk A, Van Limbergen J. Regulation of antimicrobial pathways by endogenous heat shock proteins in gastrointestinal disorders. *Gastrointestinal Disord* (2019) 1(1):39–56. doi: 10.3390/gidisord1010005
- Di P, Gao Y. [Studies of heat shock protein 60 and heat shock protein 70 in oral lichen planus]. *Zhonghua Kou Qiang Yi Xue Za Zhi* (2003) 38(4):275–8. doi: 10.3760/j.issn:1002-0098.2003.04.013
- Tyagi N, Shetty DC, Urs AB. Altered expression of HSP70 in oral lichen planus. *J Oral Maxillofac Pathol* (2012) 16(2):189–94. doi: 10.4103/0973-029X.98497
- Mohtasham N, Shahabinejad M, Kafiroudi S, Mohajertehran F. Evaluation of the altered tissue expression of HSP60 and HSP70 genes in oral and cutaneous lichen planus compared to normal healthy tissues. *Indian J Dermatol* (2021) 66 (6):591–7. doi: 10.4103/ijd.ijd_1060_20
- Chaiyapit P, Kafrawy AH, Miles DA, Zunt SL, Van Dis ML, Gregory RL. Oral lichen planus: an immunohistochemical study of heat shock proteins (HSPs) and cytokeratins (CKs) and a unifying hypothesis of pathogenesis. *J Oral Pathol Med* (1999) 28(5):210–5. doi: 10.1111/j.1600-0714.1999.tb02026.x
- Bayramgürler D, Ozkara SK, Apaydin R, Erçin C, Bilen N. Heat shock proteins 60 and 70 expression of cutaneous lichen planus: comparison with normal skin and psoriasis vulgaris. *J Cutan Pathol* (2004) 31(9):586–94. doi: 10.1111/j.0303-6987.2004.00234.x
- Balkwill F. TNF-alpha in promotion and progression of cancer. *Cancer Metastasis Rev* (2006) 25(3):409–16. doi: 10.1007/s10555-006-9005-3
- Vassalli P. The pathophysiology of tumor necrosis factors. *Annu Rev Immunol* (1992) 10:411–52. doi: 10.1146/annurev.iy.10.040192.002211
- Simark-Mattsson C, Bergenholtz G, Jontell M, Eklund C, Seymour GJ, Sugerman PB, et al. Distribution of interleukin-2, -4, -10, tumour necrosis factor-alpha and transforming growth factor-beta mRNAs in oral lichen planus. *Arch Oral Biol* (1999) 44(6):499–507. doi: 10.1016/S0003-9969(99)00013-8
- Sklavounou-Andrikopoulou A, Chrysomali E, Iakovou M, Garinis GA, Karameris A. Elevated serum levels of the apoptosis related molecules TNF-alpha, Fas/Apo-1 and bcl-2 in oral lichen planus. *J Oral Pathol Med* (2004) 33 (7):386–90. doi: 10.1111/j.1600-0714.2004.00221.x
- Rhodus NL, Cheng B, Myers S, Bowles W, Ho V, Ondrey F. A comparison of the pro-inflammatory, NF-kappaB-dependent cytokines: TNF-alpha, IL-1-alpha, IL-6, and IL-8 in different oral fluids from oral lichen planus patients. *Clin Immunol* (2005) 114(3):278–83. doi: 10.1016/j.clim.2004.12.003
- Carrozzo M, Ubaldi de Capei M, Dametto E, Fasano ME, Arduino P, Brocchetto R, et al. Tumor necrosis factor-alpha and interferon-gamma polymorphisms contribute to susceptibility to oral lichen planus. *J Invest Dermatol* (2004) 122(1):87–94. doi: 10.1046/j.0022-202X.2003.22108.x
- Mehta AK, Gracias DT, Croft M. TNF activity and T cells. *Cytokine* (2018) 101:14–8. doi: 10.1016/j.cyto.2016.08.003

37. Jungell P, Kontinen YT, Nortamo P, Malmström M. Immunoelectron microscopic study of distribution of T cell subsets in oral lichen planus. *Scand J Dent Res* (1989) 97(4):361–7. doi: 10.1111/j.1600-0722.1989.tb01624.x
38. Lodi G, Scully C, Carrozzo M, Griffiths M, Sugerman PB, Thongprasom K. Current controversies in oral lichen planus: report of an international consensus meeting. part 1. viral infections and etiopathogenesis. *Oral Surg Oral Med Oral Pathol Oral Radiol Endod* (2005) 100(1):40–51. doi: 10.1016/j.tripleo.2004.06.077
39. Old LJ. Tumor necrosis factor (TNF). *Science* (1985) 230(4726):630–2. doi: 10.1126/science.2413547
40. Hajeer AH, Hutchinson IV. TNF-alpha gene polymorphism: clinical and biological implications. *Microsc Res Tech* (2000) 50(3):216–28. doi: 10.1002/1097-0029(20000801)50:3<216::AID-JEMT5>3.0.CO;2-Q
41. Brinkman BM, Zuijdest D, Kaijzel EL, Breedveld FC, Verweij CL. Relevance of the tumor necrosis factor alpha (TNF alpha) -308 promoter polymorphism in TNF alpha gene regulation. *J Inflamm* (1995) 46(1):32–41.
42. Kroeger KM, Steer JH, Joyce DA, Abraham LJ. Effects of stimulus and cell type on the expression of the -308 tumor necrosis factor promoter polymorphism. *Cytokine* (2000) 12(2):110–9. doi: 10.1006/cyto.1999.0529
43. Zhou Y, Vieira AR. Association between TNFα - 308 G/A polymorphism and oral lichen planus (OLP): a meta-analysis. *J Appl Oral Sci* (2018) 26:e20170184. doi: 10.1590/1678-7757-2017-0184
44. Bai J, Jiang L, Lin M, Zeng X, Wang Z, Chen Q. Association of polymorphisms in the tumor necrosis factor-alpha and interleukin-10 genes with oral lichen planus: a study in a chinese cohort with han ethnicity. *J Interferon Cytokine Res* (2009) 29(7):381–8. doi: 10.1089/jir.2008.0089
45. Kimkong I, Hirankarn N, Nakkuntod J, Kitkumthorn N. Tumor necrosis factor-alpha gene polymorphisms and susceptibility to oral lichen planus. *Oral Dis* (2011) 17(2):206–9. doi: 10.1111/j.1601-0825.2010.01722.x
46. Al-Mohaya MA, Al-Harthi F, Arfin M, Al-Asmari A. TNF-α, TNF-β and IL-10 gene polymorphism and association with oral lichen planus risk in Saudi patients. *J Appl Oral Sci* (2015) 23(3):295–301. doi: 10.1590/1678-775720150075
47. Brant JM, Vasconcelos AC, Rodrigues LV. Role of apoptosis in erosive and reticular oral lichen planus exhibiting variable epithelial thickness. *Braz Dent J* (2008) 19(3):179–85. doi: 10.1590/S0103-64402008000300001
48. Werth VP, Zhang W, Dortzbach K, Sullivan K. Association of a promoter polymorphism of tumor necrosis factor-alpha with subacute cutaneous lupus erythematosus and distinct photoregulation of transcription. *J Invest Dermatol* (2000) 115(4):726–30. doi: 10.1046/j.1523-1747.2000.00118.x
49. Suárez A, López P, Mozo L, Gutiérrez C. Differential effect of IL10 and TNF {alpha} genotypes on determining susceptibility to discoid and systemic lupus erythematosus. *Ann Rheum Dis* (2005) 64(11):1605–10. doi: 10.1136/ard.2004.035048
50. Solé C, Gimenez-Barcons M, Ferrer B, Ordi-Ros J, Cortés-Hernández J. Microarray study reveals a transforming growth factor-β-dependent mechanism of fibrosis in discoid lupus erythematosus. *Br J Dermatol* (2016) 175(2):302–13. doi: 10.1111/bjd.14539
51. Moreira AL, Sampaio EP, Zmuidzinis A, Frindt P, Smith KA, Kaplan G. Thalidomide exerts its inhibitory action on tumor necrosis factor alpha by enhancing mRNA degradation. *J Exp Med* (1993) 177(6):1675–80. doi: 10.1084/jem.177.6.1675
52. Deng L, Ding W, Granstein RD. Thalidomide inhibits tumor necrosis factor-alpha production and antigen presentation by langerhans cells. *J Invest Dermatol* (2003) 121(5):1060–5. doi: 10.1046/j.1523-1747.2003.12565.x
53. Domingo S, Solé C, Moliné T, Ferrer B, Ordi-Ros J, Cortés-Hernández J. Efficacy of thalidomide in discoid lupus erythematosus: Insights into the molecular mechanisms. *Dermatology* (2020) 236(5):467–76. doi: 10.1159/000508672
54. Cemil BC, Atas H, Canpolat F, Akca Y, Sasmaz R. Infliximab-induced discoid lupus erythematosus. *Lupus* (2013) 22(5):515–8. doi: 10.1177/0961203313479423
55. Asarch A, Gottlieb AB, Lee J, Masterpol KS, Scheinman PL, Stadecker MJ, et al. Lichen planus-like eruptions: an emerging side effect of tumor necrosis factor-alpha antagonists. *J Am Acad Dermatol* (2009) 61(1):104–11. doi: 10.1016/j.jaad.2008.09.032
56. Cleaver N, Ramirez J, Gildenberg S. Cutaneous lupus erythematosus in a patient undergoing intravitreal bevacizumab injections: case report and review of the literature. *J Drugs Dermatol* (2013) 12(9):1052–5.
57. Turner DM, Williams DM, Sankaran D, Lazarus M, Sinnott PJ, Hutchinson IV. An investigation of polymorphism in the interleukin-10 gene promoter. *Eur J Immunogenet* (1997) 24(1):1–8. doi: 10.1111/j.1365-2370.1997.tb00001.x
58. Mörmann M, Rieth H, Hua TD, Assouh C, Roupelieva M, Hu SL, et al. Mosaics of gene variations in the interleukin-10 gene promoter affect interleukin-10 production depending on the stimulation used. *Genes Immun* (2004) 5(4):246–55. doi: 10.1038/sj.gene.6364073
59. Koss K, Satsangi J, Fanning GC, Welsh KI, Jewell DP. Cytokine (TNF alpha, LT alpha and IL-10) polymorphisms in inflammatory bowel diseases and normal controls: differential effects on production and allele frequencies. *Genes Immun* (2000) 1(3):185–90. doi: 10.1038/sj.gene.6363657
60. Grewe M, Gyufko K, Krutmann J. Interleukin-10 production by cultured human keratinocytes: regulation by ultraviolet b and ultraviolet A1 radiation. *J Invest Dermatol* (1995) 104(1):3–6. doi: 10.1111/1523-1747.ep12613446
61. Scholzen T, Hartmeyer M, Fastrich M, Brzoska T, Becher E, Schwarz T, et al. Ultraviolet light and interleukin-10 modulate expression of cytokines by transformed human dermal microvascular endothelial cells (HMEC-1). *J Invest Dermatol* (1998) 111(1):50–6. doi: 10.1046/j.1523-1747.1998.00229.x
62. O'Garra A, Vieira P. T(H)1 cells control themselves by producing interleukin-10. *Nat Rev Immunol* (2007) 7(6):425–8. doi: 10.1038/nri2097
63. Skórka K, Bhattacharya N, Wlasiuk P, Kowal M, Mertens D, Dmoszyńska A, et al. Thalidomide regulation of NF-κB proteins limits tregs activity in chronic lymphocytic leukemia. *Adv Clin Exp Med* (2014) 23(1):25–32. doi: 10.17219/acem/37018
64. Lu R, Zhang J, Sun W, Du G, Zhou G. Inflammation-related cytokines in oral lichen planus: an overview. *J Oral Pathol Med* (2015) 44(1):1–14. doi: 10.1111/jop.12142
65. Asadullah K, Sterry W, Stephanek K, Jasulaitis D, Leupold M, Audring H, et al. IL-10 is a key cytokine in psoriasis. proof of principle by IL-10 therapy: a new therapeutic approach. *J Clin Invest* (1998) 101(4):783–94. doi: 10.1172/JCI1476
66. Neumann C, Scheffold A, Rutz S. Functions and regulation of T cell-derived interleukin-10. *Semin Immunol* (2019) 44:101344. doi: 10.1016/j.smim.2019.101344
67. Pestka S, Krause CD, Sarkar D, Walter MR, Shi Y, Fisher PB. Interleukin-10 and related cytokines and receptors. *Annu Rev Immunol* (2004) 22:929–79. doi: 10.1146/annurev.immunol.22.012703.104622
68. Saraiva M, O'Garra A. The regulation of IL-10 production by immune cells. *Nat Rev Immunol* (2010) 10(3):170–81. doi: 10.1038/nri2711
69. Evans HG, Roostalu U, Walter GJ, Gullick NJ, Frederiksen KS, Roberts CA, et al. TNF-α blockade induces IL-10 expression in human CD4+ T cells. *Nat Commun* (2014) 5:3199. doi: 10.1038/ncomms4199
70. Mozaffari HR, Ramezani M, Mahmoudiahmadabadi M, Omidpanah N, Sadeghi M. Salivary and serum levels of tumor necrosis factor-alpha in oral lichen planus: a systematic review and meta-analysis study. *Oral Surg Oral Med Oral Pathol Oral Radiol* (2017) 124(3):e183–e9. doi: 10.1016/j.oooo.2017.06.117
71. Gueiros LA, Araújo T, Souza T, Vieira CL, Gomez RS, Almeida OP, et al. IL17A polymorphism and elevated IL17A serum levels are associated with oral lichen planus. *Oral Dis* (2018) 24(3):377–83. doi: 10.1111/odi.12718
72. Abdeldayem E, Rashed L, Ali S. Salivary expression of lncRNA DQ786243 and IL-17 in oral lichen planus: case-control study. *BMC Oral Health* (2022) 22(1):240. doi: 10.1186/s12903-022-02277-0
73. Talungchit S, Buajeeb W, Lerdtripop C, Surarit R, Chairatvit K, Roytrakul S, et al. Putative salivary protein biomarkers for the diagnosis of oral lichen planus: a case-control study. *BMC Oral Health* (2018) 18(1):42. doi: 10.1186/s12903-018-0504-8
74. Hatami M, Rezaei M, Sadeghi M, Tadakamadla J, Pekiner FN, Mozaffari HR. A systematic review and meta-analysis on serum and salivary levels of total antioxidant capacity and c-reactive protein in oral lichen planus patients. *Arch Oral Biol* (2022) 140:105445. doi: 10.1016/j.archoralbio.2022.105445
75. Wang J, Yang J, Wang C, Zhao Z, Fan Y. Systematic review and meta-analysis of oxidative stress and antioxidant markers in oral lichen planus. *Oxid Med Cell Longev* (2021) 2021:9914652. doi: 10.1155/2021/9914652
76. Kramer IR, Lucas RB, Pindborg JJ, Sobin LH. Definition of leukoplakia and related lesions: an aid to studies on oral precancer. *Oral Surg Oral Med Oral Pathol* (1978) 46(4):518–39. doi: 10.1016/0030-4220(78)90383-3
77. Sugerman PB, Savage NW, Walsh LJ, Zhao ZZ, Zhou XJ, Khan A, et al. The pathogenesis of oral lichen planus. *Crit Rev Oral Biol Med* (2002) 13(4):350–65. doi: 10.1177/154411130201300405
78. Warnakulasuriya S, Kujan O, Aguirre-Uribe JM, Bagan JV, González-Moles M, Kerr AR, et al. Oral potentially malignant disorders: A consensus report from an international seminar on nomenclature and classification, convened by the WHO collaborating centre for oral cancer. *Oral Dis* (2021) 27(8):1862–80. doi: 10.1111/odi.13704
79. Wang Z, Yao H, Cui B, Ning G, Tang GY. Genetic linkage analysis of oral lichen planus in a Chinese family. *Genet Mol Res* (2011) 10(3):1427–33. doi: 10.4238/vol10-3gmr1137

80. Xiang M, Chen Q, Feng Y, Wang Y, Wang J, Liang J, et al. Bioinformatic analysis of key biomarkers and immune infiltration of skin biopsy in discoid lupus erythematosus. *Lupus* (2021) 30(5):807–17. doi: 10.1177/0961203321992434
81. Sun S, Zhong B, Li W, Jin X, Yao Y, Wang J, et al. Immunological methods for the diagnosis of oral mucosal diseases. *Br J Dermatol* (2019) 181(1):23–36. doi: 10.1111/bjd.17589
82. Tan EM, Cohen AS, Fries JF, Masi AT, McShane DJ, Rothfield NF, et al. The 1982 revised criteria for the classification of systemic lupus erythematosus. *Arthritis Rheumatol* (1982) 25(11):1271–7. doi: 10.1002/art.1780251101
83. Dan H, Liu W, Wang J, Wang Z, Wu R, Chen Q, et al. Elevated IL-10 concentrations in serum and saliva from patients with oral lichen planus. *Quintessence Int* (2011) 42(2):157–63.
84. Pekiner FN, Demirel GY, Borahan MO, Ozbayrak S. Cytokine profiles in serum of patients with oral lichen planus. *Cytokine* (2012) 60(3):701–6. doi: 10.1016/j.cyto.2012.08.007
85. Antiga E, Del Bianco E, Difonzo E, Fabbri P, Caproni M. Serum levels of the regulatory cytokines transforming growth factor- β and interleukin-10 are reduced in patients with discoid lupus erythematosus. *Lupus* (2011) 20(6):556–60. doi: 10.1177/0961203310392424



OPEN ACCESS

EDITED BY

Zhi Wang,
Sun Yat-sen University, China

REVIEWED BY

Alina Popp,
Carol Davila University of Medicine
and Pharmacy, Romania
Yasuhiro Mouri,
Tokushima University, Japan
Tong Wu,
Sun Yat-sen University, China

*CORRESPONDENCE

Lu Jiang
jianglu@scu.edu.cn
Wei Wei
ww8075@126.com

[†]These authors share first authorship

SPECIALTY SECTION

This article was submitted to
Mucosal Immunity,
a section of the journal
Frontiers in Immunology

RECEIVED 13 June 2022

ACCEPTED 26 July 2022

PUBLISHED 16 August 2022

CITATION

Zhang T, Hou F, Liu D, Zhou H, Sun Y,
Deng X, Xu Y, Xiao Y, Wang X, Wu C,
Meng Y, Yuan P, Qiu X, Ye L, Liang Y,
Wei W and Jiang L (2022) Association
of Hashimoto's thyroiditis and anti-
thyroid antibodies with oral lichen
planus: A cross-sectional study.
Front. Immunol. 13:967988.
doi: 10.3389/fimmu.2022.967988

COPYRIGHT

© 2022 Zhang, Hou, Liu, Zhou, Sun,
Deng, Xu, Xiao, Wang, Wu, Meng, Yuan,
Qiu, Ye, Liang, Wei and Jiang. This is an
open-access article distributed under
the terms of the [Creative Commons
Attribution License \(CC BY\)](https://creativecommons.org/licenses/by/4.0/). The use,
distribution or reproduction in other
forums is permitted, provided the
original author(s) and the copyright
owner(s) are credited and that the
original publication in this journal is
cited, in accordance with accepted
academic practice. No use,
distribution or reproduction is
permitted which does not comply with
these terms.

Association of Hashimoto's thyroiditis and anti-thyroid antibodies with oral lichen planus: A cross-sectional study

Tianyu Zhang^{1†}, Feifei Hou^{1†}, Dan Liu¹, Hangfan Zhou¹,
Yutong Sun¹, Xiaoting Deng¹, Yiming Xu¹, Yanxuan Xiao¹,
Xianwen Wang¹, Chuanji Wu¹, Yang Meng¹, Peiyang Yuan¹,
Xuemei Qiu¹, Lu Ye¹, Yuye Liang¹, Wei Wei^{2*} and Lu Jiang^{1*}

¹State Key Laboratory of Oral Diseases, National Clinical Research Center for Oral Diseases, Department of Oral Medicine, West China Hospital of Stomatology, Sichuan University, Chengdu, China, ²Department of Emergency, West China Hospital, Sichuan University, Chengdu, China

Hashimoto's thyroiditis (HT) and its autoantibodies may be associated with oral lichen planus (OLP). In this cross-sectional study, we aimed to assess the relationship among HT, auto-anti-thyroid antibodies, and OLP in a Chinese population of 247 patients with oral lichen planus. Clinical manifestations of OLP were evaluated using the Thongprasom scoring system and clinical type. The diagnosis of HT was based on thyroid function, anti-thyroid peroxidase antibody (anti-TPOAb) and anti-thyroglobulin antibody (anti-TgAb) detection, and ultrasonography. The prevalence of HT in all patients with OLP was 39.68% (98/247); the prevalence in females with OLP was 46.24% (86/186), which was higher than that in males with OLP 19.67% (12/61) ($P < 0.01$). The titers of the two HT autoantibodies in females with OLP were higher than those in males ($P < 0.01$). The clinical manifestations of OLP, regardless of being evaluated using the Thongprasom system or clinical type, were not significantly associated with HT development or TPOAb ($P = 0.864$) or TgAb titers ($P = 0.745$). In this population-based southern Chinese cohort, the prevalence of HT in patients with OLP, particularly in female patients with OLP, was significantly higher than that in the general population. Female patients had higher HT autoantibody titers than male patients. However, the clinical manifestations of OLP were not significantly correlated with either HT development or auto-anti-thyroid antibody levels. The findings could help further elucidate the factors involved in the relationship between oral lichen planus and Hashimoto's thyroiditis.

KEYWORDS

oral lichen planus, Hashimoto's thyroiditis, autoantibodies, TPOAb thyroperoxidase antibodies, TgAb thyroglobulin

Abbreviations: HT, Hashimoto's thyroiditis; IFN- γ , interferon gamma; IL, interleukin; OLP, oral lichen planus; Tg, thyroglobulin; TgAb, thyroglobulin antibody; TPO, thyroid peroxidase; TPOAb, thyroid peroxidase antibody

1 Introduction

Oral lichen planus (OLP) is a chronic inflammatory autoimmune disease of the oral mucosa mediated by T cells (1). The associated morbidity rate is approximately 0.5%–2.0% of the general population (2), with a substantially higher rate in middle-aged and older women (3). However, a valid systematic review and meta-analysis in 2021 of 66 studies (involving 500 424 patients) reported a global estimate of OLP prevalence of 1.01%. Furthermore, from the age of 40 years, the incidence of OLP-related morbidity increases considerably and progressively, and there is no difference in prevalence between the sexes (4). The specific etiology and pathogenesis of OLP remain unclear. Risk factors such as mental status, immune function, endocrine function, infections (including hepatitis C virus infection), and some systemic diseases (hypertension, diabetes mellitus, dyslipidemia, thyroid disorders, and chronic liver disease) may play important roles in OLP development (5–8).

Hashimoto thyroiditis (HT), considered an autoimmune thyroid disease (TD) related to T cells (9), affects approximately 2% of the total population and continues to rise; women are more susceptible to HT (10). The pathogenesis of HT is not known, and its development depends on genetic susceptibility, epigenetic inheritance, and environmental factors (11).

The relationship between OLP and HT has been studied. The prevalence of HT in patients with OLP is considerably higher than that in the common population, suggesting a correlation between OLP and HT (12–15). The thyroid autoantibodies include anti-thyroid peroxidase (TPO), anti-thyroglobulin (Tg), and anti-thyroid-stimulating hormone receptor antibodies. The most common autoantibodies expressed in patients with HT are thyroid peroxidase antibodies (TPOAb) and thyroglobulin antibodies (TgAb). Studies have shown that anti-thyroid antibodies also play a part in extra-thyroid diseases, mainly through the localization, category, function, and duration of antigens (16). Circulating autoantibodies against HT are associated with other extra-thyroid autoimmune diseases such as rheumatoid arthritis, celiac disease, and type 1 diabetes mellitus (17, 18). Anti-TPO and anti-Tg antibodies lack specificity, resulting in occasional reports of their extra-thyroid effects (19). Circulating autoantibodies against HT have also been detected in patients with OLP, suggesting a correlation between the diseases (20).

No definite conclusion can be drawn from the findings of previous studies regarding the relationship between OLP and HT. Previous studies on OLP and HT had notable limitations and problems, such as diverse diagnostic criteria for HT and OLP among studies. Moreover, some studies did not explicitly

include oral lichenoid lesions, which are related to several systemic or local factors such as specific drugs, dental material, and graft-versus-host disease. Additionally, there is a lack of analyses of the correlation between HT autoantibody levels and OLP. This cross-sectional study was designed to further investigate the correlation between HT and OLP in the Chinese Han population and study the relationship between autoantibody levels of HT and the clinical manifestations of OLP.

2 Materials and methods

2.1 Study design and ethics statement

This study was approved by the Ethics Committee of the West China Hospital of Stomatology, Sichuan University (WCHSIRB-D-2017-187). Two hundred and forty-seven patients with OLP were referred to the Department of Oral Medicine, West China Hospital of Stomatology from January 1, 2018 to May 1, 2021. All patients signed an informed consent form before the study. Patient demographic information, including age, sex, and medical and medication history, was recorded.

2.2 Participant selection

2.2.1 Inclusion criteria

The study involved patients with OLP who were mainly diagnosed based on their history, clinical manifestations, and histopathological biopsy report according to the World Health Organization diagnostic criteria (21). The lesions in the buccal mucosa, lingual body, hard palate, soft palate, and gingiva were symmetrical on both sides; the lesions appeared as white and gray-white stripes with small papules. The pathological biopsy criteria included hyperkeratosis of the epithelium, liquefaction of basal cells, and dense infiltration of lymphocytes in the intrinsic layer.

2.2.2 Exclusion criteria

The exclusion criteria were as follows: patients who (1) were diagnosed with other oral mucosal diseases; (2) had severe systemic diseases, tumors, and other autoimmune diseases that seriously affect the quality of life, such as psoriasis, Behçet's disease, and bullous diseases; (3) received immune preparations within 3 months; (4) used certain drugs or amalgam fillers that may cause oral lichenoid lesions; (5) had organ transplantation; and (6) were pregnant or lactating.

2.3 Evaluation of OLP clinical manifestations

The Thongprasom scoring system and clinical type were used to assess the clinical manifestations of OLP as follows (22): 0 = no lesion, normal mucosa; 1 = mild white striae only, no atrophic areas; 2 = white striae with atrophic areas < 1 cm²; 3 = white striae with atrophic areas > 1 cm²; 4 = white striae with erosive areas < 1 cm²; and 5 = white striae with erosive areas > 1 cm². The clinical manifestations of OLP were described as reticular type, atrophic type, and erosion type, representing “1,” “2&3,” “4&5,” respectively.

2.4 HT diagnostic criteria

Currently, the diagnosis of HT is established by a combination of clinical signs, thyroid function (TSH, T3, T4, FT3, and FT4), serum antibodies against thyroid antigens (mainly anti-TPOAb and TgAb), and thyroid color Doppler examination (23). The serum antibodies against the thyroid were detected by the clinical laboratory at the West China Hospital of Sichuan University. The detection method is Electrochemiluminescence immunoassay (ECLIA). Meanwhile, diffuse goiter, with a tough texture, especially with the enlargement of the pyramidal lobe of the isthmus, should be suspected of HT regardless of the changes in thyroid function. If the blood is positive for TPOAb or TgAb, HT can be diagnosed. Diagnosis was made for each patient by two independent experienced endocrinologists at the West China Hospital of Sichuan University.

2.5 Statistical analyses

The collected data were analyzed using SPSS software (version 23.0, IBM Corp., Armonk, NY, USA). The 95% confidence interval (CI) was used to compare thyroid disease and HT prevalence between patients with OLP and the general population. Comparison of the sex parameters of patients with OLP was performed using the χ^2 test. Analysis of variance and rank-sum test were used to compare OLP scores with thyroid disease and the HT group with the control group. Statistical significance was set at $P \leq 0.05$.

3 Results

3.1 Demographic information

Two hundred and forty-seven patients with OLP (61 males and 186 females; mean age 45.21 ± 12.72 years) were recruited.

Sixty patients had a history of systemic diseases (except HT). The information is presented in Table 1.

3.2 Prevalence of HT in patients with OLP

Among the 247 patients with OLP, the prevalence of HT was 39.68% (95% CI=33.58%-45.78%). The prevalence of HT was 46.24% in female patients with OLP, which was considerably higher than that in male patients with OLP (19.67%) (Table 2).

3.3 Anti-thyroid antibodies in patients with OLP

For the overall frequency of anti-thyroid antibodies, the positive rate of TPOAb in male patients with OLP was 19.67% (12/61) and that in female patients with OLP was 39.25% (73/186), which was considerably higher than that in male patients ($P = 0.005$). The positivity rate of TgAb in male patients with OLP was 6.56% (4/61) and that in female patients with OLP was 25.27% (47/186), which was considerably higher than that in male patients ($P = 0.002$) (Table 2). The titer of TPOAb base-10 logarithm in male patients with OLP was 1.23 and that in females was 1.52, which was considerably higher than that in male patients ($t = 2.921$, $P = 0.0038$). The titer of TgAb base-10 logarithm in male patients with OLP was 1.12 and that in females was 1.48, which was considerably higher than that in male patients ($t = 4.375$, $P < 0.0001$) (Figure 1).

TABLE 1 Demographics information of the 247 patients with OLP.

Characteristic	OLP (n = 247)
Mean age (years)	45.21 ± 12.72
Sex	
Male	61 (24.70%)
Female	186 (75.30%)
Other systemic diseases	111 (44.94%)
Hypertension	11 (4.45%)
Diabetes	5 (2.02%)
Thyroid disorders except HT	51 (20.65%)
Others*	44 (17.82%)
Medication history	
Yes	16 (6.48%)
No	231 (93.52%)

Data are presented as mean ± standard deviation unless specified otherwise.

*Others: included hepatitis, gallstone, gastritis, gastric ulcer, rectal cancer, nephritis, prostatitis, pulmonary cyst, fibroid, breast nodule, cervical carcinoma, anemia OLP, oral lichen planus; HT, Hashimoto's thyroiditis.

TABLE 2 HT prevalence and its autoantibodies in patients with OLP.

Characteristic	Male (n = 61)	Female (n = 186)	Total	P
HT				
With (%)	12 (19.67)	86 (46.24)	98	0.000
Without (%)	49 (80.33)	100 (53.76)	149	
TPOAb				
Positive (%)	12 (19.67)	73 (39.25)	65	0.005
Negative (%)	49 (80.33)	113 (60.75)	182	
TgAb				
Positive (%)	4 (6.56)	47 (25.27)	51	0.002
Negative (%)	57 (93.44)	139 (74.73)	196	

OLP, oral lichen planus; HT, Hashimoto's thyroiditis; TPOAb, thyroperoxidase antibodies; TgAb, thyroglobulin antibodies.

3.4 Relations between OLP clinical manifestations and HT development

We divided the clinical manifestations in patients with OLP into scores 1–5 according to the clinical examination sign score; the prevalence of HT was 37.76%, 18.38%, 8.16%, 29.59%, and 6.11%, respectively. In the rank test, the P value was $0.877 > 0.05$. Patients with OLP were divided into the following three types: reticular, atrophic, and erosion; the prevalence of HT was 37.76%, 26.53%, and 35.71%, respectively. In the rank test, the P value was $0.306 > 0.05$. We statistically analyzed the HT detection rate in patients with OLP and clinical manifestations of OLP. The association between HT and OLP was independent of OLP clinical scores or subtypes. The results are presented in Table 3.

3.5 Relations between OLP clinical manifestations and HT autoantibodies

The clinical manifestations of OLP were divided into 1–5 points, and the Ig-TPO levels were 1.38, 1.63, 1.39, 1.53, and 1.45, respectively (rank test $P = 0.864 > 0.05$). The Ig-Tg levels were 1.37, 1.55, 1.48, 1.54 and 1.46, respectively (rank test $P = 0.745 > 0.05$). Patients with OLP were divided into the following three types: reticular, atrophic, and erosion. The Ig TPO levels were 1.38, 1.55, and 1.51, respectively (rank test $P = 0.243 > 0.05$). The Ig-Tg levels were 1.37, 1.53, and 1.52, respectively (rank test $P = 0.142 > 0.05$). We statistically analyzed the HT detection rate in patients with OLP and clinical manifestations of OLP. The HT antibody titer was not related to the OLP clinical scores or subtypes. The results are shown in Table 4.

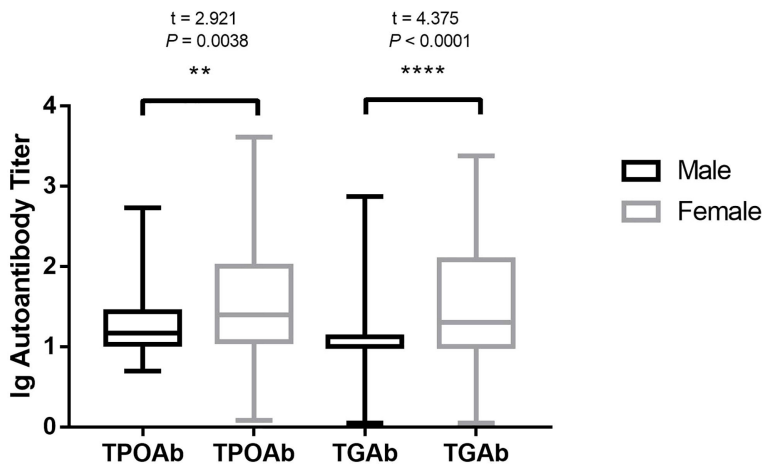


FIGURE 1 HT autoantibody in different sexes of patients with OLP. HT, Hashimoto's thyroiditis; OLP, oral lichen planus; TPOAb, thyroid peroxidase antibodies; TgAb, thyroglobulin antibodies. ** $P < 0.01$. **** $P < 0.0001$.

TABLE 3 Correlations between OLP clinical manifestations and developing HT.

Clinical manifestations	With HT (%)	Without HT (%)	Total	P
OLP scoring				0.877
1	37 (37.76)	69 (46.31)	106	
2	18 (18.38)	17 (11.41)	35	
3	8 (8.16)	12 (8.05)	20	
4	29 (29.59)	36 (24.16)	65	
5	6 (6.11)	15 (10.07)	21	
OLP clinical type				0.306
Reticular type	37 (37.76)	69 (46.31)	106	
Atrophic type	26 (26.53)	29 (19.46)	55	
Erosion type	35 (35.71)	51 (34.23)	86	

OLP, oral lichen planus; HT, Hashimoto's thyroiditis.

OLP scoring: 0 = no lesion, normal mucosa; 1 = mild white striae only, no atrophic areas; 2 = white striae with atrophic areas < 1 cm²; 3 = white striae with atrophic areas > 1 cm²; 4 = white striae with erosive areas < 1 cm²; and 5 = white striae with erosive areas > 1 cm².

4 Discussion

In this study, we aimed to explore the relationship between HT and OLP. The prevalence of HT in patients with OLP (39.68%) was significantly higher than that in the general population (2%) (10). The HT incidence rate in female patients with OLP was significantly higher than that in male patients. The titer of HT autoantibodies in female patients was considerably higher than that in male patients. However, HT prevalence and HT autoantibody levels in patients with OLP were not related to the OLP clinical manifestations.

Previous studies (20, 24) have inferred that OLP is related to HT, and this hypothesis has a theoretical basis. OLP and HT, as autoimmune diseases related to T-cell-mediated immune responses, seem to have some common immune triggers and pathogenic processes (25). Simultaneously, oral mucosal epithelial cells express antigens recognized by HT autoantibodies (TPOAb and TgAb) or antigens with structures similar to their recognized antigens (25). These might also be involved in the concurrent occurrence of these two diseases. Muzio (20) reported the HT prevalence rate in patients with OLP was 14.29% (15/105) in Italy. Tang (26) reported that the prevalence was 12.14% (71/585) in

East China. Zhou (24) reported that the prevalence was 20.83% (40/192). These rates are significantly higher than the prevalence in the general population. Our results are consistent with the conclusions of previous studies: the prevalence of HT in patients with OLP (39.68%) was significantly higher than that in the general population. However, in this study, the prevalence of HT in patients with OLP was higher than that in previous studies, which may be related to the ethnic differences of patients and the OLP diagnostic criteria (oral lichenoid lesions were excluded).

Our study also implied the role of thyroid antibodies which may be associated with autoimmune diseases arising in the oral mucosa. The possible mechanisms related to HT and OLP may include the following two aspects. Patients with one specific autoimmune disease are more susceptible to the other (27). Autoimmune diseases may interact with each other, such as epitope spreading, and this may be one possible mechanism (28, 29). Patients with HT are more likely to suffer from other autoimmune diseases, such as OLP. Circulating thyroid antibodies may target oral/skin keratinocytes or cross-react with proteins on keratinocyte membranes, which stimulate cytotoxic T cells to release chemokines to promote the development of OLP lesions and attract more immune cells into developing lesions,

TABLE 4 Correlations between OLP clinical manifestations and the HT autoantibody levels.

Clinical manifestation	Ig TPO level	P	Ig Tg level	P
OLP scoring		0.864		0.745
1	1.38		1.37	
2	1.63		1.55	
3	1.39		1.48	
4	1.53		1.54	
5	1.45		1.46	
OLP clinical type		0.243		0.142
Reticular type	1.38		1.37	
Atrophic type	1.55		1.53	
Erosion type	1.51		1.52	

OLP, oral lichen planus; HT, Hashimoto's thyroiditis; TPO, thyroid peroxidase; Tg, thyroglobulin.

OLP scoring: 0 = no lesion, normal mucosa; 1 = mild white striae only, no atrophic areas; 2 = white striae with atrophic areas < 1 cm²; 3 = white striae with atrophic areas > 1 cm²; 4 = white striae with erosive areas < 1 cm²; and 5 = white striae with erosive areas > 1 cm².

eventually leading to more cryptic epitope exposure and OLP lesions (25). The active systemic immune state during the course of autoimmune diseases is also a possible precipitating factor. Previous studies (30, 31) have inferred that both OLP and HT are mainly Th1-type patterns of immune response. The levels of interferon gamma (IFN- γ) and interleukin-4 (IL-4) in the serum and lesions of patients with OLP are increased. Th1 cells may play a leading role in immune balance in the pathogenesis of OLP (30). Higher levels of IL-12 and IFN- γ and lower levels of IL-4 indicate that the Th1 immune response characterized by cellular immunity is the main type of HT (32). Furthermore, the TPOAb level was associated with an increased production of Th1 cytokines (31). An increase in systemic immune activity in patients with HT may lead to OLP susceptibility. A molecular simulation study on the pathogenesis of lichen and thyroid autoimmunity showed that human protein autoantigens involved in specific autoimmune diseases gave lichen and thyroid autoimmunity a certain genetic susceptibility (33).

Most previous studies on OLP and HT did not include the clinical manifestations of OLP or the level of HT autoantibodies in the correlation analysis of the two diseases. In our study, we discussed the relationship between OLP clinical manifestations and HT prevalence in patients with OLP for the first time. The results showed no definite correlations. We also studied the relationship between clinical manifestations of OLP and the level of HT autoantibodies. The results indicated that there was no definite correlation between the level of HT autoantibodies and clinical manifestations of OLP, and the same results were observed between the sexes. Based on a case-control study in 2017, Alikhani et al. (34) reported that the serum TPOAb level in patients with erosive OLP was higher than patients with non-erosive OLP, and that the blood levels of TPOAb were significantly correlated with an increased risk of erosive OLP. Possible reasons for these findings include ethnic differences, inclusion criteria for OLP (patients with oral lichenoid lesions were excluded), and sample capacity.

In our study, the positivity rate and serum HT autoantibodies levels in female patients with OLP were significantly higher than those in male patients. This is because females are susceptible to OLP and HT. The prevalence of autoimmune diseases is associated with age and sex (35). These findings may be related to an autoimmune response, female sex hormone levels and receptors, inactivation of chromosome X, and fetal microchimerism (36–38). Therefore, we speculate that the significant difference in the prevalence of HT in different sexes of patients with OLP may be related to predisposition of women with autoimmune disease. We believe that HT incidence in patients with OLP is related to sex, and that female patients with OLP are more likely to suffer from HT. Men represent one-tenth of HT prevalence rate in the general population (39). However, the gap narrows in patients with OLP. In our study, 46.24% of the females had HT, twice the prevalence in males (19.67%). The HT prevalence in male patients with OLP has

significantly increased. The reason for this is unclear, and further clinical investigation is required.

Some aspects of the study need further improvement. This was a cross-sectional study and a causal relationship between the diseases could not be determined. Owing to the single-center nature and small number of patients, the samples may not have accurately represented the population; additionally, there was a lack of prospective studies. Moreover, potential confounding effects of changes in thyroid autoantibody levels were not excluded. Considering the cross-sectional design of this study, we could not directly examine or determine the potential mechanism underlying the association between OLP and HT. Large-sample multicenter prospective studies are needed to demonstrate our findings and search the potential pathophysiological mechanisms of these two diseases.

In conclusion, we found that OLP is associated with HT in the Chinese Han population. HT prevalence in patients with OLP was significantly higher than that in the general population; however, it was not significantly related to the OLP clinical manifestations or the level of HT autoantibodies. We speculate that the correlation between OLP and HT is mainly related to systemic immune status, epitope spreading, and other factors. Interestingly, women with OLP had a higher prevalence of HT and higher levels of thyroid autoantibodies. Moreover, HT prevalence in male patients with OLP has significantly increased, which needs to be investigated in future research. The findings could help further elucidate the factors involved in the relationship between oral lichen planus and Hashimoto's thyroiditis.

Data availability statement

The raw data supporting the conclusions of this article will be made available by the authors, without undue reservation.

Ethics statement

The studies involving human participants were reviewed and approved by Ethics Committee of the West China Hospital of Stomatology, Sichuan University. The patients/participants provided their written informed consent to participate in this study.

Author contributions

TZ: Conceptualization, methodology, investigation, data curation, formal analysis, writing – original draft preparation. FH: Conceptualization, methodology, investigation, data curation, formal analysis, writing – original draft preparation. DL, HZ, YS, XD, YMX: Investigation, data curation, formal analysis, writing – review and editing. YXX, XW, CW, YM, PY, XQ, LY, YL: Investigation, data curation, formal analysis. WW, LJ:

Conceptualization, methodology, funding acquisition, project administration, supervision, validation, writing – review and editing. All authors contributed to the article and approved the submitted version.

Funding

This work was supported by National Natural Science Foundation of China (81872208 and 82171809) and Sichuan Province Science and Technology Planning Project (2020JDJQ0013).

Acknowledgments

We thank the individuals who participated in this study for their willingness to contribute to the advancement of science.

References

- Alrashdan MS, Cirillo N, McCullough M. Oral lichen planus: A literature review and update. *Arch Dermatol Res* (2016) 308:539–51. doi: 10.1007/s00403-016-1667-2
- Scully C, Eisen D, Carrozzo M. Management of oral lichen planus. *Am J Clin Dermatol* (2000) 1:287–306. doi: 10.2165/00128071-200001050-00004
- Eisen D, Carrozzo M, Bagan Sebastian JV, Thongprasom K, Number V oral lichen planus: Clinical features and management. *Oral Dis* (2005) 11:338–49. doi: 10.1111/j.1601-0825.2005.01142.x
- González-Moles MÁ, Warnakulasuriya S, González-Ruiz I, González-Ruiz L, Ayén A, Lenouvel D, et al. Worldwide prevalence of oral lichen planus: A systematic review and meta-analysis. *Oral Dis* (2021) 27:813–28. doi: 10.1111/odi.13323
- Olson MA, Rogers RS3rd, Bruce AJ. Oral lichen planus. *Clin Dermatol* (2016) 34:495–504. doi: 10.1016/j.clindermatol.2016.02.023
- Roopashree MR, Gondhalekar RV, Shashikanth MC, George J, Thippeswamy SH, Shukla A. Pathogenesis of oral lichen planus—a review. *J Oral Pathol Med* (2010) 39:729–34. doi: 10.1111/j.1600-0714.2010.00946.x
- Alaizari NA, Al-Maweri SA, Al-Shamiri HM, Tarakji B, Shugaa-Addin B. Hepatitis c virus infections in oral lichen planus: A systematic review and meta-analysis. *Aust Dent J* (2016) 61:282–7. doi: 10.1111/adj.12382
- Lauritano D, Arrica M, Lucchese A, Valente M, Pannone G, Lajolo C, et al. Oral lichen planus clinical characteristics in Italian patients: A retrospective analysis. *Head Face Med* (2016) 12:18. doi: 10.1186/s13005-016-0115-z
- Esfahanian F, Ghelich R, Rashidian H, Jadali Z. Increased levels of serum interleukin-17 in patients with hashimoto's thyroiditis. *Indian J Endocrinol Metab* (2017) 21:551–4. doi: 10.4103/ijem.IJEM_412_16
- Ahmed R, Al-Shaikh S, Akhtar M. Hashimoto thyroiditis: A century later. *Adv Anat Pathol* (2012) 19:181–6. doi: 10.1097/PAP.0b013e3182534868
- Eschler DC, Hasham A, Tomer Y. Cutting edge: The etiology of autoimmune thyroid diseases. *Clin Rev Allerg Immunol* (2011) 41:190–7. doi: 10.1007/s12016-010-8245-8
- Lavaee F, Majd M. Evaluation of the association between oral lichen planus and hypothyroidism: A retrospective comparative study. *J Dent (Shiraz)* (2016) 17:38–42.
- Munde AD, Karle RR, Wankhede PK, Shaikh SS, Kulkarni M. Demographic and clinical profile of oral lichen planus: A retrospective study. *Contemp Clin Dent* (2013) 4:181–5. doi: 10.4103/0976-237X.114873
- Garcia-Pola MJ, Llorente-Pendás S, Seoane-Romero JM, Berasaluce MJ, Garcia-Martín JM. Thyroid disease and oral lichen planus as comorbidity: A prospective case-control study. *Dermatology*. (2016) 232:214–9. doi: 10.1159/000442438
- Robledo-Sierra J, Mattsson U, Jontell M. Use of systemic medication in patients with oral lichen planus - a possible association with hypothyroidism. *Oral Dis* (2013) 19:313–9. doi: 10.1111/odi.12009
- Cárdenas Roldán J, Amaya-Amaya J, Castellanos-de la Hoz J, Giraldo-Villamil J, Montoya-Ortiz G, Cruz-Tapias P, et al. Autoimmune thyroid disease in rheumatoid arthritis: A global perspective. *Arthritis*. (2012) 2012:864907. doi: 10.1155/2012/864907
- Lazúrová I, Benhatchi K, Rovenský J, Kozáková D, Wagnerová H, Tajtáková M, et al. Autoimmune thyroid disease and autoimmune rheumatic disorders: A two-sided analysis. *Ann N Y Acad Sci* (2009) 1173:211–6. doi: 10.1111/j.1749-6632.2009.04809.x
- Fröhlich E, Wahl R. Thyroid autoimmunity: Role of anti-thyroid antibodies in thyroid and extra-thyroidal diseases. *Front Immunol* (2017) 8:521. doi: 10.3389/fimmu.2017.00521
- Yavasoglu I, Senturk T, Coskun A, Bolaman Z. Rheumatoid arthritis and anti-thyroid antibodies. *Autoimmunity*. (2009) 42:168–9. doi: 10.1080/08916930802428114
- Lo Muzio L, Santarelli A, Campisi G, Lacaita M, Favia G. Possible link between hashimoto's thyroiditis and oral lichen planus: A novel association found. *Clin Oral Invest* (2013) 17:333–6. doi: 10.1007/s00784-012-0767-4
- van der Meij EH, van der Waal I. Lack of clinicopathologic correlation in the diagnosis of oral lichen planus based on the presently available diagnostic criteria and suggestions for modifications. *J Oral Pathol Med* (2003) 32:507–12. doi: 10.1034/j.1600-0714.2003.00125.x
- Thongprasom K, Luangjarmekorn L, Sererat T, Taweesap W. Relative efficacy of fluocinolone acetonide compared with triamcinolone acetonide in treatment of oral lichen planus. *J Oral Pathol Med* (1992) 21:456–8. doi: 10.1111/j.1600-0714.1992.tb00974.x
- Caturegli P, De Remigis A, Rose NR. Hashimoto thyroiditis: Clinical and diagnostic criteria. *Autoimmun Rev* (2014) 13:391–7. doi: 10.1016/j.autrev.2014.01.007
- Zhou T, Li D, Chen Q, Hua H, Li C. Correlation between oral lichen planus and thyroid disease in china: A case-control study. *Front Endocrinol (Lausanne)* (2018) 9:330. doi: 10.3389/fendo.2018.00330
- Wu P, Luo S, Zhou T, Wang R, Qiu X, Yuan P, et al. Possible mechanisms involved in the cooccurrence of oral lichen planus and hashimoto's thyroiditis. *Mediators Inflamm* (2020) 4:6309238. doi: 10.1155/2020/6309238
- Tang Y, Shi L, Jiang B, Zhou Z, Shen X. A cross-sectional study of oral lichen planus associated with thyroid diseases in East China. *Front Endocrinol (Lausanne)* (2019) 10:928. doi: 10.3389/fendo.2019.00928
- Jacobson DL, Gange SJ, Rose NR, Graham NM. Epidemiology and estimated population burden of selected autoimmune diseases in the united states. *Clin Immunol Immunopathol* (1997) 84:223–43. doi: 10.1006/clin.1997.4412

Conflict of interest

The authors declare that the research was conducted in the absence of any commercial or financial relationships that could be construed as a potential conflict of interest.

Publisher's note

All claims expressed in this article are solely those of the authors and do not necessarily represent those of their affiliated organizations, or those of the publisher, the editors and the reviewers. Any product that may be evaluated in this article, or claim that may be made by its manufacturer, is not guaranteed or endorsed by the publisher.

28. Cornaby C, Gibbons L, Mayhew V, Sloan CS, Welling A, Poole BD. B cell epitope spreading: Mechanisms and contribution to autoimmune diseases. *Immunol Lett* (2015) 163:56–68. doi: 10.1016/j.imlet.2014.11.001
29. Vanderlugt CL, Miller SD. Epitope spreading in immune-mediated diseases: Implications for immunotherapy. *Nat Rev Immunol* (2002) 2:85–95. doi: 10.1038/nri724
30. Wang Y, Zhou J, Fu S, Wang C, Zhou B. A study of association between oral lichen planus and immune balance of th1/th2 cells. *Inflammation*. (2015) 38:1874–9. doi: 10.1007/s10753-015-0167-4
31. Karanikas G, Schuetz M, Wahl K, Paul M, Kontur S, Pietschmann P, et al. Relation of anti-TPO autoantibody titre and T-lymphocyte cytokine production patterns in hashimoto's thyroiditis. *Clin Endocrinol (Oxf)*. (2005) 63:191–6. doi: 10.1111/j.1365-2265.2005.02324.x
32. Phenekos C, Vryonidou A, Gritzapis AD, Baxevanis CN, Goula M, Papamichail M. Th1 and Th2 serum cytokine profiles characterize patients with hashimoto's thyroiditis (Th1) and graves' disease (Th2). *Neuroimmunomodulation*. (2004) 11:209–13. doi: 10.1159/000078438
33. Guarneri F, Giuffrida R, Di Bari F, Cannavò SP, Benvenia S. Thyroid autoimmunity and lichen. *Front Endocrinol (Lausanne)* (2017) 8:146. doi: 10.3389/fendo.2017.00146
34. Alikhani M, Ghalaiani P, Askariyan E, Khunsaraki ZA, Tavangar A, Naderi A. Association between the clinical severity of oral lichen planus and anti-TPO level in thyroid patients. *Braz Oral Res* (2017) 31:e10. doi: 10.1590/1807-3107BOR-2017.vol31.0010
35. Hughes JW, Bao YK, Salam M, Joshi P, Kilpatrick CR, Juneja K, et al. Late-onset T1DM and older age predict risk of additional autoimmune disease. *Diabetes Care* (2019) 42:32–8. doi: 10.2337/dc18-1157
36. Klein SL, Flanagan KL. Sex differences in immune responses. *Nat Rev Immunol* (2016) 16:626–38. doi: 10.1038/nri.2016.90
37. Whitacre CC. Sex differences in autoimmune disease. *Nat Immunol* (2001) 2:777–80. doi: 10.1038/ni0901-777
38. Brix TH, Hansen PS, Kyvik KO, Hegedüs L. Aggregation of thyroid autoantibodies in twins from opposite-sex pairs suggests that microchimerism may play a role in the early stages of thyroid autoimmunity. *J Clin Endocrinol Metab* (2009) 94:4439–43. doi: 10.1210/jc.2009-0813
39. Hiromatsu Y, Satoh H, Amino N. Hashimoto's thyroiditis: History and future outlook. *Hormones (Athens)* (2013) 12:12–8. doi: 10.1007/BF03401282



OPEN ACCESS

EDITED BY

Dunfang Zhang,
West China Hospital, Sichuan
University, China

REVIEWED BY

Xikun Zhou,
Sichuan University, China
Qingchao Wang,
Huazhong Agricultural University,
China

*CORRESPONDENCE

Xin Jin
500934@hospital.cqmu.edu.cn
Ping Ji
jiping@hospital.cqmu.edu.cn

SPECIALTY SECTION

This article was submitted to
Mucosal Immunity,
a section of the journal
Frontiers in Immunology

RECEIVED 28 July 2022

ACCEPTED 29 August 2022

PUBLISHED 20 September 2022

CITATION

Long H, Yan L, Pu J, Liu Y, Zhong X,
Wang H, Yang L, Lou F, Luo S,
Zhang Y, Liu Y, Xie P, Ji P and Jin X
(2022) Multi-omics analysis
reveals the effects of microbiota
on oral homeostasis.
Front. Immunol. 13:1005992.
doi: 10.3389/fimmu.2022.1005992

COPYRIGHT

© 2022 Long, Yan, Pu, Liu, Zhong,
Wang, Yang, Lou, Luo, Zhang, Liu, Xie, Ji
and Jin. This is an open-access article
distributed under the terms of the
[Creative Commons Attribution License
\(CC BY\)](#). The use, distribution or
reproduction in other forums is
permitted, provided the original
author(s) and the copyright owner(s)
are credited and that the original
publication in this journal is cited, in
accordance with accepted academic
practice. No use, distribution or
reproduction is permitted which does
not comply with these terms.

Multi-omics analysis reveals the effects of microbiota on oral homeostasis

Huiqing Long^{1,2}, Li Yan³, Juncai Pu^{1,4}, Yiyun Liu^{1,4},
Xiaogang Zhong^{1,4}, Haiyang Wang^{1,4}, Lu Yang^{1,2},
Fangzhi Lou^{1,2}, Shihong Luo^{1,2}, Yingying Zhang^{1,2}, Yang Liu^{1,2},
Peng Xie^{1,4}, Ping Ji^{1,2*} and Xin Jin^{1,2*}

¹Key Laboratory of Psychosomatics, Stomatological Hospital of Chongqing Medical University, Chongqing, China, ²Chongqing Key Laboratory of Oral Diseases and Biomedical Sciences, Chongqing, China, ³School of Public Health and Management, Chongqing Medical University, Chongqing, China, ⁴NHC Key Laboratory of Diagnosis and Treatment on Brain Functional Diseases, The First Affiliated Hospital of Chongqing Medical University, Chongqing, China

The oral epithelium's normal morphological structure and function play an important role in maintaining oral homeostasis, among which microbiota and chronic stress are key contributing factors. However, the effects of microbiota and chronic stress on the morphological structures and molecular function of oral homeostasis remain unclear. In this study, morphological staining was used to compare the tongue structure of specific pathogen-free and germ-free mice, and an integrated multi-omics analysis based on transcriptomics, proteomics, and metabolomics was performed to investigate the regulatory mechanisms of microbiota and chronic stress on oral homeostasis. We found that the morphological structure of the tongue in germ-free mice was disordered compared with in specific pathogen-free mice, especially in the epithelium. Multi-omics analysis indicated that differentially expressed molecules of the tongue between germ-free and specific pathogen-free mice were significantly enriched in the mitochondrial metabolic process and immune response. Interestingly, microbiota also significantly influenced the permeability of the oral epithelial barrier, represented by the differential expression of keratinization, and cell adhesion molecules. It was worth noting that the above changes in the tongue between specific pathogen-free and germ-free mice were more significant after chronic stress. Collectively, this is the first study to reveal that the microbiota might maintain oral homeostasis by reshaping the structure of the oral epithelial barrier and changing the function of molecular biology, a process that may be driven by the immune response and mitochondrial metabolic process of oral tissue. Furthermore, chronic stress can enhance the regulatory effects of microbiota on oral homeostasis.

KEYWORDS

microbiota, tongue, homeostasis, immunity, transcriptome, proteome, metabolome

Introduction

The mouth is an organ that communicates directly with external pathogens and is exposed to the unstable microenvironment formed by various bacteria, viruses and fungi for a long time (1). A delicate balance between the host and oral microbiota is established, known as oral homeostasis, and heredity and the external environment may disrupt this natural balance in the mouth, resulting in regional oral and systemic diseases. The microbiota and chronic stress are key influencing factors in the acquired environment.

The interaction between microbiota and host plays an important role in maintaining homeostasis. Compared with conventionally fed mice, the intestinal surface area and villi number of germ-free (GF) mice are reduced, accompanied by decreased immune function (2). Similar findings were found in the nasal mucosa of GF mice (3). Research on microbiota in stomatology has gained significant momentum in recent years. Most oral diseases such as periodontitis and oral squamous cell carcinoma are closely related to the dysbiosis of oral microbiota (4, 5). However, the above studies have been mainly focused on the interaction between microbiota and certain oral diseases, with no emphasis placed on the effect and mechanism of microbiota on the morphological structure and biological function of oral tissue from an integrated multi-omics perspective.

Stress related factors that cause psychological anxiety and depression are closely related to oral diseases (6). Many oral diseases are accompanied by a high incidence of anxiety and depression (7, 8), and the prevalence of depression in oral squamous cell carcinoma reportedly exceeds 65% (9). Meanwhile, current evidence suggests that bad mental attitudes are not conducive to the prognosis of oral disease (10), while inflammatory mediators were found to be increased locally in the tumors of stressed rats (11). Moreover, it has been found that the expression of neurotransmitters was elevated in saliva and serum of patients with burning mouth syndrome with mood disorders (12). Although significant emphasis has been placed on the interaction between stress-related factors and oral diseases, few studies have investigated the potential molecular mechanisms.

This study sought to provide an integrated multi-omics perspective to explore the effects of microbiota on oral homeostasis, and to elucidate the molecular mechanisms of microbiota and chronic stress on oral homeostasis. To this end, we compared the morphological structure of the tongue between GF and specific pathogen-free (SPF) mice and clarified the effects of microbiota and chronic stress on the biological function of oral tissues based on the integrated analysis of transcriptomics, proteomics and metabolomics.

Material and methods

Animal

Eight male Kunming mice in a specific pathogen-free environment and eight male GF mice in a germ-free environment were obtained from the NHC Key Laboratory of Diagnosis and Treatment on Brain Functional Diseases. All procedures involving animals were carried out in accordance with the guidelines of the Institutional Animal Care and Use Committee (IACUC) of Chongqing Medical University and ethical approval was obtained from the Laboratory Animal Ethics Committee of Chongqing Medical University (Approval Number: 2021(063)). Additionally, we have complied with the Animal Research: Reporting *In Vivo* Experiments (ARRIVE) 2.0 guidelines.

Chronic stress

All mice were adaptively fed for one week before the formal experiment and a suitable number of mice were matched according to weight and age by statistical analysis. Half of the SPF mice and GF mice were confined to plastic tubes slightly larger than themselves for 2-4 hours a day, and the other mice were housed in a conventionally suitable environment (temperature of 23°C, humidity of 55%, day/night cycle of 12h/12h) every day. The experimental procedure is shown in Figure 1.

Integrated analysis of transcriptomics, proteomics, and metabolomics

Metascape (<https://metascape.org/gp/index.html#/main/>) was used for the integrated analysis of differentially expressed genes (DEGs) and differentially expressed proteins (DEPs), and the biological enrichment pathways and functions of the above differentially expressed molecules were identified by Gene Ontology (GO), Kyoto Encyclopedia of Genes and Genomes (KEGG) and Reactome based on $p < 0.05$. Furthermore, MetaboAnalyst5.0 (<http://www.metaboanalyst.ca/MetaboAnalyst/>) was applied to the integrated analysis of transcriptomics, proteomics, and metabolomics. All identified differentially expressed molecules underwent to KEGG pathway enrichment analysis, and the top-ranked pathways were listed according to FDR values ($FDR < 0.05$). Molecular network analysis was then performed using Ingenuity Pathway Analysis (IPA, <http://www.ingenuity.com>). Statistical significance was set at an $FDR < 0.05$ in all analyses, and the top two in molecular networks were selected.

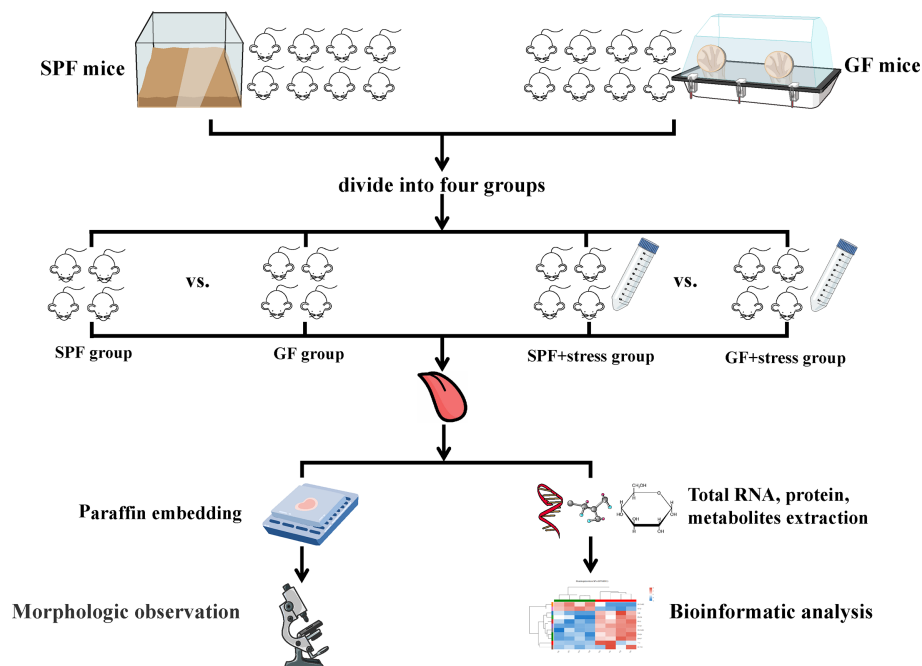


FIGURE 1

Flowchart of this study. (n=4/SPF group; n=4/GF group; n=4/SPF + chronic stress group; n=4/GF + chronic stress group). SPF mice, specific pathogen-free mice; GF mice, germ-free mice.

Statistical analysis

All statistical operations were processed by the IBM SPSS Statistics (Version 26; IBM Corporation, Armonk, NY, USA) and GraphPad Prism 8 (GraphPad Software, San Diego, CA, USA). Quantitative data were expressed by mean \pm standard deviation. The student's t-test (two-tailed) was used to calculate the significance of the difference between the two groups of samples, and one-way ANOVA was conducted on multiple groups. A p -value < 0.05 was considered as statistically significant.

The detailed protocols of the following experiment are shown in the Supplementary materials:

- H & E staining
- Quantitative PCR
- Transcriptomics Analysis
- Proteomics Analysis
- Metabolomics Analysis

Results

1. Morphological observation indicates that microbiota and chronic stress affect the epithelial structure of the tongue

Morphological observation showed there were some similarities and differences in the structure of tongues between SPF and GF mice. The similarity was that the distribution of different types of lingual papilla in the dorsal lingual epithelium of SPF and GF mice was roughly the same (Figure S1). The difference was that the morphological structure of the tongue epithelium of was clearly visualized in SPF mice compared with GF mice, while the epithelial structure of GF mice was disordered, especially between stratum spinosum and basal layer (Figures 2A–H). Additionally, filiform papillae in GF mice were more slender and uneven than in SPF mice (Figures 2I, J). There were no significant changes in the morphology of tongue in the two kinds of mice after chronic stress. Interestingly, we found that chronic stress led to the increase in the thickness of the epithelial stratum corneum of the tongue in both GF and SPF mice, especially in the filiform papillae (Figures 2K–N). The stratum corneum thickness of tongue epithelium was compared among the four groups, and it was statistically confirmed that chronic stress could thicken the stratum corneum of the tongue epithelium in both two kinds of mice (Figure 2O).

2. Multi-omics analysis reveals the influence of microbiota on oral homeostasis

A comparison of integrated multi-omics analysis of the tongue between SPF and GF mice reflected the molecular

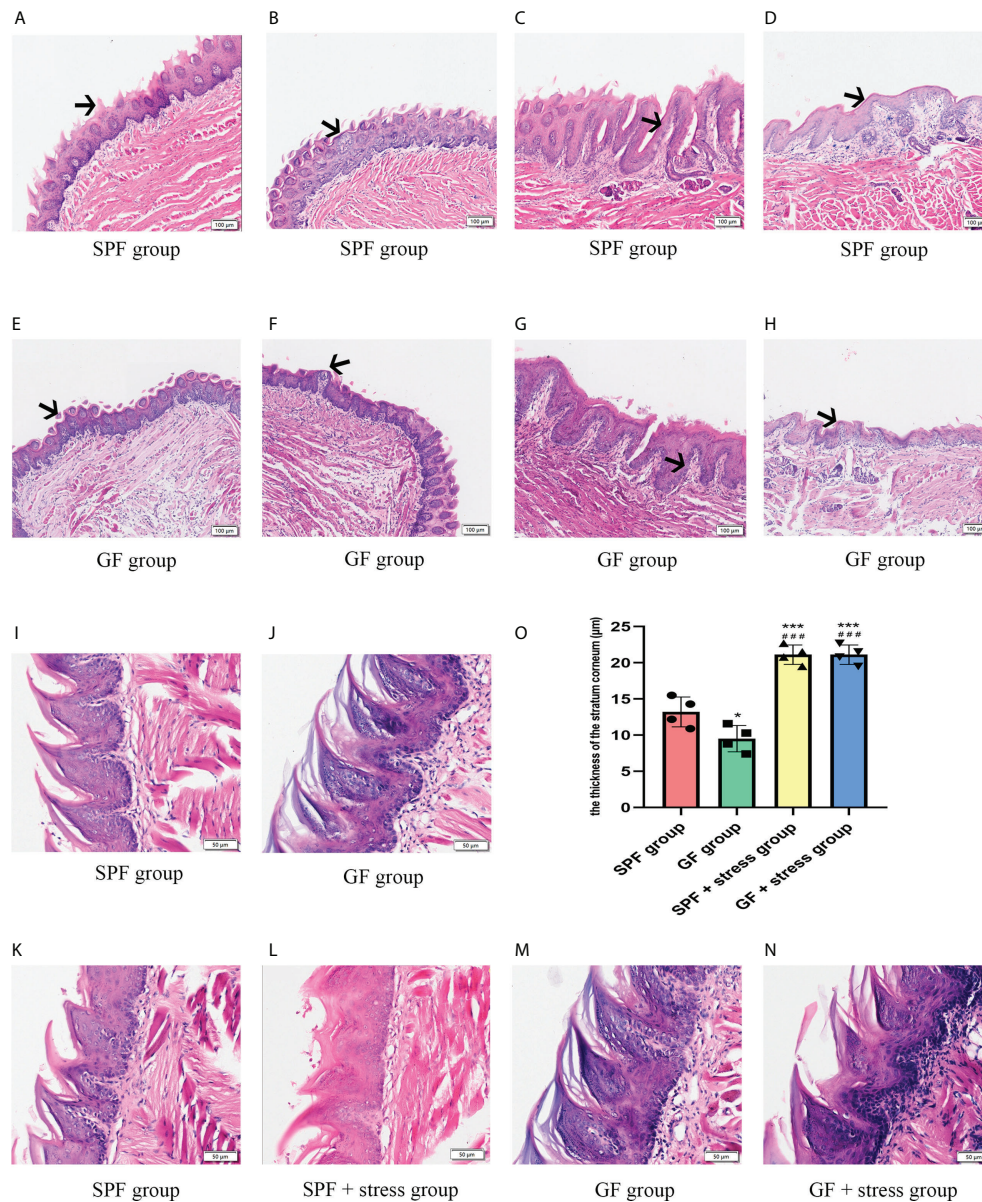


FIGURE 2

Microbiota regulates the morphological structure of the lingual epithelium. (A, B) HE staining of the anterior and middle regions of the lingual dorsum of SPF mice. The black arrows in Figures A and B represent the Fip and Fup on the lingual dorsum of SPF mice, respectively. (C, D) HE staining of the posterior region of the lingual dorsum in SPF mice. The black arrows in Figures C and D represent the Fop and Cip on the lingual dorsum of SPF mice, respectively. (E, F) HE staining of the anterior and middle regions of the lingual dorsum of GF mice. The black arrows in Figures E and F represent the Fip and Fup on the lingual dorsum of GF mice, respectively. (G, H) HE staining of the posterior region of the lingual dorsum in GF mice. The black arrows in Figures G and H represent the Fop and Cip on the lingual dorsum of GF mice, respectively. (I) The morphological structure of Fip on the lingual dorsum of SPF mice. (J) The morphological structure of Fip on the lingual dorsum of GF mice. (K) The morphological structure of tongue epithelium in SPF mice. (L) The morphological structure of tongue epithelium in SPF mice under chronic stress. (M) The morphological structure of tongue epithelium in GF mice. (N) The morphological structure of tongue epithelium in GF mice under chronic stress. (O) The bar graph of stratum corneum thickness of tongue epithelium in four groups of mice. Fip, filiform papillae; Fup, fungiform papillae; Fop, foliate papillae; Cip, circumvallate papillae. Scale bar: 100 or 50 μm. The experiments were performed at least three times independently. * $p < 0.05$ vs SPF group; ** $p < 0.01$ vs SPF group; *** $p < 0.001$ vs SPF group; # $p < 0.05$ vs GF group; ## $p < 0.01$ vs GF group; ### $p < 0.001$ vs GF group.

mechanism of microbial regulation on oral homeostasis. Principal Component Analysis (PCA) of transcriptomics, proteomics and metabolomics showed good biological duplication within the same group and clear segregation between the GF and SPF group, especially in the metabolomics (Figures 3A–C), which ensured the reliability of the subsequent analysis. Additionally, we performed inter-group Venn analysis

and showed the co-expressed and specially expressed transcripts, proteins, and metabolites between GF and SPF group. (Figure S2).

We analyzed DEGs in the tongue tissues of SPF and GF mice using DESeq2, and a total of 540 DEGs were identified (using the criteria false discovery rate, [FDR] < 0.05 and fold change, [$|\text{FC}|$] > 2). We found that 271 and 269 DEGs were up-regulated

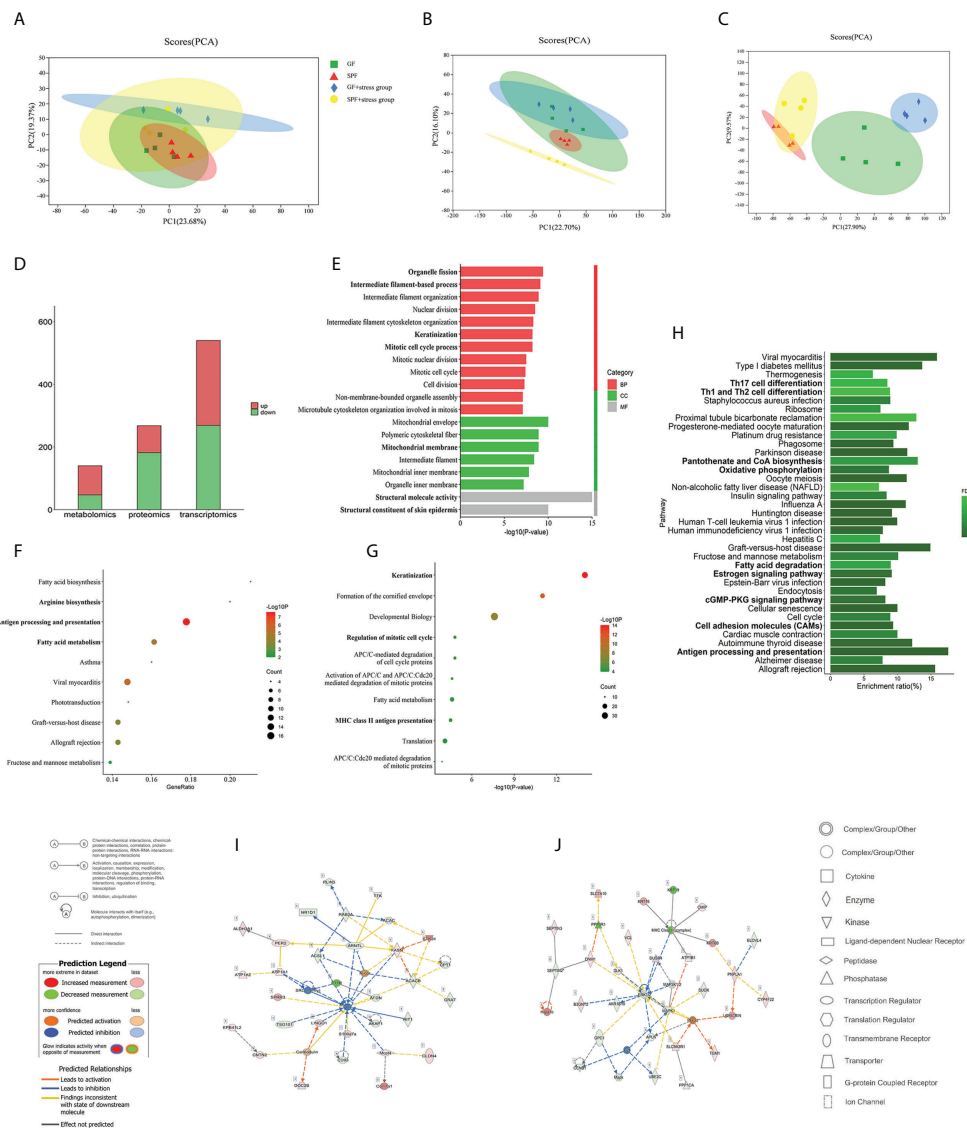


FIGURE 3

Multi-omics analysis reveals that microbiota can regulate oral homeostasis. (A–C) PCA of the transcriptomics, proteomics, and metabolomics of the tongue in SPF and GF mice. (D) Histogram showing the number of differentially expressed molecules in the tongues of SPF and GF mice during multi-omics analysis. (E–G) GO/KEGG/Reactome enrichment analysis of integrated transcriptomics and proteomics of the tongue in SPF and GF mice. (H) KEGG pathway enrichment analysis of multi-omics of the tongue in SPF and GF mice. (I, J) IPA of multi-omics of the tongue in SPF and GF mice. The bold fonts represent the molecules of particular interest in the enrichment pathway. PCA, Principal Component Analysis; IPA, Ingenuity Pathway Analysis; GO, Gene Ontology; KEGG, Kyoto Encyclopedia of Genes and Genomes.

and down-regulated, respectively (Figure S3A). For DEPs, a total of 268 proteins were obtained based on thresholds of fold change >1.2 or 0.83 , and $p < 0.05$, including 86 upregulated and 182 downregulated proteins (Figure S3B). 140 differentially expressed metabolites ($p < 0.05$ and $VIP > 1$) were detected in the tongue tissues between GF and SPF mice, including 93 upregulated and 47 downregulated metabolites (Figure S3C). The numbers of differentially expressed molecules in the multi-omics analysis are shown in Figure 3D.

3. An integrated bioinformatics analysis of the tongue tissues between SPF and GF mice suggests a mechanism underlying the regulatory role of microbiota on oral homeostasis

To conduct a bioinformatics analysis of the above differentially expressed molecules, the biological enrichment pathways and functions of the above DEGs and DEPs were first identified by Gene Ontology (GO), Kyoto Encyclopedia of Genes and Genomes (KEGG) and Reactome (Table S1). Among the 670 GO items, the top 20 terms were “Structural molecule activity”, “Structural constituent of skin epidermis”, “Mitochondrial envelope”, “Organelle fission”, and so on (Figure 3E). Interestingly, the above items were mainly involved in mitochondrial metabolism, cell division, and keratinization. There were 66 and 117 items in KEGG and Reactome pathway enrichment analysis, and the top 10 items are shown in Figures 3F, G, including significant enrichment in “Antigen processing and presentation”, “Fatty acid (FA) metabolism”, and “Keratinization”.

To comprehensively explore the effect of microbiota on oral homeostasis, we performed an integrated analysis of the differentially expressed molecules, which yielded 289 enriched pathways (Table S2). After screening, a total of 37 pathways were statistically significant, and the results showed significant enrichment in functions, including “Th17 cell differentiation”, “Th1 and Th2 cell differentiation”, “Oxidative phosphorylation (OXPHOS)”, “Cell adhesion molecules (CAMs)”, and “Antigen processing presentation” (Figure 3H). We then identified the molecular networks using Ingenuity Pathway Analysis and selected the top two. The results indicated that the microbiota might play an important regulatory role in oral homeostasis by activating immune response and inflammatory reaction (Figures 3I, J; Table S3).

4. Multi-omics analysis reveals the influence of chronic stress on oral homeostasis

To investigate the effects of chronic stress on oral homeostasis from a multi-omics perspective, the PCA results showed clear segregation between two types of mice under chronic stress, and the trend was more obvious than in the non-chronic stress state (Figures 3A–C). The above results indicated that there was clear segregation between the GF and SPF group under chronic stress, especially in proteomics and metabolomics results. The inter-group Venn analysis was performed to show the co-expressed and specially expressed transcripts, proteins, and metabolites between GF and SPF

group under the chronic stress (Figure S4). The intersection of genes between SPF and GF mice under chronic stress yielded 794 DEGs ($FDR < 0.05$ and $|FC| > 2$) (Figure S5A), among which 527 DEGs were up-regulated and 267 DEGs were down-regulated (Figure 4A). The number of differentially expressed proteins and metabolites of tongues between GF and SPF mice under chronic stress was 574 and 173, respectively ($p < 0.05$) (Figures S5B, C, 4A).

5. The integrated bioinformatics analysis of the tongue between SPF and GF mice under chronic stress suggests the molecular mechanism of chronic stress on oral homeostasis

We performed an integrated transcriptomics and proteomics analysis of the tongue between SPF and GF mice under chronic stress (Table S4), and GO, KEGG, and Reactome enrichment analyses were used to identify enriched pathways and functions of DEGs and DEPs under chronic stress. GO enrichment analysis yielded 932 items, among which “Cellular respiration”, “Mitochondrial inner membrane”, and “Oxidoreductase activity” were the top GO terms for biological process, cellular component, and molecular function, respectively (Figure 4B). KEGG and Reactome pathway enrichment analysis yielded 68 and 197 items, respectively, and the top 10 items are shown in Figures 4C, D. KEGG enrichment analysis showed significant enrichment in “Citrate cycle (TCA)”, “Oxidative phosphorylation”, and “Mucin type O-glycan biosynthesis”, while Reactome pathway enrichment analysis indicated significant differences in “Antigen processing - Cross presentation”, “Cellular response to chemical stress”, and “Neutrophil degranulation” between the two groups.

To comprehensively explore the mechanisms of chronic stress on oral homeostasis, we integrated the data from transcriptomics, proteomics and metabolomics analysis, and the results indicated that chronic stress mainly affected biological functions, including mitochondrial metabolism, epithelial adhesion and immune response in oral homeostasis (Figure 4E; Table S5). “OXPHOS”, “Glycolysis or gluconeogenesis”, “Glutathione metabolism”, “FA degradation”, “Citrate cycle”, and “beta-alanine metabolism” reflected the mitochondrial metabolic process, while epithelial adhesion was associated with “Tight junction”, “PPAR signaling pathway”, and “Mucin type O-glycan biosynthesis”. Additionally, Ingenuity Pathway Analysis indicated that chronic stress might affect oral homeostasis by activating inflammatory cascade reaction and immune response (Figures 4F, G; Table S6). In order to better demonstrate the effects of microbiota and chronic stress on oral homeostasis, the mRNA expression of epithelial permeability indicators was detected in tongue tissues of the four groups of mice. The results showed that compared with SPF mice, the expression of ZO-1 in the tongue tissue of GF mice decreased, while the expression of occludin and claudin-1 increased, and chronic stress caused similar changes in oral epithelial permeability (Figure 4H). Overall, our results suggest that chronic stress can affect the structural remodeling and biological

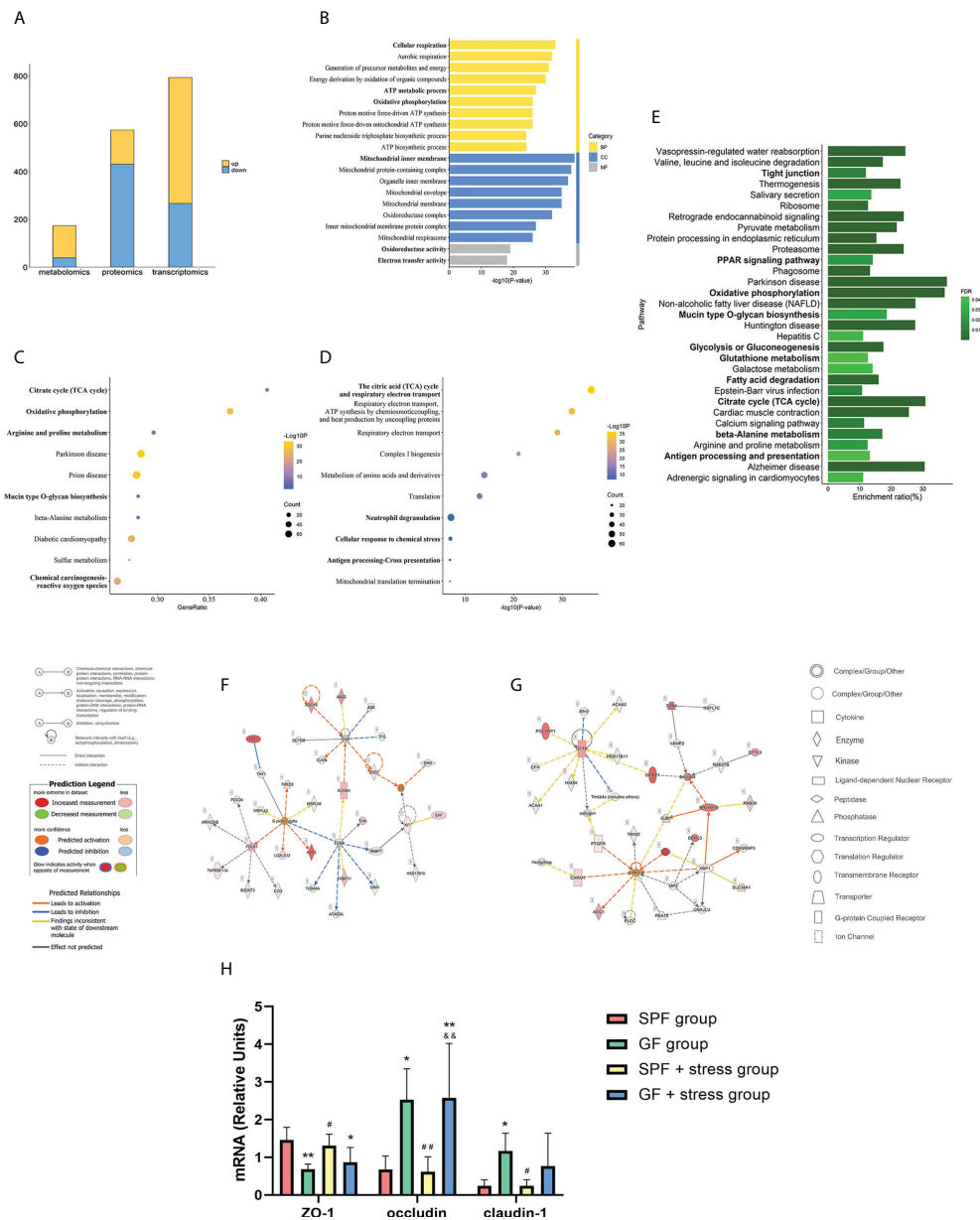


FIGURE 4

Multi-omics analysis suggests that chronic stress may enhance the regulation of microbiota on oral homeostasis. **(A)** Histogram showing the number of differentially expressed genes during the tongues of SPF and GF mice in multi-omics analysis under chronic stress. **(B–D)** GO/KEGG/Reactome enrichment analysis of combined transcriptomics and proteomics of the tongue in SPF and GF mice under chronic stress. **(E)** KEGG pathway enrichment analysis of multi-omics of the tongue in SPF and GF mice under chronic stress. **(F, G)** IPA of multi-omics of the tongue in SPF and GF mice under chronic stress. **(H)** The bar graph of mRNA expression representing oral epithelial permeability in four groups of mice. The bold fonts represent the molecules of particular interest in the enrichment pathway. Scale bar: 50 μ m. The experiment of qPCR was performed at least three times independently. * $p < 0.05$ vs SPF group; ** $p < 0.01$ vs SPF group; *** $p < 0.001$ vs SPF group; # $p < 0.05$ vs GF group; ## $p < 0.01$ vs GF group; ### $p < 0.001$ vs GF group; $\delta p < 0.05$ vs SPF + stress group; $\delta\delta p < 0.01$ vs SPF + stress group; $\delta\delta\delta p < 0.001$ vs SPF + stress group.

function of the oral epithelium, thus enhancing the regulatory role of microbiota on oral homeostasis.

Discussion

To the best of our knowledge, this is the first study to comprehensively analyze the molecular regulatory mechanisms of microbiota and chronic stress on oral homeostasis by comparing the morphological structure and integrating multi-omics data of the tongue between SPF and GF mice. We found that the microbiota could affect structural remodeling of the oral epithelium, which was mainly reflected in keratinization and cellular adhesion, and the microbiota may regulate oral homeostasis by mitochondrial metabolic process and immune response. Additionally, chronic stress can enhance these regulatory processes.

Herein, we found that the microbiota can regulate oral homeostasis by affecting structural remodeling. As the structural basis of the oral mucosa, the integrity of the epithelial barrier is a firewall against pathogenic microbiota. Indeed, oral epithelial morphology also embodies the integrity of the epithelial barrier. In this study, we found that the morphological structure of oral epithelium in GF mice was more disordered in SPF mice, and the lingual papilla was more slender and uneven, similar to nasal and intestinal mucosal epithelium structure (2, 3). Proper structure and function of the oral epithelium are essential for maintaining symbiosis of bacteria and protecting the host from infection, especially for keratinization. Indeed, epithelial cells participate in the effective defense against microbiota invasion. A study found that the keratinization of the oral mucosa of baboons was closely related to the number of bacteria (13). In addition to keratinization, the expression of CAMs also plays an important role in epithelial permeability. An epithelium with poor permeability confers an appropriate protective effect against pathogen infections, and the high expression of CAMs reflects the repeated resistance of the mucosal epithelium to the attack of pathogen infections (14). The expression of mucosal Adressin cell adhesion molecule 1 (MAdCAM-1) at birth was more prevalent in the intestinal mucosal blood vessels of CV mice than in GF mice (15). In oral mucosa, it was also found that the microbiota limited the absorption of foreign pathogens in the mucosal barrier by increasing the expression of epithelial-adhesive proteins to support the protective mucosal layer (16), which was consistent with the mRNA expression of epithelial adhesion molecule in our study. The enhanced permeability of the tongue epithelium in GF mice suggested that microbiota could activate the protective mechanism of the oral epithelial barrier. Moreover, human keratinocytes exposed to *Porphyromonas gingivalis* (Pg) showed low expression of connexin and Grainyhead-like 2 (*Grhl2*), and *Grhl2* conditional knockout (KO) mice showed increased epithelial

infiltration of oral bacteria compared with wild-type mice, which could disrupt the epithelial barrier, thereby leading to the aggravation of periodontal disease (17). Our results suggested that hyper-keratinization of epithelial cells and adhesion change of endothelial cells were important manifestations of host anti-microbial defense.

Our integrated omics analysis revealed that microbiota could regulate the immune response in oral homeostasis. Oral epithelium can trigger inflammatory cascade signals and immune responses during microbial imbalance. Firstly, EGF/EGFR, as a known upstream activator of both the pro-survival phosphoinositide 3-kinase/Akt and proinflammatory mitogen-activated protein (MAP) kinase pathways, could protect oral epithelia from barrier damage (18–20). Mechanically, EGF/EGFR can play a positive regulatory role on the permeability of mucosal barrier by regulating the integrity of tight junction proteins (21). It is worth noting that EGF can change the ability of microbiota to colonize the intestinal and respiratory mucosa and prevent barrier defects induced by pathogenic microbiota (22, 23). Additionally, it has found that the severity of oral mucositis was positively correlated with the content of EGF in saliva (24). In this study, our integrated analysis indicated that EGF/EGFR could be activated by microbiota and chronic stress to regulate oral homeostasis. It is well-established that *Streptococcus* and *Veillonella* in oral flora can activate a series of inflammatory tandem pathways represented by MAPK and PI3K-Akt-mTOR (25, 26). The microbiota can induce host immune defense by direct contact with microbiota or indirectly activating inflammatory cytokines, and this process is environmentally adaptive. It has been reported that T-cells response to *Akkermansia muciniphila* in a sterile environment could be limited to the activation of T follicular helper cells. In contrast, in an inflammatory environment, various manifestations such as Th17 cell differentiation have been observed (27). It has been shown that *Bacteroides Fragilis* could enhance the differentiation of CD4+ T cells into T helper cells 1 (Th1) and Th2 (28), and the above phenomenon of helper T cell skewing was similar to our results. In the present study, we revealed that the microbiota affects oral homeostasis via an immune response by activating inflammatory cascade signals, which are adaptive changes after the microbiota competes with the host.

Furthermore, our results demonstrated that mitochondrial metabolism might also be a major regulator of microbial-mediated oral homeostasis. Metabolic adaptation is the basis of cell life activities, and the mitochondrial metabolic process can regulate microbial-mediated oral homeostasis by affecting immune cell differentiation (29). The metabolic processes of OXPHOS, TCA cycle, and nucleotide biosynthesis are strongly activated in activated naïve and memory T cells, while aerobic glycolysis is a marker of activated CD8+ T cells (30). In addition, it has been established that Fatty acid (FA) provides energy for cell metabolism through FA oxidation and closely regulates the

homeostasis of immune cells (31). The results of our multi-omics analysis suggested that microbiota may regulate oral homeostasis by changes in the mitochondrial metabolic process, thus affecting the epithelium's inflammatory activation and immune response of. Experiments with *Staphylococcus aureus* infection of human keratinocytes demonstrated a positive correlation between glycolysis and innate immunity of epithelial cells (32). Thus, upregulation of glycolysis is more likely to occur in an inflammatory environment (33), whereas OXPHOS positively correlates with anti-inflammatory activation (34). Additionally, membrane-associated protein can reportedly promote the uptake of FA to meet the host immune cells' nutritional supply and energy requirements (35), consistent with our results. Collectively, specific metabolic changes may adapt to different functional outputs, and the mitochondrial metabolic process could be an adaptive adjustment of host defense pathogens in the epithelium (Figure 5).

Herein, we explored the role of chronic stress in oral homeostasis. On the one hand, chronic stress could regulate the morphological structure of the oral epithelium. On the other hand, we found significant differences in the expression of tight junction and mucin-type O-glycan biosynthesis in the tongues of GF and SPF mice, consistent with the literature (36). In this respect, the loss of O-glycosyltransferase in oral mucus-secreting cells led to changes in oral microbial composition, suggesting that O-glycosylation regulated microbial composition and the stability of colonization (36). Mucin is a protein with high-density O-glycosylated serine and threonine residue domains, closely related to microbial dysregulation in the mucosa (37). In saliva, N- and O-terminal glycan structures may act as bait-binding receptors to competitively inhibit pathogen adherence to oral mucosal surfaces (38). A study found that mucin O-glycan was involved in the microbial-mediated immune tolerance in intestinal mucosa during the development of

microbial-induced gastrointestinal disease. Interestingly, glycosylation patterns in the distal intestinal epithelium of mice have changed under psychological stress, and this region became a marker for resistance to microbial attack (39). In addition to mucin-type O-glycan, tight junctions often act as important regulatory components of transmembrane pattern recognition receptors such as Toll-like receptors to protect the epithelium from exogenous pathogens (40). Compared with SPF mice, the expression of junctional complex molecules in colon epithelial cells of GF mice was decreased, which was consistent with the expression of epithelial permeability factors in tongue tissues of different groups in our study. Oral administration of indole-containing capsules increased the expression of tight junction-related molecules in the colon epithelium of GF mice, resulting in higher resistance to dextran sodium sulfate (DSS)-induced colitis in GF mice (41). Overall, chronic stress can regulate the biological function by modifying the epithelial barrier structure, thus maintaining oral homeostasis against adverse microbial invasion.

There were still some limitations in this study. First, the sample size included in this study was small, which increased the experimental error to some extent. Besides, gender and species heterogeneity in microbial-mediated oral homeostasis emphasize the need for further investigation to understand the underlying mechanisms of pathogenic microbiota and epithelial barrier interactions. Additionally, other oral tissues can be applied for more research. Finally, in addition to chronic stress, more stress models should be considered in further studies.

In conclusion, we investigated the morphological structure and integrated the transcriptomics, proteomics, and metabolomics data to study the microbiota's effects and mechanisms on oral homeostasis. The findings of this study suggest that microbiota may regulate oral homeostasis by affecting structural remodeling and biological function.

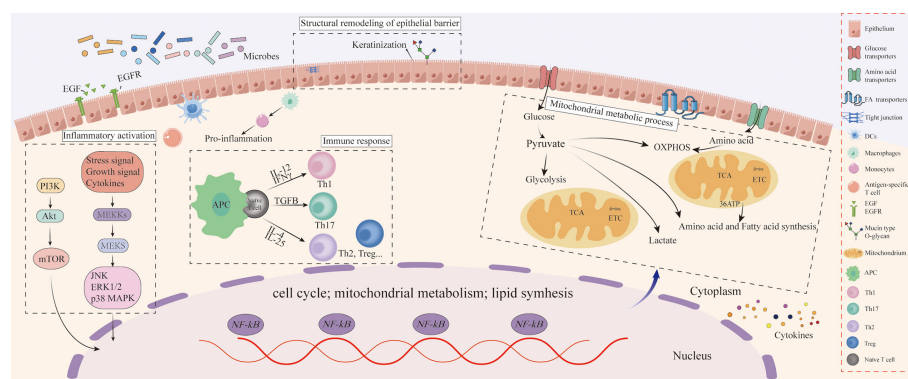


FIGURE 5
Schematic diagram of oral epithelial barrier resistance to microbial invasion.

Furthermore, chronic stress can enhance the regulatory role of microbiota on oral homeostasis by affecting the mitochondrial metabolic process and immune response. This study contributes to existing knowledge of microbiota, and reveals the limitations of previous studies investigating the biological effects of microbiota on oral homeostasis.

Data availability statement

The original contributions presented in the study are included in the article/**Supplementary Material**. Further inquiries can be directed to the corresponding authors.

Ethics statement

The animal study was reviewed and approved by the Institutional Animal Care and Use Committee (IACUC) of Chongqing Medical University and ethical approval was obtained from the Laboratory Animal Ethics Committee of Chongqing Medical University (Approval Number: 2021(063)).

Author contributions

HL contributed to design, and interpretation, drafted and critically revised the manuscript; LiY and XZ contributed to data acquisition and analysis; JP, YiL, and HW contributed to conception and critically revised the manuscript; LuY, FL, and SL contributed to data analysis and interpretation; YZ, YaL, and PX contributed to design and interpretation; JP and XJ contributed to design and critically revised the manuscript. All

authors gave final approval and agree to be accountable for all aspects of the work.

Funding

The study was supported by grants from the National Natural Science Foundations of China (No. 81870775, 81500855, and 81771081).

Conflict of interest

The authors declare that the research was conducted in the absence of any commercial or financial relationships that could be construed as a potential conflict of interest.

Publisher's note

All claims expressed in this article are solely those of the authors and do not necessarily represent those of their affiliated organizations, or those of the publisher, the editors and the reviewers. Any product that may be evaluated in this article, or claim that may be made by its manufacturer, is not guaranteed or endorsed by the publisher.

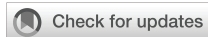Supplementary material

The Supplementary Material for this article can be found online at: <https://www.frontiersin.org/articles/10.3389/fimmu.2022.1005992/full#supplementary-material>

References

1. Dawson DV, Drake DR, Hill JR, Brogden KA, Fischer CL, Wertz PW. Organization, barrier function and antimicrobial lipids of the oral mucosa. *Int J cosmetic Sci* (2013) 35(3):220–3. doi: 10.1111/ics.12038
2. Rigby RJ, Carr J, Orgel K, King SL, Lund PK, Dekaney CM. Intestinal bacteria are necessary for doxorubicin-induced intestinal damage but not for doxorubicin-induced apoptosis. *Gut Microbes* (2016) 7(5):414–23. doi: 10.1080/19490976.2016.1215806
3. Jain R, Waldvogel-Thurlo S, Darveau R, Douglas R. Differences in the paranasal sinuses between germ-free and pathogen-free mice. *Int Forum Allergy rhinol* (2016) 6(6):631–7. doi: 10.1002/alr.21712
4. Matsha TE, Prince Y, Davids S, Chikite U, Erasmus RT, Kengne AP, et al. Oral microbiome signatures in diabetes mellitus and periodontal disease. *J Dental Res* (2020) 99(6):658–65. doi: 10.1177/0022034520913818
5. Yang SF, Lin CW, Chuang CY, Lee YC, Chung WH, Lai HC, et al. Host genetic associations with salivary microbiome in oral cancer. *J Dental Res* (2022) 101(5):590–8. doi: 10.1177/00220345211051967
6. Werner H, Hakeberg M, Dahlström L, Eriksson M, Sjögren P, Strandell A, et al. Psychological interventions for poor oral health: A systematic review. *J Dental Res* (2016) 95(5):506–14. doi: 10.1177/0022034516628506
7. De Porras-Carrique T, González-Moles M, Warnakulasuriya S, Ramos-García P. Depression, anxiety, and stress in oral lichen planus: a systematic review and meta-analysis. *Clin Oral investigations* (2022) 26(2):1391–408. doi: 10.1007/s00784-021-04114-0
8. Rezazadeh F, Farahmand F, Hosseinpour H, Shahriarirad R, Sabet Eghlidi A. The association between emotional stress, sleep disturbance, depression, and burning mouth syndrome. *BioMed Res Int* (2021) 2021:5555316. doi: 10.1155/2021/5555316
9. Yuan L, Pan B, Wang W, Wang L, Zhang X, Gao Y. Prevalence and predictors of anxiety and depressive symptoms among patients diagnosed with oral cancer in China: a cross-sectional study. *BMC Psychiatry* (2020) 20(1):394. doi: 10.1186/s12888-020-02796-6
10. Wang YH, Li JQ, Shi JF, Que JY, Liu JJ, Lappin JM, et al. Depression and anxiety in relation to cancer incidence and mortality: a systematic review and meta-analysis of cohort studies. *Mol Psychiatry* (2020) 25(7):1487–99. doi: 10.1038/s41380-019-0595-x
11. Verza FA, Valente VB, Oliveira LK, Kayahara GM, Crivelini MM, Furuse C, et al. Social isolation stress facilitates chemically induced oral carcinogenesis. *PloS One* (2021) 16(1):e0245190. doi: 10.1371/journal.pone.0245190

12. Guo Y, Wang B, Gao H, He C, Hua R, Gao L, et al. Insight into the role of psychological factors in oral mucosa diseases. *Int J Mol Sci* (2022) 23(9):4760. doi: 10.3390/ijms23094760
13. Aufdemorte TB, Cameron IL. The relation of keratinization to bacterial colonization on the baboon tongue as demonstrated by scanning electron microscopy. *J Dental Res* (1981) 60(6):1008–14. doi: 10.1177/00220345810600060201
14. Zitzmann NU, Berglundh T, Marinello CP, Lindhe J. Expression of endothelial adhesion molecules in the alveolar ridge mucosa, gingiva and periimplant mucosa. *J Clin periodontol* (2002) 29(6):490–5. doi: 10.1034/j.1600-051x.2002.290603.x
15. Williams AM, Probert CS, Stepankova R, Tlaskalova-Hogenova H, Phillips A, Bland PW. Effects of microflora on the neonatal development of gut mucosal T cells and myeloid cells in the mouse. *Immunology* (2006) 119(4):470–8. doi: 10.1111/j.1365-2567.2006.02458.x
16. Richter GM, Kruppa J, Keceli HG, Ataman-Duruel ET, Graetz C, Pischon N, et al. Epigenetic adaptations of the masticatory mucosa to periodontal inflammation. *Clin Epigenet* (2021) 13(1):203. doi: 10.1186/s13148-021-01190-7
17. Chen W, Alshaikh A, Kim S, Kim J, Chun C, Mehrzarin S, et al. Porphyromonas gingivalis impairs oral epithelial barrier through targeting GRHL2. *J Dental Res* (2019) 98(10):1150–8. doi: 10.1177/0022034519865184
18. Roxas JL, Koutsouris A, Viswanathan VK. Enteropathogenic escherichia coli-induced epidermal growth factor receptor activation contributes to physiological alterations in intestinal epithelial cells. *Infection Immun* (2007) 75(5):2316–24. doi: 10.1128/iai.01690-06
19. Chen L, Liu Q, Liu Z, Li H, Liu X, Yu H. EGF protects epithelial cells from barrier damage in chronic rhinosinusitis with nasal polyps. *J Inflamm Res* (2022) 15:439–50. doi: 10.2147/jir.s345664
20. Yu M, Kim J, Ahn JH, Moon Y. Nononcogenic restoration of the intestinal barrier by E. coli-delivered Hum EGF. *JCI Insight* (2019) 4(16):e125166. doi: 10.1172/jci.insight.125166
21. Terakado M, Gon Y, Sekiyama A, Takeshita I, Kozu Y, Matsumoto K, et al. The Rac1/JNK pathway is critical for EGFR-dependent barrier formation in human airway epithelial cells. *Am J Physiol Lung Cell Mol Physiol* (2011) 300(1):L56–63. doi: 10.1152/ajplung.00159.2010
22. Lamb-Rosteski JM, Kalischuk LD, Inglis GD, Buret AG. Epidermal growth factor inhibits campylobacter jejuni-induced claudin-4 disruption, loss of epithelial barrier function, and escherichia coli translocation. *Infection Immun* (2008) 76(8):3390–8. doi: 10.1128/iai.01698-07
23. Soong G, Martin FJ, Chun J, Cohen TS, Ahn DS, Prince A. Staphylococcus aureus protein a mediates invasion across airway epithelial cells through activation of RhoA GTPase signaling and proteolytic activity. *J Biol Chem* (2011) 286(41):35891–8. doi: 10.1074/jbc.M111.295386
24. Epstein JB, Gorsky M, Guglietta A, Le N, Sonis ST. The correlation between epidermal growth factor levels in saliva and the severity of oral mucositis during oropharyngeal radiation therapy. *Cancer* (2000) 89(11):2258–65. doi: 10.1002/1097-0142(20001201)89:11<2258::aid-cncr14>3.0.co;2-z
25. Shang L, Deng D, Buskermolen JK, Roffel S, Janus MM, Krom BP, et al. Commensal and pathogenic biofilms alter toll-like receptor signaling in reconstructed human gingiva. *Front Cell Infect Microbiol* (2019) 9:282. doi: 10.3389/fcimb.2019.00282
26. Tsay JJ, Wu BG, Badri MH, Clemente JC, Shen N, Meyn P, et al. Airway microbiota is associated with upregulation of the PI3K pathway in lung cancer. *Am J Respir Crit Care Med* (2018) 198(9):1188–98. doi: 10.1164/rccm.201710-2118OC
27. Ansaldo E, Slayden LC, Ching KL, Koch MA, Wolf NK, Plichta DR, et al. Akkermansia muciniphila induces intestinal adaptive immune responses during homeostasis. *Sci (New York NY)* (2019) 364(6446):1179–84. doi: 10.1126/science.aaw7479
28. Mazmanian SK, Liu CH, Tzianabos AO, Kasper DL. An immunomodulatory molecule of symbiotic bacteria directs maturation of the host immune system. *Cell* (2005) 122(1):107–18. doi: 10.1016/j.cell.2005.05.007
29. Gómez H, Kellum JA, Ronco C. Metabolic reprogramming and tolerance during sepsis-induced AKI. *Nat Rev Nephrol* (2017) 13(3):143–51. doi: 10.1038/nrneph.2016.186
30. Gleeson LE, Sheedy FJ. Metabolic reprogramming & inflammation: Fuelling the host response to pathogens. *Semin Immunol* (2016) 28(5):450–68. doi: 10.1016/j.smim.2016.10.007
31. Raud B, McGuire PJ, Jones RG, Sparwasser T, Berod L. Fatty acid metabolism in CD8(+) T cell memory: Challenging current concepts. *Immunol Rev* (2018) 283(1):213–31. doi: 10.1111/immr.12655
32. Wong Fok Lung T, Monk IR, Acker KP, Mu A, Wang N, Riquelme SA, et al. Staphylococcus aureus small colony variants impair host immunity by activating host cell glycolysis and inducing necroptosis. *Nat Microbiol* (2020) 5(1):141–53. doi: 10.1038/s41564-019-0597-0
33. O'Neill LA, Hardie DG. Metabolism of inflammation limited by AMPK and pseudo-starvation. *Nature* (2013) 493(7432):346–55. doi: 10.1038/nature11862
34. Kelly B, O'Neill LA. Metabolic reprogramming in macrophages and dendritic cells in innate immunity. *Cell Res* (2015) 25(7):771–84. doi: 10.1038/cr.2015.68
35. Furuhashi M, Hotamisligil GS. Fatty acid-binding proteins: role in metabolic diseases and potential as drug targets. *Nat Rev Drug Discov* (2008) 7(6):489–503. doi: 10.1038/nrd2589
36. Peluso G, Tian E, Abusleme L, Munemasa T, Mukaibo T, Ten Hagen KG. Loss of the disease-associated glycosyltransferase Galnt3 alters Muc10 glycosylation and the composition of the oral microbiome. *J Biol Chem* (2020) 295(5):1411–25. doi: 10.1074/jbc.RA119.009807
37. Selwal KK, Selwal MK, Yu Z. Mucolytic bacteria: prevalence in various pathological diseases. *World J Microbiol Biotechnol* (2021) 37(10):176. doi: 10.1007/s11274-021-03145-9
38. Everest-Dass AV, Jin D, Thaysen-Andersen M, Nevalainen H, Kolarich D, Packer NH. Comparative structural analysis of the glycosylation of salivary and buccal cell proteins: innate protection against infection by candida albicans. *Glycobiology* (2012) 22(11):1465–79. doi: 10.1093/glycob/cws112
39. Omata Y, Aoki R, Aoki-Yoshida A, Hiemori K, Toyoda A, Tateno H, et al. Reduced fucosylation in the distal intestinal epithelium of mice subjected to chronic social defeat stress. *Sci Rep* (2018) 8(1):13199. doi: 10.1038/s41598-018-31403-8
40. Foerster EG, Mukherjee T, Cabral-Fernandes L, Rocha JDB, Girardin SE, Philpott DJ. How autophagy controls the intestinal epithelial barrier. *Autophagy* (2022) 18(1):86–103. doi: 10.1080/15548627.2021.1909406
41. Shimada Y, Kinoshita M, Harada K, Mizutani M, Masahata K, Kayama H, et al. Commensal bacteria-dependent indole production enhances epithelial barrier function in the colon. *PloS One* (2013) 8(11):e80604. doi: 10.1371/journal.pone.0080604



OPEN ACCESS

EDITED BY
Zhi Wang,
Sun Yat-sen University, China

REVIEWED BY
Linjun Shi,
Shanghai Jiao Tong University, China
Mihaela-Simona Subtirelu,
University of Medicine and Pharmacy
of Craiova, Romania
Yuan He,
The Affiliated Stomatology Hospital of
Tongji University, China

*CORRESPONDENCE
Qianming Chen
qmchen@scu.edu.cn
Xiaobo Luo
xiaobol@scu.edu.cn

SPECIALTY SECTION
This article was submitted to
Mucosal Immunity,
a section of the journal
Frontiers in Immunology

RECEIVED 08 August 2022
ACCEPTED 14 September 2022
PUBLISHED 29 September 2022

CITATION
Li C, Wu Y, Xie Y, Zhang Y, Jiang S,
Wang J, Luo X and Chen Q (2022)
Oral manifestations serve as potential
signs of ulcerative colitis: A review.
Front. Immunol. 13:1013900.
doi: 10.3389/fimmu.2022.1013900

COPYRIGHT
© 2022 Li, Wu, Xie, Zhang, Jiang, Wang,
Luo and Chen. This is an open-access
article distributed under the terms of
the [Creative Commons Attribution
License \(CC BY\)](https://creativecommons.org/licenses/by/4.0/). The use, distribution
or reproduction in other forums is
permitted, provided the original
author(s) and the copyright owner(s)
are credited and that the original
publication in this journal is cited, in
accordance with accepted academic
practice. No use, distribution or
reproduction is permitted which does
not comply with these terms.

Oral manifestations serve as potential signs of ulcerative colitis: A review

Chunyu Li, Yuqi Wu, Yulang Xie, You Zhang, Sixin Jiang,
Jiongke Wang, Xiaobo Luo* and Qianming Chen*

State Key Laboratory of Oral Diseases, National Clinical Research Center for Oral Diseases, Chinese Academy of Medical Sciences Research Unit of Oral Carcinogenesis and Management, West China Hospital of Stomatology, Sichuan University, Chengdu, China

As an immune dysregulation-related disease, although ulcerative colitis (UC) primarily affects the intestinal tract, extraintestinal manifestations of the disease are evident, particularly in the oral cavity. Herein, we have reviewed the various oral presentations, potential pathogenesis, and treatment of oral lesions related to UC. The oral manifestations of UC include specific and nonspecific manifestations, with the former including pyostomatitis vegetans and the latter encompassing recurrent aphthous ulcers, atrophic glossitis, burning mouth syndrome, angular cheilitis, dry mouth, taste change, halitosis, and periodontitis. Although the aetiology of UC has not been fully determined, the factors leading to its development include immune system dysregulation, dysbiosis, and malnutrition. The principle of treating oral lesions in UC is to relieve pain, accelerate the healing of lesions, and prevent secondary infection, and the primary procedure is to control intestinal diseases. Systemic corticosteroids are the preferred treatment options, besides, topical and systemic administration combined with dietary guidance can also be applied. Oral manifestations of UC might accompany or precede the diagnosis of UC, albeit with the absence of intestinal symptoms; therefore, oral lesions, especially pyostomatitis vegetans, recurrent aphthous ulcer and periodontitis, could be used as good mucocutaneous signs to judge the occurrence and severity of UC, thus facilitating the early diagnosis and treatment of UC and avoiding severe consequences, such as colon cancer.

KEYWORDS

ulcerative colitis, inflammatory bowel disease, oral manifestation, immune dysfunction, pyostomatitis vegetans

Introduction

Ulcerative colitis (UC) is a chronic inflammatory disease of the gastrointestinal tract. Along with Crohn's disease (CD), UC is one major type of the inflammatory bowel disease (IBD) family. Although its aetiology has not been completely determined, the factors contributing to disease development include genetic predisposition,

environmental factors, immune system dysregulation, dysbiosis, and malnutrition (1, 2), of which immune dysfunction ranks as one of the most dominant aetiologies. Numerous studies have suggested that ulcerative colitis is a modified T-helper (Th) 2 disease, in which the innate immune system initiates the inflammatory events, with the adaptive immune system perpetuating the inflammatory cascade (3, 4). Similarly, another study has reported the differences in mucosal and systemic immune profiles between early and late stage disease in patients with active UC (5). Specifically, a transition from a Th1- to a Th2-driven state is revealed in the intestine of patients with UC in the late stage of disease (5).

The highest reported annual incidences of UC are 24.3, 19.2 and 6.3 per 100 000 persons in Europe, North America, and Asia together with the Middle East (6), respectively. The female-to-male ratio ranges from 0.51 to 1.58 for the incidence of UC, suggesting that the diagnosis of UC is not sex-specific (6). The peak age in most UC studies was between 20 and 40 years of age, with 51.1% of studies reporting the highest incidences of UC among people aged 20–29 years (6). The current mortality rate of patients with UC is close to or slightly higher than that of the general population (7, 8), implying the potential threat of UC. Moreover, patients with long-term UC are more likely to develop colorectal cancer than healthy controls (9). The more extensive and active the disease, the poorer the prognosis in patients with UC (10).

Common clinical features of UC consist of abdominal pain, diarrhoea, rectal bleeding, and other gastrointestinal symptoms (11). Currently, the diagnosis of UC is based on typical clinical symptoms and histological and endoscopic evidences (12), among which colonoscopy combined with biopsy is regarded as the gold standard. Specifically, endoscopy might reveal ulceration, exudate, fragility, granular mucosa, and loss of a typical vascular pattern (13, 14). However, patients with early intestinal discomfort might not be willing to undergo endoscopy. Other than these frequent symptoms of the gastrointestinal tract, 6–40% of patients suspected of having IBD might also present with various extraintestinal manifestations. Notably, the occurrence of extraintestinal manifestations may precede the ultimate diagnosis of IBD (15–18).

A substantial proportion of patients with UC may exhibit lesions within the oral cavity and perioral skin, which can occur prior to, or parallel with UC activity (18). Lesions in the oral cavity harbour innate superiority over other sites for the early detection of UC. First, oral lesions are easy to observe and examine, thus facilitating the early diagnosis of the intestinal disease; second, some oral lesions related to UC that require pathological diagnosis, such as pyostomatitis vegetans (PSV), exhibit the advantage of being observation-intuitive and biopsy-convenient compared with other sites (19). Thus, oral manifestations could serve as good cutaneous signs of the disease severity of UC, and recognition of these signs could contribute to the early detection of IBD (20). This article reviews

the various oral presentations, potential pathogenesis, and treatment of oral lesions related to UC, providing guidance for clinicians in managing, diagnosing, and treating these challenging oral manifestations.

Oral manifestations of UC

UC may be characterised by a series of specific and nonspecific oral lesions, as described in detail below (Table 1).

Specific oral lesions

Pyostomatitis vegetans is a rare chronic mucocutaneous inflammatory disease associated with IBD and remarkably associated with UC. Thus, PSV is regarded as a highly specific marker of UC (27, 31). Lourenço et al. reported that one patient who was initially diagnosed with mild colitis accompanied by PSV, had typical features of UC on colonoscopy 2 years later (20). A recent study indicated that the subsequent onset of PSV was observed in a patient with UC upon aggravation of gastrointestinal symptoms, suggesting that PSV may indicate active or aggravated UC (32). Moreover, a patient with active UC presented with PSV after receiving an initial coronavirus disease 2019 (COVID-19) vaccination, implying the potential immunological link between the onset of PSV and UC, which might have been triggered by the vaccination (33).

As for the clinical characteristics, PSV tends to be more prevalent in patients aged between 20 and 59 years, among which men have a higher incidence than women (34, 35). Distinct clinical manifestations of PSV include miliary abscesses and pustular lesions, with white or yellow contents accompanied by erythematous and oedematous mucosal bases. Pustular lesions are prone to rupture, resulting in erosions and a characteristic ulceration resembling the morphology of the ‘snail track’ (31, 36, 37). Oral lesions predominantly involve the lips, gingiva, and buccal mucosa, although pustules may occur in the entire oral cavity (Figure 1). Patients may experience fever, localised pain, or enlarged and tender submandibular lymph nodes (38). In addition, the principal histological features of PSV are intraepithelial and subepithelial microabscesses, accompanied by infiltration of neutrophils and eosinophils. Furthermore, hyperkeratosis, acanthosis, and focal acantholysis may be present (20, 35).

The diagnosis of PSV is based on clinical manifestations, including concurrent IBD, peripheral eosinophilia, and histological characteristics (20, 38). Although the pathogenesis of PSV is undetermined, it is hypothesised that the abnormal immune response to unidentified factors or the presence of cross-reactive antigens in the bowel and skin leads to these secondary mucocutaneous manifestations (38). In general, PSV can resolve if the underlying UC is sufficiently controlled; however, topical corticosteroids or tacrolimus ointment can be applied to oral lesions (19, 39, 40).

TABLE 1 Specific and nonspecific oral manifestations in patients with UC.

Oral diseases	Manifestations	Disease specificity	Treatment
Pyostomatitis vegetans	Miliary abscess and pustular lesions with white or yellow contents Erythematous and edematous mucosal base “Snail track” ulcers	Specific	Drug therapy: Topical antiseptic mouthwashes (chlorhexidine), corticosteroids (triamcinolone acetonide paste or betamethasone mouthwash), systemic steroid therapy (21, 22)
Recurrent aphthous ulcer	Recurrent bouts of one or more shallow, rounded, or ovoid painful ulcers Clear boundaries, red and slightly raised margin, and covered by yellow or white pseudomembrane Minor RAU are the most common type in UC	Not specific	Drug therapy: Topical steroids, antiseptic mouthwash, nonsteroidal anti-inflammatory pastes (23) Non-drug therapy: Laser therapy (24)
Atrophic glossitis	Glossy tongue appearance with red background Painful, burning sensation of oral mucosa and dry mouth	Not specific	Drug therapy: Vitamin and iron supplements (25)
Burning mouth syndrome	Burning sensation of the oral mucosa Dry mouth and taste disturbances	Not specific	Drug therapy: Anticonvulsants, antidepressants, phytochemicals, saliva substitute (26) Non-drug therapy: Food supplements, lower-level laser therapy, transcranial magnetic stimulation, oral appliances, cognitive behavioural therapy (26)
Angular cheilitis	Erythema, scaling, rhagades, ulcerations, and crusting of the lip corners along with the adjacent skin	Not specific	Drug therapy: Vitamin supplements, 5-ASA mouthwashes, topical steroids (1% hydrocortisone), intra-lesional steroids (27)
Taste change	Taste change	Not specific	Drug therapy: Iron, zinc, or vitamin supplements (28)
Halitosis	Halitosis	Not specific	Drug therapy: Topical mouthwash (29) Non-drug therapy: Tongue brushing (29)
Periodontitis	More severe gingival bleeding, fewer teeth, greater pocket probing depth, and higher frequency of sites with clinical attachment loss	Not specific	Drug therapy: Antibiotics (30) Non-drug therapy: Supragingival scaling and root planning, periodontal surgery (30)

UC, Ulcerative colitis; RAU, Recurrent aphthous ulcer; ASA, aminosalicilic acid.

Nonspecific oral lesions

Patients with active UC may be at a higher risk of experiencing more oral diseases that negatively affect their quality of life than those without active UC (41). Nonspecific oral lesions in UC are observed to be more prevalent than specific lesions (37), including recurrent aphthous ulcer (RAU), atrophic glossitis (AG), burning mouth syndrome (BMS), angular cheilitis (AC), dry mouth, taste change, halitosis, and periodontitis.

Recurrent aphthous ulcer

The most common oral mucosal lesions which occur in patients with UC are RAU (42, 43). The clinical manifestations of RAU associated with UC appear to be similar to those of RAU in the general population. It is characterised by the recurrence of one or more shallow round or ovoid ulcers with clear boundaries, surrounded by red and slightly raised margins, and covered by yellow or white pseudomembranes. Ulcers are usually painful and affect mastication as well as speech (31). Recurrent aphthous ulcers tends to involve the buccal mucosa, labial mucosa, tongue, soft palate, and other non-masticatory mucosa (44).

Currently, three clinical presentations of RAU are recognised: minor, major, and herpetiform, of which the minor type is the most frequent type found in patients with UC, presenting as small and superficial round or oval ulcers that are similar to the ulcers in the colon (45–47).

Scholars have reached controversial conclusions regarding the association between RAU and UC. One study reported that the frequency of RAU in 105 patients with UC, aged from 17 to 82 years, was 18.1% among those with extraintestinal manifestations, and 27.8% of patients were diagnosed with RAU before the diagnosis of IBD among those presenting with oral manifestations (18). Similarly, another team have showed that the frequency of aphthous ulcers in 50 patients with UC was 20% (42). Another study reported that the frequency of oral manifestations among 119 patients with UC, aged from 19 to 77 years, was 29.4%, and 15.1% of patients were diagnosed as RAU, accounting for more than half of the oral manifestations (48). Besides, Khozeimeh and colleagues showed that RAU could appear 1–3 years before the diagnosis of UC (48). Furthermore, Habashneh et al. pointed out that the incidence of deep oral ulceration in patients with UC was markedly higher than in participants without UC ($p=0.004$) (49). Moreover, Laranjeira et al. found that 35.3% of patients complained about the occurrence of RAU within the active stage of IBD, compared with 4.2% in the remissive phase of IBD (50). Similarly, the exacerbation of RAU was reported during UC recurrence (36); Elahi et al. found the frequency of RAU in patients with severe UC was 46%, 18% in patients with moderate UC, and 5% in patients with mild UC (42). All studies suggested that the assessment of RAU severity might be employed as an indicator of UC relapse and recurrence. However, a few studies have not shown a significant relationship between UC disease activity and

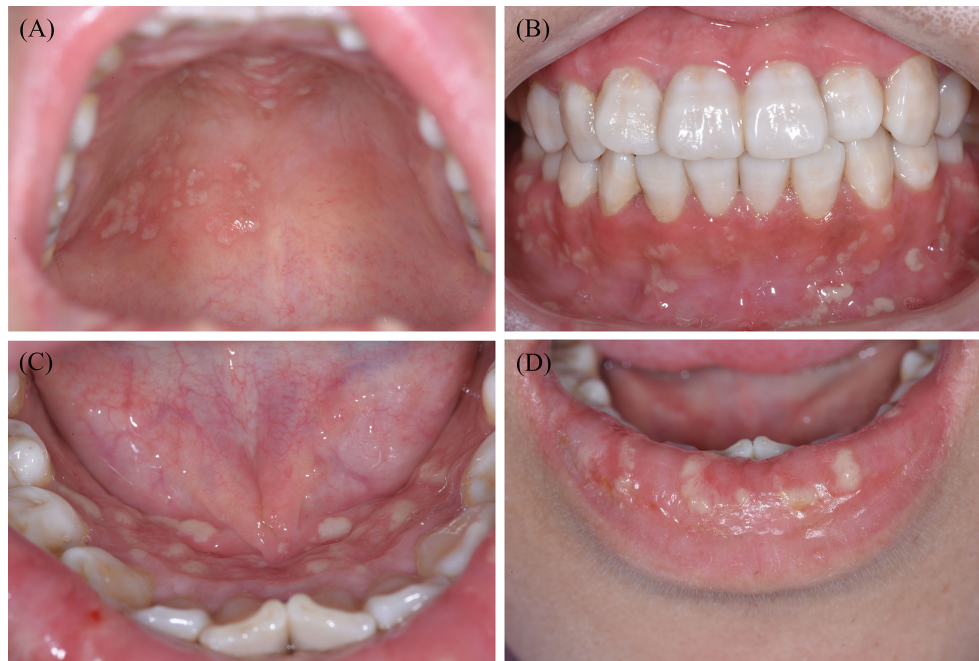

FIGURE 1

Typical clinical features of one patient with PSV in our clinic. Widespread yellow or white pustular lesions as well as its secondary ulcers were observed on the palate (A), the labial gingivae (B), the anterior floor of mouth (C), and the lower lip (D) of the patient. PSV, Pyostomatitis vegetans.

RAU frequency (16, 41); for instance, one study found that the frequency of RAU in patients with active UC was 4.1%, while that in patients with inactive UC was 3%, with no statistical difference indicated (16). Another research implied that the frequency of RAU in patients with active UC was 21.4%, while that in patients with inactive UC was 29.7%, with no statistical difference suggested (41). More well-designed multi-centre studies are warranted to validate the association between RAU and UC.

Other oral mucosal lesions associated with ulcerative colitis

Atrophic glossitis or smooth tongue is an atrophic change of the tongue mucosa which might exhibit a glossy appearance with a red background, caused by atrophy of the filiform papillae (51). Histologically, epithelial atrophy and chronic inflammation of the subepithelial connective tissue are key features of AG (52). The main symptoms reported in previous research were pain, burning sensation in the oral mucosa, and dry mouth. Atrophic glossitis is more common in CD than in UC; and the incidence of AG in patients with UC along with its association with disease activity remains unclear (25). Further studies are required to fill this gap in the field.

Patients with BMS mainly present with a burning sensation of the oral mucosa, sometimes accompanied by dry mouth, taste

disturbances, and other discomfort. Usually, the burning sensation is bilateral, and most commonly involves the tongue, followed by the labial mucosa and anterior hard palate (53, 54). Goldinova et al. found that 9.8% of patients with UC suffered from BMS, compared with an absence of BMS in the control group without UC. Moreover, BMS was found in 14.3% and 8.1% of patients with UC in active or inactive phase of the intestinal disease, respectively (41). The authors also demonstrated that subjective perception of dry mouth is related to disease activity of UC, while no correlation was found with the objective salivary secretion rate (41).

Angular cheilitis is characterised by erythema, scaling, rhagades, ulcerations, and crusting of the lip corners and adjacent skin (55). Klichowska-Palanka et al. reported that the incidence of AC in paediatric patients with UC is approximately 12.5% (56). Furthermore, Goldinova and colleagues found that 21.6% of patients with UC had AC, compared with none in the control group without UC (41). Thus, AC may serve as another associated condition of UC.

Additionally, Melis et al. reported that patients with IBD had impaired salty, sweet, bitter, umami, and fat tastes but an increased sour taste (28). Elahi et al. found that 40% of patients with UC presented with taste change, while 68% of patients with UC had halitosis, which demonstrated a statistically significant difference from the control set (42).

Katz et al. included 20 patients with UC, 10 of whom were in the active disease stage. The incidence of halitosis was notably higher in the active UC group than in the control group (50% versus 10%) (57). Additionally, another study indicated that in the presence of the perinuclear antineutrophil cytoplasmic antibody, immunoglobulins A and G, anti-*Saccharomyces cerevisiae* antibodies, antibodies to *Escherichia coli* outer membrane porin C, anti-flagellin antibody, fragments of *Pseudomonas fluorescens* bacterial DNA, and other serological immune markers (58), further investigation with colonoscopy might be prompted to exclude the diagnosis of IBD.

Periodontitis

Periodontitis is one of the most common oral diseases that is closely related to systemic diseases; which is inseparable from systemic and local immune dysregulation (59). To date, various studies have demonstrated inconsistent results on the relationship between periodontitis and the occurrence of UC.

Four meta-analyses revealed that, compared to healthy controls, patients with UC were significantly more likely to experience periodontitis, have fewer teeth, greater pocket probing depth, and higher frequency of sites with clinical attachment loss (CAL) >3mm (60–63). Habashneh et al. highlighted that patients with UC had more severe and significantly higher risk of developing periodontitis than patients without IBD (49). Another study found that, compared with healthy control subjects, IBD patients exhibited more severe gingival bleeding ($p < 0.01$), periodontitis ($p = 0.04$) and higher CAL ($p < 0.01$) (64). Vavricka et al. had reached similar conclusions. Moreover, IBD, as a spectrum of diseases, is also regarded as a significant risk factor for periodontitis (OR=3.35) (65). Koutsochristou et al. reported that there was an increased incidence of periodontal disease in children and adolescents with IBD, although the oral hygiene indicators were comparable to controls (66).

Contrastingly, Grössner et al. found no significant differences regarding the periodontal findings for patients with or without IBD (67). Tan et al. reported that, compared with non-IBD patients, the DPSI (Dutch Periodontal Screening Index) scores were not significantly increased in UC patients (68).

Taken together, the manifestations of PSV, RAU, AG, BMS, AC, dry mouth, taste change, halitosis and periodontitis may serve as a clue to the diagnosis of UC (18, 20, 25, 41, 42, 56, 61); Among these, RAU and periodontitis might serve as a strong sign of latent UC through assessing these relevant studies using Grading of Recommendations Assessment, Development and Evaluation (GRADE) standard (69), and PSV, as a rare disease, may represent the relatively specific sign of UC to some extent (Table 2). Therefore, when patients present with these oral manifestations, they should be screened for UC by enquiring specifically about potential UC-related gastrointestinal

symptoms upon history-taking. If necessary, relevant antibodies tests, and endoscopy as well as biopsy should be considered by gastroenterologists to determine the presence of UC and potential intestinal cancer.

Pathogenesis

The exact pathologic mechanism of the oral manifestations associated with UC is still uncharacterised but is potentially related to dysbiosis, immune system dysregulation, and malnutrition (Figure 2).

Dysbiosis

Several studies have indicated a possible correlation between dysbiosis of the gut, and oral microbiota, with the latter causing UC-related oral manifestations. Said et al. have demonstrated that oral dysbiosis, manifesting as a relative abundance of *Streptococcus*, *Haemophilus*, *Prevotella*, and *Veillonella* in the oral cavity, was closely related to the inflammatory response triggered by lower saliva lysozyme and increased interleukin (IL)-1 β levels which might be related to dysbiosis of the gut microbiota (70). In addition, Xun et al. found that *Streptococcus*, *Corynebacterium*, *Lautropia*, *Acinetobacter*, and *Cardiobacterium* were observably enriched in the oral cavity of UC patients, while *Anaerovorax*, *Porphyromonas*, *Prevotella*, *Catonella*, *Oribacterium*, and *Peptostreptococcus* were significantly eliminated in the oral cavity of these patients. Simultaneously, their study also showed that the biosynthesis and transport of substances that enhance oxidative stress and virulence, bacterial violence, enzyme families activity, and the frequency of apoptosis in the oral region were increased in patients with UC, thus suggesting that the presence of both oral dysbiosis and functional disorders might be associated with UC (71).

With regards to oral dysbiosis, Molinero et al. found that *Proteobacteria* and *Neisseriaceae* in the saliva were higher in the UC group, while *Peptostreptococcaceae*, *Atopobiaceae*, *Lachnospiraceae*, and *Ruminococcaceae* were significantly reduced. They also reported that the *Staphylococcus* species and its four differential species or phylotypes were only present in UC patients, and not in the control group (72). Further, changes in salivary lysozyme levels may be associated with gut dysbiosis and is responsible for the resulting periodontitis (73). Therefore, the secondary inflammatory responses induced by UC play a critical role in the development of oral manifestations such as periodontitis (74).

Additionally, the resemblance between oral and gut microbiota might be another factor bridging UC and oral lesions. One study demonstrated that *Enterobacteriaceae* residing in saliva, particularly *Klebsiella*, were considered as potent Th1 inducers in the gut that might trigger pathogenic

TABLE 2 Evaluation of the level of evidence-based medicine of these research findings.

References	Oral manifestations	Research type	GRADE classification
Vavricka 2011 (16)	RAU	Cohort study	Moderate
Vavricka 2015 (18)	RAU	Cohort study	Moderate
Kamal 2020 (19)	PSV	Case report	Very low
Lourenço 2010 (20)	PSV	Case reports	Very low
Zeng 2022 (32)	PSV	Case report	Very low
Hou 2022 (33)	PSV	Case report	Very low
Ruiz-Roca 2005 (35)	PSV	Case report	Very low
Kumar2018 (36)	RAU	Case-control study	Low
Yasuda 2008 (39)	PSV	Case report	Very low
Werchniak 2005 (40)	PSV	Case report	Very low
Goldinova 2020 (41)	RAU, BMS, AC, dry mouth	Cohort study	Low
Elahi 2012 (42)	RAU, taste change, halitosis	Case-control study	Low
Khozeimeh 2021 (48)	RAU	Cross-sectional study	Low
Habashneh 2012 (49)	RAU, periodontitis	Case-control study	Low
Laranjeira 2015 (50)	RAU	Case-control study	Low
Klichowska-Palotka 2021 (56)	AC	Case-control study	Low
Melis 2020 (28)	Taste change	Case-control study	Low
Katz 2003 (57)	Halitosis	Case-control study	Low
She 2020 (60)	Periodontitis	Meta analysis	Moderate
Zhang 2021 (61)	Periodontitis	Meta analysis	Moderate
Lorenzo-Pouso 2021 (62)	Periodontitis	Meta analysis	Moderate
Papageorgiou 2017 (63)	Periodontitis	Meta analysis	Moderate
Schmidt 2018 (64)	Periodontitis	Case-control study	Low
Vavricka 2013 (65)	Periodontitis	Cohort study	Moderate
Koutsochristou 2015 (66)	Periodontitis	Case-control study	Low
Grössner-Schreiber 2006 (67)	Periodontitis	Case-control study	Low
Tan 2021 (68)	Periodontitis	Case-control study	Low

GRADE, Grading of Recommendations Assessment, Development and Evaluation; PSV, pyostomatitis vegetans; RAU, Recurrent aphthous ulcer; BMS, burning mouth syndrome; AC, angular cheilitis.

immune responses during ectopic intestinal colonisation (75). The inflammatory state of IBD may render the intestine more permissive to aerotolerant oral-derived bacteria than a steady-state intestine, and the continuous colonisation of oral bacteria may contribute to intestinal microbiota dysbiosis and chronic inflammation, thus intensifying the UC. Moreover, several studies have reported that *Enterobacteriaceae*, including *E. coli* and *Klebsiella*, which mainly appear in the gut, also reside in the oral cavity of humans (76, 77). Rautava et al. found that dysbiosis in murine models of colitis was related to changes in the composition of the bacteria present in saliva and in the oral cavity. Such changes in the oral microbiota may be related to the aetiology of the oral mucosal pathologies in patients with IBD (78). Thus, the oral microbiota may serve as a link between IBD types such as UC, and the related oral manifestations.

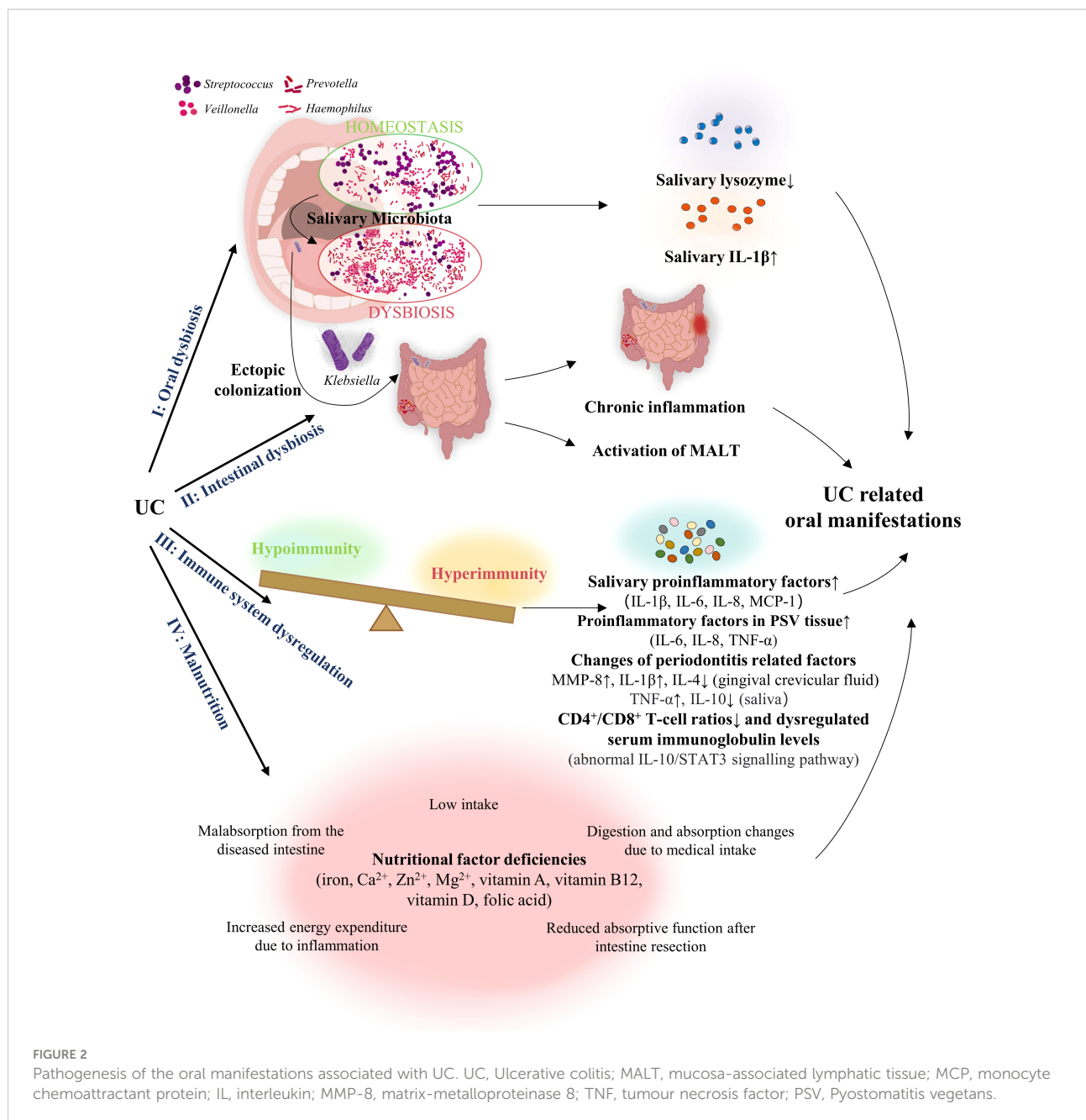
Moreover, intestinal dysbiosis has been reported to cause a chronic inflammatory state and mucosa-associated lymphatic tissue (MALT) activation in the intestine, which leads to extraintestinal pathologies (79–81). On this basis, Cappello

et al. hypothesised that oral aphthous-like ulcers in patients with IBD could be the result of concomitant intestinal dysbiosis and other events, e.g., microtraumas of the oral mucosa (82). Adjuvant therapy with probiotics has been shown to be effective in treating aphthous-like ulcers, serving as proof for this hypothesis (82).

In summary, dysbiosis of microbiota in UC may be correlated with that in the oral cavity, and secondary inflammatory responses within the gut might be responsible for these oral manifestations.

Immune system dysregulation

Several studies have revealed the potential relationship between UC and the oral presentation. As UC is a chronic and severe disease, low levels of IL-10 within the body are insufficient to inhibit the production of pro-inflammatory cytokines, such as IL-6, tumour necrosis factor (TNF)- α , interferon- γ , and IL-17. Thus, the resultant higher IL-17/IL-10 ratio may be a pivotal marker of disease severity and progression based on its



association with intestinal and extra-intestinal features (83). Oral presentations in patients with active UC may be associated with changes in cytokine activity within the gastrointestinal tract and the oral cavity (84). For instance, Said et al. reported elevated salivary levels of IL-6, IL-8, IL-1β, and monocyte chemoattractant protein (MCP)-1 in patients with UC (70). Similarly, Aleksandra et al. demonstrated that patients with UC exhibited higher salivary IL-6 levels (85). Two studies have shown that the IL-10/STAT3 signalling pathway is associated with pediatric IBD, and IL-10 receptor (IL-10R) A

together with IL-10RB mutations, responsible for the abnormal IL-10/STAT3 cascade, are common in Chinese children with IBD (86, 87). Engelhardt et al. indicated that IL-10 and IL-10R deficient patients may display RAU due to mild immunological abnormalities, including reduced CD4⁺/CD8⁺ T-cell ratios and dysregulated serum immunoglobulin levels (88). Thus, these studies suggest that IL-10 related immune abnormalities may explain the initiation of RAU subsequent to UC.

Of note, several dysregulated immune-related cytokines in saliva or oral cavity, which account for periodontitis, might be

related to UC. Schmidt et al. found that, compared with healthy control subjects, patients with IBD showed higher concentration of activated matrix-metalloproteinase 8 (MMP-8) in the gingival crevicular fluid, which has been confirmed as one of the key proteases released by inflammatory cells involved in the progression of periodontitis (64). Figueredo et al. observed that the total level of IL-4, a cytokine related to generalised aggressive periodontitis (89), was significantly reduced in the gingival crevicular fluid obtained from superficial sites of patients with UC (90). Meanwhile, the study also showed markedly enhanced serum IL-18 levels in the UC group, which was positively correlated with increased IL-1 β in the gingival crevicular fluid of these patients. The latter served as a contributor in the pathogenesis of periodontal disease, thus accounting for the occurrence of periodontitis in patients with UC (90). Another study similarly demonstrated an increase of IL-1 β in the gingival crevicular fluid of patients with UC (91). In addition, Enver et al. found that TNF- α levels were significantly higher in the saliva of patients with UC diagnosed with periodontitis, along with a reduction of IL-10 levels (91).

Meanwhile, oral diseases might also promote UC development in an immune-dependent manner. One study indicated that bacteria contributing to periodontitis might stimulate the production of pro-inflammatory cytokines by oral epithelial cells, namely IL-6, IL-8, and TNF- α , thus resulting in the progression of UC (92).

Conversely, UC is a possible immune trigger of oral manifestations. As speculated by Brakenhoff et al., the ability of IBD to induce extra-intestinal inflammatory response is partially due to the recognition of common epitopes throughout the body. Specifically, the extraintestinal manifestations of IBD may be a broad adaptive immune response caused by local intestinal dysbiosis, leading to recognition of these epitopes in gingiva and other oral sites, causing periodontitis (93, 94). Additionally, studies have shown that immune responses to colonic bacteria dysregulation in patients with IBD may trigger T cell-mediated responses and cytokine production, thus inducing PSV (95). Ficarra et al. found that T cells would transfer to the oral mucosa under the influence of antigenic stimulation. Thereafter, the CD8⁺T lymphocytes, as well as the infiltrating macrophages and neutrophils, might induce the epithelial damage and ulceration which are prevalent in PSV (96). They also demonstrated the overexpression of IL-6, IL-8, and TNF- α in PSV, suggesting that these pro-inflammatory cytokines, which lead to the recruitment of inflammatory cells to UC lesions, may synergistically contribute to the proinflammatory pathogenesis of PSV (96). Therefore, these studies suggest that immune system dysregulation may be an important link bridging PSV and UC.

Therefore, these studies suggest that immune system dysregulation may be an important link bridging not only PSV, but also other oral manifestations, and UC.

Malnutrition

Approximately 23% of outpatients and 85% of hospitalised patients with UC develop malnutrition (97). Malnutrition with undernutrition is common in patients with UC due to insufficient intake, malabsorption in the diseased intestine, decreased absorptive function after intestinal resection, increased energy consumption caused by inflammation, and changes in digestion and absorption due to medication intake (98). Patients with UC might develop anaemia due to deficiencies of iron, folic acid, and vitamin B12 from a lack of nutrition (98–100). Sun et al. found that deficiencies in haemoglobin, iron, and vitamin B12 were significantly correlated with AG (101). Wu et al. showed that the incidence of oral features, including lingual varicosity, AG, dry mouth, and burning sensation of the oral mucosa, was considerably higher in patients with iron-deficiency anaemia than in those without (102). Lin et al. showed that patients with BMS have a significantly higher incidence of haemoglobin, iron, or vitamin B12 deficiency (103). Nutritional deficiencies, including deficiencies of iron and B vitamins, impede wound healing and account for 25% of all AC cases (104). Hence, patients with UC are at an increased risk of micronutrient deficiencies, including calcium, iron, vitamin A, vitamin B12, vitamin D, folic acid, magnesium, and zinc (1). Therefore, patients with UC may develop RAU, AG, BMS, AC, dry mouth, taste change, and halitosis due to nutritional deficiencies.

Treatment strategies for UC-related oral discomfort

The purpose of treating oral lesions in UC is to relieve pain, expedite the concrescence of lesions, and prevent secondary infections (37). In most patients with oral lesions associated with UC, initial control of intestinal diseases is critical for the treatment of oral signs (20). Topical and systemic medications combined with dietary instructions may also be used. In brief, the preferred treatment involves the application of systemic corticosteroids, which are often helpful in relieving the oral manifestations of patients with UC. Immunosuppressive and biological agents have also been suggested (105).

Treatment for PSV includes topical use of antiseptic mouthwashes, such as chlorhexidine, and corticosteroids, such as betamethasone mouthwash or triamcinolone acetonide paste. Systemic steroid therapy may also be used to control lesions because of the limited efficacy of topical steroid therapy (21, 22). One case study demonstrated that for PSV lesions in patients with UC, despite the ineffectiveness of topical clobetasol propionic ointment and betamethasone gargle, the administration of dapsone (75 mg/day) successfully controlled PSV in 1 week, and all eruptions disappeared after 4 weeks (106). However, Bardasi et al. reported that oral beclomethasone was

capable of gradually relieving PSV lesions (107). Interestingly, one case study indicated that although partial improvement of PSV lesions was achieved after total colectomy, new lesions appeared 1 month postoperatively. The patient's lesion was topically treated with tacrolimus ointment, which resulted in significant improvement of PSV (39). In contrast, Kitayama et al. showed that after subtotal colectomy for UC, the prescribed medicine to control intestinal symptoms could alleviate the PSV lesion simultaneously. The patient was treated with oral mesalazine, with no recurrence of mucocutaneous or intestinal lesions at follow-up (108).

For UC-related RAU, intestinal symptoms should be initially controlled, and the treatment modality for RAU depends on the frequency and severity of oral ulcers. Given the painful presentation and inflammatory nature of RAU, it responds well to the application of topical or systemic anti-inflammatory agents, especially corticosteroids (23). Topical steroids are the first-line treatment for RAU, whereas topical anaesthetics, antiseptic mouthwash, or nonsteroidal anti-inflammatory pastes can also be utilised (109). Pereira et al. reported that in one case of UC with RAU, the RAU was initially treated with 0.05% dexamethasone mouthwash for 3 months, with the symptoms being completely resolved. Then, the patient was instructed to use 0.05% dexamethasone mouthwash whenever RAU recurred (110).

Laser therapy may also help improve pain control and promote the healing of recalcitrant RAU lesions (24). Aggarwal found that after application of low-level laser therapy for RAU, the patient's pain score decreased immediately and remained stable for 3 follow-up days ($p < 0.001$ for all time periods). Additionally, the size of the lesions after low-level laser therapy decreased significantly ($p < 0.05$) (111).

AG, BMS, and AC are usually caused by anaemia and malnutrition, and iron, folic acid, and vitamin B12 supplements are required in patients with specific deficiencies (98–100). For the management of AG, vitamin and iron supplements may be effective (25). Vitamin supplements, topical steroids (1% hydrocortisone), 5-aminosalicylic acid (5-ASA) mouthwashes, and intralesional steroids may be used to treat AC (27). The primary goal of BMS therapy is to eliminate painful burning disorders. Current treatments for BMS include anticonvulsants, antidepressants, phytomedicines, food supplements, lower-level laser therapy, saliva substitutes, transcranial magnetic stimulation, oral appliances, and cognitive behavioural therapy (26). Taste change may be triggered by iron, zinc, or vitamin deficiency due to rectal bleeding and intestinal malabsorption associated with IBD or by drug therapy (28), which should be supplemented with deficient nutrients or adjusted IBD medication. Tongue brushing and application of topical mouthwash, such as 0.2% chlorhexidine, are effective in treating halitosis (29).

With regard to the UC patient with concurrent periodontitis, routine dental treatment including supragingival scaling and root planning combined with drug therapy such as antibiotics and periodontal surgery are suggested as first-line therapies (30). Further, although no direct evidence exists in terms of the relationship between the UC treatment and periodontal disease's outcome, several findings might serve as auxiliary proof. One study indicated that patients with UC but undiagnosed periodontitis showed improvement in salivary immunoglobulin A and myeloperoxidase after the treatment against UC, suggesting that UC therapy may improve the oral host defense, which is crucial to controlling periodontitis due to its microbial aetiology (112). Another study demonstrated that the treatment of IBD with anti-TNF- α biologic agents increased the probability of periodontal healing (113).

Furthermore, for UC patients with highly resistant or intractable oral lesions that seriously affect oral feeding and quality of life, colectomy may be the ultimate solution (45). A recent study demonstrated that one patient with UC achieved complete remission of PSV immediately after total colectomy due to a final diagnosis of colon adenocarcinoma (114).

Conclusions

Oral manifestations of UC include specific lesions, such as PSV, and nonspecific lesions, namely RAU, AG, BMS, AC, dry mouth, taste change, halitosis, and periodontitis. The pathogenesis of oral manifestations in UC may be related to dysbiosis, immune system dysregulation, and malnutrition. Management of intestinal diseases is the foremost step in the treatment of oral lesions in patients with UC. Topical and systemic medications, including systemic corticosteroids, immunosuppressive agents, and biological agents, combined with dietary instructions can also be used to treat oral signs.

Oral manifestations of UC may be the most intuitive evidence of an underlying systemic disease. Oral lesions may accompany or precede the diagnosis of UC. When oral manifestations are accompanied by abdominal pain, diarrhoea, rectal bleeding, and other intestinal symptoms, stomatologists should cooperate with gastroenterologists to actively investigate the possibility of UC. The presence of oral manifestations, such as PSV, might be a crucial indicator of UC, even in the absence of intestinal symptoms, thereby enabling treatment of the disease at an early stage to prevent more severe consequences, such as colon cancer. However, the incidence of nonspecific oral lesions in patients with UC along with its association with disease activity remains largely uncharacterised. Moreover, the exact pathologic mechanism of the oral manifestations associated with UC has yet to be thoroughly characterised. Further studies are required to fill these gaps.

Author contributions

CL was mainly responsible for drafting and organization of the work, YW and YX collated the literature data and participated in the draft preparation, YZ and SJ conducted the literature search, JW assisted in revision of the work, XL made contributions to the conceptional design and substantively revised the work, QC provided suggestions to the conceptional design of the work and revised the work. All authors have approved the final manuscript.

Funding

The work is funded by National Natural Science Foundation of China (81902782, 82002888, 81730030), Research Funding from West China School/Hospital of Stomatology Sichuan University (No.RCDWJS2022-16), the CAMS Innovation Fund for Medical Sciences (CIFMS, 2019-I2M-5-004),

References

- Owczarek D, Rodacki T, Domagala-Rodacka R, Cibor D, Mach T. Diet and nutritional factors in inflammatory bowel diseases. *World J Gastroenterol* (2016) 22:895–905. doi: 10.3748/wjg.v22.i3.895
- Ramos GP, Papadakis KA. Mechanisms of disease: Inflammatory bowel diseases. *Mayo Clinic Proc* (2019) 94:155–65. doi: 10.1016/j.mayocp.2018.09.013
- Xavier RJ, Podolsky DK. Unravelling the pathogenesis of inflammatory bowel disease. *Nature* (2007) 448:427–34. doi: 10.1038/nature06005
- Ungaro R, Mehandru S, Allen PB, Peyrin-Biroulet L, Colombel J-F. Ulcerative colitis. *Lancet (London England)* (2017) 389:1756–70. doi: 10.1016/S0140-6736(16)32126-2
- Mavroudis G, Magnusson MK, Isaksson S, Sundin J, Simrén M, Öhman L, et al. Mucosal and systemic immune profiles differ during early and late phases of the disease in patients with active ulcerative colitis. *J Crohn's Colitis* (2019) 13:1450–8. doi: 10.1093/ecco-jcc/jjz072
- Molodecky NA, Soon IS, Rabi DM, Ghali WA, Ferris M, Chernoff G, et al. Increasing incidence and prevalence of the inflammatory bowel diseases with time, based on systematic review. *Gastroenterology* (2012) 142. doi: 10.1053/j.gastro.2011.10.001
- Jess T, Gamborg M, Munkholm P, Sørensen TIA. Overall and cause-specific mortality in ulcerative colitis: Meta-analysis of population-based inception cohort studies. *Am J Gastroenterol* (2007) 102:609–17. doi: 10.1111/j.1572-0241.2006.01000.x
- Manninen P, Karvonen AL, Huhtala H, Rasmussen M, Salo M, Mustaniemi L, et al. Mortality in ulcerative colitis and crohn's disease. A population-based study in Finland. *J Crohn's colitis* (2012) 6:524–8. doi: 10.1016/j.crohns.2011.10.009
- Yashiro M. Ulcerative colitis-associated colorectal cancer. *World J Gastroenterol* (2014) 20:16389–97. doi: 10.3748/wjg.v20.i44.16389
- da Silva BC, Lyra AC, Rocha R, Santana GO. Epidemiology, demographic characteristics and prognostic predictors of ulcerative colitis. *World J Gastroenterol* (2014) 20:9458–67. doi: 10.3748/wjg.v20.i28.9458
- Kucharzik T, Koletzko S, Kannengiesser K, Dignass A. Ulcerative colitis—diagnostic and therapeutic algorithms. *Deutsches Arzteblatt Int* (2020) 117:564–74. doi: 10.3238/arztebl.2020.0564
- Feuerstein JD, Cheifetz AS. Ulcerative colitis: Epidemiology, diagnosis, and management. *Mayo Clinic Proc* (2014) 89:1553–63. doi: 10.1016/j.mayocp.2014.07.002
- Langan RC, Gotsch PB, Krafczyk MA, Skilling DD. Ulcerative colitis: diagnosis and treatment. *Am Family physician* (2007) 76:1323–30.
- Fine KD, Seidel RH, Do K. The prevalence, anatomic distribution, and diagnosis of colonic causes of chronic diarrhea. *Gastrointestinal endoscopy* (2000) 51:318–26. doi: 10.1016/S0016-5107(00)70362-2
- Bernstein CN, Blanchard JF, Rawsthorne P, Yu N. The prevalence of extraintestinal diseases in inflammatory bowel disease: A population-based study. *Am J Gastroenterol* (2001) 96:1116–22. doi: 10.1111/j.1572-0241.2001.03756.x
- Vavricka SR, Brun L, Ballabeni P, Pittet V, Prinz Vavricka BM, Zeitz J, et al. Frequency and risk factors for extraintestinal manifestations in the Swiss inflammatory bowel disease cohort. *Am J Gastroenterol* (2011) 106:110–9. doi: 10.1038/ajg.2010.343
- Ricart E, Panaccione R, Loftus EV Jr, Tremaine WJ, Harmsen WS, Zinsmeister AR, et al. Autoimmune disorders and extraintestinal manifestations in first-degree familial and sporadic inflammatory bowel disease: A case-control study. *Inflammation Bowel Dis* (2004) 10:207–14. doi: 10.1097/00054725-200405000-00005
- Vavricka SR, Rogler G, Gantenbein C, Spoorri M, Prinz Vavricka M, Navarini AA, et al. Chronological order of appearance of extraintestinal manifestations relative to the time of IBD diagnosis in the Swiss inflammatory bowel disease cohort. *Inflammation Bowel Dis* (2015) 21:1794–800. doi: 10.1097/MIB.0000000000000429
- Kamal N, Bookwalter A, Foss R, Cross RK. Pyostomatitis vegetans: An unusual oral manifestation of inflammatory bowel disease. *Am J Gastroenterol* (2020) 115:1385. doi: 10.14309/ajg.0000000000000532
- Lourenço SV, Hussein TP, Bologna SB, Sipahi AM, Nico MMS. Oral manifestations of inflammatory bowel disease: A review based on the observation of six cases. *J Eur Acad Dermatol Venereology JEADV* (2010) 24:204–7. doi: 10.1111/j.1468-3083.2009.03304.x
- Trost LB, McDonnell JK. Important cutaneous manifestations of inflammatory bowel disease. *Postgraduate Med J* (2005) 81:580–5. doi: 10.1136/pgmj.2004.031633
- Brinkmeier T, Frosch PJ. Pyodermitis-pyostomatitis vegetans: a clinical course of two decades with response to cyclosporine and low-dose prednisolone. *Acta dermato-venereologica* (2001) 81:134–6. doi: 10.1080/00015550152384290
- Scully C, Gorsky M, Lozada-Nur F. The diagnosis and management of recurrent aphthous stomatitis: A consensus approach. *J Am Dental Assoc* (1939) (2003) 134:200–7. doi: 10.14219/jada.archive.2003.0134
- Saikaly SK, Saikaly TS, Saikaly LE. Recurrent aphthous ulceration: A review of potential causes and novel treatments. *J Dermatol Treat* (2018) 29:542–52. doi: 10.1080/09546634.2017.1422079

the 14th special grant from China Postdoctoral Science Foundation (2021T140484).

Conflict of interest

The authors declare that the research was conducted in the absence of any commercial or financial relationships that could be construed as a potential conflict of interest.

Publisher's note

All claims expressed in this article are solely those of the authors and do not necessarily represent those of their affiliated organizations, or those of the publisher, the editors and the reviewers. Any product that may be evaluated in this article, or claim that may be made by its manufacturer, is not guaranteed or endorsed by the publisher.

25. Sbeit W, Kadah A, Mahamid M, Karayanni H, Mari A, Tali S, et al. Oral manifestations of inflammatory bowel disease: The neglected piece of the puzzle. *Eur J Gastroenterol Hepatol* (2020) 32:1422–31. doi: 10.1097/MEG.0000000000001918
26. Tan HL, Smith JG, Hoffmann J, Renton T. A systematic review of treatment for patients with burning mouth syndrome. *Cephalalgia an Int J Headache* (2022) 42:128–61. doi: 10.1177/03331024211036152
27. Lankarani KB, Sivandzadeh GR, Hassanpour S. Oral manifestation in inflammatory bowel disease: A review. *World J Gastroenterol* (2013) 19:8571–9. doi: 10.3748/wjg.v19.i46.8571
28. Melis M, Mastinu M, Sollai G, Paduano D, Chicco F, Magri S, et al. Taste changes in patients with inflammatory bowel disease: Associations with PROP phenotypes and polymorphisms in the salivary protein, gustin and CD36 receptor genes. *Nutrients* (2020) 12(2):409. doi: 10.3390/nu12020409
29. Bollen CML, Beikler T. Halitosis: The multidisciplinary approach. *Int J Oral Sci* (2012) 4:55–63. doi: 10.1038/ijos.2012.39
30. Graziani F, Karapetsa D, Alonso B, Herrera D. Nonsurgical and surgical treatment of periodontitis: How many options for one disease? *Periodontol 2000* (2017) 75:152–88. doi: 10.1111/prd.12201
31. Field EA, Allan RB. Review article: oral ulceration–aetiopathogenesis, clinical diagnosis and management in the gastrointestinal clinic. *Alimentary Pharmacol Ther* (2003) 18:949–62. doi: 10.1046/j.1365-2036.2003.01782.x
32. Zeng X, Hua H, Hu X. Rare mucocutaneous manifestations of ulcerative colitis: A case report of pyostomatitis vegetans and sweet syndrome. *Oral Surg Oral Med Oral Pathol Oral Radiol* (2022) S2212-4403:01016-1. doi: 10.1016/j.oooo.2022.06.004
33. Hou P-C, Huang H-Y, Lee JY-Y, Hsu C-K. Pyostomatitis vegetans following coronavirus disease 2019 vaccination in a patient with ulcerative colitis. *J Dermatol* (2022) 49:e285–6. doi: 10.1111/1346-8138.16409
34. Hegarty AM, Barrett AW, Scully C. Pyostomatitis vegetans. *Clin Exp Dermatol* (2004) 29:1–7. doi: 10.1111/j.1365-2230.2004.01438.x
35. Ruiz-Roca JA, Berini-Ayts L, Gay-Escoda C. Pyostomatitis vegetans. Report of two cases and review of the literature. *Oral surgery Oral medicine Oral pathology Oral radiology endodontics* (2005) 99:447–54. doi: 10.1016/j.tripleo.2003.08.022
36. Kumar KM, Nachiammai N, Madhushankari GS. Association of oral manifestations in ulcerative colitis: A pilot study. *J Oral Maxillofac Pathol JOMFP* (2018) 22:199–203. doi: 10.4103/jomfp.JOMFP_223_16
37. Muhvić-Urek M, Tomac-Stojmenović M, Mijandrušić-Sinčić B. Oral pathology in inflammatory bowel disease. *World J Gastroenterol* (2016) 22:5655–67. doi: 10.3748/wjg.v22.i25.5655
38. Femiano F, Lanza A, Buonaiuto C, Perillo L, Dell'Ermo A, Cirillo N. Pyostomatitis vegetans: A review of the literature. *Medicina oral patologia Oral y cirugía bucal* (2009) 14:E114–7.
39. Yasuda M, Amano H, Nagai Y, Tamura A, Ishikawa O, Yamaguchi S. Pyodermitis-pyostomatitis vegetans associated with ulcerative colitis: Successful treatment with total colectomy and topical tacrolimus. *Dermatol (Basel Switzerland)* (2008) 217:146–8. doi: 10.1159/000135708
40. Werchniak AE, Storm CA, Plunkett RW, Beutner EH, Dinulos JGH. Treatment of pyostomatitis vegetans with topical tacrolimus. *J Am Acad Dermatol* (2005) 52:722–3. doi: 10.1016/j.jaad.2004.11.041
41. Goldinova A, Tan CX, Bouma G, Duijvestein M, Brand HS, de Boer NK, et al. Oral health and salivary function in ulcerative colitis patients. *United Eur Gastroenterol J* (2020) 8:1067–75. doi: 10.1177/2050640620957138
42. Elahi M, Telkabadi M, Samadi V, Vakili H. Association of oral manifestations with ulcerative colitis. *Gastroenterol Hepatol bed to bench* (2012) 5:155–60.
43. Thrash B, Patel M, Shah KR, Boland CR, Menter A. Cutaneous manifestations of gastrointestinal disease: part II. *J Am Acad Dermatol* (2013) 68 (2):211.e1–246. doi: 10.1016/j.jaad.2012.10.036
44. Cui RZ, Bruce AJ, Rogers RS. Recurrent aphthous stomatitis. *Clinics Dermatol* (2016) 34:475–81. doi: 10.1016/j.clindermatol.2016.02.020
45. Katsanos KH, Torres J, Roda G, Brygo A, Delaporte E, Colombel JF. Review article: Non-malignant oral manifestations in inflammatory bowel diseases. *Alimentary Pharmacol Ther* (2015) 42:40–60. doi: 10.1111/apt.13217
46. Jurge S, Hegarty AM, Hodgson T. Orofacial manifestations of gastrointestinal disorders. *Br J Hosp Med (London Engl 2005)* (2014) 75:497–501. doi: 10.12968/hmed.2014.75.9.497
47. Rogler G, Singh A, Kavanaugh A, Rubin DT. Extraintestinal manifestations of inflammatory bowel disease: Current concepts, treatment, and implications for disease management. *Gastroenterology* (2021) 161:1118–32. doi: 10.1053/j.gastro.2021.07.042
48. Khozeimeh F, Shakerin H, Daghighzadeh H, Najrazadegan F, Golestannejad Z, Adibi P. Oral manifestations in inflammatory bowel disease: A cross-sectional study in isfahan. *Dental Res J* (2021) 18:4. doi: 10.4103/1735-3327.310033
49. Habashneh RA, Khader YS, Alhumouz MK, Jadallah K, Ajlouni Y. The association between inflammatory bowel disease and periodontitis among Jordanians: A case-control study. *J periodontal Res* (2012) 47:293–8. doi: 10.1111/j.1600-0765.2011.01431.x
50. Laranjeira N, Fonseca J, Meira T, Freitas J, Valido S, Leitão J. Oral mucosa lesions and oral symptoms in inflammatory bowel disease patients. *Arg Gastroenterol* (2015) 52:105–10. doi: 10.1590/S0004-28032015000200006
51. Reamy BV, Derby R, Bunt CW. Common tongue conditions in primary care. *Am Family physician* (2010) 81:627–34.
52. Li H, Sun J, Wang X, Shi J. Oral microbial diversity analysis among atrophic glossitis patients and healthy individuals. *J Oral Microbiol* (2021) 13:1984063. doi: 10.1080/20002297.2021.1984063
53. Klein B, Thoppay JR, De Rossi SS, Ciarrocca K. Burning mouth syndrome. *Dermatologic Clinics* (2020) 38:477–83. doi: 10.1016/j.det.2020.05.008
54. Gurvits GE, Tan A. Burning mouth syndrome. *World J Gastroenterol* (2013) 19:665–72. doi: 10.3748/wjg.v19.i5.665
55. Pilati S, Bianco BC, Vieira D, Modolo F. Histopathologic features in actinic cheilitis by the comparison of grading dysplasia systems. *Oral Dis* (2017) 23:219–24. doi: 10.1111/odi.12597
56. Klichowska-Palanka M, Komsta A, Pac-Kożuchowska E. The condition of the oral cavity at the time of diagnosis of inflammatory bowel disease in pediatric patients. *Sci Rep* (2021) 11:21898. doi: 10.1038/s41598-021-01370-8
57. Katz J, Shenkman A, Stavropoulos F, Melzer E. Oral signs and symptoms in relation to disease activity and site of involvement in patients with inflammatory bowel disease. *Oral Dis* (2003) 9:34–40. doi: 10.1034/j.1601-0825.2003.00879.x
58. Huang C, Kugathasan S. Markers that differentiate early from late IBD. *Digestive Dis (Basel Switzerland)* (2012) 30:380–2. doi: 10.1159/000338130
59. Hajishengallis G. Periodontitis: from microbial immune subversion to systemic inflammation. *Nat Rev Immunol* (2015) 15:30–44. doi: 10.1038/nri3785
60. She YY, Kong XB, Ge YP, Liu ZY, Chen JY, Jiang JW, et al. Periodontitis and inflammatory bowel disease: A meta-analysis. *BMC Oral Health* (2020) 20:67. doi: 10.1186/s12903-020-1053-5
61. Zhang Y, Qiao D, Chen R, Zhu F, Gong J, Yan F. The association between periodontitis and inflammatory bowel disease: A systematic review and meta-analysis. *BioMed Res Int* (2021) 2021:6692420. doi: 10.1155/2021/6692420
62. Lorenzo-Pouso AI, Castelo-Baz P, Rodriguez-Zorrilla S, Pérez-Sayáns M, Vega P. Association between periodontal disease and inflammatory bowel disease: A systematic review and meta-analysis. *Acta Odontologica Scandinavica* (2021) 79:344–53. doi: 10.1080/00016357.2020.1859132
63. Papageorgiou SN, Hagner M, Nogueira AV, Franke A, Jäger A, Deschner J. Inflammatory bowel disease and oral health: Systematic review and a meta-analysis. *J Clin periodontology* (2017) 44:382–93. doi: 10.1111/jcpe.12698
64. Schmidt J, Weigert M, Leuschner C, Hartmann H, Raddatz D, Haak R, et al. Active matrix metalloproteinase-8 and periodontal bacteria-interlink between periodontitis and inflammatory bowel disease? *J Periodontology* (2018) 89:699–707. doi: 10.1002/JPER.17-0486
65. Vavricka SR, Manser CN, Hediger S, Vögelin M, Scharl M, Biedermann L, et al. Periodontitis and gingivitis in inflammatory bowel disease: A case-control study. *Inflammation Bowel Dis* (2013) 19:2768–77. doi: 10.1097/01.MIB.0000438356.84263.3b
66. Koutsochristou V, Zellos A, Dimakou K, Panayotou I, Siahianidou S, Roma-Giannikou E, et al. Dental caries and periodontal disease in children and adolescents with inflammatory bowel disease: A case-control study. *Inflammation Bowel Dis* (2015) 21:1839–46. doi: 10.1097/MIB.0000000000000452
67. Grössner-Schreiber B, Fetter T, Hedderich J, Kocher T, Schreiber S, Jepsen S. Prevalence of dental caries and periodontal disease in patients with inflammatory bowel disease: A case-control study. *J Clin periodontology* (2006) 33:478–84. doi: 10.1111/j.1600-051X.2006.00942.x
68. Tan CXW, Brand HS, Kalender B, De Boer NKH, Forouzanfar T, de Visscher JGAM. Dental and periodontal disease in patients with inflammatory bowel disease. *Clin Oral Investigations* (2021) 25:5273–80. doi: 10.1007/s00784-021-03835-6
69. Brozek JL, Akl EA, Alonso-Coello P, Lang D, Jaeschke R, Williams JW, et al. Grading quality of evidence and strength of recommendations in clinical practice guidelines. Part 1 of 3. An overview of the GRADE approach and grading quality of evidence about interventions. *Allergy* (2009) 64:669–77. doi: 10.1111/j.1398-9995.2009.01973.x
70. Said HS, Suda W, Nakagome S, Chinen H, Oshima K, Kim S, et al. Dysbiosis of salivary microbiota in inflammatory bowel disease and its association with oral immunological biomarkers. *DNA Res an Int J Rapid Publ Rep Genes Genomes* (2014) 21:15–25. doi: 10.1093/dnares/dst037

71. Xun Z, Zhang Q, Xu T, Chen N, Chen F. Dysbiosis and ecotypes of the salivary microbiome associated with inflammatory bowel diseases and the assistance in diagnosis of diseases using oral bacterial profiles. *Front In Microbiol* (2018) 9:1136. doi: 10.3389/fmicb.2018.01136
72. Molinero N, Taladrid D, Zorraquín-Peña I, de Celis M, Belda I, Mira A, et al. Ulcerative colitis seems to imply oral microbiome dysbiosis. *Curr Issues In Mol Biol* (2022) 44:1513–27. doi: 10.3390/cimb44040103
73. Surna A, Kubilius R, Sakalauskienė J, Vitkauskienė A, Jonaitis J, Saferis V, et al. Lysozyme and microbiota in relation to gingivitis and periodontitis. *Med Sci monitor Int Med J Exp Clin Res* (2009) 15:CR66–73.
74. Chandan JS, Thomas T. The impact of inflammatory bowel disease on oral health. *Br Dental J* (2017) 222:549–53. doi: 10.1038/sj.bdj.2017.318
75. Atarashi K, Suda W, Luo C, Kawaguchi T, Motoo I, Narushima S, et al. Ectopic colonization of oral bacteria in the intestine drives T1 cell induction and inflammation. *Sci (New York N.Y.)* (2017) 358:359–65. doi: 10.1126/science.aan4526
76. Souto R, Andrade AFB, Uzeda M, Colombo APVJ. Prevalence of "non-oral" pathogenic bacteria in subgingival biofilm of subjects with chronic periodontitis. *Brazilian Journal of Microbiology* (2006) 37:208–15. doi: 10.1590/S1517-83822006000300002
77. Zawadzki PJ, Perkowski K, Starościak B, Baltaza W, Padzik M, Pionkowski K, et al. Identification of infectious microbiota from oral cavity environment of various population group patients as a preventive approach to human health risk factors. *Ann Agric Environ Med AAEM* (2016) 23:566–9. doi: 10.5604/12321966.1226847
78. Rautava J, Pinnell LJ, Vong L, Akseer N, Assa A, Sherman PM. Oral microbiome composition changes in mouse models of colitis. *J Gastroenterol Hepatol* (2015) 30:521–7. doi: 10.1111/jgh.12713
79. Tomasello G, Mazzola M, Leone A, Sinagra E, Zummo G, Farina F, et al. Nutrition, oxidative stress and intestinal dysbiosis: Influence of diet on gut microbiota in inflammatory bowel diseases. *Biomed papers Med Faculty Univ Palacky Olomouc Czechoslovakia* (2016) 160:461–6. doi: 10.5507/bp.2016.052
80. Tomasello G, Mazzola M, Jurjus A, Cappello F, Carini F, Damiani P, et al. The fingerprint of the human gastrointestinal tract microbiota: A hypothesis of molecular mapping. *J Biol regulators homeostatic Agents* (2017) 31:245–9.
81. Hevia A, Milani C, López P, Cuervo A, Arbolea S, Duranti S, et al. Intestinal dysbiosis associated with systemic lupus erythematosus. *mBio* (2014) 5:e01548–14. doi: 10.1128/mBio.01548-14
82. Cappello F, Rappa F, Canepa F, Carini F, Mazzola M, Tomasello G, et al. Probiotics can cure oral aphthous-like ulcers in inflammatory bowel disease patients: A review of the literature and a working hypothesis. *Int J Mol Sci* (2019) 20(20):5026. doi: 10.3390/ijms20205026
83. Zdravkovic ND, Jovanovic IP, Radosavljevic GD, Arsenijevic AN, Zdravkovic ND, Mitrovic SL, et al. Potential dual immunomodulatory role of VEGF in ulcerative colitis and colorectal carcinoma. *Int J Med Sci* (2014) 11:936–47. doi: 10.7150/ijms.8277
84. Vasovic M, Gajovic N, Brajkovic D, Jovanovic M, Zdravkovic N, Kanjevac T. The relationship between the immune system and oral manifestations of inflammatory bowel disease: A review. *Central-European J Immunol* (2016) 41:302–10. doi: 10.5114/cej.2016.63131
85. Aleksandra Nielsen A, Nederby Nielsen J, Schmedes A, Brandslund I, Hey H. Saliva interleukin-6 in patients with inflammatory bowel disease. *Scandinavian J Gastroenterol* (2005) 40:1444–8. doi: 10.1080/00365520510023774
86. Lin Z, Wang Z, Hegarty JP, Lin TR, Wang Y, Deiling S, et al. Genetic association and epistatic interaction of the interleukin-10 signaling pathway in pediatric inflammatory bowel disease. *World J Gastroenterol* (2017) 23:4897–909. doi: 10.3748/wjg.v23.i27.4897
87. Xiao Y, Wang X-Q, Yu Y, Guo Y, Xu X, Gong L, et al. Comprehensive mutation screening for 10 genes in Chinese patients suffering very early onset inflammatory bowel disease. *World J Gastroenterol* (2016) 22:5578–88. doi: 10.3748/wjg.v22.i24.5578
88. Engelhardt KR, Shah N, Faizura-Yeop I, Kocak Uygün DF, Frede N, Muise AM, et al. Clinical outcome in IL-10- and IL-10 receptor-deficient patients with or without hematopoietic stem cell transplantation. *J Allergy Clin Immunol* (2013) 131:825–30. doi: 10.1016/j.jaci.2012.09.025
89. Bastos MF, Lima JA, Vieira PM, Mestnik MJ, Faveri M, Duarte PM. TNF- α and IL-4 levels in generalized aggressive periodontitis subjects. *Oral Dis* (2009) 15:82–7. doi: 10.1111/j.1601-0825.2008.01491.x
90. Figueredo CM, Brito F, Barros FC, Menegat JSB, Pedreira RR, Fischer RG, et al. Expression of cytokines in the gingival crevicular fluid and serum from patients with inflammatory bowel disease and untreated chronic periodontitis. *J Periodontal Res* (2011) 46:141–6. doi: 10.1111/j.1600-0765.2010.01303.x
91. Enver A, Ozmeric N, Isler SC, Toruner M, Fidan C, Demirci G, et al. An evaluation of periodontal status and cytokine levels in saliva and gingival crevicular fluid of patients with inflammatory bowel diseases. *J Periodontology* (2022). doi: 10.1002/JPER.22-0065
92. Plemmenos G, Evangelidou E, Polizopoulos N, Chalazias A, Deligianni M, Piperi C. Central regulatory role of cytokines in periodontitis and targeting options. *Curr medicinal Chem* (2021) 28:3032–58. doi: 10.2174/0929867327666200824112732
93. Brakenhoff LKPM, van der Heijde DM, Hommes DW, Huizinga TWJ, Fidder HH. The joint-gut axis in inflammatory bowel diseases. *J Crohn's Colitis* (2010) 4:257–68. doi: 10.1016/j.crohns.2009.11.005
94. Vavricka SR, Schoepfer A, Scharl M, Lakatos PL, Navarini A, Rogler G. Extraintestinal manifestations of inflammatory bowel disease. *Inflammation Bowel Dis* (2015) 21:1982–92. doi: 10.1097/MIB.0000000000000392
95. Sartor RB. Mechanisms of disease: Pathogenesis of crohn's disease and ulcerative colitis. *Nat Clin Pract Gastroenterol Hepatol* (2006) 3:390–407. doi: 10.1038/ncpgasthep0528
96. Ficarra G, Baroni G, Massi D. Pyostomatitis vegetans: Cellular immune profile and expression of IL-6, IL-8 and TNF- α . *Head Neck Pathol* (2010) 4:1–9. doi: 10.1007/s12105-009-0149-7
97. Triantafyllidis JK, Vagianos C, Papalois AE. The role of enteral nutrition in patients with inflammatory bowel disease: Current aspects. *BioMed Res Int* (2015) 2015:197167. doi: 10.1155/2015/197167
98. Hartman C, Eliakim R, Shamir R. Nutritional status and nutritional therapy in inflammatory bowel diseases. *World J Gastroenterol* (2009) 15:2570–8. doi: 10.3748/wjg.15.2570
99. Piskin S, Sayan C, Durukan N, Senol M. Serum iron, ferritin, folic acid, and vitamin B12 levels in recurrent aphthous stomatitis. *J Eur Acad Dermatol Venereology JEADV* (2002) 16:66–7. doi: 10.1046/j.1468-3083.2002.00369.x
100. Dignass AU, Gasche C, Bettenworth D, Birgegård G, Danese S, Gisbert JP, et al. European Consensus on the diagnosis and management of iron deficiency and anaemia in inflammatory bowel diseases. *J Crohn's colitis* (2015) 9:211–22. doi: 10.1093/ecco-jcc/jju009
101. Sun A, Lin H-P, Wang Y-P, Chiang C-P. Significant association of deficiency of hemoglobin, iron and vitamin B12, high homocysteine level, and gastric parietal cell antibody positivity with atrophic glossitis. *J Oral Pathol Med Off Publ Int Assoc Oral Pathologists Am Acad Oral Pathol* (2012) 41:500–4. doi: 10.1111/j.1600-0714.2011.01122.x
102. Wu Y-C, Wang Y-P, Chang JY-F, Cheng S-J, Chen H-M, Sun A. Oral manifestations and blood profile in patients with iron deficiency anemia. *J Formosan Med Assoc = Taiwan yi zhi* (2014) 113:83–7. doi: 10.1016/j.jfma.2013.11.010
103. Lin H-P, et al. Significant association of hematinic deficiencies and high blood homocysteine levels with burning mouth syndrome. *J Formosan Med Assoc = Taiwan yi zhi* (2013) 112:319–25. doi: 10.1016/j.jfma.2012.02.022
104. Park KK, Brodell RT, Helms SE. Angular cheilitis, part 2: Nutritional, systemic, and drug-related causes and treatment. *Cutis* (2011) 88:27–32.
105. Jajam M, Bozzolo P, Niklander S. Oral manifestations of gastrointestinal disorders. *J Clin Exp dentistry* (2017) 9:e1242–8. doi: 10.4317/jced.54008
106. Mizukami Y, Imanishi H, Tateishi C, Kaneshiro S, Sowa-Osako J, Ohsawa M, et al. Successful treatment of pyostomatitis vegetans with ulcerative colitis using dapsone without systemic steroids. *J Dermatol* (2019) 46:e316–7. doi: 10.1111/1346-8138.14885
107. Bardasi G, Romagnoli A, Foschini MP, Mantovani A, Alvisi P. Pyostomatitis vegetans in a pediatric patient with ulcerative colitis: Case report of a rare pediatric inflammatory bowel disease extraintestinal manifestation and review of the literature. *Eur J Gastroenterol Hepatol* (2020) 32:889–92. doi: 10.1097/MEG.0000000000001723
108. Kitayama A, Misago N, Okawa T, Iwakiri R, Narisawa Y. Pyodermitis-pyostomatitis vegetans after subtotal colectomy for ulcerative colitis. *J Dermatol* (2010) 37:714–7. doi: 10.1111/j.1346-8138.2010.00961.x
109. Jurgé S, Kuffer R, Scully C, Porter SR. Mucosal disease series. Number VI. recurrent aphthous stomatitis. *Oral Dis* (2006) 12:1–21. doi: 10.1111/j.1601-0825.2005.01143.x
110. Pereira MS, Munerato MC. Oral manifestations of inflammatory bowel diseases: Two case reports. *Clin Med Res* (2016) 14:46–52. doi: 10.3121/cmr.2015.1307
111. Aggarwal H, Singh MP, Nahar P, Mathur H, Gv S. Efficacy of low-level laser therapy in treatment of recurrent aphthous ulcers - a sham controlled, split mouth follow up study. *J Clin Diagn Res JCDR* (2014) 8:218–21. doi: 10.7860/JCDR/2014/7639.4064
112. Nijakowski K, Rutkowski R, Eder P, Korybalska K, Witowski J, Surdacka A. Changes in salivary parameters of oral immunity after biologic therapy for inflammatory bowel disease. *Life (Basel Switzerland)* (2021) 11(12):1409. doi: 10.3390/life11121409

113. Cotti E, Mezzena S, Schirru E, Ottonello O, Mura M, Ideo F, et al. Healing of apical periodontitis in patients with inflammatory bowel diseases and under anti-tumor necrosis factor alpha therapy. *J Endodontics* (2018) 44:1777–82. doi: 10.1016/j.joen.2018.09.004

114. Calobrisi SD, Mutasim DF, McDonald JS. Pyostomatitis vegetans associated with ulcerative colitis. temporary clearance with fluocinonide gel and complete remission after colectomy. *Oral Surgery Oral Medicine Oral Pathology Oral Radiology Endodontics* (1995) 79:452–4. doi: 10.1016/s1079-2104(05)80126-x



OPEN ACCESS

EDITED BY

Zhi Wang,
Guangdong Provincial Key Laboratory
of Stomatology, Sun Yat-sen
University, China

REVIEWED BY

Lei Hu,
Beijing Stomatological Hospital,
Capital Medical University, China
Jeffrey Ebersole,
University of Nevada, Las Vegas,
United States

*CORRESPONDENCE

Qi Wang
wqinno8751@gmail.com

[†]These authors have contributed
equally to this work

SPECIALTY SECTION

This article was submitted to
Mucosal Immunity,
a section of the journal
Frontiers in Immunology

RECEIVED 15 August 2022

ACCEPTED 15 September 2022

PUBLISHED 04 October 2022

CITATION

Yue Z, Nie L, Zhao P, Ji N,
Liao G and Wang Q (2022)
Senescence-associated secretory
phenotype and its impact on
oral immune homeostasis.
Front. Immunol. 13:1019313.
doi: 10.3389/fimmu.2022.1019313

COPYRIGHT

© 2022 Yue, Nie, Zhao, Ji, Liao and
Wang. This is an open-access article
distributed under the terms of the
[Creative Commons Attribution License](#)
(CC BY). The use, distribution or
reproduction in other forums is
permitted, provided the original
author(s) and the copyright owner(s)
are credited and that the original
publication in this journal is cited, in
accordance with accepted academic
practice. No use, distribution or
reproduction is permitted which does
not comply with these terms.

Senescence-associated secretory phenotype and its impact on oral immune homeostasis

Ziqi Yue^{1,2†}, Lulingxiao Nie^{1,2†}, Pengfei Zhao^{1,2,3}, Ning Ji^{1,2},
Ga Liao^{1,4} and Qi Wang^{1,2*}

¹State Key Laboratory of Oral Diseases, National Clinical Research Center for Oral Diseases, West China Hospital of Stomatology, Sichuan University, Chengdu, China, ²Department of Prosthodontics, West China Hospital of Stomatology, Sichuan University, Chengdu, China, ³Faculty of Dentistry, The University of Hong Kong, Sai Ying Pun, Hong Kong SAR, China, ⁴Department of Information Management, Department of Stomatology Informatics, West China Hospital of Stomatology, Sichuan University, Chengdu, China

The senescence-associated secretory phenotype (SASP), which accumulates over the course of normal aging and in age-related diseases, is a crucial driver of chronic inflammation and aging phenotypes. It is also responsible for the pathogenesis of multiple oral diseases. However, the pathogenic mechanism underlying SASP has not yet been fully elucidated. Here, relevant articles on SASP published over the last five years (2017–2022) were retrieved and used for bibliometric analysis, for the first time, to examine SASP composition. More than half of the relevant articles focus on various cytokines (27.5%), growth factors (20.9%), and proteases (20.9%). In addition, lipid metabolites (13.1%) and extracellular vesicles (6.5%) have received increasing attention over the past five years, and have been recognized as novel SASP categories. Based on this, we summarize the evidences demonstrating that SASP plays a pleiotropic role in oral immunity and propose a four-step hypothetical framework for the progression of SASP-related oral pathology—1) oral SASP development, 2) SASP-related oral pathological alterations, 3) pathological changes leading to oral immune homeostasis disruption, and 4) SASP-mediated immune dysregulation escalating oral disease. By targeting specific SASP factors, potential therapies can be developed to treat oral and age-related diseases.

KEYWORDS

oral homeostasis, senescence-associated secretory phenotype, cellular senescence, age-related disease, oral-systemic disease

1 Introduction

Oral immune homeostasis is a delicate balance established and shaped by the interaction between pathogen invasion and host immune response (1). Any disruption to this balance results in local or systemic diseases. Some pathophysiological changes are attributed to the environmental impact of senescent cells (2). The primary non-spontaneous effects of senescent cells appear to be closely linked to the senescence-associated secretory phenotype (SASP).

SASP, a product of senescent cells, is mainly classified into the following categories: 1) pro-inflammatory cytokines (such as interleukin (IL)-1 α , IL-1 β , IL-6, and IL-8); 2) chemokines (such as CXCL-1/3 and CXCL-10); 3) proteases: including matrix remodeling enzymes and plasminogen activators; 4) growth factors (such as VEGF, TGF- β and GM-CSF); 5) bioactive lipids (like oxidized lipid mediators); 6) extracellular vesicles (EVs); and 7) others (2, 3). SASP profiles exhibit a significant cell type-dependent heterogeneity, and SASP strength and composition are spatially and temporally dependent (4). In this paper, we summarize the different SASP categories, and reveal the most relevant cell types *via* bibliometric analysis, and propose a framework for the role of SASP in oral immune homeostasis to provide insights into the potential of SASP as a novel therapeutic target.

2 Methods

2.1 Data source and retrieval strategy

We searched the Web of Science Core Collection and PubMed databases for articles related to SASP factors published from 2017 to 2022. The retrieval strategy for the Web of Science Core Collection database was as follows: (((ALL=(cytokine) OR ALL=(chemokine) OR ALL=(protease) OR ALL=(growth factor) OR ALL=(lipid) OR ALL=(proinflammatory factor)) AND (ALL=(senescence associated secretory phenotype) OR ALL=(sasp))) AND (DOP==(2017-01-01:2022-04-01))) AND ((LA==(“ENGLISH”)) NOT (DT==(“REVIEW”))). The retrieval strategy for the PubMed database was as follows: (((((((cytokine) OR (chemokine)) OR (protease)) OR (growth factor)) OR (proinflammatory factor)) OR (lipid) AND ((y_5[Filter]) AND (English[Filter])))) AND ((senescence associated secretory phenotype) OR (sasp) AND ((y_5[Filter]) AND (English[Filter])))) NOT review[PT].

Inclusion criteria were as follows: Research articles 1. related to SASP; 2. published between 2017-01-01 and 2022-04-01; and 3. written in English. Exclusion criteria were as follows: 1. Literature whose content is not closely related to SASP factors; 2. Studies including guidance, consensus, industry standards, interviews, comments, announcements, advertisements, or letters to the

editor; and 3. informally published studies, such as graduate theses.

2.2 Data processing and analysis

After retrieval, data screening and quality control were performed. This was conducted by reading titles and abstracts to remove literature that met the exclusion criteria. The data from papers that met the inclusion criteria were downloaded and merged. After removing duplicates, CiteSpace 6.1.R1 was used for data analysis. Next, different words or phrases expressing the same meaning were merged. For example, nuclear factor-kappa b and nf kappa b were merged as NF-kappa B. To clearly demonstrate the relationships among different type of SASP factors clearly, we further merged the same type SASP factors. For example, NF-kappa B, CCN1, and cyclin d1 were merged as proinflammatory factors, and stem cells, mesenchymal stem cells, and cancer stem cells were merged as pluripotent stem cells. Finally, a keyword co-occurrence network was built to visualize the relationships among knowledge domains and identify important SASP factors that have attracted attention in recent years.

3 Results

3.1 Analysis of the proportion of reported SASP factors

In total, 564 articles were included in the bibliometric analysis. In the last 5 years, the most cited SASP factors have been cytokines, including IL-6, IL-1, IL-8, CXCL-8; tumor necrosis factors (TNFs); and interferons. These proinflammatory cytokines account for 27.5% of the reported SASP factors. Among them, interleukins were determined to be the most important SASP factors, accounting for nearly half of these proinflammatory cytokines. The second-most cited SASP factors are growth factors and proteases. These two types of SASP factors account for 20.9% of variations in the SASP factors. IGF-1, TGF- β , and VEGF are the most frequently cited growth factors. Matrix metalloproteinases (MMPs) are the most cited proteases. In the past five years, more than half of the articles related to SASP have focused on various cytokines, growth factors, and proteases (Figure 1A).

3.2 Analysis of relevant cell type

As shown in Figure 1B, a tight and complex network of interactions is formed among different types of SASP factors and between SASP factors and different types of cells. The main cell

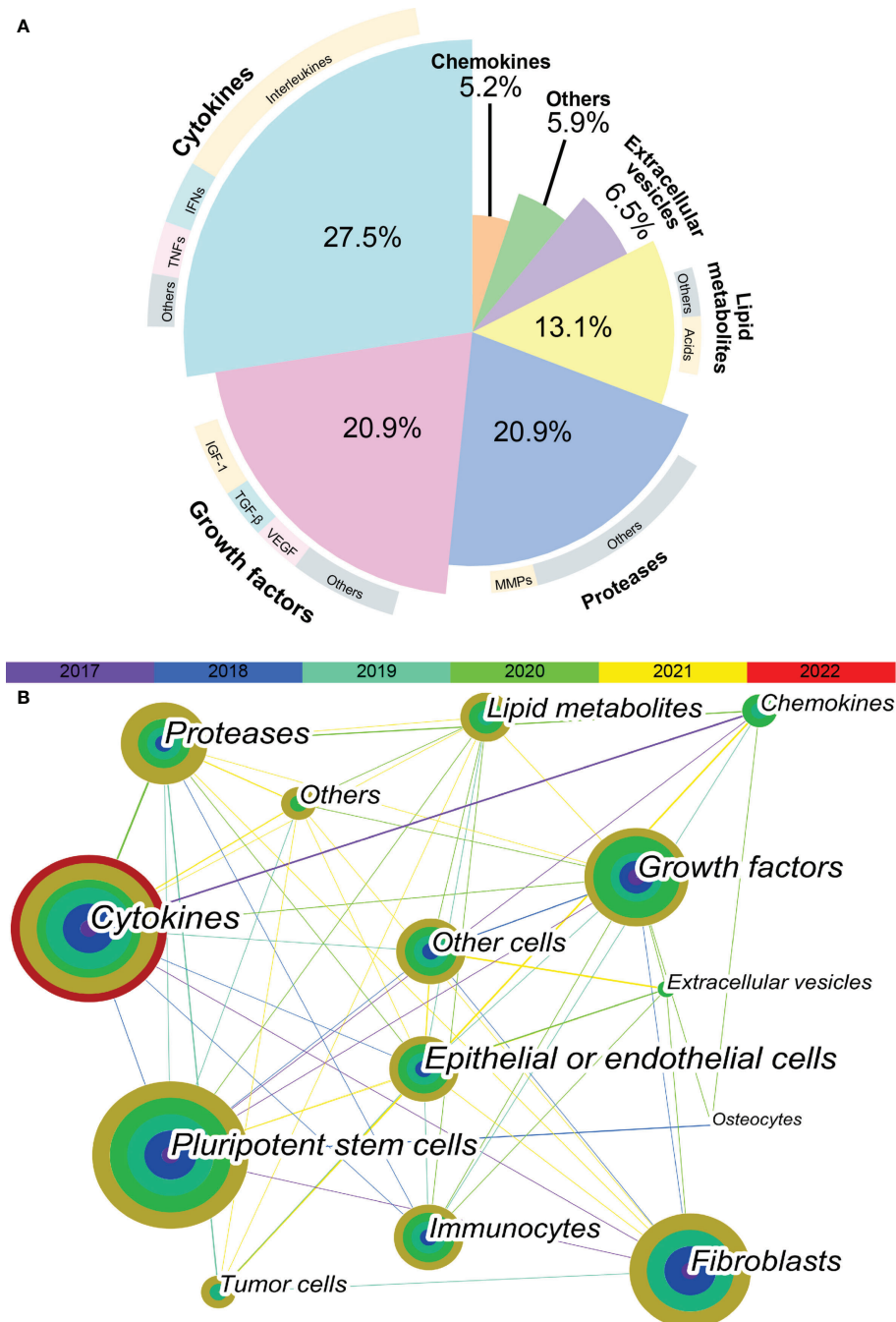


FIGURE 1

Keyword co-occurrence network visualization. **(A)** The proportion of different SASP factors in articles published in recent 5 years. Demonstrated as a pie plot. The inner are different types of SASP factors. The outer are most cited SASP factors of each type. **(B)** The keyword co-occurrence network shows the relationship between different types of SASP factors and different types of cells. Each node is a concentric circle, and the thickness of each layer of the concentric circle represents the frequency of use of this keyword in a certain year. The color of each line represents the year of the first co-occurrence between the two keywords. The thickness of each line represents the frequency of co-occurrence between the two keywords.

types of interest in recent studies of SASP were pluripotent stem cells, fibroblasts, epithelial or endothelial cells, and immunocytes. The cell types in which the different SASP factors mainly act are listed in [Table 1](#). The results of bibliometric analysis demonstrated that different SASP factors tend to affect different cell types. For example, cytokines mainly act on pluripotent stem cells, whereas proteases mainly act on tumor cells. Pluripotent stem cells, fibroblasts, and epithelial or endothelial cells are often affected by SASP factors.

4 Discussion

4.1 Main components of SASP

4.1.1 Cytokines

The most prominent cytokines are members of the IL-1, IL-6, and TNF families. The membrane-binding IL-1 α is an upstream regulator of age-related cytokine networks (5). The secreted IL-1 β is excreted from cells in the early stages of the inflammatory process and then binds to the IL-1 receptor to trigger an inflammatory response (6). IL-6 initiates intracellular signaling by binding to its membrane-binding receptor, IL-6R α , or its soluble receptor, sIL-6R (7). An enhanced TNF signaling is considered pertinent to immune system defects (8).

4.1.2 Chemokines

Chemokines act as local sensors of infection and inflammation (9). The most-studied chemokines in the field of aging in the past 5 years are the CXCL family members IL-8, CXCL-1, -2, and -3 and CCL family members like MCP-1, -2, and -4 and MIP-3 α and -1 α .

4.1.3 Growth factors

The diffusion of growth factors into the surrounding environment induces cell activation and proliferation, stimulates granulation tissue formation, regulates inflammatory responses, induces angiogenesis, and participates in matrix remodeling and re-epithelialization (10).

4.1.4 Extracellular proteases

Matrix metalloproteinases (MMPs) and tissue inhibitors of metalloproteinases (TIMPs) The MMP family is capable of degrading various components of extracellular matrix (ECM) proteins. TIMPs abrogate the proteolytic activity of MMPs by competing with them (11).

Serine proteases and their inhibitors Urokinase-type plasminogen activator (uPA) and tissue-type plasminogen activator (tPA) can modulate immune responses by activating MMPs to alter ECM composition, thus promoting the migration of macrophages and dendritic cells and modulating cytokine activity (12).

TABLE 1 Varies cell types where different SASP factors mainly act on.

SASP factors	Cell types	Rank
Cytokines	Pluripotent stem cells	1 st
	Immunocytes	2 nd
	Fibroblasts	3 rd
Growth factors	Pluripotent stem cells	1 st
	Fibroblast	2 nd
	Other cells	3 rd
Proteases	Tumor cells	1 st
	Pluripotent stem cells	2 nd
	Immunocytes	3 rd
Lipid metabolites	Epithelial or endothelial cells	1 st
	Other cells	2 nd
	Immunocytes	3 rd
Extracellular vesicles	Other cells	1 st
	Epithelial or endothelial cells	2 nd
	Fibroblasts	3 rd
Chemokines	Tumor cells	1 st
	Osteocytes	2 nd
	Pluripotent stem cells	3 rd
Others	Pluripotent stem cells	1 st
	Tumor cells	2 nd
	Fibroblasts	3 rd

This table shows the top 3 cell types that are most strongly affected by each type of SASP.

Cathepsin An increased expression of cathepsin B and its nuclear translocation contribute to proinflammatory responses (13). Cathepsin D, an acidic protease active in intracellular protein breakdown, is significantly overexpressed during aging (14).

4.1.5 Lipid metabolites

Abnormal lipid accumulation induces pro-inflammatory genes activation and senescence phenotype (15). Ni et al. suggested that oxidized lipid mediators may serve as novel components of the SASP (16). Moreover, the levels of cyclooxygenase and its major product, prostaglandin E2 (PGE2), are increased in both replicative and premature senescence (17). Leukotriene D4 plays a role in cellular senescence (18).

4.1.6 Extracellular vesicles

EVs are small vesicles that contain proteins, lipids, and noncoding RNAs (19). An increased EV production is a common feature of senescence and senescent cells (20). Secreted EVs interact with or are internalized by recipient cells to transmit pro-senescence signals between cells and organs, and partially induce immune and inflammatory activation (21, 22).

4.1.7 Others

Additionally, the contributions of small molecules, such as ECM, miRNAs, and ROS, to SASP function remain understudied and may be considered an important future target.

4.2 Molecular mechanisms of SASP induction

Given the complexity and pleiotropic functionality of the SASP, we generalized the underlying mechanisms regulating it (Figure 2). The DNA damage response (DDR) is associated with SASP expression (23). The expression of some inflammatory SASP is regulated by NF- κ B and C/EBP β transcription cofactors by binding to SASP factor promoters. GATA-binding protein 4 transcription factor is responsible for upstream NF- κ B signaling and, thus, regulates SASP factor expression (24).

Furthermore, many signaling pathways regulate SASP expression at the transcriptional level. For example, the Janus kinase signal transducer and activator of the transcription pathway participate in regulating SASP expression (25). Activation of p38 signaling also promotes SASP expression (26). More recently, the antiviral cyclic GMP-AMP synthase (cGAS)-stimulator of interferon genes (STING) pathway has been found to be important for SASP expression (27). Additionally, NOTCH signaling regulates the dynamic SASP transition (28).

SASP expression is transcriptionally regulated. mTOR pathway activation promotes the translation of SASP factors such as IL-1 α . mTOR also stabilizes SASP mRNA transcripts by regulating MAPKAPK2 translation (29). Inflammasomes are key mediators of SASP induction; inflammasomes upstream of caspase-1 can activate the IL-1 inflammatory cascade during senescence (30).

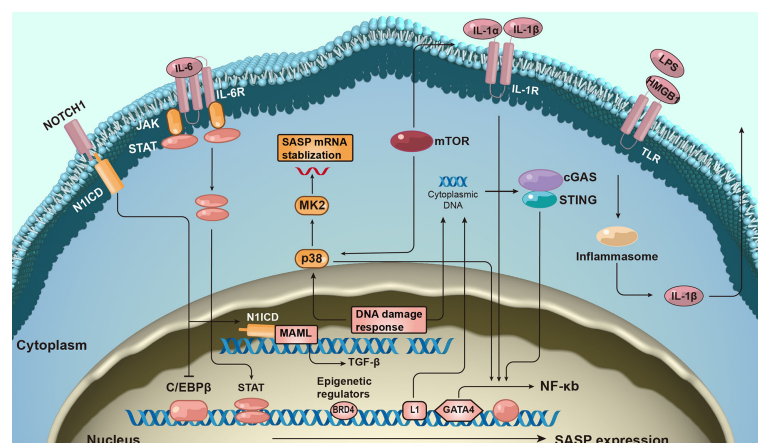


FIGURE 2

The molecular mechanism of senescence-associated secretory phenotype production. The formation of senescence-associated secretory phenotype (SASP) networks in cells is regulated by a complex molecular mechanism. The DNA damage response is related to senescence activation and SASP expression. SASP protein expression is regulated at both the transcription and post-transcriptional levels. Additionally, epigenetic changes regulate SASP gene expression.

The expression of SASP also correlates with epigenetic changes. Recruitment of chromatin reader bromodomain-containing protein 4 (BRD4) leads to the remodeling of super-enhancer elements adjacent to SASP genes (31). Several ncRNAs can also affect SASP production at transcriptional and post-translational levels.

4.3 Source of oral SASP

4.3.1 Oral senescent cells with locally secreted SASP

Dental tissue-derived cells Long-term stress on teeth may induce the human dental pulp cells senescence and up-regulation of SASP factors in human dental pulp cells (32). In aging patients, dental pulp stem cells exhibit elevated expression of SASP factors (33). Dental follicle cells are positive for SA- β -gal staining in later stages of cell culture (34). Dental follicle stem cells secrete TGF- β 3, TSP-1, and TGF- β 2 to promote and relieve inflammation (35–37).

Periodontal-derived cells Senescent periodontal ligament cells express high levels of MMP2 (38). The induction of senescent periodontal ligament stem cell by TGF- β is accompanied by increased levels of certain SASP factors (39). *In vitro* experiments have shown that p16, p21, IL-6, and IL-8 mRNA expression in human gingival fibroblasts is upregulated after replicative senescence (40–42). Researchers have observed that liposaccharide (LPS) exposure causes osteocyte senescence and SASP expression by activating p53 (43).

Oral mucosa cells SASP secretion is significantly increased in senescent human oral keratinocytes (44–47), and IL-6, TNF- α , and IFN- γ levels are increased in the oral tongue tissues of the elderly (48). Tongue muscle stem cells and epithelial cells have been shown to degenerate with age, but the relevant SASP profile has not been tested (49, 50).

Cancer cells In head and neck squamous cell carcinoma, the number of SA- β -gal-positive aged cells and SASP factor levels are significantly increased after LY2835219 treatment (51). Moreover, an increased secretion of SASP has been observed in senescent cancer-associated fibroblasts (CAF). The senescent CAFs co-cultured with oral squamous cell carcinoma (OSCC) cells also exhibit higher levels of IL-6 and CXCL1 (52). In precancerous lesions, senescent oral submucosal fibroblasts accumulate and upregulate MMPs (53).

Immunocytes High-glucose induces macrophage senescence and increases IL-1, IL-6, TNF- α , MMP-2, and MMP-8 secretion (54). Periodontal pathogens induce monocyte activation and the up-regulation of multiple cytokines (55). Overactive neutrophils can release inflammatory molecules and MMPs (56). The SASP profile of B cells and plasma cells in the aging gingival tissue changes (57). The SASP profile varies with cell type; factors inducing senescence are shown in Table 2.

4.3.2 ARDs with increased circulating SASP

Circulating SASP is associated with aging and age-related diseases (ARDs) (64). Compared to that in young individuals, the proportion of senescent cells is increased in aging individuals; additionally, the levels of some SASP proteins (age-related SASP) increase significantly (65). Concurrently, the premature cells induced by ARDs can accelerate this process (ARD-related SASP) (66). Age-related versus ARD-related SASP and their effects on oral health are shown in Table 3.

4.4 Pleiotropic effects of SASP on oral immune homeostasis

The heterogeneity of SASP may partly account for its pleiotropic effects. Based on the mechanisms of SASP, we propose a four-step hypothetical framework by which oral disease progresses from the pathologic role of SASP to the destabilization of oral immune homeostasis. The pleiotropic effects of the SASP can be interpreted using the model depicted in Figure 3.

4.4.1 Step 1: Induction of cellular senescence in oral microenvironment

Replicative- and stress-induced senescence are the main patterns of cellular senescence in the oral microenvironment.

4.4.1.1 Replicative senescence

Serial cultivation of human diploid cells leads to indefinite cell division, which is currently defined as replicative senescence (72). Senescent cells arising from this physiological phenomenon are defined as primary senescent cells (73), which have a series of typical morphologies and biomarker alterations, including DDR (γ -H2AX and p53), cell cycle arrest (p16^{INK4A} and p21^{CDKN1A}), anti-apoptotic genes (BCL-proteins), lysosomal content (SA- β -gal), and heterochromatin markers (H3K9me3 and HP1 γ) (2, 74).

4.4.1.2 Stress-induced senescence

Due to various stressors, the stress in senescing cells can be classified as secondary senescent cells as follows: 1) DNA damage-induced senescence, which can lead to cellular senescence by inducing DNA damage (35, 75); 2) chemotherapy-induced senescence, in which chemotherapy and anti-resorptive agents have been shown to induce senescence in oral cells (76); 3) oxidative stress-induced senescence whereby H₂O₂ treatment increases the positive rate of SA- β -gal staining in human dental pulp cells; 4) oncogene-induced senescence wherein senescence markers are upregulated in oral premalignant lesions (77). 5) epigenetically induced senescence, which is characterized by the blockade of DNA

TABLE 2 Cellular senescence and SASP involved in the oral cavity.

Cell type		Senescence trigger	SASP factors involved	Ref.		
Dental-derived cells	Human dental pulp cells	H ₂ O ₂ -induced	ICAM-1, VCAM-1, PPAR-g	(58)		
	Human dental pulp stem cells	<i>p</i> -cresol-induced	IL-6	(33)		
	Dental follicle stem cells	LPS-induced	TGF-β2, IL-6, IL-8, IL-1β	(37)		
Periodontal -derived cells	Human periodontal ligament fibroblasts	Replicative and radiation-induced	MMP2	(38)		
	human periodontal ligament stem cell	TGF-β-induced	IL-8, IL-18, IL-6	(39)		
	Human gingival fibroblast	Replicative	IL-6, IL-8	(40)		
		Replicative	IL-6, IL-8, TNF, TIMP-1	(41)		
		Replicative	MMP3, MMP12, IL-1α	(42)		
	Alveolar osteocyte	LPS-induced	ICAM-1, IL-1β, IL-6, IL-8, MCP-1, MMP12, MMP13	(43)		
	Oral mucosa cells	Human oral keratinocytes	Bisphosphonates-induced	IL-8, IL-6, MMP3	(59)	
Replicative			IL-1β, IL-1α, IL-8, IL-6	(46)		
Replicative			IL-1β, MMP3, PGF, CTGF, VEGF, MMP1, TIMP2, IL-8, MMP9,	(44)		
Replicative			IL-1β, IL-1α, IL-8, IL-6, TNF-α, G-CSF, GM-CSF, GROα	(47)		
High glucose-induced			IL-1β, IL-6, TNF-α	(60)		
Cancer cells			Cal27, HSC3 and HSC6 cell lines	LY2835219-induced	IL6, IL8, MCP1, CXCL1, CXCL2, CXCL3	(51)
			CAF from OSCC	Cisplatin-induced	MCP-1, IL-6	(61)
Immunocytes	Oral submucous fibroblasts	H ₂ O ₂ -induced	TGF-β, MMP2	(62)		
		Co-culture with OSCC cells	IL-6, CXCL1	(52)		
		The progression of oral submucous fibrosis	MMP1, MMP2	(53)		
		High glucose-induced	IL-1, IL-6, TNF-α, MMP-2, and MMP-8	(54)		
		Macrophage	<i>Pg</i> and <i>Aa</i> -induced	IL-1β, TNF-α, IL-6, IL-23	(55)	
		Monocytes	LPS, <i>Pg</i> , <i>Aa</i> and zymosan A-induced	IL-8, MMP-9	(56)	
		Neutrophils	Replicative	MMP2, MMP9, CTSK, TNF-α	(57)	
	B cells/plasmacytes	And Periodontal pathogens-induced				
		<i>Pg</i> -induced	IL-17A, IFN-γ	(63)		

CAF, cancer-associated fibroblast; OSCC, oral squamous cell carcinoma; LPS, lipopolysaccharide; ICAM, intercellular adhesion molecule; VCAM, vascular cell adhesion molecule; PPAR, peroxisome proliferator-activated receptor; IL, interleukin; MCP, monocyte chemoattractant protein; MMP, matrix metalloproteinase; TNF, tumor necrosis factor; PGF, placental growth factor; CTGF, connective tissue growth factor; VEGF, vascular endothelial-derived growth factor; TIMP, tissue inhibitor of metalloproteinases; G-CSF, granulocyte colony-stimulating factor; GM-CSF, granulocyte-macrophage colony-stimulating factor; GROα(CXCL1), C-X-C motif chemokine ligand 1; *Pg*, *Porphyromonas gingivalis*; *Aa*, *Aggregatibacter actinomycetemcomitans*.

TABLE 3 Age-related versus ARD-related circulating SASP and effects on oral health.

Age-related or ARD-related		Study type	Circulating increased SASP factors	Effects on oral health
Age-related		Cross-sectional study (65)	IL-6, TNF-α, CCL3, CCL4, GDF15, ACTIVIN A, TNFR1, FAS	1. Recruitment of immune cells: chemokines (CCL3, CCL4) 2. Matrix remodeling: MMPs (MMP9) 3. Fibrosis: growth factors (TGF-β)
ARDs	Diabetes	Case-control study (67)	IL-6	4. Senescence re-enforcement: cytokines (IL-6, TNF-α, IL-10)
		Cohort study (68)	IL-6, TNF-α	
	Cancer	Systematic review (69)	IL-6, TGF-β, IL-10	
	Cardiovascular disease	Case-control study (70)	MMP9	
		Systematic review (71)	IL-6	

ARD, age-related disease; SASP, senescence-associated secretory phenotype; GDF, Growth/differentiation factor; TNFR, tumor necrosis factor receptor; CCL, CC chemokine ligand; TNF, tumor necrosis factor; TGF, transforming growth factor; MMP, matrix metalloproteinase.

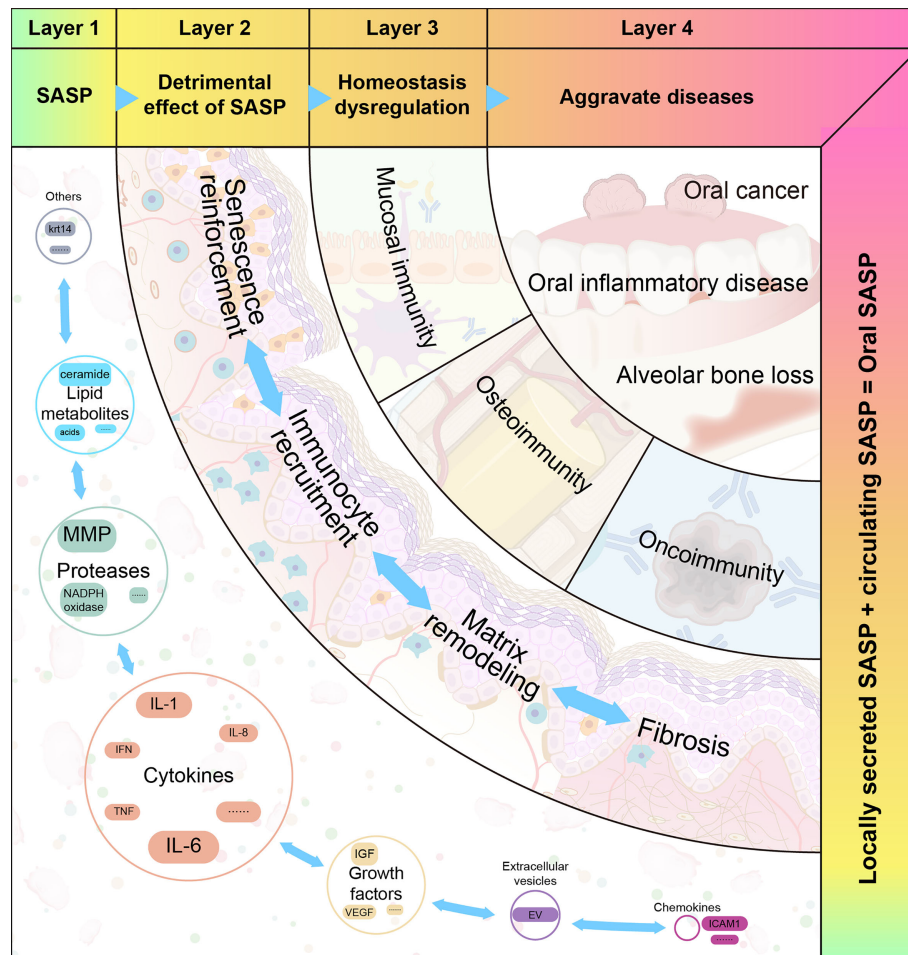


FIGURE 3

The four proposed layers of how senescence-associated secretory phenotype impacts oral diseases. Senescence-associated secretory phenotype (SASP) (including cytokines, chemokines, growth factors, and proteases) secreted by oral senescent cells, as well as circulating SASP, constitute the aging microenvironment of oral cavity. As an important mediator, SASP accelerates oral pathological alterations including senescence re-enforcement, recruitment of immune cells, matrix remodeling and fibrosis. Then, the SASP-induced dysregulation of immune homeostasis can be divided into three categories: mucosal immunity, bone immunity, and tumor immunity. These destroy the structure and function of different oral tissues. When age-related tissue damage accumulates, it manifests as age-related diseases.

Methyltransferase 1 (DNMT1) and activation of histone acetylation in oral cells (78); and 6) paracrine senescence wherein the SASP produced by primary senescent cells initiates senescence in surrounding cells.

4.4.1.3 Distinguishing senescence and inflammation

The inflammatory cytokines secreted by activated immune cells overlap with SASP factors. Some cytokines are unique to inflammation (such as IL-22), while others are unique to senescence (such as TIMP). By definition, SASP is downstream of cellular senescence. Notably, the senescence process is generally accompanied by sterile, chronic, low-level inflammation, termed inflamm-aging (79). Chronic inflammation may occur due to age-related immune

dysregulation or decreased resistance to challenges, which can induce tissue pathology. The frameworks for aging, inflammation, and cellular senescence are shown in Figure 4.

4.4.2 Step 2: SASP accelerates oral pathologic alterations

The SASP is beneficial for maintaining homeostasis and regeneration at a moderate level. However, when SASP is expressed continuously, it induces pathological alterations and disrupts the immune homeostasis of the oral microenvironment.

4.4.2.1 Amplifying the immune cascade

Secreted SASP activates proximal and distant immunocytes in autocrine and paracrine manners. IL-1 β is known to induce

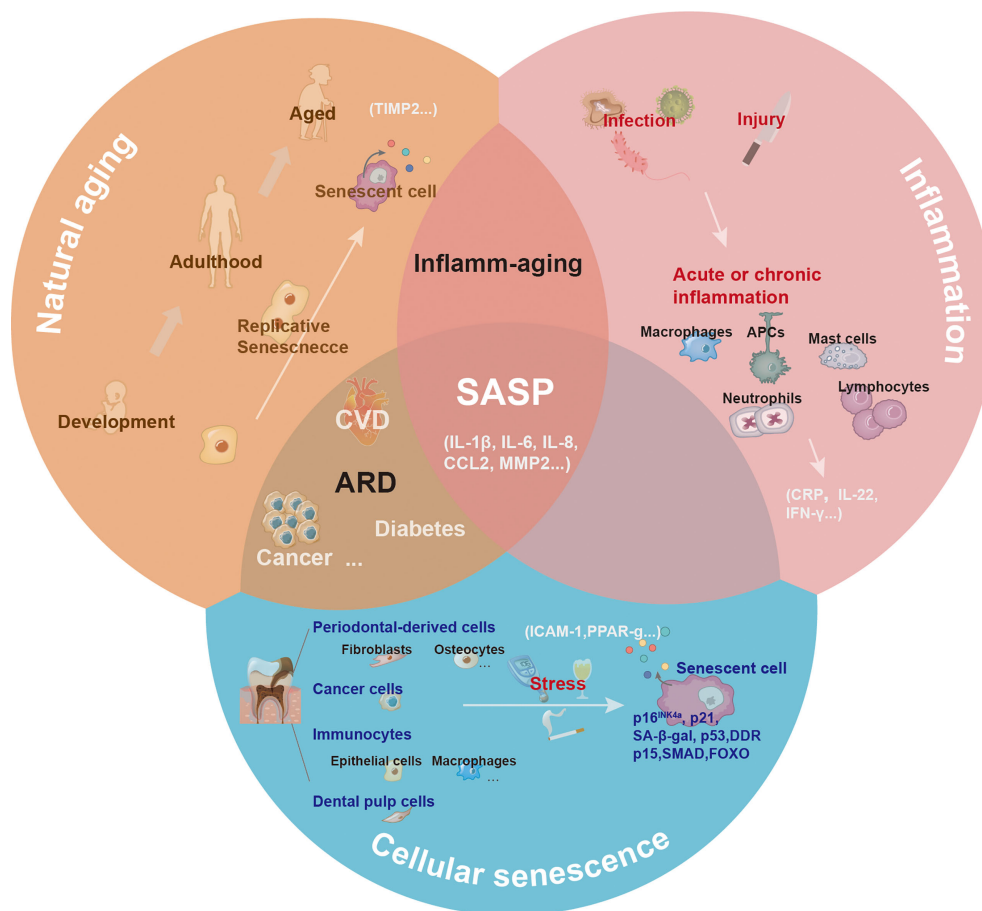


FIGURE 4

The central role of senescence-associated secretory phenotype in natural aging, inflammation, and cellular senescence. With natural aging, there is a progressive loss in tissue and organ functions, and accumulated senescence-associated secretory phenotype (SASP) can contribute to this process. Depending on the triggers, including infection or injury, the inflammatory response has different pathological consequences. The inflammatory response can be amplified via the secretion of inflammatory cytokines. Various cells (such as epithelial cells, dental pulp cells, fibroblasts, and macrophages) in the oral cavity undergoing senescence release SASP to the local microenvironment under the induction of natural aging and stress.

CD4⁺ T cell proliferation in response to challenges associated with cognate antigens (80). IL-8 induces the migration of activated immune cells to gingival tissue and promotes tissue remodeling and angiogenesis (81). Elevated CCL2 and CCL4 levels are responsible for macrophage recruitment in periodontal lesions (82). The CXCL1 secreted by tumor cells promotes tumor growth by recruiting tumor-associated neutrophils (83).

4.4.2.2 Supporting senescence reinforcement

Certain key SASP factors, such as IL-6, IL-8, GRO α , and IGFBP-7, act in an autocrine feedback loop. Non-senescent human oral epithelial keratinocytes cultured with senescent cell supernatants exhibit increased SA- β -gal activity and SASP expression (84). The IL-1 β expressed by tumor cells can significantly increase CXCL1 production in CAFs *via* paracrine signaling (85). Moreover, IL-1 β induces significant

IL-6 production in human gingival fibroblasts and promotes cellular responsiveness to IL-6 through an autocrine loop (86). IL-6 induces normal fibroblast senescence by establishing a senescence induction circuit (87).

4.4.2.3 Remodeling the extracellular matrix

MMPs constitute an important proteolytic pathway that affects tissue remodeling and ECM structure. MMP expression reduces the ability of tissues to maintain homeostasis (88). Specifically, MMP-1 destroys the periodontal connective tissue by directly degrading collagen or activating the fibrinolytic protease cascade, leading to tooth loss (89). The proinflammatory factors IL-1 β and IL-6 aggravate tissue destruction by increasing MMP-1 in periodontal tissue (90, 91). Furthermore, TNF- α is important for osteoclast formation

and bone resorption in mice and suppresses ECM protein expression (92, 93).

4.4.2.4 Promoting fibrosis

TGF- β is the primary factor driving fibrosis. TGF- β activation in epithelial cells can interact with fibroblast cells and induce the expression of other profibrotic cytokines (e.g., endothelin and CTGF) (94). Areca nut alkaloids induce senescence in oral fibroblasts and TGF- β production, which is favorable for the development of oral submucosal fibrosis (95). TIMP-1 and -2 have also been proven to be early indicators of oral submucous fibrosis and aging (96). Additionally, the MMP-1 and MMP-3 secreted by senescent cells during oral submucosal fibrosis have been shown to promote fibrosis in the advanced stages (97).

4.4.3 Step 3: SASP disrupts oral immune homeostasis

4.4.3.1 Effects on mucosal immunity

SASP challenges mucosal epithelial homeostasis by undermining the physical barrier. MMP-2 cleaves cell–cell adhesion molecules, thus disrupting epithelial adhesion (62). An increased MMP-1 expression in inflamed tissues directly leads to the degradation of collagen, thereby causing tissue destruction (89). TNF modulates the apoptosis of epithelial cells and fibroblasts and suppresses ECM proteins. These results indicate that TNF—in the senescence process—can damage the epithelial barrier (93). Some SASP factors participate in the recruitment and activation of immune cells. IL-1 β greatly induces the proliferation and activation of Th1 and Th2 cells (80). IL-8 regulates neutrophil activation and migration in inflamed tissues (98). Additionally, IL-6 significantly increases the production of VEGF, bFGF, and cathepsin B in human gingival fibroblasts and synergistically induces angiogenesis in periodontitis lesions (86, 99). Senescent macrophages in the gingiva contribute to SASP release and inflammatory response, which indicates that senescence may also play an important role.

4.4.3.2 Effect on osteoimmunity

The secretome produced *via* innate host responses facilitates communication between immune cells and bone cells. Senescent immune cells regulate bone homeostasis through immune mediators that involve the SASP. For instance, IL-17, IL-1, and IL-6, as well as low levels of IFN- γ secreted by Th17 cells, promote osteoclastogenesis (100, 101). TNF- α has also been shown to strengthen osteoclastogenesis by synergizing with RANKL (102). In contrast, the bone-senescent microenvironment further enhances alveolar bone ageing. SASP factors released extracellularly from osteocytes accelerate the senescence of bone marrow (BM) (103). Selected SASP markers secreted by senescent

osteocytes from alveolar bones promote inflammation and alveolar bone loss (43). In senescent fibroblasts, IL-1 β increases the production of chemokines, including PGE2, an important chemical mediator of alveolar bone resorption (104). Additionally, senescent osteocytes develop a unique SASP signature composed of upregulated MMPs (105). MMPs can degrade ECM proteins, including sulfated proteoglycans, collagen, and fibronectin, in cartilage. Moreover, insulin-like growth factor-binding protein 4 (IGFBP-4) are upregulated in senescent osteocytes and myeloid cells, leading to deficiency in bone formation (22, 106).

4.4.3.3 Effect on oncoimmunity

Senescent cells in the tumor microenvironment (TME) may play roles in tumor progression and metastasis. CAFs are the most prominent stromal cells in TME. CAFs are senescent cells that actively communicate with other cells in the TME by secreting the SASP. TGF- β levels are upregulated by senescent oral CAFs and synergize with MMP-2 to reduce the expression of cell adhesion molecules and promote epithelial invasion (107). CAFs also modulate the epithelial-mesenchymal transition (EMT) by secreting TGF- β (108). Moreover, activated CAFs secrete proinflammatory factors that recruit and activate infiltrating immune cells (IICs). IICs provide mitogenic growth factors that stimulate the proliferation of tumor cells and other nearby stromal cells (109). IICs also express multiple proteolytic enzymes that selectively modify ECM structure and composition (110). Additionally, Park et al. proposed that the serum levels of IL-6 may be a serum biomarker for OSCC diagnosis (111). IL-6 promotes the invasion of cancer cells through the epithelial-mesenchymal transition (112). However, the immune cell subtype and its mechanism in the TME require further elucidation; further research is necessary to determine the specific roles of these factors in oral cancer.

4.4.4 Step 4: Aging and SASP in oral diseases

4.4.4.1 SASP in oral inflammatory disease

The SASP may be responsible for chronic oral inflammation, as it disrupts mucosal homeostasis through matrix degradation, senescence reinforcement, and immune cell recruitment. Compared to their young counterparts, old mice suffer frequent spontaneous periodontitis, and the expression of IL-1 β and TNF- α in the gingiva is significantly elevated (113). Increased levels of IL-6 and MMP-8 have been observed in the saliva of patients with chronic periodontitis (114). Enhanced senescence and increased SASP are observed after ligation and *P. gingivalis* infection-induced periodontitis *in vivo* (115, 116). Additionally, hyperglycemia can increase the burden of senescence in the gingival tissue (54). Senescent cells accumulate in aged and diseased oral tissues, and this accumulation is associated with severe tissue destruction.

4.4.4.2 SASP in alveolar bone loss

Bone integrity and quality undergo differential changes in various oral diseases (117). Animal studies have shown that aging is positively correlated with alveolar bone loss. Old mice have poorer alveolar bone quality, lower alveolar bone crest height, and more active bone resorption (118). Senescence-associated distension of satellites (an early and consistent marker of senescence) and p16 mRNA expression are increased in old alveolar bone samples (119). Moreover, senescent osteocytes show changes in cell phenotype and diminished osteocyte density during age-related skeletal changes. This may further damage the mechanical conduction, impair nutrient access, influence signal transduction, and ultimately result in significant bone loss (120). Senescent bone cells exacerbate chronic inflammation through SASP accumulation, leading to deterioration of the periodontal environment (119). The SASP factor secreted by LPS-induced senescent osteocytes promotes the proliferation of some oral pathogens. These pathogens produce more LPS, thereby exacerbating the senescence of alveolar osteocytes and resulting in alveolar bone loss (43).

4.4.4.3 SASP in oral cancer

Cell senescence occurs throughout life and plays dual roles in modulating the progression and suppression of oral cancers (121). The number of SA- β -Gal-positive cells is higher in OSCC specimens than in tumor-free marginal tissues (52). Senescent fibroblasts also accumulate in precancerous lesions *in vivo* (53). Senescent cells secrete many SASP factors into the TME, which may support cell proliferation, EMT, and angiogenesis, thereby promoting tumor growth and invasion. MMP-1, -2, -10, and -12 levels in the saliva of OSCC patients increase significantly (122). In OSCC, the expression of MMP-11 is associated with an increased lymph node metastasis and a low survival rate (123). MMP-7 is mainly expressed in the invasive portion of oral cancer, whereas MMP-8 and MMP-9 are mainly detected in peritumoral inflammatory cells (124). This evidence suggests that senescent cells and the SASP are key factors in the onset and progression of oral cancer.

5 Concluding remarks

SASP, derived from senescent cells, includes secreted factors that may alter the extracellular environment (proteases), mediators that transmit and amplify senescence signals (cytokines, chemokines, bioactive lipids, and EVs), and proteins that influence cancer behavior (growth factors). The composition of SASP in the oral environment consists of two parts: local SASP and circulating SASP. Local SASP is secreted by

oral senescent cells undergoing primary or secondary senescent patterns while the circulating SASP is closely associated with chronological age and ARD. As an important bridge for intercellular communication, the SASP communicates with different immune cells and is the key to securing oral homeostasis. Conversely, the SASP-induced dysregulation of immune homeostasis leads to intrinsically complex phenotypes in oral pathology. A better understanding of the relationship between SASP and the immune system is necessary for developing therapies to prevent or treat various ARDs in the oral cavity.

Author contributions

ZY and LN contributed to design, drafted and revised the manuscript; PZ contributed to design, and critically revised the manuscript; NJ and GL assisted data analysis. QW, contributed to conception, design, and critically revised the manuscript. All authors gave final approval and agree to be accountable for all aspects of the work.

Funding

The authors disclosed receipt of the following financial support for the research, authorship, and/or publication of this article: this study was supported by the National Natural Science Foundation of China (81870779) and Sichuan Provincial Science and Technology Innovation Talent Program (2021JDRC0036). Chengdu Science & Technology Program (2022-YF05-01760-SN).

Conflict of interest

The authors declare that the research was conducted in the absence of any commercial or financial relationships that could be construed as a potential conflict of interest.

Publisher's note

All claims expressed in this article are solely those of the authors and do not necessarily represent those of their affiliated organizations, or those of the publisher, the editors and the reviewers. Any product that may be evaluated in this article, or claim that may be made by its manufacturer, is not guaranteed or endorsed by the publisher.

References

- Zubeidat K, Hovav A-H. Shaped by the epithelium-postnatal immune mechanisms of oral homeostasis. *Trends Immunol* (2021) 42:622–34. doi: 10.1016/j.it.2021.05.006
- Calcinotto A, Kohli J, Zagato E, Pellegrini L, Demaria M, Alimonti A. Cellular senescence: Aging, cancer, and injury. *Physiol Rev* (2019) 99:1047–78. doi: 10.1152/physrev.00020.2018
- Basisty N, Kale A, Jeon OH, Kuehnemann C, Payne T, Rao C, et al. A proteomic atlas of senescence-associated secretomes for aging biomarker development. *PLoS Biol* (2020) 18:e3000599–e3000599. doi: 10.1371/journal.pbio.3000599
- Hernandez-Segura A, De Jong TV, Melov S, Guryev V, Campisi J, Demaria M. Unmasking transcriptional heterogeneity in senescent cells. *Curr Biol* (2017) 27:2652–60.e4. doi: 10.1016/j.cub.2017.07.033
- Gardner SE, Humphry M, Bennett MR, Clarke MCH. Senescent vascular smooth muscle cells drive inflammation through an interleukin-1 α -Dependent senescence-associated secretory phenotype. *Arteriosclerosis thrombosis Vasc Biol* (2015) 35:1963–74. doi: 10.1161/ATVBAHA.115.305896
- Migliorini P, Italiani P, Pratesi F, Puxeddu I, Boraschi D. The IL-1 family cytokines and receptors in autoimmune diseases. *Autoimmun Rev* (2020) 19:102617. doi: 10.1016/j.autrev.2020.102617
- Schaper F, Rose-John S. Interleukin-6: Biology, signaling and strategies of blockade. *Cytokine Growth Factor Rev* (2015) 26:475–87. doi: 10.1016/j.cytogfr.2015.07.004
- Varfolomeev E, Vucic D. Intracellular regulation of TNF activity in health and disease. *Cytokine* (2018) 101:26–32. doi: 10.1016/j.cyto.2016.08.035
- Sokol CL, Luster AD. The chemokine system in innate immunity. *Cold Spring Harbor Perspect Biol* (2015) 7:a016303. doi: 10.1101/cshperspect.a016303
- Smith PC, Martínez C, Cáceres M, Martínez J. Research on growth factors in periodontology. *Periodontology 2000* (2015) 67:234–50. doi: 10.1111/prd.12068
- Checchi V, Maravic T, Bellini P, Generali L, Consolo U, Breschi L, et al. The role of matrix metalloproteinases in periodontal disease. *Int J Environ Res Public Health* (2020) 17(14):4923. doi: 10.3390/ijerph17144923
- Gonias SL. Plasminogen activator receptor assemblies in cell signaling, innate immunity, and inflammation. *Am J Physiology-Cell Physiol* (2021) 321:C721–34. doi: 10.1152/ajpcell.00269.2021
- Meng J, Liu Y, Xie Z, Qing H, Lei P, Ni J. Nucleus distribution of cathepsin b in senescent microglia promotes brain aging through degradation of sirtuins. *Neurobiol Aging* (2020) 96:255–66. doi: 10.1016/j.neurobiolaging.2020.09.001
- Byun H-O, Han N-K, Lee H-J, Kim K-B, Ko Y-G, Yoon G, et al. Cathepsin d and eukaryotic translation elongation factor 1 as promising markers of cellular senescence. *Cancer Res* (2009) 69:4638–47. doi: 10.1158/0008-5472.CAN-08-4042
- Hamsanathan S, Gurkar AU. Lipids as regulators of cellular senescence. *Front Physiol* (2022) 13:796850–0. doi: 10.3389/fphys.2022.796850
- Ni C, Narzt M-S, Nagelreiter I-M, Zhang CF, Larue L, Rossiter H, et al. Autophagy deficient melanocytes display a senescence associated secretory phenotype that includes oxidized lipid mediators. *Int J Biochem Cell Biol* (2016) 81:375–82. doi: 10.1016/j.biocel.2016.10.006
- Wu D, Mura C, Beharka AA, Han SN, Paulson KE, Hwang D, et al. Age-associated increase in PGE2 synthesis and COX activity in murine macrophages is reversed by vitamin E. *Am J Physiology-Cell Physiol* (1998) 275:C661–8. doi: 10.1152/ajpcell.1998.275.3.C661
- Wei J, Chen S, Guo W, Feng B, Yang S, Huang C, et al. Leukotriene D4 induces cellular senescence in osteoblasts. *Int Immunopharmacol* (2018) 58:154–9. doi: 10.1016/j.intimp.2017.12.027
- Yin Y, Chen H, Wang Y, Zhang L, Wang X. Roles of extracellular vesicles in the aging microenvironment and age-related diseases. *J extracellular vesicles* (2021) 10:e12154–4. doi: 10.1002/jev2.12154
- Robbins PD. Extracellular vesicles and aging. *Stem Cell Invest* (2017) 4:98–8. doi: 10.21037/sci.2017.12.03
- Gonda A, Kabagwira J, Senthil GN, Wall NR. Internalization of exosomes through receptor-mediated endocytosis. *Mol Cancer Res* (2019) 17:337–47. doi: 10.1158/1541-7786.MCR-18-0891
- Al Suraih MS, Trussoni CE, Splinter PL, Larusso NF, O'hara SP. Senescent cholangiocytes release extracellular vesicles that alter target cell phenotype via the epidermal growth factor receptor. *Liver Int* (2020) 40:2455–68. doi: 10.1111/liv.14569
- Rodier F, Coppé JP, Patil CK, Hoeijmakers WA, Muñoz DP, Raza SR, et al. Persistent DNA damage signalling triggers senescence-associated inflammatory cytokine secretion. *Nat Cell Biol* (2009) 11:973–9. doi: 10.1038/ncb1909
- Kang C, Xu Q, Martin TD, Li MZ, Demaria M, Aron L, et al. The DNA damage response induces inflammation and senescence by inhibiting autophagy of GATA4. *Science* (2015) 349:aaa5612. doi: 10.1126/science.aaa5612
- Farr JN, Xu M, Weivoda MM, Monroe DG, Fraser DG, Onken JL, et al. Targeting cellular senescence prevents age-related bone loss in mice. *Nat Med* (2017) 23:1072–9. doi: 10.1038/nm.4385
- Freund A, Patil CK, Campisi J. p38MAPK is a novel DNA damage response-independent regulator of the senescence-associated secretory phenotype. *EMBO J* (2011) 30:1536–48. doi: 10.1038/emboj.2011.69
- De Cecco M, Ito T, Petrashen AP, Elias AE, Skvir NJ, Criscione SW, et al. L1 drives IFN in senescent cells and promotes age-associated inflammation. *Nature* (2019) 566:73–8. doi: 10.1038/s41586-018-0784-9
- Ito Y, Hoare M, Narita M. Spatial and temporal control of senescence. *Trends Cell Biol* (2017) 27:820–32. doi: 10.1016/j.tcb.2017.07.004
- Herranz N, Gallage S, Mellone M, Wuestefeld T, Klotz S, Hanley CJ, et al. mTOR regulates MAPKAPK2 translation to control the senescence-associated secretory phenotype. *Nat Cell Biol* (2015) 17:1205–17. doi: 10.1038/ncb3225
- He M, Chiang HH, Luo H, Zheng Z, Qiao Q, Wang L, et al. An acetylation switch of the NLRP3 inflammasome regulates aging-associated chronic inflammation and insulin resistance. *Cell Metab* (2020) 31:580–91.e5. doi: 10.1016/j.cmet.2020.01.009
- Tasdemir N, Banito A, Roe JS, Alonso-Curbelo D, Camiolo M, Tschaharganeh DF, et al. BRD4 connects enhancer remodeling to senescence immune surveillance. *Cancer Discovery* (2016) 6:612–29. doi: 10.1158/2159-8290.CD-16-0217
- Maeda H. Aging and senescence of dental pulp and hard tissues of the tooth. *Front Cell Dev Biol* (2020) 8:605996. doi: 10.3389/fcell.2020.605996
- Zayed M, Iohara K. Effects of p-cresol on senescence, survival, inflammation, and odontoblast differentiation in canine dental pulp stem cells. *Int J Mol Sci* (2020) 21(18):6931. doi: 10.3390/ijms21186931
- Morsczeck C. Effects of cellular senescence on dental follicle cells. *Pharmacology* (2021) 106:137–42. doi: 10.1159/000510014
- Zhai Y, Wei R, Liu J, Wang H, Cai W, Zhao M, et al. Drug-induced premature senescence model in human dental follicle stem cells. *Oncotarget* (2017) 8:7276–93. doi: 10.18632/oncotarget.14085
- Chen X, Yang B, Tian J, Hong H, Du Y, Li K, et al. Dental follicle stem cells ameliorate lipopolysaccharide-induced inflammation by secreting TGF- β 3 and TSP-1 to elicit macrophage M2 polarization. *Cell Physiol Biochem* (2018) 51:2290–308. doi: 10.1159/000495873
- Um S, Lee J-H, Seo B-M. TGF- β 2 downregulates osteogenesis under inflammatory conditions in dental follicle stem cells. *Int J Oral Sci* (2018) 10:29–9. doi: 10.1038/s41368-018-0028-8
- Konstantonis D, Papadopoulou A, Makou M, Eliades T, Basdra EK, Kletsas D. Senescent human periodontal ligament fibroblasts after replicative exhaustion or ionizing radiation have a decreased capacity towards osteoblastic differentiation. *Biogerontology* (2013) 14:741–51. doi: 10.1007/s10522-013-9449-0
- Fan C, Ji Q, Zhang C, Xu S, Sun H, Li Z. TGF- β induces periodontal ligament stem cell senescence through increase of ROS production. *Mol Med Rep* (2019) 20(4):3123–30. doi: 10.3892/mmr.2019.10580
- Xia Y, Sun M, Xie Y, Shu R. mTOR inhibition rejuvenates the aging gingival fibroblasts through alleviating oxidative stress. *Oxid Med Cell Longev* (2017) 2017:6292630. doi: 10.1155/2017/6292630
- Páez J, Hernández R, ESPINOZA J, ROJAS L, Martínez CE, TOBAR N, et al. Uncoupled inflammatory, proliferative, and cytoskeletal responses in senescent human gingival fibroblasts. *J Periodontol Res* (2020) 55:432–40. doi: 10.1111/jre.12727
- Kim S, Ahn SH, Lee J-S, Song J-E, Cho S-H, Jung S, et al. Differential matrix metalloproteinase (MMP) expression profiles found in aged gingiva. *PLoS One* (2016) 11:e0158777–e0158777. doi: 10.1371/journal.pone.0158777
- Aquino-Martinez R, Rowsey JL, Fraser DG, Eckhardt BA, Khosla S, Farr JN, et al. LPS-induced premature osteocyte senescence: Implications in inflammatory alveolar bone loss and periodontal disease pathogenesis. *Bone* (2020) 132:115220. doi: 10.1016/j.bone.2019.115220
- Jang DH, Bhawal UK, Min HK, Kang HK, Abiko Y, Min BM. A transcriptional roadmap to the senescence and differentiation of human oral keratinocytes. *J Gerontol A Biol Sci Med Sci* (2015) 70:20–32. doi: 10.1093/gerona/glt212
- Zhao P, Yue Z, Nie L, Zhao Z, Wang Q, Chen J, et al. Hyperglycaemia-associated macrophage pyroptosis accelerates periodontal inflamm-aging. *J Clin Periodontology* (2021) 48:1379–92. doi: 10.1111/jcpe.13517

46. Niklander S, Bandaru D, Lambert DW, Hunter KD. ROCK inhibition modulates the senescence-associated secretory phenotype (SASP) in oral keratinocytes. *FEBS Open Bio* (2020) 10:2740–9. doi: 10.1002/2211-5463.13012
47. Schwartz RE, Shokhirev MN, Andrade LR, Gutkind JS, Iglesias-Bartolome R, Shadel GS. Insights into epithelial cell senescence from transcriptome and secretome analysis of human oral keratinocytes. *Aging* (2021) 13:4747–77. doi: 10.18632/aging.202658
48. Bhaskaran N, Faddoul F, Paes Da Silva A, Jayaraman S, Schneider E, Mamileti P, et al. IL-1 β -MyD88-mTOR axis promotes immune-protective IL-17A(+)Foxp3(+) cells during mucosal infection and is dysregulated with aging. *Front Immunol* (2020) 11:595936–6. doi: 10.3389/fimmu.2020.595936
49. Kletzien H, Kelm-Nelson CA, Wang S, Suzuki M, Connor NP. Myogenic marker expression as a function of age and exercise-based therapy in the tongue. *Exp Gerontology* (2020) 142:111104–4. doi: 10.1016/j.exger.2020.111104
50. Barlagiannis D, Dietrich E, Papaliagkas V, Makri S, Toskas A, Papamitsou T. Ultrastructural aspects of the effects of L-carnitine administration on epithelial cells in the aging rat tongue. *Hippokratia* (2014) 18(1):32–6.
51. Hu Q, Peng J, Jiang L, Li W, Su Q, Zhang J, et al. Metformin as a senostatic drug enhances the anticancer efficacy of CDK4/6 inhibitor in head and neck squamous cell carcinoma. *Cell Death Dis* (2020) 11:925. doi: 10.1038/s41419-020-03126-0
52. Kim EK, Moon S, Kim DK, Zhang X, Kim J. CXCL1 induces senescence of cancer-associated fibroblasts via autocrine loops in oral squamous cell carcinoma. *PLoS One* (2018) 13:e0188847. doi: 10.1371/journal.pone.0188847
53. Pitiyage GN, Slijepcevic P, Gabrani A, Chianea YG, Lim KP, Prime SS, et al. Senescent mesenchymal cells accumulate in human fibrosis by a telomere-independent mechanism and ameliorate fibrosis through matrix metalloproteinases. *J Pathol* (2011) 223:604–17. doi: 10.1002/path.2839
54. Zhang P, Wang Q, Nie L, Zhu R, Zhou X, Zhao P, et al. Hyperglycemia-induced inflamm-aging accelerates gingival senescence via NLR4 phosphorylation. *J Biol Chem* (2019) 294:18807–19. doi: 10.1074/jbc.RA119.010648
55. Cheng W-C, Van Asten SD, Burns LA, Evans HG, Walter GJ, Hashim A, Hughes FJ, et al. Periodontitis-associated pathogens p. gingivalis and a. actinomycetemcomitans activate human CD14+ monocytes leading to enhanced Th17/IL-17 responses. *Eur J Immunol* (2016) 46:2211–21. doi: 10.1002/eji.201545871
56. Restaino CG, Chaparro A, Valenzuela MA, Kettlun AM, Vernal R, Silva A, et al. Stimulatory response of neutrophils from periodontitis patients with periodontal pathogens. *Oral Dis* (2007) 13:474–81. doi: 10.1111/j.1601-0825.2006.01323.x
57. Ebersole JL, Kirakodu SS, Novak MJ, Orraca L, Martinez JG, Cunningham LL, et al. Transcriptome analysis of b cell immune functions in periodontitis: Mucosal tissue responses to the oral microbiome in aging. *Front Immunol* (2016) 7:272–2. doi: 10.3389/fimmu.2016.00272
58. Lee Y-H, Kim G-E, Cho H-J, Yu M-K, Bhattarai G, Lee N-H, et al. Aging of *In vitro* pulp illustrates change of inflammation and dentinogenesis. *J Endodontics* (2013) 39:340–5. doi: 10.1016/j.joen.2012.10.031
59. Kim RH, Lee RS, Williams D, Bae S, Woo J, Lieberman M, et al. Bisphosphonates induce senescence in normal human oral keratinocytes. *J Dent Res* (2011) 90:810–6. doi: 10.1177/0022034511402995
60. Zhang P, Lu B, Zhu R, Yang D, Liu W, Wang Q, et al. Hyperglycemia accelerates inflammaging in the gingival epithelium through inflammasomes activation. *J Periodontol Res* (2021) 56(4):667–78. doi: 10.1111/jre.12863
61. Kabir TD, Leigh RJ, Tasena H, Mellone M, Coletta RD, Parkinson EK, et al. A miR-335/COX-2/PTEN axis regulates the secretory phenotype of senescent cancer-associated fibroblasts. *Aging (Albany NY)* (2016) 8:1608–35. doi: 10.18632/aging.100987
62. Hassona Y, Cirillo N, Heesom K, Parkinson EK, Prime SS. Senescent cancer-associated fibroblasts secrete active MMP-2 that promotes keratinocyte dis-cohesion and invasion. *Br J Cancer* (2014) 111:1230–7. doi: 10.1038/bjc.2014.438
63. Cheng W-C, Hughes FJ, Taams LS. The presence, function and regulation of IL-17 and Th17 cells in periodontitis. *J Clin Periodontology* (2014) 41:541–9. doi: 10.1111/jcpe.12238
64. He S, Sharpless NE. Senescence in health and disease. *Cell* (2017) 169:1000–11. doi: 10.1016/j.cell.2017.05.015
65. Schafer MJ, Zhang X, Kumar A, Atkinson EJ, Zhu Y, Jachim S, et al. The senescence-associated secretome as an indicator of age and medical risk. *JCI Insight* (2020) 5(12):e133668 doi: 10.1172/jci.insight.133668
66. Wang Q, Nie L, Zhao P, Zhou X, Ding Y, Chen Q, et al. Diabetes fuels periodontal lesions via GLUT1-driven macrophage inflammaging. *Int J Oral Sci* (2021) 13:11. doi: 10.1038/s41368-021-00116-6
67. Pradhan AD, Manson JE, Rifai N, Buring JE, Ridker PM. C-reactive protein, interleukin 6, and risk of developing type 2 diabetes mellitus. *JAMA* (2001) 286:327–34. doi: 10.1001/jama.286.3.327
68. Spranger J, Kroke A, Möhlig M, Hoffmann K, Bergmann MM, Ristow M, et al. Inflammatory cytokines and the risk to develop type 2 diabetes: Results of the prospective population-based European prospective investigation into cancer and nutrition (EPIC)-potsdam study. *Diabetes* (2003) 52:812–7. doi: 10.2337/diabetes.52.3.812
69. Lippitz BE. Cytokine patterns in patients with cancer: a systematic review. *Lancet Oncol* (2013) 14:e218–28. doi: 10.1016/S1470-2045(12)70582-X
70. Ferroni P, Basili S, Martini F, Cardarello CM, Ceci F, Franco MD, et al. Serum metalloproteinase 9 levels in patients with coronary artery disease: A novel marker of inflammation. *J Invest Med* (2003) 51:295. doi: 10.1136/jim-51-05-17
71. Zhang B, Li XL, Zhao CR, Pan CL, Zhang Z. Interleukin-6 as a predictor of the risk of cardiovascular disease: A meta-analysis of prospective epidemiological studies. *Immunol Invest* (2018) 47:689–99. doi: 10.1080/08820139.2018.1480034
72. Hayflick L, Moorhead PS. The serial cultivation of human diploid cell strains. *Exp Cell Res* (1961) 25:585–621. doi: 10.1016/0014-4827(61)90192-6
73. Ebersole JL, Graves CL, Gonzalez OA, Dawson D3rd, Morford LA, Huja PE, et al. Aging, inflammation, immunity and periodontal disease. *Periodontol* 2000 (2016) 72:54–75. doi: 10.1111/prd.12135
74. Hernandez-Segura A, Nehme J, Demaria M. Hallmarks of cellular senescence. *Trends Cell Biol* (2018) 28:436–53. doi: 10.1016/j.tcb.2018.02.001
75. Hodjat M, Rezvafar MA, Abdollahi M. A systematic review on the role of environmental toxicants in stem cells aging. *Food Chem Toxicol* (2015) 86:298–308. doi: 10.1016/j.fct.2015.11.002
76. Childs BG, Li H, Van Deursen JM. Senescent cells: a therapeutic target for cardiovascular disease. *J Clin Invest* (2018) 128:1217–28. doi: 10.1172/JCI95146
77. Bascones-Martínez A, López-Durán M, Cano-Sánchez J, Sánchez-Verde L, Díez-Rodríguez A, Aguirre-Echebarria P, et al. Differences in the expression of five senescence markers in oral cancer, oral leukoplakia and control samples in humans. *Oncol Lett* (2012) 3:1319–25. doi: 10.3892/ol.2012.649
78. Hodjat M, Khan F, Saadat KASM. Epigenetic alterations in aging tooth and the reprogramming potential. *Ageing Res Rev* (2020) 63:101140. doi: 10.1016/j.arr.2020.101140
79. Chung HY, Cesari M, Anton S, Marzetti E, Giovannini S, Seo AY, et al. Molecular inflammation: underpinnings of aging and age-related diseases. *Ageing Res Rev* (2009) 8:18–30. doi: 10.1016/j.arr.2008.07.002
80. Ben-Sasson SZ, Hu-Li J, Quiel J, Cauchetaux S, Ratner M, Shapira I, et al. IL-1 acts directly on CD4 T cells to enhance their antigen-driven expansion and differentiation. *Proc Natl Acad Sci United States America* (2009) 106:7119–24. doi: 10.1073/pnas.0902745106
81. Lagdive SS, Marawar PP, Byakod G, Lagdive SB. Evaluation and comparison of interleukin-8 (IL-8) level in gingival crevicular fluid in health and severity of periodontal disease: a clinico-biochemical study. *Indian J Dent Res* (2013) 24:188–92. doi: 10.4103/0970-9290.116675
82. Hou KL, Lin SK, Kok SH, Wang HW, Lai EH, Hong CY, et al. Increased expression of glutaminase in osteoblasts promotes macrophage recruitment in periapical lesions. *J Endod* (2017) 43:602–8. doi: 10.1016/j.joen.2016.11.005
83. Yuan M, Zhu H, Xu J, Zheng Y, Cao X, Liu Q. Tumor-derived CXCL1 promotes lung cancer growth via recruitment of tumor-associated neutrophils. *J Immunol Res* (2016) 2016:6530410. doi: 10.1155/2016/6530410
84. Wang H, Wang Z, Huang Y, Zhou Y, Sheng X, Jiang Q, et al. Senolytics (DQ) mitigates radiation ulcers by removing senescent cells. *Front Oncol* (2019) 9:1576. doi: 10.3389/fonc.2019.01576
85. Wei LY, Lee JJ, Yeh CY, Yang CJ, Kok SH, Ko JY, et al. Reciprocal activation of cancer-associated fibroblasts and oral squamous carcinoma cells through CXCL1. *Oral Oncol* (2019) 88:115–23. doi: 10.1016/j.oraloncology.2018.11.002
86. Sawada S, Chosa N, Ishisaki A, Nariishi K. Enhancement of gingival inflammation induced by synergism of IL-1 β and IL-6. *Biomed Res* (2013) 34:31–40. doi: 10.2220/biomedres.34.31
87. Kojima H, Kunitomo H, Inoue T, Nakajima K. The STAT3-IGFBP5 axis is critical for IL-6/gp130-induced premature senescence in human fibroblasts. *Cell Cycle* (2012) 11:730–9. doi: 10.4161/cc.11.4.19172
88. Bonnema DD, Webb CS, Pennington WR, Stroud RE, Leonardi AE, Clark LL, et al. Effects of age on plasma matrix metalloproteinases (MMPs) and tissue inhibitor of metalloproteinases (TIMPs). *J Card Fail* (2007) 13:530–40. doi: 10.1016/j.cardfail.2007.04.010
89. Emingil G, Han B, Gürkan A, Berdeli A, Tervahartiala T, Salo T, et al. Matrix metalloproteinase (MMP)-8 and tissue inhibitor of MMP-1 (TIMP-1) gene polymorphisms in generalized aggressive periodontitis: Gingival crevicular fluid MMP-8 and TIMP-1 levels and outcome of periodontal therapy. *J Periodontology* (2014) 85:1070–80. doi: 10.1902/jop.2013.130365
90. Kida Y, Kobayashi M, Suzuki T, Takeshita A, Okamatsu Y, Hanazawa S, et al. Interleukin-1 stimulates cytokines, prostaglandin E2 and matrix metalloproteinase-1 production via activation of MAPK/AP-1 and NF- κ B in

human gingival fibroblasts. *Cytokine* (2005) 29:159–68. doi: 10.1016/j.cyto.2004.10.009

91. Scheres N, Laine ML, Sipos PM, Bosch-Tijhof CJ, Crielaard W, De Vries TJ, et al. Periodontal ligament and gingival fibroblasts from periodontitis patients are more active in interaction with porphyromonas gingivalis. *J Periodontol Res* (2011) 46:407–16. doi: 10.1111/j.1600-0765.2011.01353.x
92. Leonardi R, Talic NF, Loreto C. MMP-13 (collagenase 3) immunolocalisation during initial orthodontic tooth movement in rats. *Acta Histochemica* (2007) 109:215–20. doi: 10.1016/j.acthis.2007.01.002
93. Pan W, Wang Q, Chen Q. The cytokine network involved in the host immune response to periodontitis. *Int J Oral Sci* (2019) 11:30. doi: 10.1038/s41368-019-0064-z
94. Kondaiah P, Pant I, Khan I. Molecular pathways regulated by areca nut in the etiopathogenesis of oral submucous fibrosis. *Periodontol* (2019) 80:213–24. doi: 10.1111/prd.12266
95. Rehman A, Ali S, Lone MA, Atif M, Hassona Y, Prime SS, et al. Areca nut alkaloids induce irreparable DNA damage and senescence in fibroblasts and may create a favourable environment for tumour progression. *J Oral Pathol Med* (2016) 45:365–72. doi: 10.1111/jop.12370
96. Pitiyage GN, Lim KP, Gemenitzidis E, Teh MT, Waseem A, Prime SS, et al. Increased secretion of tissue inhibitors of metalloproteinases 1 and 2 (TIMPs -1 and -2) in fibroblasts are early indicators of oral sub-mucous fibrosis and ageing. *J Oral Pathol Med* (2012) 41:454–62. doi: 10.1111/j.1600-0714.2012.01129.x
97. Sharma M, Hunter KD, Fonseca FP, Radhakrishnan R. Emerging role of cellular senescence in the pathogenesis of oral submucous fibrosis and its malignant transformation. *Head Neck* (2021) 43:3153–64. doi: 10.1002/hed.26805
98. Chen X, Huang J, Zhong L, Ding C. Quantitative assessment of the associations between interleukin-8 polymorphisms and periodontitis susceptibility. *J Periodontology* (2015) 86:292–300. doi: 10.1902/jop.2014.140450
99. Naruishi K, Nishimura F, Yamada-Naruishi H, Omori K, Yamaguchi M, Takashiba S. C-jun n-terminal kinase (JNK) inhibitor, SP600125, blocks interleukin (IL)-6-induced vascular endothelial growth factor (VEGF) production: cyclosporine a partially mimics this inhibitory effect. *Transplantation* (2003) 76(5):1380–2. doi: 10.1097/01.TP.0000085661.52980.95
100. Sato K, Suematsu A, Okamoto K, Yamaguchi A, Morishita Y, Kadono Y, et al. Th17 functions as an osteoclastogenic helper T cell subset that links T cell activation and bone destruction. *J Exp Med* (2006) 203:2673–82. doi: 10.1084/jem.20061775
101. Takayanagi H, Ogasawara K, Hida S, Chiba T, Murata S, Sato K, et al. T-Cell-mediated regulation of osteoclastogenesis by signalling cross-talk between RANKL and IFN- γ . *Nature* (2000) 408:600–5. doi: 10.1038/35046102
102. Azuma Y, Kaji K, Katogi R, Takeshita S, Kudo A. Tumor necrosis factor- α induces differentiation of and bone resorption by osteoclasts*. *J Biol Chem* (2000) 275:4858–64. doi: 10.1074/jbc.275.7.4858
103. Zhou S, Greenberger JS, Epperly MW, Goff JP, Adler C, Leboff MS, et al. Age-related intrinsic changes in human bone-marrow-derived mesenchymal stem cells and their differentiation to osteoblasts. *Ageing Cell* (2008) 7:335–43. doi: 10.1111/j.1474-9726.2008.00377.x
104. Hwang YH, Kim T, Kim R, Ha H. The natural product 6-gingerol inhibits inflammation-associated osteoclast differentiation via reduction of prostaglandin E₂ levels. *Int J Mol Sci* (2018) 19(7):2068. doi: 10.3390/ijms19072068
105. Litwinoff E, Hurtado Del Pozo C, Ramasamy R, Schmidt AM. Emerging targets for therapeutic development in diabetes and its complications: The RAGE signaling pathway. *Clin Pharmacol Ther* (2015) 98:135–44. doi: 10.1002/cpt.148
106. Mohan S, Baylink D. Serum insulin-like growth factor binding protein (IGFBP)-4 and IGFBP-5 levels in aging and age-associated diseases. *Endocrine* (1997) 7:87–91. doi: 10.1007/BF02778070
107. Hassona Y, Cirillo N, Lim KP, Herman A, Mellone M, Thomas GJ, et al. Progression of genotype-specific oral cancer leads to senescence of cancer-associated fibroblasts and is mediated by oxidative stress and TGF- β . *Carcinogenesis* (2013) 34:1286–95. doi: 10.1093/carcin/bgt035
108. Chaffer CL, Weinberg RA. A perspective on cancer cell metastasis. *Science* (2011) 331:1559–64. doi: 10.1126/science.1203543
109. Balkwill F, Charles KA, Mantovani A. Smoldering and polarized inflammation in the initiation and promotion of malignant disease. *Cancer Cell* (2005) 7:211–7. doi: 10.1016/j.ccr.2005.02.013
110. Bonnans C, Chou J, Werb Z. Remodelling the extracellular matrix in development and disease. *Nat Rev Mol Cell Biol* (2014) 15:786–801. doi: 10.1038/nrm3904
111. Park DG, Woo BH, Lee BJ, Yoon S, Cho Y, Kim YD, et al. Serum levels of interleukin-6 and titers of antibodies against porphyromonas gingivalis could be potential biomarkers for the diagnosis of oral squamous cell carcinoma. *Int J Mol Sci* (2019) 20(11):2749. doi: 10.3390/ijms20112749
112. Qu Y, He Y, Yang Y, Li S, An W, Li Z, et al. ALDH3A1 acts as a prognostic biomarker and inhibits the epithelial mesenchymal transition of oral squamous cell carcinoma through IL-6/STAT3 signaling pathway. *J Cancer* (2020) 11:2621–31. doi: 10.7150/jca.40171
113. Liang S, Hosur KB, Domon H, Hajishengallis G. Periodontal inflammation and bone loss in aged mice. *J Periodontol Res* (2010) 45:574–8. doi: 10.1111/j.1600-0765.2009.01245.x
114. Miller CS, Ding X, Dawson Iii DR, Ebersole JL. Salivary biomarkers for discriminating periodontitis in the presence of diabetes. *J Clin Periodontology* (2021) 48:216–25. doi: 10.1111/jcpe.13393
115. Wang Q, Zhou X, Zhang P, Zhao P, Nie L, Ji N, et al. 25-hydroxyvitamin D (3) positively regulates periodontal inflammaging via SOCS3/STAT signaling in diabetic mice. *Steroids* (2020) 156:108570. doi: 10.1016/j.steroids.2019.108570
116. Qin ZY, Gu X, Chen YL, Liu JB, Hou CX, Lin SY, et al. Toll-like receptor 4 activates the NLRP3 inflammasome pathway and periodontal inflammaging by inhibiting Bmi-1 expression. *Int J Mol Med* (2021) 47:137–50. doi: 10.3892/ijmm.2020.4787
117. Kato CN, Barra SG, Tavares NP, Amaral TM, Brasileiro CB, Mesquita RA, et al. Use of fractal analysis in dental images: a systematic review. *Dentomaxillofac Radiol* (2020) 49:20180457. doi: 10.1259/dmfr.20180457
118. Damanaki A, Memmert S, Nokhbehsaim M, Sanyal A, Gnad T, Pfeifer A, et al. Impact of obesity and aging on crestal alveolar bone height in mice. *Ann Anat* (2018) 218:227–35. doi: 10.1016/j.aanat.2018.04.005
119. Aquino-Martinez R, Eckhardt BA, Rowsey JL, Fraser DG, Khosla S, Farr JN, et al. Senescent cells exacerbate chronic inflammation and contribute to periodontal disease progression in old mice. *J Periodontol* (2020) 92(10):1483–95. doi: 10.1002/JPER.20-0529
120. Holguin N, Brodt MD, Silva MJ. Activation of wnt signaling by mechanical loading is impaired in the bone of old mice. *J Bone Miner Res* (2016) 31:2215–26. doi: 10.1002/jbmr.2900
121. Kumar M, Nanavati R, Modi TG, Dobariya C. Oral cancer: Etiology and risk factors: A review. *J Cancer Res Ther* (2016) 12:458–63. doi: 10.4103/0973-1482.186696
122. Feng Y, Li Q, Chen J, Yi P, Xu X, Fan Y, et al. Salivary protease spectrum biomarkers of oral cancer. *Int J Oral Sci* (2019) 11:7. doi: 10.1038/s41368-018-0032-z
123. Hsin CH, Chou YE, Yang SF, Su SC, Chuang YT, Lin SH, et al. MMP-11 promoted the oral cancer migration and Fak/Src activation. *Oncotarget* (2017) 8:32783–93. doi: 10.18632/oncotarget.15824
124. Ahmed Haji Omar A, Haglund C, Virolainen S, Häyry V, Atula T, Kontio R, et al. MMP-7, MMP-8, and MMP-9 in oral and cutaneous squamous cell carcinomas. *Oral Surg Oral Med Oral Pathol Oral Radiol* (2015) 119:459–67. doi: 10.1016/j.oooo.2014.12.019



OPEN ACCESS

EDITED BY

Dunfang Zhang,
Sichuan University, China

REVIEWED BY

HAO Xu,
Sichuan University, China
Xiaobing Guan,
Capital Medical University, China

*CORRESPONDENCE

Wenmei Wang
wenmei-wang@hotmail.com
Fuhua Yan
yanfh@nju.edu.cn
Qinggang Hu
qghu@nju.edu.cn

[†]These authors have contributed
equally to this work

SPECIALTY SECTION

This article was submitted to
Mucosal Immunity,
a section of the journal
Frontiers in Immunology

RECEIVED 13 August 2022

ACCEPTED 30 September 2022

PUBLISHED 19 October 2022

CITATION

Wang X, Xiong K, Huang F, Huang J,
Liu Q, Duan N, Ruan H, Jiang H,
Zhu Y, Lin L, Song Y, Zhao M, Zheng L,
Ye P, Qian Y, Hu Q, Yan F and Wang W
(2022) A metagenome-wide
association study of the gut
microbiota in recurrent aphthous ulcer
and regulation by thalidomide.
Front. Immunol. 13:1018567.
doi: 10.3389/fimmu.2022.1018567

COPYRIGHT

© 2022 Wang, Xiong, Huang, Huang,
Liu, Duan, Ruan, Jiang, Zhu, Lin, Song,
Zhao, Zheng, Ye, Qian, Hu, Yan and
Wang. This is an open-access article
distributed under the terms of the
Creative Commons Attribution License
(CC BY). The use, distribution or
reproduction in other forums is
permitted, provided the original
author(s) and the copyright owner(s)
are credited and that the original
publication in this journal is cited, in
accordance with accepted academic
practice. No use, distribution or
reproduction is permitted which does
not comply with these terms.

A metagenome-wide association study of the gut microbiota in recurrent aphthous ulcer and regulation by thalidomide

Xiang Wang^{1†}, Kexu Xiong^{2†}, Fan Huang^{1†}, Jinqun Huang^{3†},
Qin Liu^{1†}, Ning Duan¹, Huanhuan Ruan¹, Hongliu Jiang¹,
Yanan Zhu¹, Lin Lin¹, Yuefeng Song¹, Maomao Zhao¹,
Lichun Zheng¹, Pei Ye¹, Yajie Qian¹, Qinggang Hu^{1*},
Fuhua Yan^{1*} and Wenmei Wang^{1*}

¹Nanjing Stomatological Hospital, Medical School of Nanjing University, Nanjing, China, ²College of Life Sciences, University of Chinese Academy of Sciences, Beijing, China, ³Beijing Genomics Institute (BGI)-genomics, BGI-Shenzhen, Shenzhen, China

Recurrent aphthous ulcer (RAU), one of the most common diseases in humans, has an unknown etiology and is difficult to treat. Thalidomide is an important immunomodulatory and antitumor drug and its effects on the gut microbiota still remain unclear. We conducted a metagenomic sequencing study of fecal samples from a cohort of individuals with RAU, performed biochemical assays of cytokines, immunoglobulins and antimicrobial peptides in serum and saliva, and investigated the regulation effects of thalidomide administration and withdrawal. Meanwhile we constructed the corresponding prediction models. Our metagenome-wide association results indicated that gut dysbacteriosis, microbial dysfunction and immune imbalance occurred in RAU patients. Thalidomide regulated gut dysbacteriosis in a species-specific manner and had different sustainable effects on various probiotics and pathogens. A previously unknown association between gut microbiota alterations and RAU was found, and the specific roles of thalidomide in modulating the gut microbiota and immunity were determined, suggesting that RAU may be affected by targeting gut dysbacteriosis and modifying immune imbalance. In-depth insights into sophisticated networks consisting of the gut microbiota and host cells may lead to the development of emerging treatments, including prebiotics, probiotics, synbiotics, and postbiotics.

KEYWORDS

gut microbiota, recurrent aphthous ulcer, metagenome, immunity, thalidomide

Introduction

Recurring aphthous ulcer (RAU), also known as recurrent oral ulcer, is a condition that affects 20% of the world's population and is characterized by painful, yellow ulcers in the oral mucosa (1). Frequent or almost continuous recurrence causes terrible difficulties in eating, drinking, swallowing, and speaking, and as a result, it negatively affects the quality of life of RAU patients. Several factors have been proposed as possible causative agents for RAU, including microbial and immune factors, but a definitive etiology of RAU has yet to be clearly established (2).

Characterization of the gut microbiota has become an important research area for human diseases. The important role of dysbacteriosis in a variety of diseases [colorectal cancer, type 2 diabetes, and Behcet's disease (BD)] has been widely recognized (3–5). The gut microbiota, microbial function, and immune factors, which are generally in a state of dynamic balance, contribute substantially to human health. A previous study indicated that RAU is related to changes in the oral microflora (6), but the relationship between the gut microbiota and RAU is still rarely reported. Moreover, a correlation network study based on metagenomic analysis of the gut microbiota along with immune factor assays of serum and saliva has not been conducted.

Thalidomide has long been used for the treatment of RAU, and can effectively reduce the frequency, number, and pain of ulcers (7). Thalidomide has immunomodulatory, anti-inflammatory and antiangiogenic effects and has been widely applied in the treatment of immune system diseases and malignant tumors (8). Thalidomide is effective in RAU treatment, but the specific mechanism is still unclear. To the best of our knowledge, thalidomide has not been linked to microbiota modulation in the literature.

Pioneering studies on the oral microbiota characteristics of RAU patients were based on 16S rRNA gene amplicon sequencing (9, 10). So far, no individual pathogens have been conclusively shown to be correlative agents of RAU (6). A recent study suggested that RAU occurrence is significantly associated with an increase in *Escherichia coli* and a decrease in *Alloprevotella* abundances (11). However, few metagenomic studies on RAU have been reported. Metagenomic sequencing can provide better genome coverage and obtain genetic diversity, molecular ecological, and microbial function information (12).

In this study, we first investigated the metagenome-wide association of the gut microbiota in RAU and found previously unknown aberrant profiles of the intestinal microbiota in RAU and the specific regulatory effects of thalidomide on the intestinal microbiota and immune factors. Our study might improve the understanding of RAU pathogenesis and the possible mechanism of thalidomide in treating the disease, providing novel ideas for precision therapy by supplementing with probiotics, prebiotics, synbiotics and postbiotics.

Results

Diversity analysis of the gut microbiota in RAU

To examine the gut microbiota of patients with RAU, we first analyzed fecal samples from 81 patients with refractory RAU [at the visit time (T)1] and 44 age- and sex-matched healthy controls (Control) by metagenomic sequencing. The bacterial diversity of the fecal microbiota in the RAU and control groups is shown in Figure 1, and the baseline information of the two groups is shown in Table S1. In total, 238 species belonging to 17 phyla (Actinobacteria, Bacteroidetes, Fibrobacteres, Firmicutes, Fusobacteria, Gemmatimonadetes, Proteobacteria, etc.) were detected by comparisons [Control vs. T1, T1 vs. T2, T2 vs. T3, false discovery rate (FDR) ≤ 0.05] (Table S2) and there were no differences of gut microbiome-associated taxonomic and functional diversity in the RAU patients and controls (Figure 2).

Taxonomical signatures of the gut microbiota in RAU and regulation by thalidomide

To reveal the differences in gut microbes between the RAU patients and controls, we used Kraken2 to annotate the sequenced reads and Bracken to correct the species abundance and screened out the species with significant differences between different stages (FDR ≤ 0.005). The results showed that a total of 86 species were significantly differentially abundant between the RAU patients and controls (comparison of Control vs. T1) (FDR ≤ 0.005). A great number of probiotics were significantly depleted, while an array of pathogens were remarkably enriched in the gut microbiota of patients with RAU. *Acidaminococcus intestini*, *Raoultella terrigena*, *Enterococcus faecium*, *Hafnia paralvei* and other probiotics were significantly depleted in the RAU patients (Figures 3A, S1). *Bacteroides fragilis*, *Parabacteroides* sp. CT06, *Enterococcus phage IMEEFm1*, *Enterobacter bugandensis* and other pathogens were significantly enriched in RAU patients (Figures 3A, S1). Notably, *A. intestini*, *Enterococcus faecium*, *Proteus mirabilis* and other probiotics increased in T2 and continued to increase in T3 (Figure 3A), indicating that thalidomide has an upregulatory effect on the decreased abundances of probiotics and that this effect could be maintained via a long-term regulation. Our results showed that *A. intestine* abundance decreased in RAU patients, indicating that *A. intestini* is a potential probiotic. *A. intestini* is known to be a normal commensal of the human gut (13). Its metabolic end products are acetic acid, butyric acid and propionic acid. The antibiotic-resistant *Enterococcus phage IMEEFm1* has shown highly effective lytic activity against *Enterococcus faecium* (14).

Similarly, one month after taking thalidomide, *B. fragilis*, *E. coli*, *Parabacteroides* sp. CT06, *Enterococcus phage IMEEFm1*,

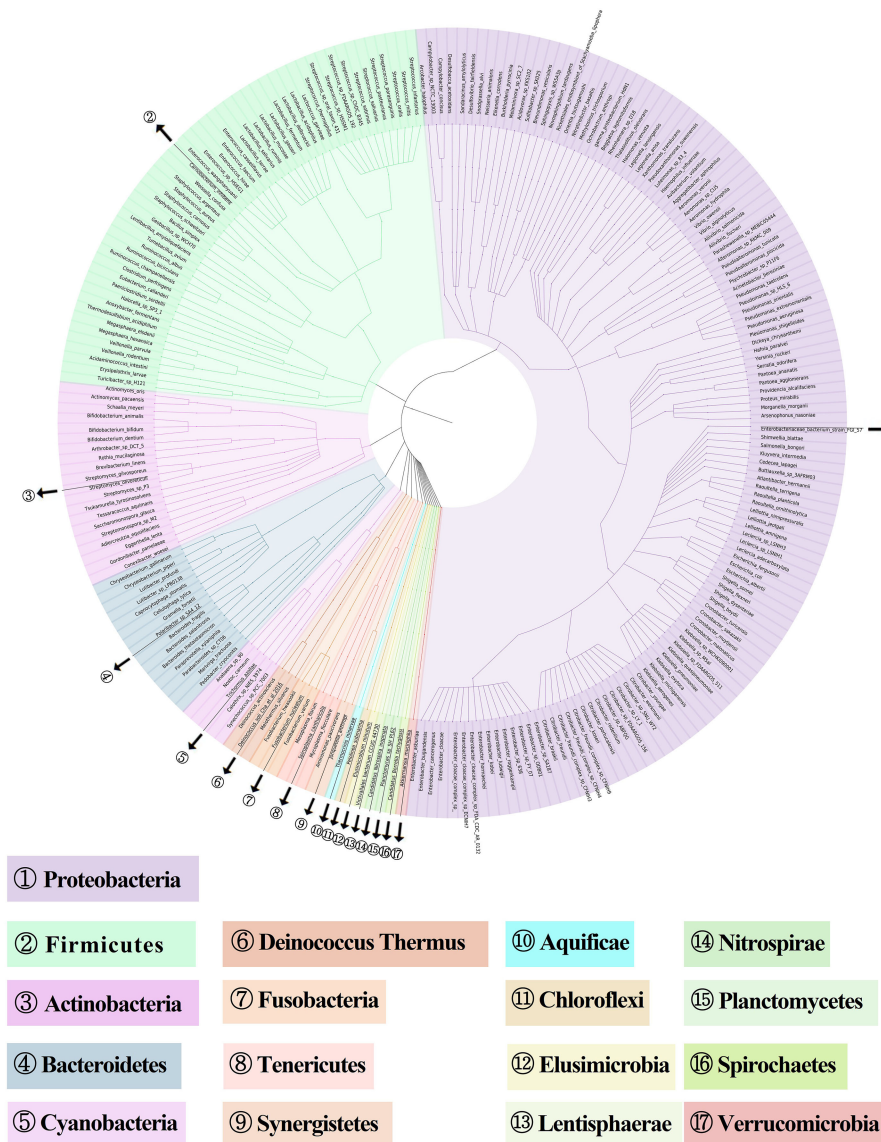


FIGURE 1
Metagenome-based diversity analysis of RAU gut microbiota. In total, 238 abundant species between RAU patients and healthy controls are shown in a phylogenetic tree according to the color code. The phylums of bacteria are given in the outer circles with circled numbers which including 17 phylums.

and *Citrobacter freundii* abundances were significantly reduced and dropped continuously one month after thalidomide withdrawal (Figures 3A, S1). These results indicated that thalidomide had a downregulatory effect on the increase in pathogenic bacteria abundance and that this effect could be maintained via a long-term regulation. *B. fragilis* is an opportunistic pathogen involved in causing disease in humans under certain conditions, such as disruption of the colon mucosal surface induced by inflammation, trauma, or surgery, and the spread of *B. fragilis* to the bloodstream or surrounding tissues results in clinically significant infection (15).

A previous study also suggested that RAU occurrence is significantly associated with an increase in *E. coli* abundance (11). In this study, thalidomide increased the abundance of potential probiotics, which was maintained after drug discontinuation, while it reduced the abundance of potential pathogenic bacteria, which was maintained after drug discontinuation. Our results suggest that thalidomide can regulate the disturbance of the gut flora, which further suggests that this may be a novel mechanism of thalidomide in the treatment of RAU.

The symbiosis factor of *B. fragilis*, PSA, can directly induce the anti-inflammatory function of regulatory T cells (Tregs) and

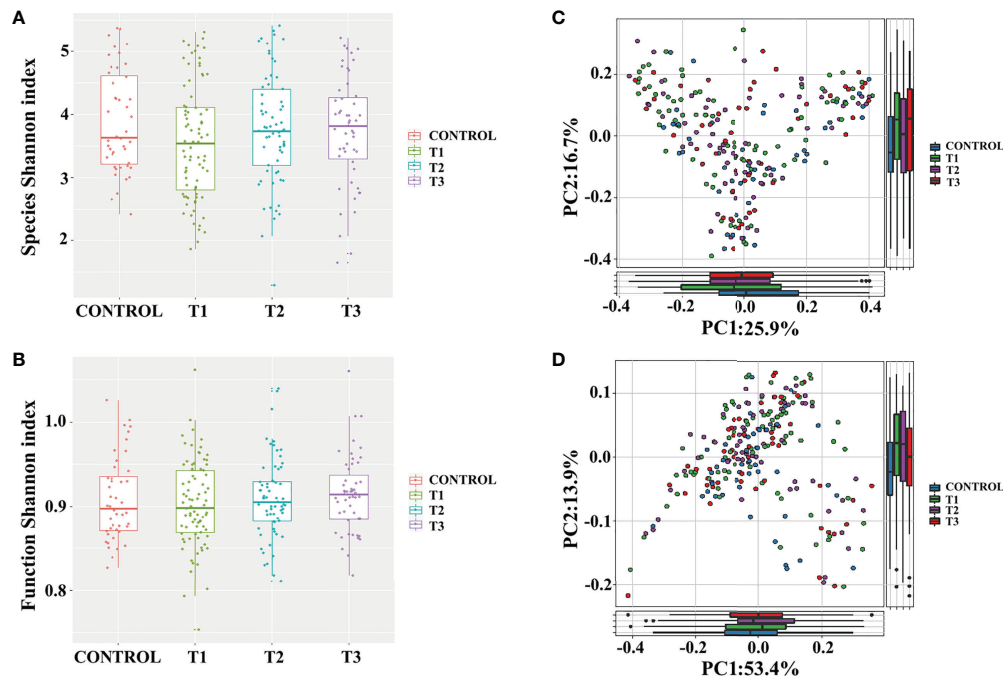


FIGURE 2

Gut microbiome-associated taxonomic and functional characteristics of RAU patients and healthy controls. (A) Taxonomic alpha-diversity of RAU and healthy controls ($P>0.05$). (B) Functional alpha-diversity of RAU and healthy controls ($P>0.05$). (C) Taxonomic beta-diversity of RAU and healthy controls ($P>0.05$). (D) Functional beta-diversity of RAU and healthy controls ($P>0.05$).

restrain intestinal T helper 17 (Th17) cell development and responses during commensal colonization (16). Moreover, *B. fragilis* can produce propionic acid to increase Treg cell numbers while decreasing Th17 cell numbers (17, 18). Additionally,

Parabacteroides produces acetate to alleviate inflammation by reducing neutrophil infiltration (17).

To reveal the key microbial groups leading to gut microbiota variation in RAU, edgeR was used to evaluate the differences

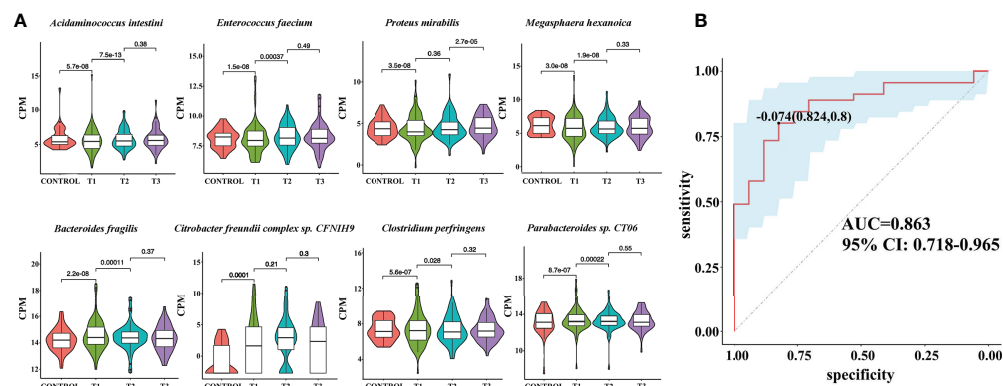


FIGURE 3

Metagenomic sequencing-based exploration of RAU-associated fecal microbiomes with those of healthy individuals and the prediction model based on fecal microbial species of RAU and healthy controls. (A) Violin plot analysis comparing the levels of fecal microbial species in control, T1, T2 and T3 groups ($P<0.05$). The vertical position of each histogram represents the relative expression level of fecal microbial species. (B) Receiver operating characteristic curves for fecal microbial species comprising samples from RAU and healthy controls. "0.824" is the sensitivity of the optimal threshold point, and "0.8" is the specificity. "-0.074" is the score of adaboost model at the optimal threshold point. The blue area 95% confidence represents the confidence interval.

between Control and T1 samples ($FDR \leq 0.05$). A total of 190 bacterial species were screened out. The area under curve (AUC) value (R function roc) was calculated for each of the 190 species, and 38 species with $AUC > 0.7$ were screened out. Through the ensemble learning method, these bacteria were modeled (adabag package), and the prediction model with an AUC of 0.863 was obtained by 100 iterations (Figure 3B). AUC is used to judge the advantages and disadvantages of the prediction model. The closer the model is to one, the more accurate the prediction is. In addition the correlation of gut microbiome-associated species and blood and saliva factors is shown in the heatmap and some distinct modules could be found (Figure 4).

Functional signatures of the gut microbiota in RAU

We used HumanN3 to generate a functional map of the gut microbiota, and our results indicated that there were 90 pathways with significantly distinct abundance between RAU patients and healthy individuals ($FDR \leq 0.05$). Among these pathways, menaquinol-8_biosynthesis_II, L-arginine_biosynthesis_IV_archaeobacteria, folate_transformations_II, chorismate_biosynthesis_from_3-dehydroquinate and other pathways were significantly depleted in RAU patients at T1 compared with those in the controls (Figures 5A, S2). Acetylene degradation, TCA cycle VII acetate production, phytate degradation I and other pathways were significantly enriched at T1 compared with those in the controls and positively correlated

with pathogenic bacteria (Figures 5A, S3). L-arginine mediates an important function, maintaining intestinal barrier function and inflammation-associated immunosuppression. Pathways related to short-chain fatty acid (SCFA) and L-arginine synthesis play a significant role in shaping the gut microbiota and innate immunity, thus improving gut development and protecting against pathogenic infection (19). Dietary L-arginine supplementation alleviates liver injury caused by *E. coli* LPS (20), activates intestinal innate immunity (21), and protects against deoxynivalenol-induced toxicity (22).

In particular, there was a positive correlation between probiotics and menaquinol-8_biosynthesis_II, which were significantly depleted at T1 compared with those in the controls. We found that this pathway was negatively correlated with some pathogenic bacteria, such as *E. coli*. It has been reported that cytochrome bo(3) [cyt bo(3)] is one of the three terminal oxygen reductases in the aerobic respiratory chain of *E. coli* and maintains the activity of ubiquitin oxidase through the menaquinol-8 pathway. A potential explanation is that the decrease in the abundance of the menaquinol-8 pathway could induce cyt bo(3) dysfunction or interruption or decrease the function of the aerobic respiratory chain of *E. coli* and enhance micro-oxygen or anaerobic conditions, initiating *E. coli* pathogenicity and RAU (23).

The tricarboxylic acid cycle (TCA) cycle (24) has long been considered a “housekeeping” pathway in *E. coli* and *Salmonella enterica*, and the pathway is highly regulated at the transcriptional level and responds to respiratory conditions. Glyoxylate bypass has long been known to be essential for

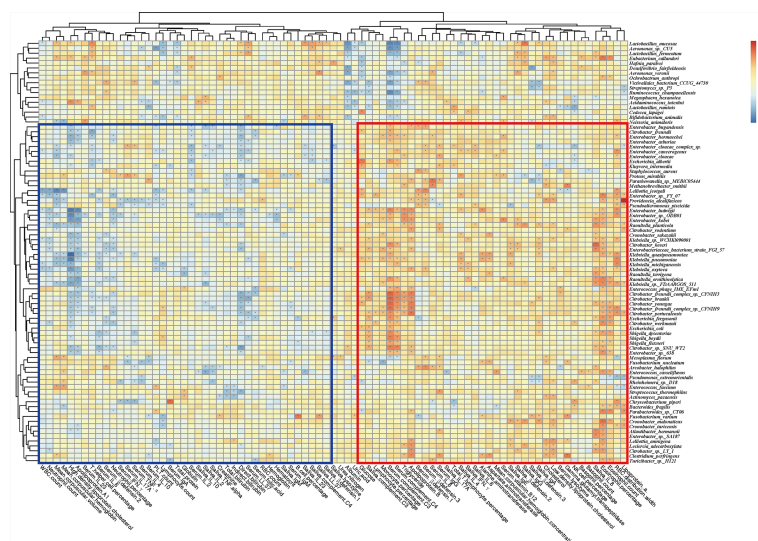


FIGURE 4

Correlation heatmap of gut microbiome-associated species and the blood and saliva factors between RAU patients and healthy controls. Blue boxes denote the cluster of negative correlation, those encompassed by the red box represent the cluster of positive correlation. The colors are proportional to the correlation strength, the variation from red to blue represent positive to negative trend. “**” means $P < 0.05$.

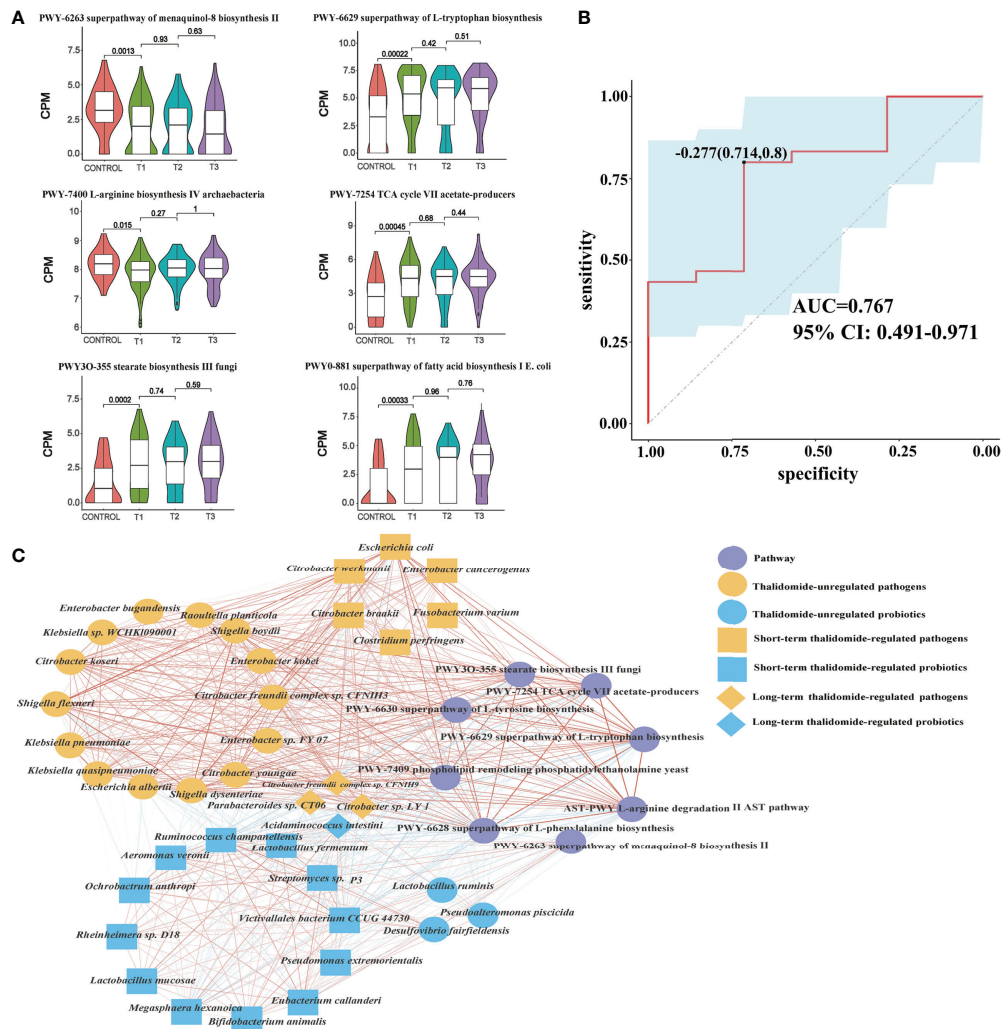


FIGURE 5

Contributinal diversity of fecal microbiome pathways. (A) Violin plot analysis comparing the levels of fecal pathways in control, T1, T2 and T3 groups ($P < 0.05$ between control and T1). (B) Receiver operating characteristic curves for fecal microbial pathways comprising samples from RAU and healthy controls. "0.714" is the sensitivity of the optimal threshold point, and "0.8" is the specificity. "-0.277" is the score of adaboost model at the optimal threshold point. The blue area 95% confidence represents the confidence interval. (C) Abundance-based species-pathways correlation network enriched in RAU patients and healthy individuals. Two nodes are linked if they are related. The edge width is proportional to the correlation strength. Nodes with the different color and shapes are classified in the different effective order level with Thalidomide.

growth on carbon sources such as acetate or fatty acids. Strains lacking this pathway fail to grow on these carbon sources, since acetate carbon entering the TCA cycle is quantitatively lost as CO_2 , resulting in the lack of a means to replenish the dicarboxylic acids consumed in amino acid biosynthesis. A microbial production platform has been developed in *E. coli* to synthesize D-glyceric acid from D-galacturonate (24). The use of adequate probiotic lactobacilli, i.e., homolactic and/or facultatively heterolactic l-lactic acid-producing lactobacilli (25), reduces the amounts of intestinal bacteria, toxic metabolites, D-lactic acid and ethanol by fermentative production of the nontoxic l-lactic acid from glucose.

Accordingly, through functional analysis, we found that the beneficial bacteria were negatively correlated with the L-tryptophan biosynthesis pathway, while pathogenic bacteria were positively correlated with the L-tryptophan biosynthesis pathway. A previous study (26) confirmed that some *E. coli* variants can promote an increase in indole and tryptophan production. Tryptophan and 5-hydroxyindoleacetic acid have been found to be significantly enriched in patients with colorectal cancer, indicating that the tryptophan metabolic pathway is closely related to anti-inflammatory effects (27). Changes in the microbiome regulate the host immune system by regulating tryptophan metabolism. In addition,

tryptophan has profound effects on gut microbiome composition, microbial metabolism, the host immune system, host-microbiome interplay, and host-immune system-gut microbiome interactions. Our results indicated that both *E. coli* and the tryptophan pathway were significantly enriched in RAU, suggesting that changes in the tryptophan metabolic pathway along with *E. coli* abundance were closely related to the occurrence of RAU.

To reveal the key pathways leading to functional variation of the gut microbiota in RAU, differences in Control and T1 samples were evaluated by limma ($FDR \leq 0.05$), and a total of 90 pathways were screened out. The AUC value (R function roc) was calculated for each of the 90 pathways, and 5 pathways ($AUC > 0.7$) were selected. Through the ensemble learning method, these pathways were modeled (adabag package) and iterated 100 times to obtain the prediction model with an AUC of 0.767, including pathways (Figure 5B). The correlation network of relevant pathways and species between the RAU patients and health controls is shown in Figure 5C. The main contributonal pathways of feces microbiota are shown in Figure 6 and the correlation heatmap of gut microbiome-associated metabolic pathways and blood and saliva factors is shown in Figure 7.

Regulatory effects of thalidomide on immune factor levels in RAU

To measure the alterations in serum and saliva levels of cytokines, antimicrobial peptides, and immunoglobins between groups, ELISAs were used. The results showed that the levels of interleukin (IL)-17A, tumor necrosis factor (TNF)- α , IL-2, IL-4, IL-8, β -defensin-2, β -defensin-3, immunoglobulin (Ig)A, and

complement C3, C4 in serum were significantly different between comparisons (Figures 8A, S4). The levels of IL-6, IL-23, interferon (IFN)- γ , lysozyme, IgA, IgG, IgM, and complement C3, C4 in saliva were significantly different between groups (Figures 8A, S5). Interestingly, we detected that TNF- α , IL-4, IL-8, IL-17A, β -defensin-1, β -defensin-2, and β -defensin-3 levels in serum were positively correlated with probiotic abundances. However, lysozyme in serum and lysozyme, IFN- γ , IL-6, IL-23, IgA, complement C3, and C4 in saliva were positively correlated with pathogenic bacteria. Most notably, serum IL-17A levels significantly decreased at T1 compared with those in the controls, suggesting that systemic and protective Th17 inflammation was inhibited in the RAU. One month after taking thalidomide, serum IL-17A levels significantly increased at T2 compared with T1 (Figures 8A), indicating that thalidomide can rescue protective Th17 inflammation and immunity against pathogens. Moreover, our results indicated that serum IL-4 and IL-8 levels significantly increased at T2 compared with T1 (Figures 8A, S4). Additionally, our results indicated that serum IL-23 level and saliva IL-6, IFN- γ , lysozyme, complement C3, and C4 levels significantly decreased at T2 compared with T1 (Figures 8A, S4, S5). Since most inflammatory and autoimmune diseases involve Th17 generation, it could be proposed that one of the novel mechanisms of action of thalidomide and its analogs could be blocking this cytokine, enhancing an anti-inflammatory response (28).

Digestive tract dysbacteriosis may cause diseases. Most recently, studies have demonstrated that finely tuned crosstalk between the microbiota, immune cells, and the epithelium is critical for the maintenance of the mucosal architecture and homeostasis (29–31). An increasing body of evidence suggests that perturbations of the mucosal microbiota can modulate innate

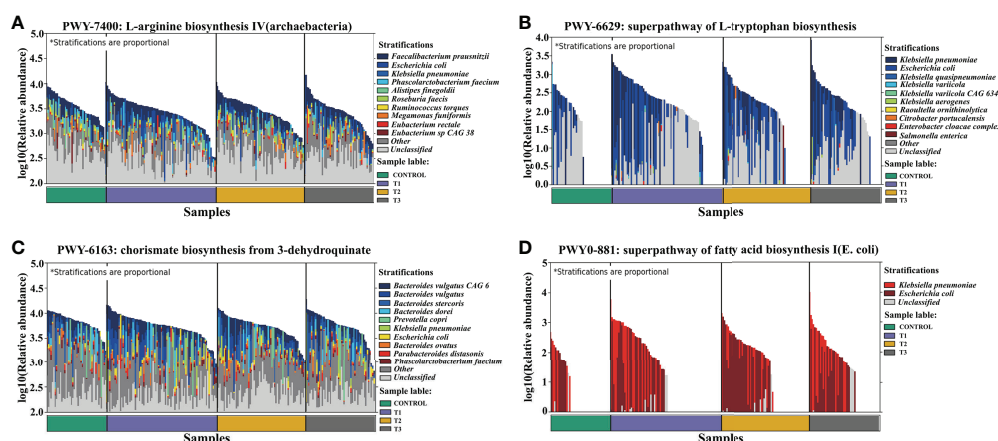


FIGURE 6

Dominant species contributing to metabolic pathways. (A) L-arginine biosynthesis IV (archaeobacterial). (B) Superpathway of L-tryptophan biosynthesis. (C) Chorismate biosynthesis from 3-dehydroquinate. (D) Superpathway of fatty acid biosynthesis I (*E. coli*).

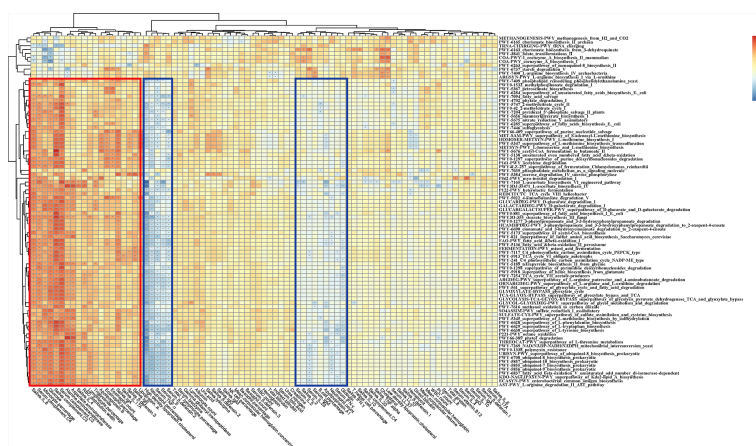


FIGURE 7

Correlation heatmap of gut microbiome-associated metabolic pathways and the blood and saliva factors between the RAU patients and health controls. Blue boxes denote the cluster of negative correlation, those encompassed by the red box represent the cluster of positive correlation. The colors are proportional to the correlation strength, the variation from red to blue represent positive to negative trend. “*” means $P < 0.05$.

and adaptive immune responses, with inflammation arising due to a reduction in the number of symbiont microorganisms and/or an increase in the number of pathobiont microorganisms (commensal bacteria with pathogenic potential) (32, 33). For example, one mechanism by which these microbes regulate immunity is by controlling Tregs and Th17 cells (34). In addition, the epithelium recognizes and responds to the microbiota, and in turn, microbial dysbiosis and associated metabolite alterations destroy the integrity of the mucosal epithelium and its barrier functions (35). The protective effects of the newly identified lineage of Th17 cells against pathogens such as *E. coli*, *Klebsiella pneumoniae*, *Citrobacter rodentium* and *Candida albicans* indicate the capacity of Th17 cells to confer protection against extracellular bacterial and fungal pathogens.

The immunopathogenesis of RAU probably involves a cell-mediated immune response mechanism including TNF- α (36). TNF- α , a major inflammatory mediator, induces regulation of immune cells and initiation of the inflammatory process to protect the host from pathogens. Our data suggest that serum TNF- α levels were negatively correlated with the tryptophan, tyrosine and phenylalanine biosynthesis pathways. TNF- α is strongly modulated by microbial metabolism and degradation of tryptophan to tryptophol (37). Changes in the microbiota stimulate the immune system of the host by regulating tryptophan and other amino acid metabolism, which may be accompanied by changes in factors such as TNF- α and IL-17. The use of thalidomide plays a certain role in the regulation of the gut microbiota and immune system, contributing to the recovery of homeostasis in the host.

To reveal the key immune factors leading to functional variation of the gut microbiota in RAU, differences in Control

and T1 samples were evaluated by limma ($FDR \leq 0.05$), and these immune factors were modeled (adabag package) and iterated 100 times to obtain the prediction model with an AUC of 0.996 (Figure 8B). All metagenomic results in this study are summarized in Table S1. The correlation network of relevant factors and species is shown in Figure 8C. Given that the entire community of microbial inhabitants in the digestive tract influences immune response balance and epithelial barrier function, our results suggested that RAU could potentially be the outcome of microbiota dysbiosis due to homeostatic disturbance of host-microbe interactions.

Relapsable characterization of gut microbiota after thalidomide withdrawal

At T3 the taxonomic differences between relapsable and relapse-free individuals were calculated by edgeR ($FDR \leq 0.05$), and a total of 20 bacteria were screened out as shown in Figure 9A. According to the results, the reduction of *Mycoplasma flocculare* or *Metallosphaera sedula* is more likely to cause relapse, suggesting that these two bacteria may be probiotics to prevent relapse. The AUC value (R function roc) was calculated for each of the species, and 10 species with $AUC > 0.7$ were screened out. The prediction model with an AUC of 0.899 was obtained by 100 iterations (Figure 9B), meaning that these bacteria have about 89.9% accuracy of predicting recurrence. The correlation heatmap of relapse-associated species and blood and saliva factors between relapsable patients and relapse-free individuals is shown in Figure 9C.

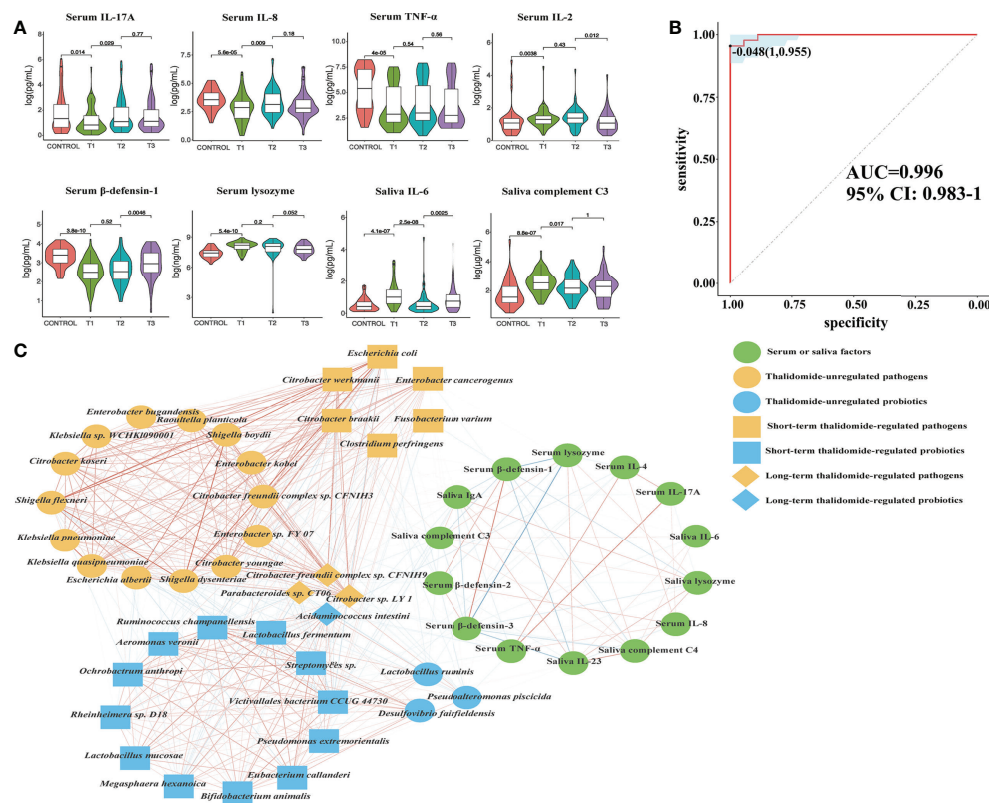


FIGURE 8

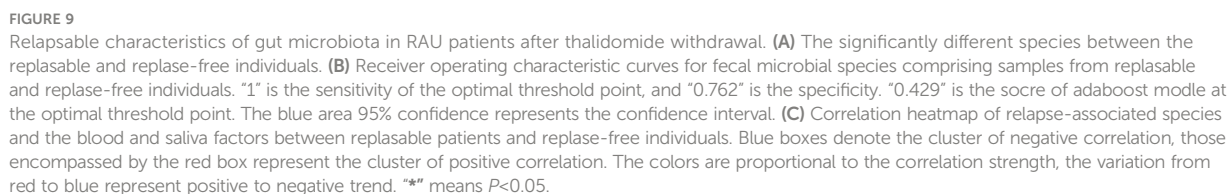
Contribution diversity of fecal microbiome cytokines. (A) Violin plot analysis comparing the levels of serum and salivary cytokines in control, T1, T2 and T3 groups ($P < 0.05$ between control and T1). (B) Receiver operating characteristic curves for fecal microbial cytokines comprising samples from RAU and healthy controls. "1" is the sensitivity of the optimal threshold point, and "0.955" is the specificity. "-0.048" is the score of adaboost model at the optimal threshold point. The blue area 95% confidence represents the confidence interval. (C) Abundance-based species-cytokines correlation network enriched in RAU patients and healthy individuals. Two nodes are linked if they are related. The edge width is proportional to the correlation strength. Nodes with the different color and shapes are classified in the different effective order level with Thalidomide.

Discussion

Evidence that the gut microbiota contributes to the development of RAU is accumulating. Thus, characterization of the gut microbiota in RAU and identification of microbial therapeutic targets are highly warranted. In this study, it was found for the first time that there were concurrent gut dysbiosis, microbial dysfunction and immune imbalance in RAU. Although there were no significant differences in the relative abundances of enteroviruses and fungi between RAU patients and healthy individuals, we found that an array of probiotics were depleted while a large number of pathogens were enriched in the gut microbiota of RAU patients. Overall, there is an imbalance between probiotics and pathogenic bacteria. Notably, some *Lactobacillus*, *Bifidobacterium*, *Streptococcus*, and *Enterococcus* species, such as *Lactobacillus ruminis*, *Bifidobacterium animalis*, *S. thermophilus* and *Enterococcus faecium*, have been used as commercial probiotic products (38).

Existing studies suggest that microbiota-driven variations in the inflammatory response regulate the host response to infection (37). A possible explanation is that the imbalance between anti-inflammatory and proinflammatory responses suppresses protective Th17 inflammation and impairs defense against pathogens. In particular, a considerable decrease in the abundance of probiotics, including *A. intestine*, and an increase in the abundance of numerous pathogens, including *B. fragilis* and *E. coli*, were noted in this study. Moreover, pathogen-associated pathways were significantly increased, such as the TCA cycle and tryptophan biosynthesis pathways.

Thalidomide treatment contributes to an increase in the abundance of some probiotics, such as *A. intestine*, and a decrease in the abundance of some pathogens, such as *B. fragilis*. This regulation can be maintained long-term, but thalidomide has no regulatory role for some pathogenic bacteria, suggesting that thalidomide may indirectly alter the gut microbiota by regulating immune factor levels of the host.



Tryptophan can be used as a biomarker to reflect the occurrence and development of diseases and can also be used to monitor the response to treatment. Tryptophan and other amino acid metabolic pathways are activated in cancers and other diseases (27). Our results indicated that these pathways were significantly enriched in RAU, suggesting an anti-inflammatory role of these pathways in RAU. Based on our results and the literature (40), the possible mechanisms are

The limitations of our study should be considered. Although in this study we investigated changes in species abundance at the metagenomic level, microbial function of the gut microbiota, and serum and saliva levels of immune factors in RAU, animal experiments are absent because there is currently a void regarding animal models exactly simulating RAU in humans. Second, we performed a metagenomic study of saliva microbial samples (data not shown), but enough high-quality metagenomic data were not available due to host exfoliated cell DNA. Therefore, technological breakthroughs in oral and salivary metagenomics are urgently needed to fulfill disease-associated metagenomic profiling.

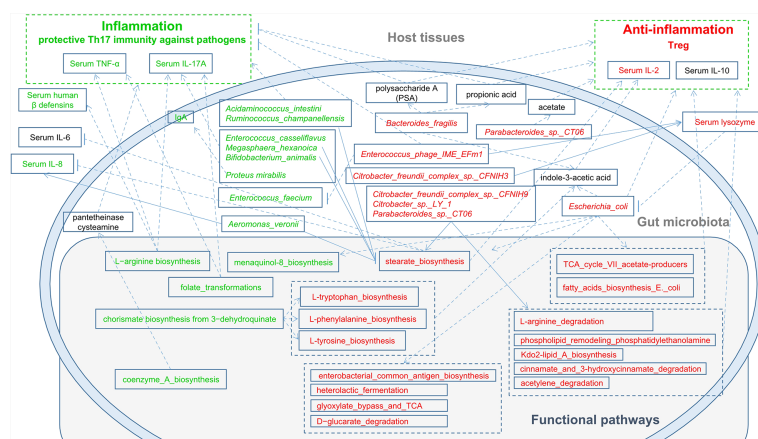


FIGURE 10

A schematic diagram showing the main functions and cytokines of the gut microbes that had a predicted RAU association. Red text denotes enriched functions, species and cytokines in RAU patients. Green text denotes depleted functions, species and cytokines in RAU patients.

Conclusion

In the present study, species-pathway-factor correlation networks facilitated improved metagenomic analysis and helped pinpoint disease- and host-associated shifts in the microbiome's functional capacity. We observed dynamic shifts in the species composition of the gut microbiota, functional pathways of signature bacteria and immune factor levels in RAU. It was noted that protective Th17 inflammation against pathogens was impaired, contributing to an immunosuppressive microenvironment and probiotic-pathogen dysbiosis. Thalidomide ameliorated gut dysbacteriosis, regulated immune imbalance, and alleviated RAU severity. Probiotics, prebiotics, synbiotics, postbiotics, and other emerging treatments may be beneficial supplements for RAU treatment. With the continuous in-depth study of RAU-related pathogenesis, it may be possible to apply precise treatment of RAU in the future. In conclusion, our findings extend our insights into the metagenome of the gut microbiota and the host in RAU and the regulatory roles of thalidomide, pointing to possible future modalities for RAU prophylaxis and treatment.

Methods

Study subjects

This study was approved by the Ethics Committee, Nanjing Stomatological Hospital, Medical School of Nanjing University [2014NL-002(KS)]. The samples and clinical information used in this study were obtained under conditions of informed consent. The diagnostic criteria of RAU patients referred to the criteria previously documented in the literature (43). According to recurrence period and frequency (44, 45), RAU

is classified as refractory type (attack at least once per month, totally more than 50% of the time with aphthous ulcers) and common type (attack once 2 or more months) based on the literature and our previous study. According to the severity, RAU is classified as minor, major and herpetiform types classically. Only the patients affected with refractory and minor RAU were included in this study. Individuals with inflammatory diseases, including BD and Crohn's disease; systematic diseases, including cardiovascular diseases, diabetes and anemia; infectious diseases; and a history of drug abuse were excluded from this study. In this study, 81 RAU patients receiving no medication consisting of antibiotics, corticosteroids or analgesics for at least 1 month along with 44 sex-, age-, and BMI-matched healthy controls were recruited according to the previous studies on gut microbiota and metagenomic analysis (46–48). Information on lifestyle, oral health status, clinical characteristics of ulcers, and blood test-related data were obtained. The participants in this study were healthy controls labeled Control and RAU patients at three points labeled T1, T2, and T3 [T1: before thalidomide administration (thalidomide 50mg nightly) (7, 49); T2: one month after thalidomide administration; T3: one month after thalidomide withdrawal].

Sample collection and processing

Serum, saliva and fecal samples were collected from participants at approximately 8 am before breakfast. Venous blood from each individual was collected to harvest serum samples. Fecal samples were collected using an OMNIgene-GUT stool/feces sampling kit (DNA Genotek, Ottawa, Canada). Unstimulated whole saliva was collected using a sampling tube

and an ORAGene-DNA saliva sampling kit (DNA Genotek, Ottawa, Canada). All samples were immediately frozen and stored at -80°C until analysis.

Biochemical assays

Serum and saliva samples for biochemical assays were analyzed by ELISA. IL-2, IL-4, IL-6, IL-8, IL-10, IL-17A, IL-23, TNF- α , IFN- γ , IgA, IgG, IgM, and IgE were analyzed using ELISA kits (MultiScience, Hangzhou, Zhejiang, China). LL-37, hBD-1, hBD-2, and hBD-3 were detected using ELISA kits (Cusabio, Houston, TX, USA). Lysozyme, complement-3, and complement-4 were measured using ELISA kits (Abcam, Cambridge, MA, USA). ELISA was performed according to the manufacturers' instructions.

Metagenomic sequencing

Paired-end metagenomic sequencing was performed on the Illumina HiSeq 4000 platform (BGI-genomics, China) with an insert size of 350 bp and paired-end (PE) reads of 150 bp for each sample. After removing adaptors and low quality (quality ≤ 20) and ambiguous bases from the raw reads, the remaining reads were aligned to human genome reference (hg19) by SOAPaligner (v2.22, parameters: -m 280 -x 420 -r 1 -l 32 -s 75 -c 0.9) to remove human host DNA contamination.

Microbiome characterization

All metagenomic sequencing data were processed using the same extensive processing pipeline: bacterial, archaeal, viral, and microeukaryote abundances were determined using Kraken2 (50) and corrected by Bracken (51). A cladogram was produced by GraPhlAn (52). Microbial pathways and abundances were determined using HUMAnN3 (53) (nucleotide-database: chocophlan; protein-database: uniref90) software.

Statistical analyses

To compare the collected phenotypes of the disease cohort with the population controls, categorical data were tested using edgeR (54) (calcNormFactors: trimmed mean of M-values method). The statistical analysis for differentially expressed (DE) was done using edgeR (glmLRT test). Pathways or species with $\text{FDR} \leq 0.05$ were set as cutoff values to be considered differentially expressed. ANOVA (Tukey-HSD) test was used to assess differences in taxonomic and functional diversity.

To test for differentially distributed pathways across genotypes, data obtained with HUMAnN3 (pathway

composition) were fitted into limma's model (55) using subjects as blocking variables. Since both software programs quantify biological units using relative counts (HUMAnN2 uses "copies per million"), we transformed these data into logarithmic values using the formula $\log_2(x + 0.1)$, where x is the relative counts. The obtained P values were corrected using the Benjamini-Hochberg correction method.

The Spearman coefficient was used to evaluate the correlation between phenotypes and the correlation between microbiome features. Correlations with corresponding empirical P values less than 0.05 were retained. Correlation coefficients with magnitudes of 0.3 or greater were selected for visualization in Cytoscape.

The AUC value of one hundred ninety statistically significantly differentially abundant species (edgeR-TMM, $\text{FDR} \leq 0.05$) between CONTROL vs. T1 calculated by the ROCR package, and thirty-eight species with $\text{AUC} > 0.7$ were discriminated cases (T1 phenotype) from controls with an AUC value according to the adabag package (56) (boosting, $\text{mfinal} = 100$). All relevant pathways, factors, and species were screened based on Spearman's correlation coefficient. Correlation coefficients with magnitudes of 0.2 or greater were selected for visualization in Cytoscape (v. 3.8.2). For model training, the adabag (R package) was used to create an adaboost model. Half of the samples were randomly selected as the training set and the other half as the test set. About the parameter set of training, we defined 1000 trees for fitting, and set parameter shrinkage = 0.01 and cv. folds = 5.

Data availability statement

The datasets presented in this study can be found in online repositories. Sequences generated from this study are deposited in the China National GeneBank (CNCB) at <https://db.cngb.org/cnsga/> (accession number: CNP0001744).

Ethics statement

The studies involving human participants were reviewed and approved by Nanjing Stomatological Hospital, Medical School of Nanjing University [2014NL-002(KS)]. The patients/participants provided their written informed consent to participate in this study.

Author contributions

XW, KX, FH, JH, QL, and WW had full access to all data and take responsibility for the integrity of the data and accuracy of data analysis. The study concept and design were provided by XW, QH, FY and WW. Acquisition, analysis or interpretation of data was carried out by all authors. Drafting of the manuscript was performed by QL and FH. All authors critically revised the

manuscript for important intellectual content. Statistical analysis was carried out by KX and JH. Funding was obtained by XW, QH, FY, WW. Administrative, technical or material support was provided by XW, JH and WW. The study was supervised by QH, FY and WW. All authors contributed to the article and approved the submitted version.

Funding

This work was supported by the National Natural Scientific Foundation of China (81870767 & 81570978), the Key Project of Science and Technology Department of Jiangsu Province (BL2014018), the Project of Jiangsu Provincial Medical Youth Talent (QNRC2016118), and the Nanjing Clinical Research Center for Oral Diseases (2019060009).

Acknowledgments

We would thank BGI-genomics (Shenzhen, China) for technical assistance and bioinformatics analysis.

References

- Tohidinik HR, Rodriguez A, Regueira-Mendez C, Takkouche B. Sleep quality and risk of recurrent aphthous ulcers: A Spanish cohort study. *Oral Dis* (2021) 28 (7):1882–90. doi: 10.1111/odi.13955
- Akintoye SO, Greenberg MS. Recurrent aphthous stomatitis. *Dental Clinics North America* (2014) 58(2):281–97. doi: 10.1016/j.cden.2013.12.002
- Kim J, Lee HK. Potential role of the gut microbiome in colorectal cancer progression. *Front Immunol* (2021) 12:807648. doi: 10.3389/fimmu.2021.807648
- Priyadarshini M, Navarro G, Reiman DJ, Sharma A, Xu K, Lednovich K, et al. Gestational insulin resistance is mediated by the gut microbiome-indoleamine 2,3-dioxygenase axis. *Gastroenterology* (2022) 162(6):1675–89. doi: 10.1053/j.gastro.2022.01.008
- Ye Z, Zhang N, Wu C, Zhang X, Wang Q, Huang X, et al. A metagenomic study of the gut microbiome in behcet's disease. *Microbiome* (2018) 6(1):135. doi: 10.1186/s40168-018-0520-6
- Lin D, Yang L, Wen L, Lu H, Chen Q, Wang Z. Crosstalk between the oral microbiota, mucosal immunity, and the epithelial barrier regulates oral mucosal disease pathogenesis. *Mucosal Immunol* (2021) 14(6):1247–58. doi: 10.1038/s41385-021-00413-7
- Deng Y, Wei W, Wang Y, Pan L, Du G, Yao H, et al. A randomized controlled clinical trial on dose optimization of thalidomide in maintenance treatment for recurrent aphthous stomatitis. *J Oral Pathol Med* (2022) 51(1):106–12. doi: 10.1111/jop.13259
- Wang X, Shen Y, Li S, Lv M, Zhang X, Yang J, et al. Importance of the interaction between immune cells and tumor vasculature mediated by thalidomide in cancer treatment (Review). *Int J Mol Med* (2016) 38(4):1021–9. doi: 10.3892/ijmm.2016.2724
- Hijazi K, Lowe T, Meharg C, Berry SH, Foley J, Hold GL. Mucosal microbiota in patients with recurrent aphthous stomatitis. *J Dental Res* (2015) 94(3 Suppl):87s–94s. doi: 10.1177/0022034514565458
- Kim YJ, Choi YS, Baek KJ, Yoon SH, Park HK, Choi Y. Mucosal and salivary microbiota associated with recurrent aphthous stomatitis. *BMC Microbiol* (2016) 16 Suppl 1:57. doi: 10.1186/s12866-016-0673-z
- Yang Z, Cui Q, An R, Wang J, Song X, Shen Y, et al. Comparison of microbiomes in ulcerative and normal mucosa of recurrent aphthous stomatitis (Ras)-affected patients. *BMC Oral Health* (2020) 20(1):128. doi: 10.1186/s12903-020-01115-5
- Gu W, Deng X, Lee M, Sucu YD, Arevalo S, Stryke D, et al. Rapid pathogen detection by metagenomic next-generation sequencing of infected body fluids. *Nat Med* (2021) 27(1):115–24. doi: 10.1038/s41591-020-1105-z
- D'Auria G, Galan JC, Rodriguez-Alcayna M, Moya A, Baquero F, Latorre A. Complete genome sequence of acidaminococcus intestini ryc-Mr95, a gram-negative bacterium from the phylum firmicutes. *J Bacteriol* (2011) 193(24):7008–9. doi: 10.1128/JB.06301-11
- Zhang X, Wang Y, Li S, An X, Pei G, Huang Y, et al. A novel termini analysis theory using hts data alone for the identification of enterococcus phage Ef4-like genome termini. *BMC Genomics* (2015) 16(1):414. doi: 10.1186/s12864-015-1612-3
- Ramakrishna C, Kujawski M, Chu H, Li L, Mazmanian SK, Cantin EM. Bacteroides fragilis polysaccharide a induces il-10 secreting b and T cells that prevent viral encephalitis. *Nat Commun* (2019) 10(1):2153. doi: 10.1038/s41467-019-09884-6
- Round JL, Lee SM, Li J, Tran G, Jabri B, Chatila TA, et al. The toll-like receptor 2 pathway establishes colonization by a commensal of the human microbiota. *Sci (New York NY)* (2011) 332(6032):974–7. doi: 10.1126/science.1206095
- Lei Y, Tang L, Liu S, Hu S, Wu L, Liu Y, et al. Parabacteroides produces acetate to alleviate heparanase-exacerbated acute pancreatitis through reducing neutrophil infiltration. *Microbiome* (2021) 9(1):115. doi: 10.1186/s40168-021-01065-2
- Su X, Yin X, Liu Y, Yan X, Zhang S, Wang X, et al. Gut dysbiosis contributes to the imbalance of treg and Th17 cells in graves' disease patients by propionic acid. *J Clin Endocrinol Metab* (2020) 105(11):3526–47. doi: 10.1210/clinem/dgaa511
- Schirmer M, Garner A, Vlamakis H, Xavier RJ. Microbial genes and pathways in inflammatory bowel disease. *Nat Rev Microbiol* (2019) 17(8):497–511. doi: 10.1038/s41579-019-0213-6
- Li Q, Liu Y, Che Z, Zhu H, Meng G, Hou Y, et al. Dietary l-arginine supplementation alleviates liver injury caused by escherichia coli lps in weaned pigs. *Innate Immun* (2012) 18(6):804–14. doi: 10.1177/1753425912441955
- Ren W, Chen S, Yin J, Duan J, Li T, Liu G, et al. Dietary arginine supplementation of mice alters the microbial population and activates intestinal innate immunity. *J Nutr* (2014) 144(6):988–95. doi: 10.3945/jn.114.192120
- Wu L, Liao P, He L, Feng Z, Ren W, Yin J, et al. Dietary l-arginine supplementation protects weanling pigs from deoxynivalenol-induced toxicity. *Toxins* (2015) 7(4):1341–54. doi: 10.3390/toxins7041341

Conflict of interest

The authors declare that the research was conducted in the absence of any commercial or financial relationships that could be construed as a potential conflict of interest.

Publisher's note

All claims expressed in this article are solely those of the authors and do not necessarily represent those of their affiliated organizations, or those of the publisher, the editors and the reviewers. Any product that may be evaluated in this article, or claim that may be made by its manufacturer, is not guaranteed or endorsed by the publisher.

Supplementary material

The Supplementary Material for this article can be found online at: <https://www.frontiersin.org/articles/10.3389/fimmu.2022.1018567/full#supplementary-material>

23. Ding Z, Sun C, Yi SM, Gennis RB, Dikanov SA. The ubiquinol binding site of cytochrome Bo(3) from *Escherichia coli* accommodates menaquinone and stabilizes a functional menaquinone. *Biochemistry* (2019) 58(45):4559–69. doi: 10.1021/acs.biochem.9b00750
24. Fox KJ, Prather KLJ. Production of D-glyceric acid from D-galacturonate in *Escherichia coli*. *J Ind Microbiol Biotechnol* (2020) 47(12):1075–81. doi: 10.1007/s10295-020-02323-2
25. Bongaerts GP, Severijnen RS. Preventive and curative effects of probiotics in atopic patients. *Med Hypotheses* (2005) 64(6):1089–92. doi: 10.1016/j.mehy.2004.10.018
26. Minliang C, Chengwei M, Lin C, Zeng AP. Integrated laboratory evolution and rational engineering of Galp/Glk-dependent *Escherichia coli* for higher yield and productivity of L-tryptophan biosynthesis. *Metab Eng Commun* (2021) 12:e00167. doi: 10.1016/j.mec.2021.e00167
27. Chen JL, Fan J, Yan LS, Guo HQ, Xiong JJ, Ren Y, et al. Urine metabolite profiling of human colorectal cancer by capillary electrophoresis mass spectrometry based on mrb. *Gastroenterol Res Pract* (2012) 2012:125890. doi: 10.1155/2012/125890
28. De Sanctis JB, Mijares M, Suárez A, Compagnone R, Garmendia J, Moreno D, et al. Pharmacological properties of thalidomide and its analogues. *Recent Pat Inflammation Allergy Drug Discovery* (2010) 4(2):144–8. doi: 10.2174/187221310791163026
29. Blander JM, Longman RS, Iliev ID, Sonnenberg GF, Artis D. Regulation of inflammation by microbiota interactions with the host. *Nat Immunol* (2017) 18(8):851–60. doi: 10.1038/ni.3780
30. Soderholm AT, Pedicord VA. Intestinal epithelial cells: At the interface of the microbiota and mucosal immunity. *Immunology* (2019) 158(4):267–80. doi: 10.1111/imm.13117
31. Verma D, Garg PK, Dubey AK. Insights into the human oral microbiome. *Arch Microbiol* (2018) 200(4):525–40. doi: 10.1007/s00203-018-1505-3
32. Baek K, Choi Y. The microbiology of oral lichen planus: Is microbial infection the cause of oral lichen planus? *Mol Oral Microbiol* (2018) 33(1):22–8. doi: 10.1111/omi.12197
33. Pellon A, Sadeghi Nasab SD, Moyes DL. New insights in candida albicans innate immunity at the mucosa: Toxins, epithelium, metabolism, and beyond. *Front Cell Infect Microbiol* (2020) 10:81. doi: 10.3389/fcimb.2020.00081
34. Pandiyan P, Conti HR, Zheng L, Peterson AC, Mathern DR, Hernández-Santos N, et al. Cd4(+)Cd25(+)Foxp3(+) regulatory T cells promote Th17 cells in vitro and enhance host resistance in mouse candida albicans Th17 cell infection model. *Immunity* (2011) 34(3):422–34. doi: 10.1016/j.immuni.2011.03.002
35. Allaire JM, Crowley SM, Law HT, Chang SY, Ko HJ, Vallance BA. The intestinal epithelium: Central coordinator of mucosal immunity: (Trends in immunology 39, 677–696, 2018). *Trends Immunol* (2019) 40(2):174. doi: 10.1016/j.it.2018.12.008
36. Natah SS, Häyrynen-Immonen R, Hietanen J, Patinen P, Malmström M, Savilahti E, et al. Increased density of lymphocytes bearing Gamma/Delta T-cell receptors in recurrent aphthous ulceration (Rau). *Int J Oral Maxillofac Surg* (2000) 29(5):375–80. doi: 10.1016/S0901-5027(00)80057-0
37. Schirmer M, Smeekens SP, Vlamakis H, Jaeger M, Oosting M, Franzosa EA, et al. Linking the human gut microbiome to inflammatory cytokine production capacity. *Cell* (2016) 167(4):1125–36.e8. doi: 10.1016/j.cell.2016.10.020
38. Wang Y, Liang Q, Lu B, Shen H, Liu S, Shi Y, et al. Whole-genome analysis of probiotic product isolates reveals the presence of genes related to antimicrobial resistance, virulence factors, and toxic metabolites, posing potential health risks. *BMC Genomics* (2021) 22(1):210. doi: 10.1186/s12864-021-07539-9
39. Li C, Niu Z, Zou M, Liu S, Wang M, Gu X, et al. Probiotics, prebiotics, and synbiotics regulate the intestinal microbiota differentially and restore the relative abundance of specific gut microorganisms. *J Dairy Sci* (2020) 103(7):5816–29. doi: 10.3168/jds.2019-18003
40. Glick M. Burket's oral medicine. *Shelton: People's Med Publ* (2015) 73–6.
41. Ma X, Wang X, Zheng G, Tan G, Zhou F, Wei W, et al. Critical role of gut microbiota and epigenetic factors in the pathogenesis of Behçet's disease. *Front Cell Dev Biol* (2021) 9:719235. doi: 10.3389/fcell.2021.719235
42. Kamada N, Seo SU, Chen GY, Núñez G. Role of the gut microbiota in immunity and inflammatory disease. *Nat Rev Immunol* (2013) 13(5):321–35. doi: 10.1038/nri3430
43. Wang Y, Hui Z, Ji Z, Wei M, Zhang H, Wang Y, et al. Clinical characteristics and risk factors of major oral ulcers in the mandibular retromolar region in children. *Clin Oral Investig* (2021) 25(6):3505–12. doi: 10.1007/s00784-020-03672-z
44. Baccaglini L, Lalla RV, Bruce AJ, Sartori-Valinotti JC, Latortue MC, Carrozzo M, et al. Urban legends: Recurrent aphthous stomatitis. *Oral Dis* (2011) 17(8):755–70. doi: 10.1111/j.1601-0825.2011.01840.x
45. Ruan H, Wang W, Wang X, Duan N, Jiang H, Bai Y, et al. Effects of prednisone on clinical outcome and immune parameters in the treatment of refractory recurrent aphthous ulcer. *J Oral Sci Res* (2017) 33(1):47–50. doi: 10.13701/j.cnki.kqxyj.2017.01.011
46. Kong C, Liang L, Liu G, Du L, Yang Y, Liu J, et al. Integrated metagenomic and metabolomic analysis reveals distinct gut-Microbiome-Derived phenotypes in early-onset colorectal cancer. *Gut* (2022):gutjnl-2022-327156. doi: 10.1136/gutjnl-2022-327156
47. Ma X, Ma L, Wang Z, Liu Y, Long L, Ma X, et al. Clinical features and gut microbial alterations in anti-Leucine-Rich glioma-inactivated 1 encephalitis-a pilot study. *Front Neurol* (2020) 11:585977. doi: 10.3389/fneur.2020.585977
48. Xiao S, Zhang G, Jiang C, Liu X, Wang X, Li Y, et al. Deciphering gut microbiota dysbiosis and corresponding genetic and metabolic dysregulation in psoriasis patients using metagenomics sequencing. *Front Cell Infect Microbiol* (2021) 11:605825. doi: 10.3389/fcimb.2021.605825
49. Franks ME, Macpherson GR, Figg WD. Thalidomide. *Lancet (London England)* (2004) 363(9423):1802–11. doi: 10.1016/s0140-6736(04)16308-3
50. Wood DE, Lu J, Langmead B. Improved metagenomic analysis with kraken 2. *Genome Biol* (2019) 20(1):257. doi: 10.1186/s13059-019-1891-0
51. Lu J, Breitwieser FP, Thielen P, Salzberg SL, Bracken: Estimating species abundance in metagenomics data. *PeerJ Comput Sci* (2017) 3:e104. doi: 10.1101/051813
52. Asnicar F, Weingart G, Tickle TL, Huttenhower C, Segata N. Compact graphical representation of phylogenetic data and metadata with graphlan. *PeerJ* (2015) 3:e1029. doi: 10.7717/peerj.1029
53. Franzosa EA, McIver LJ, Rahnvard G, Thompson LR, Schirmer M, Weingart G, et al. Species-level functional profiling of metagenomes and metatranscriptomes. *Nat Methods* (2018) 15(11):962–8. doi: 10.1038/s41592-018-0176-y
54. Pereira MB, Wallroth M, Jonsson V, Kristiansson E. Comparison of normalization methods for the analysis of metagenomic gene abundance data. *BMC Genomics* (2018) 19(1):274. doi: 10.1186/s12864-018-4637-6
55. Sharon G, Cruz NJ, Kang DW, Gandal MJ, Wang B, Kim YM, et al. Human gut microbiota from autism spectrum disorder promote behavioral symptoms in mice. *Cell* (2019) 177(6):1600–18.e17. doi: 10.1016/j.cell.2019.05.004
56. Alfaro E, Garcia M, Garcia N. Adabag: An R package for classification with boosting and bagging. *J Stat Softw* (2013) 54(2):1–35. doi: 10.18637/jss.v054.i02



OPEN ACCESS

EDITED BY

Dunfang Zhang,
Sichuan University, China

REVIEWED BY

Liliana Patino Molano,
National Institute of Dental and
Craniofacial Research (NIH),
United States
Jiajia Han,
Chinese Academy of Medical Sciences
and Peking Union Medical College,
China

*CORRESPONDENCE

Mónica Cáceres
monicacaceres@med.uchile.cl

SPECIALTY SECTION

This article was submitted to
Mucosal Immunity,
a section of the journal
Frontiers in Immunology

RECEIVED 14 September 2022

ACCEPTED 05 October 2022

PUBLISHED 20 October 2022

CITATION

Villalobos V, Garrido M, Reyes A,
Fernández C, Díaz C, Torres VA,
González PA and Cáceres M (2022)
Aging envisage imbalance of the
periodontium: A keystone in oral
disease and systemic health.
Front. Immunol. 13:1044334.
doi: 10.3389/fimmu.2022.1044334

COPYRIGHT

© 2022 Villalobos, Garrido, Reyes,
Fernández, Díaz, Torres, González and
Cáceres. This is an open-access article
distributed under the terms of the
[Creative Commons Attribution License](#)
(CC BY). The use, distribution or
reproduction in other forums is
permitted, provided the original
author(s) and the copyright owner(s)
are credited and that the original
publication in this journal is cited, in
accordance with accepted academic
practice. No use, distribution or
reproduction is permitted which does
not comply with these terms.

Aging envisage imbalance of the periodontium: A keystone in oral disease and systemic health

Verónica Villalobos^{1,2}, Mauricio Garrido^{1,3}, Antonia Reyes^{1,4},
Christian Fernández^{1,2}, Catalina Díaz^{1,2}, Vicente A. Torres^{1,5,6},
Pablo A. González^{1,4} and Mónica Cáceres^{1,2,7*}

¹Millennium Institute on Immunology and Immunotherapy, Santiago, Chile, ²Program of Cellular and Molecular Biology, Institute of Biomedical Sciences, Faculty of Medicine, Universidad de Chile, Santiago, Chile, ³Department of Conservative Dentistry, Faculty of Dentistry, Universidad de Chile, Santiago, Chile, ⁴Departamento de Genética Molecular y Microbiología, Facultad de Ciencias Biológicas, Pontificia Universidad Católica de Chile, Santiago, Chile, ⁵Institute for Research in Dental Sciences, Faculty of Dentistry, Universidad de Chile, Santiago, Chile, ⁶Advanced Center for Chronic Diseases (ACCDIS), Universidad de Chile, Santiago, Chile, ⁷Millennium Nucleus of Ion Channels-Associated Diseases (MiNICAD), Universidad de Chile, Santiago, Chile

Aging is a gradual and progressive deterioration of integrity across multiple organ systems that negatively affects gingival wound healing. The cellular responses associated with wound healing, such as collagen synthesis, cell migration, proliferation, and collagen contraction, have been shown to be lower in gingival fibroblasts (the most abundant cells from the connective gingival tissue) in aged donors than young donors. Cellular senescence is one of the hallmarks of aging, which is characterized by the acquisition of a senescence-associated secretory phenotype that is characterized by the release of pro-inflammatory cytokines, chemokines, growth factors, and proteases which have been implicated in the recruitment of immune cells such as neutrophils, T cells and monocytes. Moreover, during aging, macrophages show altered acquisition of functional phenotypes in response to the tissue microenvironment. Thus, inflammatory and resolution macrophage-mediated processes are impaired, impacting the progression of periodontal disease. Interestingly, salivary antimicrobial peptides, such as histatins, which are involved in various functions, such as antifungal, bactericidal, enamel-protecting, angiogenesis, and re-epithelization, have been shown to fluctuate with aging. Several studies have associated the presence of *Porphyromonas gingivalis*, a key pathogen related to periodontitis and apical periodontitis, with the progression of Alzheimer's disease, as well as gut, esophageal, and gastric cancers. Moreover, herpes simplex virus types 1 and 2 have been associated with the severity of periodontal disease, cardiovascular complications, and nervous system-related pathologies. This review encompasses the effects of aging on periodontal tissues, how *P. gingivalis* and HSV infections could favor periodontitis and their relationship with other pathologies.

KEYWORDS

aging, gingival fibroblast, macrophage, histatin, herpes simplex virus, *Porphyromonas gingivalis*

Periodontium and aging

Periodontium is a tissue that supports the teeth and protects against oral pathogens. Anatomical and functional changes in periodontal tissues have been associated with aging, including thinning of the epithelium and diminished keratinization, whereas cementum increases in width. Consequently, periodontal health decreases with aging (1).

Aging is a biological process characterized by decreased cell function that negatively affects gingival wound healing (2). Different cellular responses associated with wound healing, such as cell migration, proliferation, and collagen contraction, have been found to be lower in gingival fibroblasts (GF) derived from aged donors than in those derived from young donors (2). Accordingly, collagen production decreases by more than five-fold depending on the age of the donor (3), while old GF show increased rates of collagen phagocytosis and augmented DNA methylation in the collagen alpha-1 gene, which is followed by a reduction in mRNA levels and collagen type I synthesis (3). Interestingly, TGF- β 1 stimulation increased the α -SMA levels in both young and old fibroblasts. However, α -SMA is incorporated in actin stress fibers in young fibroblasts but not in old fibroblasts (2) (Figure 1). One of the proteins that increase its expression during aging in human GF is TMPRSS11a (4), a

type II serine protease that induces cellular senescence, a process characterized by stable cell cycle arrest, macromolecular damage induced by cellular impairment, such as DNA damage (4), telomere shortening or dysfunction, epigenetic changes, oncogene activation or loss of tumor suppressor functions, and organelle damage and with the acquisition of a senescence-associated secretory phenotype (SASP) (5). The SASP is characterized by the release of components that directly or indirectly promote inflammation such as pro-inflammatory cytokines, chemokines, growth factors, and proteases (5). This phenotype has been implicated in the recruitment of immune cells (Figure 2), impacting the local oral mucosal microenvironment and affecting cellular function in neighboring cells (6).

A study from our group showed that the exposure of young GF to blood serum from middle-aged (30–48 years old) and aged individuals (over 50 years old) increased cellular senescence. Specifically, that study showed that blood serum samples obtained from middle-aged and aged individuals were characterized by an increase in MCP-1 (CCL2) and TNF α levels compared to those in young individuals (6). Interestingly, one longitudinal study quantified physiological deterioration across multiple organ systems with chronological aging, using a 38-year-old, showing that gum health (combined

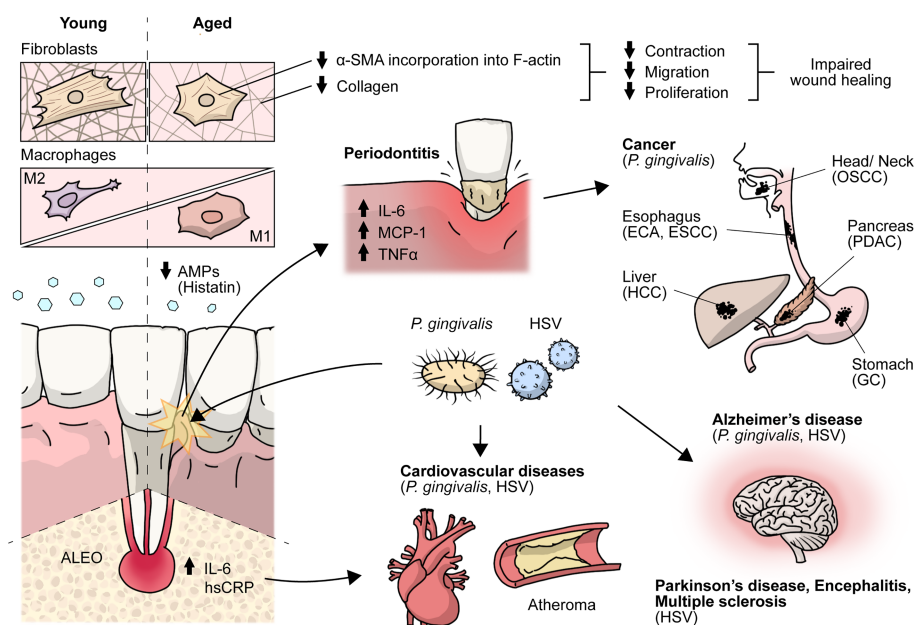


FIGURE 1

Effects of aging on the periodontium and antimicrobial peptides. Crosstalk between HSV and *P. gingivalis* with cancer, encephalitis, multiple sclerosis, cardiovascular, Parkinson's, Alzheimer's and periodontal diseases. During aging there is an impaired gingival wound healing. Aged gingival fibroblasts show decreased cell migration, proliferation and contraction, and lower α -SMA is incorporated into actin stress fibers and aged macrophages show altered acquisition of functional phenotypes, HSV and *P. gingivalis* have been associated with periodontal, cardiovascular and Alzheimer's diseases. AMPs, antimicrobial peptides; ALEO, apical lesions of endodontic origin; hsCRP, high-sensitive C-reactive protein; α -SMA, alpha-smooth muscle actin; OSCC, oral squamous cell carcinoma; ESCC, esophageal squamous cell carcinoma; PDAC, pancreatic ductal adenocarcinoma; HCC, hepatocellular carcinoma; GC, gastric cancer.

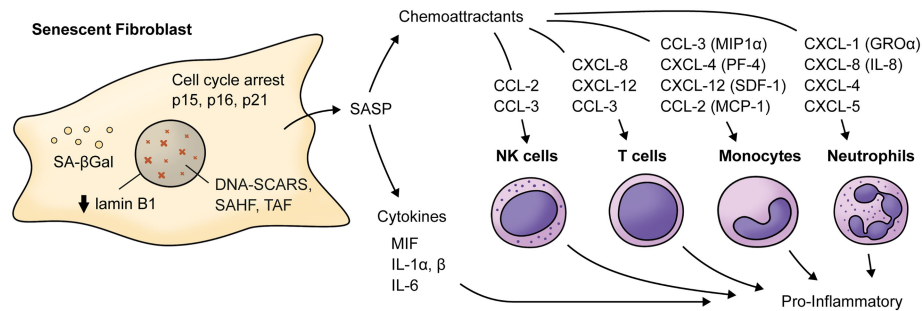


FIGURE 2

Main cytokines and chemokines elevated in the Senescence-Associated Secretory Phenotype by senescent fibroblasts. Senescent fibroblasts are characterized by cell-cycle arrest mainly related to increased levels of cyclin-dependent kinases inhibitors (p15^{INK4b}, p16^{INK4a}, p21^{CIP1}), decreased levels of lamin B1 and the presence of a SASP characterized by increased levels of cytokines and chemokine such as IL-6, MIF, IL-1α and β which acts as pro-inflammatory cytokines. For example, chemokines such as CXCL-1, CXCL-8, CXCL-5, and CXCL-4 can be chemoattractants for neutrophils. CCL-3, CCL-4, CXCL-12, and CCL-2 can be chemoattractants for monocytes, and IL-8, CXCL-12, and CCL-3 can act as a chemoattractant for T cells. Notably, CCL-2 and CCL-3 can also attract NK cells. MIF, macrophage migration inhibitory factor; MIP1α, macrophage inflammatory protein 1-alpha; MCP-1, monocyte chemoattractant protein 1; CXCL-5, C-X-C motif chemokine 5; PF-4, platelet factor 4; SDF-1, stromal cell-derived factor 1; SAHF, Senescence-associated heterochromatin foci; TAF, Telomere-associated DDR foci; DNA-SCARS, DNA segments with chromatin alterations reinforcing senescence. SA-βGal, Senescence-associated beta galactosidase; GROα, growth-regulated alpha protein.

with attachment loss) has a Z score similar to other biomarkers of aging, such as HDL cholesterol and telomeric length in leukocytes (7). Interestingly, the authors used the age of 38-year-old because individuals who were aging more rapidly were less physically able, showed cognitive decline and brain aging and looked older, so they can identify causes of aging and evaluate rejuvenation therapies.

During aging, there is a loss of periodontal attachment and alveolar bone, but these changes do not have a major clinical impact. However, in aged individuals, there is an increased pro-inflammatory state that induces increased susceptibility to autoimmune, inflammatory, or infectious diseases, including periodontitis (8). Furthermore, in the gingival tissues of aged subjects, differences associated with the innate immune system, such as higher neutrophil infiltration in gingiva from old mice (18 months old) compared to young mice, where the reduced expression of Del-1 in the gingiva of old mice was associated with higher neutrophil infiltration relative to young mice (9). The innate immune system plays a critical role in maintaining a symbiotic relationship with the oral microbiome, were observed (1). Thus, alterations in host oral mucosal immunity arise during aging that giving way to the establishment of oral dysbiosis that allows tissue colonization by bacteria such as *Porphyromonas gingivalis* (*P. gingivalis*) (1), which increases susceptibility to the development of periodontitis or latent viral infections.

Antimicrobial peptides

Antimicrobial peptides (AMPs) are central players in innate immunity, which depict additional activities beyond their

canonical antimicrobial roles, thereby contributing to maintaining tissue homeostasis (10). Within the group of salivary AMPs, histatins stand out, as their concentrations fluctuate in early and middle ages and further decrease in the elderly (11) (Figure 1). Histatins are histidine-rich proteins that elicit a variety of functions, including antifungal, bactericidal, and enamel-protective activities (12). From this family of proteins, histatin-1 and histatin-2 have been extensively studied, as they have been found to maintain oral mucosal homeostasis and promote wound healing by stimulating both tissue re-epithelialization (13) and angiogenesis (14). Particularly, histatin-1 was identified as a potent pro-angiogenic factor that stimulates endothelial cell adhesion and migration, as well as vascular morphogenesis *in vitro* and *in vivo* (14), which are thought to contribute to the high efficiency of epithelial repair in the oral cavity. In addition to its effects on wound healing, histatin-1 was also reported to contribute to maintaining periodontal tissue homeostasis, because it restores cell migration in periodontal ligament fibroblasts challenged with nicotine (14). In support of the notion that histatin-1 contributes to oral fibroblast function, this peptide induced myofibroblast differentiation and migration in a non-oral model, thereby contributing to skin wound healing (15).

The spectrum of cell types that respond to histatin-1 has broadened in recent years, as this peptide was shown to induce osteogenic differentiation and stimulate mineralization in pre-osteoblasts and mesenchymal cells derived from the dental pulp and apical papilla (16). Collectively, these findings open new avenues to explore the physiological relevance of the effects of histatin-1 in different cell types residing within the oral cavity. In addition, this scenario provides an interesting opportunity to

explore new therapeutic possibilities using this peptide as a co-adjuvant in regenerative therapies. This is relevant in the context of the reported variations in this and other histatins during aging (11).

Periodontal disease

Periodontitis is known to increase in both incidence and severity across a large proportion of the human population with aging (1) and has been associated with other age-related diseases, such as cancer, Alzheimer's disease (AD), and atherosclerosis (17–19). The etiology of periodontal disease has been commonly associated with bacterial infection solely. However, it has been reported that a severe disease also occurs in the absence of a large bacterial load, indicating an excessive immune response of the host inflammatory cytokine-mediated to subgingival pathogens, where IL-1 α plays a major role in periodontal damage (20). Alterations in the components of the periodontium that disrupt its barrier functions can lead to an increase in opportunistic pathogens, causing the development of diseases at both local and systemic levels. It is important to note that the oral microbiome can comprise bacteria, protozoans, fungi, numerous viruses, and archaea; in this review, we focus on discussing *P. gingivalis* and herpes simplex virus type 1 and 2 (HSV-1 and HSV-2, respectively).

P. gingivalis in supportive periodontal tissue diseases and systemic implications

P. gingivalis is a gram-negative anaerobic bacillus part of a cluster of oral microorganisms consistently found in severe forms of periodontal disease, classically described as “red complex”: *P. gingivalis*, *Tannerella Forsythia*, and *Treponema denticola* (17). *P. gingivalis* plays a central role in the etiology and progression of periodontal disease because of the wide range of virulence factors that are associated with the induction of a pro-inflammatory environment in the oral mucosa, leading to the destruction of periodontal tissue, diminishing its barrier function and immunological homeostasis, and hence responses against noxa (8). Inflammation favors the growth of the dysbiotic microbial community. Nevertheless, its disruptive effects on oral mucosal immunity transcend the inflammatory balance, as it also plays a role in mucosal senescence induction (21). Direct cellular invasion by this bacterium has been shown to induce immune senescence in dendritic cells, and paracrine signals amplify senescence through the secretion of inflammatory exosomes (21).

In addition, *P. gingivalis* can translocate from the oral cavity to the bloodstream and colonize distant organs, invading and

surviving within dendritic cells and monocytes/macrophages (19, 21). In this context, *P. gingivalis* was shown to play a pathogenic role in systemic diseases, such as vascular atheroma, where it is located in atherosclerotic plaques (18). In addition, periodontal disease has been associated with an increased risk of cancers (Figure 1), such as pancreatic cancer, via a mechanism that relies on *P. gingivalis*, as it was found in pancreatic cancer cells and has been shown to exert direct pro-tumoral effects on enhanced pancreatic tumor cell proliferation through its ability to survive intracellularly (22). However, the conclusive mechanism of invasion in atheroma plaques and pancreatic adenocarcinoma is not completely understood.

Although *P. gingivalis* has been associated with local inflammation and oral cancer risk, recent evidence suggests that the consequences of oral mucosal imbalance might extend beyond local malignancies. Oral dysbiosis has been shown to increase the risk of oral squamous cell carcinoma (OSCC), and bacterial communities displaying enrichment of genes associated with cell motility and pro-inflammatory processes, such as bacterial chemotaxis and flagella assembly, are significantly increased in OSCC patients (23). *P. gingivalis* is also associated with other gut cancers, such as esophageal cancer, gastric cancer, and hepatocarcinoma (17).

In contrast, *P. gingivalis*-derived gingipains and LPS, as well as their DNA, have been found in the brains of individuals with AD, suggesting transneuronal dissemination of this bacterium from the oral cavity (19). Interestingly, *P. gingivalis* is also present in individuals with AD but without established dementia, suggesting that brain infections are an early event that plays a role in AD pathogenesis (19) (Figure 1). Mechanisms underlying neurodegeneration are related to inflammation mediated by *P. gingivalis* virulence factors, including LPS, gingipains, cathepsin B, and tau, among others (24), which lead to the accumulation and production of the amyloid plaque component A β in the brain and tau-related pathology, as a result of gingipain proteolysis (19), although clinical studies correlating these data are still incipient.

Another prevalent oral disease worldwide that affects periapical supportive tissues and may cause loss of the affected tooth is apical periodontitis (25). It usually presents as an asymptomatic disease that is radiographically detected as an osteolytic area. The etiological factor is a predominantly anaerobic biofilm that triggers an immune-inflammatory response by the host (26), where macrophages play an important role in the hallmark of apical lesions of endodontic origin (ALEOs), such as root resorption. There is evidence that these ALEOs depict a high percentage of extraradicular infections, specifically *P. gingivalis* and *Porphyromonas endodontalis*, thus challenging the notion that microorganisms are confined only to the root canal system (27). Furthermore, bacterial DNA has been detected at significantly higher levels in peripheral blood mononuclear cells taken from individuals with apical periodontitis than in healthy controls, suggesting that

there might be bacterial DNA translocation from the ALEO onto the systemic circulation, reaching other tissues, such as endothelial cells of blood vessels (27). It has also been shown that *Porphyromonas* spp. induces autoimmune responses that may contribute to cardiovascular diseases; specifically, *P. gingivalis*, which can invade endothelial cells (28).

Serum levels of high-sensitivity C-reactive protein (hsCRP), used as a biomarker for a cardiovascular event, are higher in young individuals with AP than in healthy controls, as well as IL-6, matrix metalloproteinase 8 (MMP-8), and soluble E-selectin, which are implicated in atherogenesis (29) (Figure 1). There is even an association of ALEOs with hsCRP levels > of 3 mg/mL, supporting a mechanistic link between this prevalent disease and cardiovascular risk in young individuals (30).

Role of macrophages during aging

Macrophages are phagocytic cells that form the first line of defense against pathogens. These plastic cells can polarize from classically activated M1 macrophages to alternatively activated M2 macrophages *in vitro*. However, the polarization state of M1 and M2 macrophages *in vivo* corresponds to a continuum of intermediate phenotypes that can switch from one phenotype to another in response to the cytokine milieu in each tissue microenvironment, whereas an inadequate balance between the polarization states can lead to the development of chronic inflammation and disease (31).

During aging, altered acquisition of functional phenotypes in response to the tissue microenvironment has been reported in splenic macrophages (32) and bone-marrow-derived macrophages (BMMs) (33) obtained from aged mice compared to young mice. The mRNA levels of pro-inflammatory cytokines (i.e. IL-6, TNF α , iNOS, and IL-1 β) from aged splenic macrophages were decreased after LPS from *Escherichia coli* (*E. coli*) or TNF α /IFN- γ stimulation, as compared with cells derived from younger animals (32). These results are concordant with a reduced amount of pro-inflammatory cytokines, including IL-12, and increased IL-10, produced by splenic macrophages, as previously reported (34). Conversely, aged mouse BMMs from mice showed higher levels of the TNF α transcript and protein secretion after IFN- γ and *E. coli*-LPS stimulation, respectively (33). However, BMMs challenged with *P. gingivalis*, a common periodontal pathogen, show attenuated levels of cytokines and chemokines, including TNF α , IL-6, IL-10, and nitric oxide (NO) (35). Furthermore, aged macrophages showed lower levels of TLR4/MD-2, although no changes were observed in their surface density (34).

Macrophages play a role in the innate host response in periodontitis, particularly in oral tissue. Clark *et al.* (36) reported age-related changes in macrophages associated with a pro-inflammatory and M1-like phenotype (Figure 1), as well as improper polarization, which might be associated with the

impaired inflammatory regulatory activity of macrophages in response to microbial plaque and periodontal disease resolution. Likewise, decreased NO production and changes in the expression levels of toll-like receptors (TLRs), together with defects in the signaling pathways in aged macrophages (37, 38), could be related to increased susceptibility to infections in the elderly and chronic disease development such as periodontitis.

Herpes simplex virus infection in periodontal disease and systemic implications

HSV-1 and HSV-2 are two highly prevalent viruses in the human population. It is estimated that approximately 66.6% of individuals worldwide are infected with HSV-1 and 13.2% with HSV-2 (39). Both viruses have been reported to modulate the host's innate and adaptive immune responses (40, 41). HSVs cause lifelong infections with a wide range of clinical manifestations, from mild to life-threatening. A common primary infection-related clinical manifestation in children is herpetic gingivostomatitis, which consists of oral lesions in the buccal and gingival mucosae as well as the tongue, and is usually self-contained (39).

Importantly, HSV-1 and HSV-2 have been associated with the severity of periodontal diseases, such as chronic inflammatory conditions that affect the supporting tissue of the teeth (42). Notably, HSV DNA has been found in subgingival plaque samples associated with higher clinical attachment loss (≥ 4 mm) and the presence of bleeding on probing (BOP) (43). Moreover, it has been estimated that 63% of sites with aggressive periodontitis and 45% of sites with chronic periodontitis contained HSV-1 copy counts (44).

The severity of periodontal diseases related to HSV infections may be explained by the fact that herpes simplex viruses infect periodontal tissues (Figure 1), which induces local immune responses and may also serve as cofactors for bacterial virulence determinants in periodontal diseases (43). Interestingly, HSV-1 and HSV-2 DNA have been detected *via* nested PCR in T cells and monocytes/macrophages in gingival cells obtained from adult individuals with periodontitis (45). Furthermore, it was found that downregulation of periodontal T cell function caused by HSV infection may increase the risk of destructive periodontal disease, as T cells have been suggested to have a protective role in periodontal disease (45).

Importantly, the combination of bacteria associated with periodontitis and HSV infections could lead to an increased likelihood of cardiovascular complications in infected individuals (46). Indeed, HSV-1 and HSV-2 have been associated with several cardiac diseases (Figure 1), such as atherosclerosis, and are considered factors that increase the

risk of this disease (47). Noteworthy, two mechanisms have been proposed to explain the association between periodontitis and cardiovascular diseases such as atherosclerosis. Either periodontal pathogens directly invade the bloodstream or indirectly increase the systemic levels of inflammatory mediators (47). Importantly, it has been suggested that improving one of these conditions may positively affect the other diseases (47). However, this potential association requires further investigation.

HSV infections may cause nervous system-related pathologies, such as herpetic encephalitis, meningitis, and Mollaret's syndrome, and have been associated with several neurodegenerative diseases, such as Parkinson's disease, multiple sclerosis (MS), and AD (48) (Figure 1). Moreover, several studies have associated HSVs infections with neuronal aging, which, in turn, could lead to AD. For instance, it has been shown both *in vitro* and *in vivo* models that HSV-1 infection induces a significant increase in the levels of histone modifications, such as H4 lysine (K) 16 acetylation (ac) (H4K16ac) and histone-modifying factors, such as Sin3 and histone deacetylases (HDAC1), suggesting that neuronal responses to virus latency and reactivation upregulate these aging markers (49). Additionally, upregulation of the histone regulator A (HIRA) during viral latency and its different localization in cortical neurons in HSV-1-infected mouse brains have also been reported (49). Importantly, HIRA is also a key player in aging (49). Thus, HSVs infections are also linked to aging of the nervous system, which is directly related to the development of AD.

Interestingly, the frequency and magnitude of herpesvirus reactivation have been described to be affected by aging. This observation is supported by the detection of increased CD8+ T cells specific for this virus in aged subjects. However, herpesviruses can also reactivate as a result of stress. Further studies are needed to understand the effects of herpesvirus reactivation and its role in healthy aging (50).

Conclusions

There are changes at both immune and non-immune cells of the oral mucosa during aging, that lead to a destabilization of the tissue homeostasis and impaired wound healing. Also, these aging-associated changes coupled with the decrease in AMPs create a permissive environment in the periodontium for both pathogen colonization and reactivation of pre-existing pathogens such as HSV, which may influence the development and severity of oral diseases, such as periodontitis. Interestingly, pathogens involved in the development of this disease, such as *P.gingivalis*, are also involved in the development of systemic diseases including various cancers and Alzheimer's disease. Also, HSV infections at other sites than the oral cavity may nevertheless relate to periodontitis and central nervous system

diseases, given the potential of this condition to cause systemic diseases. Given this scenario, further studies on these eventual associations may shed light on previously unrecognized relations between cell and tissue aging and oral diseases as well as new insight into their consequences at the systemic level.

Author contributions

VV and MC were involved in designing the concept of the review and oversight. AR and PG were involved in the HSV section and revisions of the manuscript. VAT was involved in the AMP section and revisions of the manuscript. CF and CD were involved in the Periodontal section. VV was involved in the macrophages and *P.gingivalis* sections and drafted the manuscript. MG was involved in the apical periodontal disease section and revisions of the manuscript and MC was involved in the aging section and drafted the manuscript. All authors contributed to the article and approved the submitted version.

Funding

Millennium Institute on Immunology and Immunotherapy (ICN09_016/ICN 2021_045). Financiado por la Vicerrectoría de Investigación y Desarrollo (VID) de la Universidad de Chile, proyecto ENL05/22.

Acknowledgments

We are grateful to Mr. Diego Morales for drawing both figures. Agencia Nacional de Investigación y Desarrollo (ANID) - Millennium Science Initiative Program - ICN09_016/ICN 2021_045: Millennium Institute on Immunology and Immunotherapy (ICN09_016/ICN 2021_045; former P09/016-F). Financiado por la Vicerrectoría de Investigación y Desarrollo (VID) de la Universidad de Chile, proyecto ENL05/22. Beca doctorado ANID 21210960 (CF), 21211818 (VV), 21210509 (MG), 21210570 (CD).

Conflict of interest

The authors declare that the research was conducted in the absence of any commercial or financial relationships that could be construed as a potential conflict of interest.

Publisher's note

All claims expressed in this article are solely those of the authors and do not necessarily represent those of their affiliated

organizations, or those of the publisher, the editors and the reviewers. Any product that may be evaluated in this article, or

claim that may be made by its manufacturer, is not guaranteed or endorsed by the publisher.

References

- Ebersole JL, Graves CL, Gonzalez OA, Dawson D, Morford LA, Huja PE, et al. Aging, inflammation, immunity and periodontal disease. *Periodontology* (2016) 72:54–75. doi: 10.1111/prd.12135
- Cáceres M, Oyarzun A, Smith PC. Defective wound-healing in aging gingival tissue. *J Dent Res* (2014) 93(7):691–7. doi: 10.1177/0022034514533126
- Huttner EA, Machado DC, de Oliveira RB, Antunes AGF, Hebling E. Effects of human aging on periodontal tissues. *Spec Care Dent* (2009) 29(4):149–55. doi: 10.1111/j.1754-4505.2009.00082.x
- Fernandez C, Burgos A, Morales D, Rosales-Rojas R, Canelo J, Vergara-Jaque A, et al. TMRSS11a is a novel age-altered, tissue specific regulator of migration and wound healing. *FASEB J* (2021) 35(5):e21597. doi: 10.1096/fj.202002253RRR
- Basisty N, Kale A, Jeon OH, Kuehnemann C, Payne T, Rao C, et al. A proteomic atlas of senescence-associated secretomes for aging biomarker development. *PLoS Biol* (2020) 18(1):e3000599. doi: 10.1371/journal.pbio.3000599
- Saldías MP, Fernández C, Morgan A, Díaz C, Morales D, Jaña F, et al. Aged blood factors decrease cellular responses associated with delayed gingival wound repair. *PLoS One* (2017) 12(9):e0189566. doi: 10.1371/journal.pone.0184189
- Belsky DW, Caspi A, Houts R, Cohen HJ, Corcoran DL, Danese A, et al. Quantification of biological aging in young adults. *Proc Natl Acad Sci U S A* (2015) 112(30):E4104–10. doi: 10.1073/pnas.1506264112
- Hajishengallis G. Too old to fight? aging and its toll on innate immunity. *Mol Oral Microbiol* (2010) 25:25–37. doi: 10.1111/j.2041-1014.2009.00562.x
- Eskandari MA, Jotwani R, Abe T, Chmela J, Lim JH, Liang S, et al. The leukocyte integrin antagonist del-1 inhibits IL-17-mediated inflammatory bone loss. *Nat Immunol* (2012) 13(5):465–73. doi: 10.1038/ni.2260
- Huan Y, Kong Q, Mou H, Yi H. Antimicrobial peptides: Classification, design, application and research progress in multiple fields. *Front Microbiol* (2020) 11:2559. doi: 10.3389/fmicb.2020.582779
- Cabras T, Pisano E, Boi R, Olanas A, Manconi B, Inzitari R, et al. Age-dependent modifications of the human salivary secretory protein complex. *J Proteome Res* (2009) 8(8):4126–34. doi: 10.1021/pr900212u
- Melino S, Santone C, Di Nardo P, Sarkar B. Histatins: Salivary peptides with copper(II)- and zinc(II)-binding motifs perspectives for biomedical applications. *FEBS J* (2014) 281:657–72. doi: 10.1111/febs.12612
- Oudhoff MJ, Kroeze KL, Nazmi K, Van Den Keijbus PAM, Van 't Hof W, Fernandez-Borja M, et al. Structure-activity analysis of histatin, a potent wound healing peptide from human saliva: cyclization of histatin potentiates molar activity 1,000-fold. *FASEB J* (2009) 23(11):3928–35. doi: 10.1096/fj.09-137588
- Torres P, Díaz J, Arce M, Silva P, Mendoza P, Lois P, et al. The salivary peptide histatin-1 promotes endothelial cell adhesion, migration, and angiogenesis. *FASEB J* (2017) 31(11):4946–58. doi: 10.1096/fj.201700085R
- Cheng L, Lei X, Yang Z, Kong Y, Xu P, Peng S, et al. Histatin 1 enhanced the speed and quality of wound healing through regulating the behaviour of fibroblast. *Cell Prolif* (2021) 54(8):e13087. doi: 10.1111/cpr.13087
- Torres P, Hernández N, Mateluna C, Silva P, Reyes M, Solano L, et al. Histatin-1 is a novel osteogenic factor that promotes bone cell adhesion, migration, and differentiation. *J Tissue Eng Regen Med* (2021) 15(4):336–46. doi: 10.1002/term.3177
- Liu XB, Gao ZY, Sun CT, Wen H, Gao B, Li SB, et al. The potential role of p.gingivalis in gastrointestinal cancer: A mini review. *Infect Agents Cancer* (2019) 14(1):1–7. doi: 10.1186/s13027-019-0239-4
- Carrion J, Scisci E, Miles B, Sabino GJ, Zeituni AE, Gu Y, et al. Microbial carriage state of peripheral blood dendritic cells (DCs) in chronic periodontitis influences DC differentiation, atherogenic potential. *J Immunol* (2012) 189(6):3178. doi: 10.4049/jimmunol.1201053
- Dominy SS, Lynch C, Ermini F, Benedyk M, Marczyk A, Konradi A, et al. Porphyromonas gingivalis in alzheimer's disease brains: Evidence for disease causation and treatment with small-molecule inhibitors. *Sci Adv* (2019) 5(1):eaau3333. doi: 10.1126/sciadv.aau3333
- Dayan S, Stashenko P, Niederman R, Kupper TS. Oral epithelial overexpression of IL-1 α causes periodontal disease. *J Dent Res* (2016) 95(10):786–90. doi: 10.1177/15440591160408301010
- Elsayed R, Elashiry M, Liu Y, El-Awady A, Hamrick M, Cutler CW. Porphyromonas gingivalis provokes exosome secretion and paracrine immune senescence in bystander dendritic cells. *Front Cell Infect Microbiol* (2021) 11:471. doi: 10.3389/fcimb.2021.669989
- Gnanasekaran J, Gallimidi AB, Saba E, Pandi K, Berchoer LE, Hermano E, et al. Intracellular porphyromonas gingivalis promotes the tumorigenic behavior of pancreatic carcinoma cells. *Cancers (Basel)* (2020) 12(8):1–14. doi: 10.3390/cancers12082331
- Zhang L, Liu Y, Zheng HJ, Zhang CP. The oral microbiota may have influence on oral cancer. *Front Cell Infect Microbiol* (2020) 9:476. doi: 10.3389/fcimb.2019.00476
- Olsen I. Porphyromonas gingivalis-induced neuroinflammation in alzheimer's disease. *Front Neurosci* (2021) 15:1216. doi: 10.3389/fnins.2021.691016
- Tibúrcio-Machado CS, Michelon C, Zanatta FB, Gomes MS, Marin JA, Bier CA. The global prevalence of apical periodontitis: a systematic review and meta-analysis. *Int Endodont J Int Endod J* (2021) 54:712–35. doi: 10.1111/iej.13467
- Qian W, Ma T, Ye M, Li Z, Liu Y, Hao P. Microbiota in the apical root canal system of tooth with apical periodontitis. *BMC Genomics* (2019) 20(2):175–85. doi: 10.1186/s12864-019-5474-y
- Bordagaray MJ, Fernández A, Garrido M, Astorga J, Hoare A, Hernández M. Systemic and extracellular bacterial translocation in apical periodontitis. *Front Cell Infect Microbiol* (2021) 11. doi: 10.3389/fcimb.2021.649925
- Reyes L, Getachew H, Dunn WA, Progulsk-Fox A. Porphyromonas gingivalis W83 traffics via ICAM1 in microvascular endothelial cells and alters capillary organization in vivo. *J Oral Microbiol* (2020) 12(1):1742528. doi: 10.1080/20002297.2020.1742528
- Libby P, Ridker PM, Maseri A. Inflammation and atherosclerosis. *Circulation* (2002) 105(9):1135–43. doi: 10.1161/hc0902.104353
- Garrido M, Cárdenas AM, Astorga J, Quinlan F, Valdés M, Chaparro A, et al. Elevated systemic inflammatory burden and cardiovascular risk in young adults with endodontic apical lesions. *J Endod* (2019) 45(2):111–5. doi: 10.1016/j.joen.2018.11.014
- Tarique AA, Logan J, Thomas E, Holt PG, Sly PD, Fantino E. Phenotypic, functional, and plasticity features of classical and alternatively activated human macrophages. *Am J Respir Cell Mol Biol* (2015) 53(5):676–88. doi: 10.1165/rmb.2015-00120C
- Mahbub S, Deburghgraeve CR, Kovacs EJ. Advanced age impairs macrophage polarization. *J Interf Cytokine Res* (2012) 32(1):18–26. doi: 10.1089/jir.2011.0058
- Gibson E, Loi F, Córdova LA, Pajarinen J, Lin T, Lu L, et al. Aging affects bone marrow macrophage polarization: Relevance to bone healing. *Regener Eng Transl Med* (2016) 2(2):98–104. doi: 10.1007/s40883-016-0016-5
- Chelvarajan RL, Collins SM, Van Willigen JM, Bondada S. The unresponsiveness of aged mice to polysaccharide antigens is a result of a defect in macrophage function. *J Leukoc Biol* (2005) 77(4):503–12. doi: 10.1189/jlb.0804449
- Shaik-Dasthagirisahab YB, Kantarci A, Gibson FC. Immune response of macrophages from young and aged mice to the oral pathogenic bacterium porphyromonas gingivalis. *Immun Ageing* (2010) 7(1):1–7. doi: 10.1186/1742-4933-7-15
- Clark D, Halpern B, Mielau T, Nakamura M, Kapila Y, Marcucio R. The contribution of macrophages in old mice to periodontal disease. *J Dent Res* (2021) 100(12):1397–404. doi: 10.1177/00220345211009463
- Renshaw M, Rockwell J, Engleman C, Gewirtz A, Katz J, Sambhara S. Cutting edge: Impaired toll-like receptor expression and function in aging. *J Immunol* (2002) 169(9):4697–701. doi: 10.4049/jimmunol.169.9.4697
- van Duin D, Mohanty S, Thomas V, Ginter S, Montgomery RR, Fikrig E, et al. Age-associated defect in human TLR-1/2 function. *J Immunol* (2007) 178(2):970–5. doi: 10.4049/jimmunol.178.2.970
- Reyes A, Farias MA, Corrales N, Tognarelli E, González PA. Herpes simplex viruses type 1 and type 2. In: *Encyclopedia of infection and immunity*. Elsevier (2022). p. 12–36. Available at: <https://www.sciencedirect.com/science/article/pii/B9780128187319000628?via%3Dihub>.
- Grauwet K, Cantoni C, Parodi M, De Maria A, Devriendt B, Pende D, et al. Modulation of CD112 by the alphaherpesvirus gD protein suppresses DNAM-1-dependent NK cell-mediated lysis of infected cells. *Proc Natl Acad Sci* (2014) 111(45):16118–23. doi: 10.1073/pnas.1409485111

41. Tognarelli EI, Palomino TF, Corrales N, Bueno SM, Kalergis AM, González PA. Herpes simplex virus evasion of early host antiviral responses. *Front Cell Infect Microbiol* (2019) 9:127. doi: 10.3389/fcimb.2019.00127
42. Kazi MMAG, Bharadwaj R. Role of herpesviruses in chronic periodontitis and their association with clinical parameters and in increasing severity of the disease. *Eur J Dent* (2017) 11(03):299–304. doi: 10.4103/ejd.ejd_43_17
43. Ling L-J, Ho C-C, Wu C-Y, Chen Y-T, Hung S-L. Association between human herpesviruses and the severity of periodontitis. *J Periodontol* (2004) 75(11):1479–85. doi: 10.1902/jop.2004.75.11.1479
44. Slots J. Periodontal herpesviruses: Prevalence, pathogenicity, systemic risk. *Periodontol 2000* (2015) 69(1):28–45. doi: 10.1111/prd.12085
45. Contreras A, Zadeh HH, Nowzari H, Slots J. Herpesvirus infection of inflammatory cells in human periodontitis: Virally infected gingival cells. *Oral Microbiol Immunol* (1999) 14(4):206–12. doi: 10.1034/j.1399-302X.1999.140402.x
46. Vilkuna-Rautiainen T, Pussinen PJ, Roivainen M, Petäys T, Jousilahti P, Hovi T, et al. Serum antibody response to periodontal pathogens and herpes simplex virus in relation to classic risk factors of cardiovascular disease. *Int J Epidemiol* (2006) 35(6):1486–94. doi: 10.1093/ije/dyl166
47. Zardawi F, Gul S, Abdulkareem A, Sha A, Yates J. Association between periodontal disease and atherosclerotic cardiovascular diseases: Revisited. *Front Cardiovasc Med* (2021) 7:625579. doi: 10.3389/fcvm.2020.625579
48. Duarte LF, Farias MA, Álvarez DM, Bueno SM, Riedel CA, González PA. Herpes simplex virus type 1 infection of the central nervous system: Insights into proposed interrelationships with neurodegenerative disorders. *Front Cell Neurosci* (2019) 13:46. doi: 10.3389/fncel.2019.00046
49. Napoletani G, Protto V, Marcocci ME, Nencioni L, Palamara AT, De Chiara G. Recurrent herpes simplex virus type 1 (HSV-1) infection modulates neuronal aging marks in *In vitro* and *In vivo* models. *Int J Mol Sci* (2021) 22(12):6279. doi: 10.3390/ijms22126279
50. Stowe RP, Kozlova EV, Yetman DL, Walling DM, Goodwin JS, Glaser R. Chronic herpesvirus reactivation occurs in aging. *Exp Gerontol* (2007) 42(6):563. doi: 10.1016/j.exger.2007.01.005



OPEN ACCESS

EDITED BY

Junji Xu,
Capital Medical University, China

REVIEWED BY

Lei Hu,
Beijing Stomatological Hospital,
Capital Medical University, China
Jihua Guo,
School of Stomatology, Wuhan
University, China

*CORRESPONDENCE

Xin Zeng
zengxin22@163.com
Ning Ji
jining_1023@126.com

[†]These authors have contributed
equally to this work

SPECIALTY SECTION

This article was submitted to
Mucosal Immunity,
a section of the journal
Frontiers in Immunology

RECEIVED 02 August 2022

ACCEPTED 13 October 2022

PUBLISHED 31 October 2022

CITATION

Xue N, Wang Y, Cheng H, Liang H,
Fan X, Zuo F, Zeng X, Ji N and
Chen Q (2022) Regulatory
T cell therapy suppresses
inflammation of oral mucosa.
Front. Immunol. 13:1009742.
doi: 10.3389/fimmu.2022.1009742

COPYRIGHT

© 2022 Xue, Wang, Cheng, Liang, Fan,
Zuo, Zeng, Ji and Chen. This is an
open-access article distributed under
the terms of the [Creative Commons
Attribution License \(CC BY\)](#). The use,
distribution or reproduction in other
forums is permitted, provided the
original author(s) and the copyright
owner(s) are credited and that the
original publication in this journal is
cited, in accordance with accepted
academic practice. No use,
distribution or reproduction is
permitted which does not comply with
these terms.

Regulatory T cell therapy suppresses inflammation of oral mucosa

Ningning Xue^{1†}, Ying Wang^{1†}, Hao Cheng², Hantian Liang²,
Xinzou Fan², Fengqiong Zuo³, Xin Zeng^{1*}, Ning Ji^{1*}
and Qianming Chen¹

¹State Key Laboratory of Oral Diseases, National Clinical Research Center for Oral Diseases, Chinese Academy of Medical Sciences Research Unit of Oral Carcinogenesis and Management, West China Hospital of Stomatology, Sichuan University, Chengdu, Sichuan, China, ²Department of Biotherapy, State Key Laboratory of Biotherapy and Cancer Center, West China Hospital, Sichuan University, Chengdu, Sichuan, China, ³Department of Immunology, West China School of Basic Medical Sciences and Forensic Medicine, Sichuan University, Chengdu, Sichuan, China

Oral inflammatory diseases, including oral lichen planus (OLP) and recurrent aphthous ulcer (RAU), seriously affect the patient's quality of life. Due to the lack of ideal disease models, it is difficult to determine whether novel immunotherapy strategies are effective in treating oral inflammatory diseases. Here, we show that the deficiency of Foxp3 or IL-2 caused oral mucosa inflammation in mice, proving that Treg cells are important in maintaining the immune homeostasis in the oral mucosa. Then we determined that adoptive transfer of CD4⁺CD25⁻CD45Rb^{high} T cells could induce oral inflammation in *Rag1*^{-/-} mice, and co-transfer of Treg cells together with CD4⁺CD25⁻CD45Rb^{high} T cells could suppress the development of oral inflammation in this mouse model. Our study showed that adoptive transfer of CD4⁺CD25⁻CD45Rb^{high} T cells into *Rag1*^{-/-} mice could be a novel disease model of oral inflammation. Our data provides direct evidence that Treg cell therapy is effective in suppressing oral mucosa inflammation in mice. Therefore, Treg cell therapy may be a promising novel strategy to treat oral inflammatory diseases.

KEYWORDS

oral mucosa, Treg cells, oral inflammation, CD25, Foxp3, immunotherapy

Introduction

The majority of oral mucosal diseases are inflammatory diseases (1). Inflammatory diseases of the oral mucosa, including oral lichen planus (OLP) and recurrent aphthous ulcer (RAU) have high prevalence and incidence (2, 3). These diseases either exhibit a long disease course or relapse easily, and also seriously affects the patient's quality of life. Therefore, the

prevalence of depression, anxiety, and stress is high in patients with oral inflammatory diseases (4, 5). Although the pathogenesis of these diseases is largely unknown, an increase in various pro-inflammatory cells and cytokines has been shown to be involved in the development and perpetuation of these diseases (6–10). However, the classic immunosuppressive drugs used to treat these patients have quite limited efficacy and may cause many side effects including anxiety, swelling, and weight gain (11). Therefore, the investigation of novel effective strategies to treat inflammatory diseases of the oral mucosa will benefit patients greatly.

CD4⁺CD25⁺Foxp3⁺ regulatory T cells (Treg cells) are a subset of CD4⁺ T cells that co-express interleukin-2 receptor alpha chain (IL-2R α , also called CD25) and the transcription factor forkhead box P3 (Foxp3) (12–15). These Treg cells are the key immune cells in maintaining immune tolerance and suppressing inflammation (16). Manipulating Treg cells has been shown to be a promising strategy to suppress and treat autoimmune and inflammatory diseases, including inflammatory bowel disease (IBD), experimental autoimmune encephalomyelitis (EAE), Type I diabetes (T1D), asthma, and arthritis (17–19). The IL-2-CD25 signaling pathway has been determined to be dramatically important for Treg cell generation in the thymus and periphery, as the absence of IL-2-CD25 signaling pathway cause Treg cell deficiency and severe systemic inflammation (20–22).

A number of studies have reported that Treg cells were increased in the sub-epithelial lymphocytic infiltrate of the OLP lesions and in peripheral blood mononuclear cells (PBMCs) (23–26). Our previous study showed that Treg cell frequency was negatively correlated with immune cell activation in OLP lesions (17). These findings suggest that an enhanced Treg cell function or increased Treg cell frequency can suppress oral mucosa inflammation, such as OLP. However, these studies were based only on phenotypic descriptions and speculations, and none of them determined whether Treg cell therapy could treat inflammatory diseases of the oral mucosa. One major difficulty in determining the function of Treg cells in oral mucosal inflammation is that there are no ideal inflammatory disease models of the oral mucosa, making it difficult to perform rigorous pre-clinical studies to determine whether Treg cell therapy is effective in treating inflammation of the oral mucosa. Therefore, it is necessary to develop ideal inflammatory disease models of the oral mucosa and to determine the therapeutic function of Treg cells in oral mucosal inflammation.

Here, we determined that the deletion of IL-2-CD25 signaling causes inflammation of the oral mucosa in mice. Following these findings, we developed an inflammatory disease model of the oral mucosa by adoptively transferring CD4⁺CD25⁺CD45RB^{high} T cells into *Rag1*^{-/-} mice, and determined that Treg cell therapy suppressed inflammation of the oral mucosa.

Methods and materials

Mice

C57BL/6 mice were bred in the animal facility of West China Hospital of Stomatology, Sichuan University under specific pathogen-free (SPF) conditions. *Il2*^{-/-} mice, Scurfy mice (*Foxp3*^{-/-} mice), *Rag1*^{-/-} mice, Foxp3-eGFP mice (C57BL/6 background), and CD45.1 (C57BL/6 background) mice were obtained from The Jackson Laboratory and bred in the animal facility of Sichuan University under specific-pathogen-free (SPF) conditions. All the mice used in the experiments were aged 6–8 weeks. All animal studies were approved on February 26, 2016, by the Animal Care and Use Committees of the West China Hospital of Stomatology, Sichuan University.

Antibodies and reagents

Fluorochrome-conjugated anti-mouse CD45.1 (A20), anti-mouse CD45.2 (104), anti-mouse TCR- β (H57-597), anti-mouse CD4 (RM4-5), anti-mouse CD8 α (53-6.7), anti-mouse IFN- γ (XMG1.2), anti-mouse TNF- α (MP6-XT22), anti-mouse IL-17A (eBio17B7), and anti-mouse/rat Foxp3 (FJK-16a) antibodies were obtained from Thermo Fisher Scientific. Foxp3/Transcription Factor Staining Buffer Set (00-5523-00) was obtained from Thermo Fisher Scientific. The BD Golgi-Plug Protein Transport Inhibitor (555029) and BD Cytofix/Cytoperm Fixation/Permeabilization Solution Kit (554714) were purchased from BD bioscience. PMA (P8319) and ionomycin calcium salt (I3909) were purchased from Millipore Sigma.

T cell adoptive transfer model

The CD4⁺CD25⁺CD45RB^{hi} T cell adoptive transfer model was established as previously described (27, 28), with some modifications. CD4⁺CD25⁺CD45RB^{hi} T cells were sorted with flow cytometry (FCM) from the spleens and peripheral lymph nodes (PLNs) of CD45.1 mice; then injected these sorted cells into *Rag1*^{-/-} mice intravenously (0.4×10^6 cells per mouse). *Rag1*^{-/-} mice received CD4⁺CD25⁺CD45RB^{hi} T cells would develop oral mucosa inflammation 8–10 weeks post T cell transfer. In the Treg cell therapy model, CD4⁺CD25⁺Foxp3(eGFP)⁺ Treg cells (0.1×10^6 cells per mouse) sorted with flow cytometry from spleens and peripheral lymph nodes (PLNs) of Foxp3-eGFP mice were co-transferred with CD4⁺CD25⁺CD45RB^{hi} T cells (0.4×10^6 cells per mouse) into *Rag1*^{-/-} mice intravenously to investigate the suppression of oral inflammation.

Flow cytometry analysis

Spleens and lymph nodes were mashed with 40µm filters to get single-cell suspensions. The cell surface staining was performed by staining the cell surface markers with antibody solutions for 20 minutes at 4°C in the dark. The intracellular cytokine staining was performed by culturing the cells with PMA (5 ng/mL), ionomycin (1µM) and Golgi-Plug (1: 1,000 dilutions) at 37°C for 4 hrs. The cultured samples were then stained with cell surface markers (antibody concentration: 1µg/ml), fixed with BD Fixation/Permeabilization buffer solution and stained with antibody solutions (antibody concentration: 2µg/ml) for 40 minutes at 4°C in the dark. The intranuclear transcription factor staining was performed by staining the cells with cell surface markers (antibody concentration: 1µg/ml), permeabilizing with Foxp3/Transcription Factor Staining Buffer Set, and staining with antibody solutions (antibody concentration: 2µg/ml) for 60 minutes at 4°C in the dark. The gating strategies for the flow data are presented in [Supplementary Figure 1](#).

Statistical analysis

Statistical analysis was performed using unpaired two-tailed Student's *t*-tests to compare differences between two different groups. Statistical significance was set at $p < 0.05$.

Results

Treg cell deficiency causes severe inflammation in oral mucosa

Foxp3 is the key transcription factor of Treg cells, and loss of Foxp3 cause the deficiency of Treg cells (13–15). To determine the function of Treg cells in the oral mucosa, we bred *Foxp3*^{-/-} mice to investigate inflammation development of oral mucosa in these mice. From the histological slides of the oral mucosa of *Foxp3*^{+/+} and *Foxp3*^{-/-} mice, we found that the loss of Treg cells resulted in severe inflammation in the oral mucosa ([Figure 1A](#)). Consistent with this, the total cell number of DLNs in *Foxp3*^{-/-} mice was significantly increased ([Figure 1B](#)). To check the immune responses of oral cavity, we investigated the frequencies of IFN-γ producing T cells (Th1 cells) and IL-17 producing T cells (Th17 cells) in the cervical lymph nodes (CLNs), the draining lymph nodes (DLNs) of oral cavity. This revealed that the deletion of Treg cells caused a dramatic increase in Th1 cells and Th17 cells ([Figures 1C–E](#)). These data show that Treg cells are important for maintaining the immune homeostasis in the oral mucosa.

IL-2-CD25 signaling pathway deficiency causes severe inflammation in the oral mucosa

IL-2 is a vital cytokine for Treg cell development, and the loss of IL-2 causes the deficiency of mature Treg cells (20–22). To further confirm the function of Treg cells in the oral mucosa, we bred *Il2*^{-/-} mice to investigate inflammation development of oral mucosa in these mice. We confirmed that Treg cell generation in *Il2*^{-/-} mice was indeed impaired in DLNs of the oral mucosa ([Figures 2A, B](#)). The histological slides of the oral mucosa of *Il2*^{+/+} and *Il2*^{-/-} mice revealed that loss of IL-2 caused severe inflammation in the oral mucosa ([Figure 2C](#)). Consistent with this, the total cell number of DLNs in *Il2*^{-/-} mice was significantly increased ([Figure 2D](#)), and the frequencies of CD4+ and CD8+ T cells did not change significantly ([Supplementary Figures 2A, B](#)). To check the immune responses in the oral cavity, we investigated the frequencies of Th1 cells and Th17 cells in DLNs, and we found that the deletion of IL-2 caused a dramatic increase in Th1 cells and Th17 cells ([Figures 2E–G](#)). These data show that deficiency of the IL-2-CD25 signaling pathway indeed causes inflammation in the oral mucosa, further confirming that Treg cells are important in maintaining the immune homeostasis in the oral mucosa.

Adoptive transfer of CD4⁺CD25⁻CD45Rb^{high} T cells into *Rag1*^{-/-} mice induces oral mucosal inflammation

Since we determined that impaired Treg cell-mediated immune homeostasis led to inflammation of the oral mucosa; therefore, we surmise that effector T cells will cause inflammation of oral mucosa in the absence of functional Treg cells. To investigate this hypothesis, we transferred CD4⁺CD25⁻CD45Rb^{high} T cells (naïve T cells) into *Rag1*^{-/-} mice and allowing the cells to develop into effector T cells. Severe inflammation developed in the oral mucosa of these mice 8–10 weeks after T cell transfer ([Figure 3A](#)). To identify the immune responses of oral mucosa in these mice, we investigated the immune responses of T cells in DLNs with FCM. We found that plenty of Th1 cells and Th17 cells were present in DLNs of the oral cavity ([Figure 3B](#)), suggesting that the development of the inflammation is due to the activation of naïve T cells and the proliferation and differentiation of effector T cells in the absence of Treg cells. These data show that the CD4⁺CD25⁻CD45Rb^{high} T cell adoptive transfer model is a good disease model for investigating inflammation of the oral mucosa, as the characteristics of the immune response in this mouse model are very similar to those in patients with oral inflammation (6).

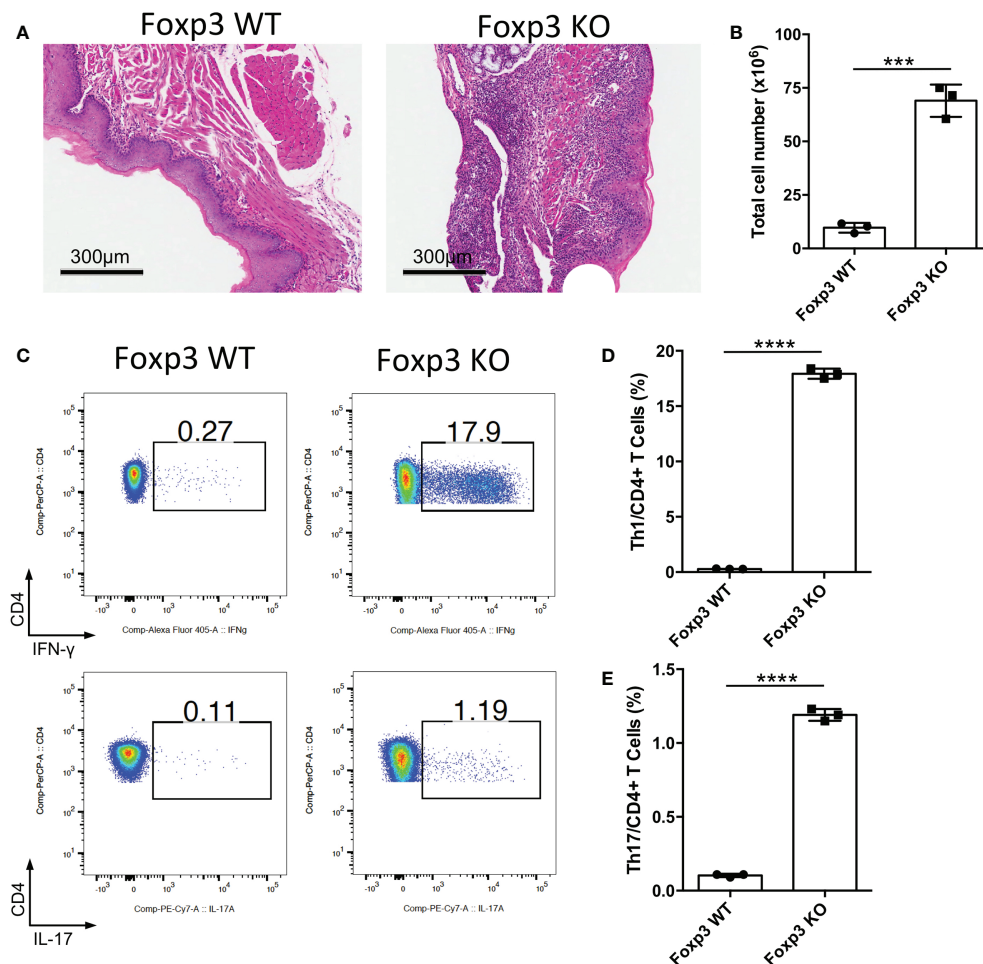


FIGURE 1
Deletion of Treg cells causes severe inflammation in oral mucosa. Oral tissues and draining lymph nodes (DLNs) of *Foxp3*^{+/+} (Foxp3 WT) and *Foxp3*^{-/-} (Foxp3 KO) mice were harvested from four-week-old mice (n=3). (A) Representative histology images of oral mucosa sections. Scale bars, 300µm. (B) Bar graphs showing total cell numbers in DLNs of the oral cavity. (C–E) Representative flow cytometry plots (C) and bar graphs (D, E) showing frequencies of CD4⁺ IFN-γ⁺ T cells (Th1 cells) and CD4⁺ IL-17A⁺ T cells (Th17 cells) in DLNs. Data are representative of two independent experiments. Summary data are presented as mean ± SD. ***p < 0.001; ****p < 0.0001, unpaired two-tailed Student's *t*-tests.

Adoptive transfer of Treg cells suppresses inflammation in oral mucosa

The CD4⁺CD25⁺CD45Rb^{high} T cell adoptive transfer model could be a disease model of oral mucosal inflammation; therefore, we used this model to identify whether adoptive transfer of functional Treg cells could suppress chronic inflammation of the oral mucosa. CD4⁺CD25⁺CD45Rb^{high} T cells isolated from CD45.1⁺ mice were transferred into *Rag1*^{-/-} mice to induce oral inflammation, with or without the co-transfer of CD4⁺CD25⁺Foxp3(eGFP)⁺ Treg cells sorted from Foxp3-eGFP mice. We found that the adoptive transfer of Treg cells suppressed the development of oral mucosal inflammation; the control group (Teff) developed oral

mucosa inflammation, whereas the Treg cell-treated group (Teff+Treg) did not 8–10 weeks after T cell transfer (Figure 4A). The changes in immune responses were determined after the mice were euthanized. Treg cell transfer significantly reduced both whole CD4⁺ T cell frequency and Th1 cell frequency in DLNs (Figures 4B–D). Moreover, the numbers of total immune cells, Th1 cells and Th17 cells in DLNs were also reduced in the Treg cell-treated group (Figures 4E–G). To further confirm that Treg cell therapy can suppress immune responses in the oral mucosa, the immune responses in the oral mucosa were determined by FCM. We found that Treg cell transfer significantly reduced both whole CD4⁺ T and Th1 cell frequencies in the oral mucosa (Figures 4H–J). Taken together, these data show that the

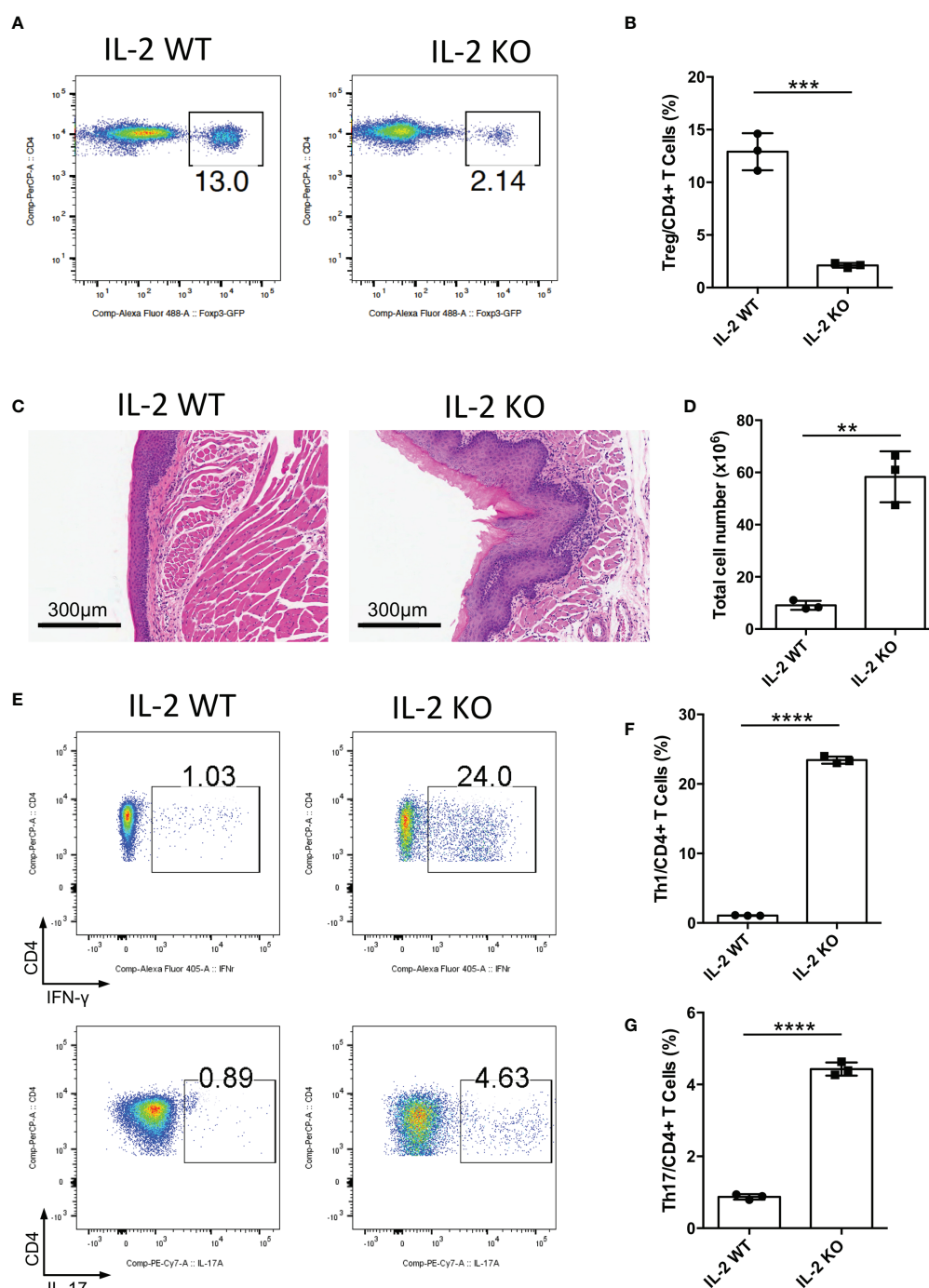


FIGURE 2

Deletion of IL-2 causes severe inflammation in oral mucosa. Oral tissues and draining lymph nodes (DLNs) of *Il2*^{+/+} (IL-2 WT) and *Il2*^{-/-} (IL-2 KO) mice were harvested from four-week-old mice (n=3). (A, B) Representative flow cytometry plots (A) and bar graphs (B) showing frequencies of CD4⁺ Foxp3⁺ Treg cells in DLNs of the oral cavity. (C) Representative histology images of oral mucosa sections. Scale bars, 300μm. (D) Bar graphs showing total cell numbers in DLNs of the oral cavity. (E–G) Representative flow cytometry plots (E) and bar graphs (F, G) showing frequencies of CD4⁺ IFN-γ⁺ T cells (Th1 cells) and CD4⁺ IL-17A⁺ T cells (Th17 cells) in DLNs. Data are representative of two independent experiments. Summary data are presented as mean ± SD. **p < 0.01, ***p < 0.001, ****p < 0.0001, unpaired two-tailed Student's t tests.

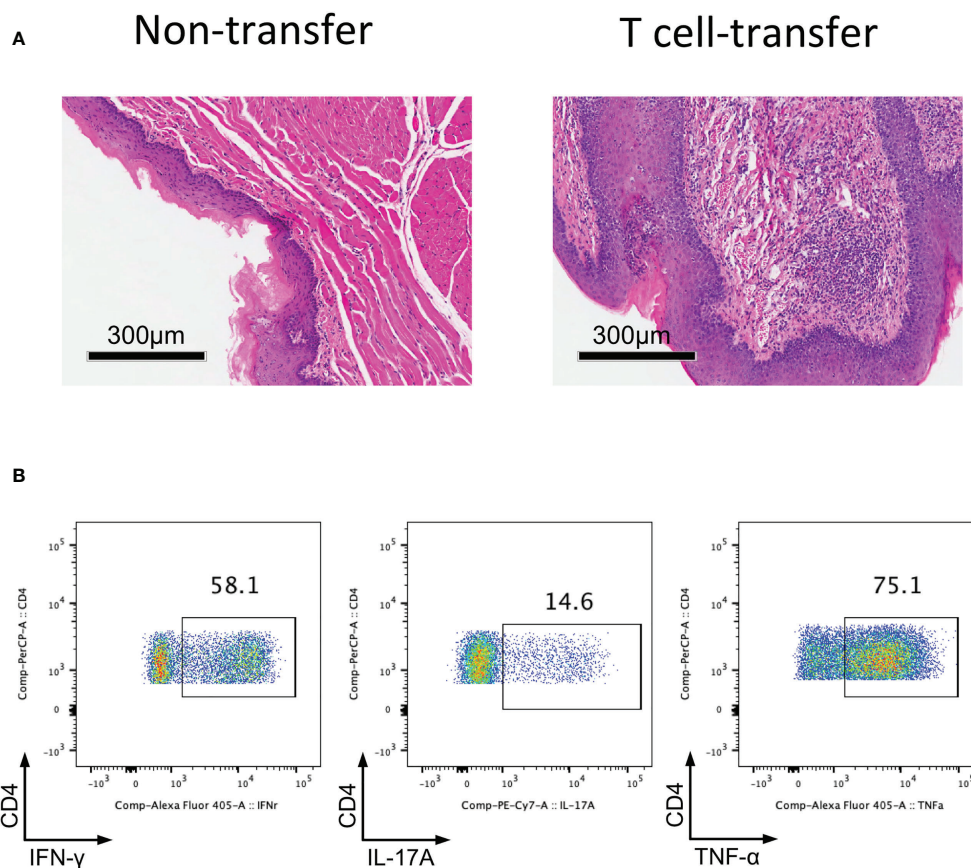


FIGURE 3

Adoptively transfer $CD4^+CD25^-CD45Rb^{high}$ T cells into $Rag1^{-/-}$ mice induces oral mucosal inflammation. $CD4^+CD25^-CD45Rb^{high}$ T cells sorted by flow cytometry from spleens and peripheral lymph nodes (PLNs) of CD45.1 mice were injected into $Rag1^{-/-}$ mice, and oral mucosa of $Rag1^{-/-}$ mice was harvested 8–10 weeks post T cell transfer ($n=3$). (A) Representative histology images of oral mucosa sections. (B) Representative flow cytometry plots showing frequencies of Th1 cells, Th17 cells and $CD4^+TNF-\alpha^+$ cells in DLNs of the oral cavity in T cell transfer mice. Data are representative of two independent experiments.

adoptive transfer of Treg cells can suppress the development of inflammation in the oral mucosa.

Discussion

In this study, Treg cell deficiency was shown to cause oral mucosal inflammation in mice. Next, the adoptive transfer of $CD4^+CD25^-CD45Rb^{high}$ T cells into $Rag1^{-/-}$ mice was shown to induce oral mucosal inflammation. By using this model of oral mucosal inflammation, we confirmed that Treg cell therapy indeed can suppress inflammation of oral mucosa. Therefore, we showed that the $CD4^+CD25^-CD45Rb^{high}$ T cell adoptive transfer model, also called the adoptive transfer inflammatory bowel disease (IBD) model, is a good disease model for investigating inflammation of the oral mucosa. Consistent with

Treg cell therapy in IBD model (18, 28), the adaptive transfer of Treg cells could also suppress inflammation of the oral mucosa.

Here, we determined that the T cell transfer mouse model of chronic inflammation could be used as a disease model of oral mucosal inflammation, as the immune responses in the oral mucosa of this mouse model are very similar to those in patients with oral inflammation (6, 10, 29, 30). Although the adoptive transfer of $CD4^+CD25^-CD45Rb^{high}$ T cells could result in oral mucosal inflammation, this disease model may develop systemic inflammation. Therefore, this disease model is not an ideal disease model for investigating the immune responses of the oral mucosa. Thus, the development of better models of oral inflammatory diseases remains an important bottleneck to overcome in future studies.

The integrity of the oral mucosa is crucial for defending against foreign antigens and maintaining homeostasis of the

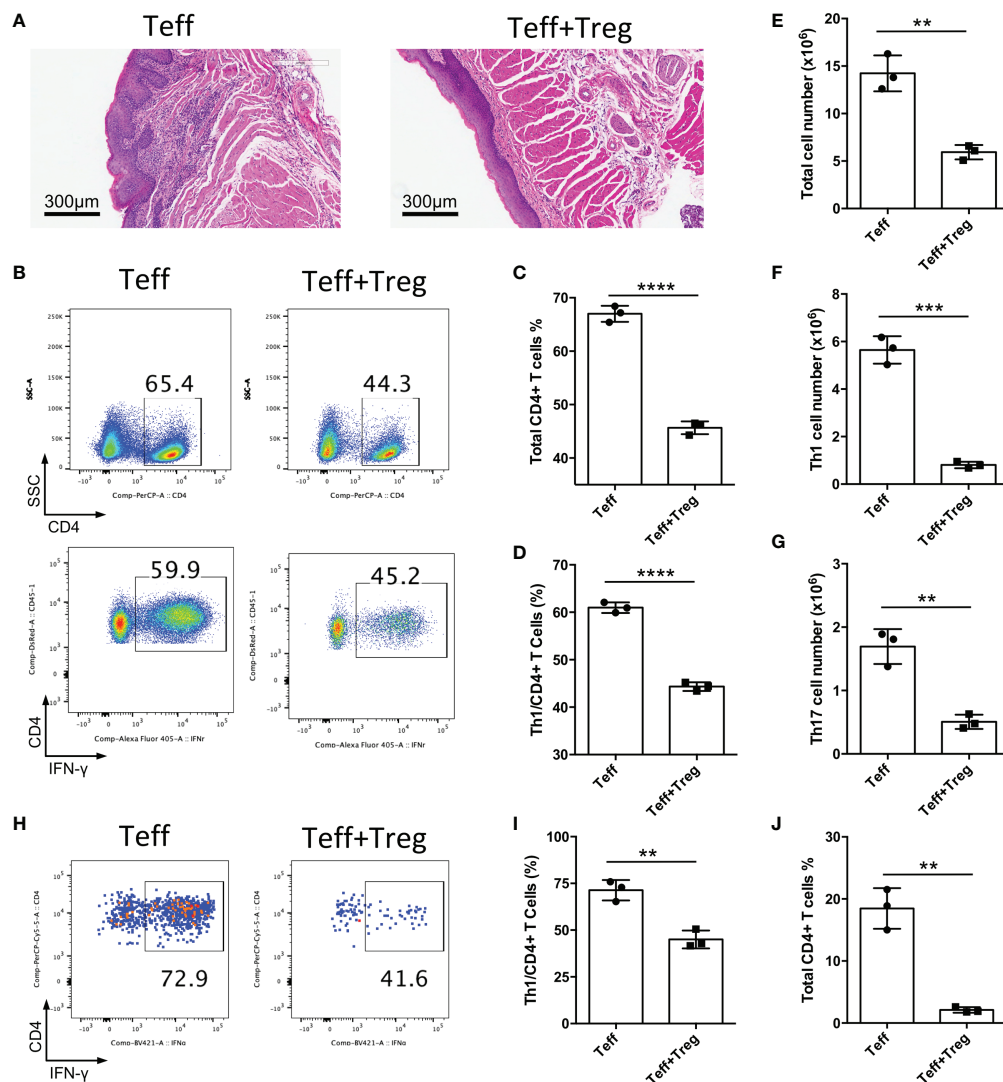


FIGURE 4

Adoptive transfer of Treg cells suppresses inflammation in oral mucosa. CD4⁺CD25⁺CD45RB^{high} T cells sorted by flow cytometry from the spleens and peripheral lymph nodes (PLNs) of CD45.1 mice were injected into *Rag1*^{-/-} mice (Teff), and CD4⁺CD25⁺Foxp3(eGFP)⁺ Treg cells of CD45.2 mice were co-transferred to treat the oral inflammation (Teff+Treg) (n=3). (A) Representative histology images of oral mucosa sections. (B-D) Representative flow cytometry plots (B) and bar graphs showing frequencies of CD45.1⁺ Teff cells (C) and Th1 cells (D) in DLNs of the oral cavity. (E-G) Bar graphs showing the numbers of total immune cells (E), Th1 cells (F) and Th17 cells (G) in DLNs of the oral cavity. (H-J) Representative flow cytometry plots (H) and bar graphs showing frequencies of Th1 cells (I) and total Teff cells (J) in the oral mucosa. Data are representative of two independent experiments. Summary data are presented as mean ± SD. **p < 0.01, ***p < 0.001, ****p < 0.0001, unpaired two-tailed Student's t tests.

oral cavity (31). Treg cells have long been considered to be effective in controlling oral mucosa inflammation; however, no study has ever confirmed it strongly. One study reported that the depletion of Treg cells causes the infiltration of effector T cells that are associated with inflammation of the oral mucosa (31). In the current study, we demonstrated that adoptive transfer of Treg cells could suppress oral mucosal inflammation. Together, these two studies show that Treg cell

therapy is a promising novel strategy for the treatment of oral inflammatory diseases.

In summary, our current study shows that the T cell transfer mouse model is a good model for investigating oral mucosal inflammation. More importantly, this study also verified that the adoptive transfer of Treg cells could suppress oral mucosa inflammation, showing that Treg cell therapy could be a promising novel strategy to treat oral inflammatory diseases.

Data availability statement

The original contributions presented in the study are included in the article/**Supplementary Material**. Further inquiries can be directed to the corresponding authors.

Ethics statement

The animal study was reviewed and approved by Animal Care and Use Committees of the West China Hospital of Stomatology, Sichuan University.

Author contributions

NX and YW designed and performed the experiments, analyzed the data and drafted the manuscript. HC, HL, and XF performed the experiments. FZ and QC supervised the study and edited the manuscript. XZ and NJ supervised the study, designed the experiments and wrote the manuscript. All authors contributed to the article and approved the submitted version.

Funding

This work was supported by the National Natural Science Foundation of China (NO. 81991502, U19A2005, 82270986,

81600876), the CAMS Innovation Fund for Medical Sciences (CIFMS, 2019-I2M-5-004, 2020-I2M-C&T-A-023) and the Key Project of the Science and Technology Department of Sichuan Province (NO. 2022YFS0003, 2020YFS0210).

Conflict of interest

The authors declare that the research was conducted in the absence of any commercial or financial relationships that could be construed as a potential conflict of interest.

Publisher's note

All claims expressed in this article are solely those of the authors and do not necessarily represent those of their affiliated organizations, or those of the publisher, the editors and the reviewers. Any product that may be evaluated in this article, or claim that may be made by its manufacturer, is not guaranteed or endorsed by the publisher.

Supplementary material

The Supplementary Material for this article can be found online at: <https://www.frontiersin.org/articles/10.3389/fimmu.2022.1009742/full#supplementary-material>

References

1. Wu RQ, Zhang DF, Tu E, Chen QM, Chen W. The mucosal immune system in the oral cavity-an orchestra of T cell diversity. *Int J Oral Sci* (2014) 6(3):125–32. doi: 10.1038/ijos.2014.48
2. Manfredini M, Guida S, Giovani M, Lippolis N, Spinass E, Farnetani F, et al. Recurrent aphthous stomatitis: Treatment and management. *Dermatol Pract Concept* (2021) 11(4):e2021099. doi: 10.5826/dpc.1104a99
3. Li C, Tang X, Zheng X, Ge S, Wen H, Lin X, et al. Global prevalence and incidence estimates of oral lichen planus: A systematic review and meta-analysis. *JAMA Dermatol* (2020) 156(2):172–81. doi: 10.1001/jamadermatol.2019.3797
4. De Porras-Carrique T, Gonzalez-Moles MA, Warnakulasuriya S, Ramos-Garcia P. Depression, anxiety, and stress in oral lichen planus: A systematic review and meta-analysis. *Clin Oral Investig* (2022) 26(2):1391–408. doi: 10.1007/s00784-021-04114-0
5. Dhopte A, Naidu G, Singh-Makkad R, Nagi R, Bagde H, Jain S. Psychometric analysis of stress, anxiety and depression in patients with recurrent aphthous stomatitis-a cross-sectional survey based study. *J Clin Exp Dent* (2018) 10(11):e1109–e14. doi: 10.4317/jced.55012
6. Wang H, Zhang D, Han Q, Zhao X, Zeng X, Xu Y, et al. Role of distinct CD4 (+) T helper subset in pathogenesis of oral lichen planus. *J Oral Pathol Med* (2016) 45(6):385–93. doi: 10.1111/jop.12405
7. Humberto JSM, Pavanin JV, Rocha M, Motta ACF. Cytokines, cortisol, and nitric oxide as salivary biomarkers in oral lichen planus: a systematic review. *Braz Oral Res* (2018) 32:e82. doi: 10.1590/1807-3107bor-2018.vol32.0082
8. Chen L, Ke Z, Zhou Z, Jiang X, Zhao Y, Zhang J. Associations of IL-1, 6, and 10 gene polymorphisms with susceptibility to recurrent aphthous stomatitis: Insights from a meta-analysis. *Genet Test Mol Biomarkers* (2018) 22(4):237–45. doi: 10.1089/gtmb.2017.0072
9. Lu R, Zhang J, Sun W, Du G, Zhou G. Inflammation-related cytokines in oral lichen planus: An overview. *J Oral Pathol Med* (2015) 44(1):1–14. doi: 10.1111/jop.12142
10. Lu R, Zeng X, Han Q, Lin M, Long L, Dan H, et al. Overexpression and selectively regulatory roles of IL-23/IL-17 axis in the lesions of oral lichen planus. *Mediators Inflammation* (2014) 2014:701094. doi: 10.1155/2014/701094
11. Kaufman MB. Adverse effects associated with dexamethasone, lorazepam, and granisetron. *Ann Pharmacother* (1994) 28(11):1306–7. doi: 10.1177/106002809402801122
12. Sakaguchi S, Sakaguchi N, Asano M, Itoh M, Toda M. Immunologic self-tolerance maintained by activated T cells expressing IL-2 receptor alpha-chains (CD25). breakdown of a single mechanism of self-tolerance causes various autoimmune diseases. *J Immunol* (1995) 155(3):1151–64.
13. Hori S, Nomura T, Sakaguchi S. Control of regulatory T cell development by the transcription factor Foxp3. *Science* (2003) 299(5609):1057–61. doi: 10.1126/science.1079490
14. Fontenot JD, Gavin MA, Rudensky AY. Foxp3 programs the development and function of CD4+CD25+ regulatory T cells. *Nat Immunol* (2003) 4(4):330–6. doi: 10.1038/ni904
15. Khattri R, Cox T, Yasayko SA, Ramsdell F. An essential role for scurf in CD4+CD25+ T regulatory cells. *Nat Immunol* (2003) 4(4):337–42. doi: 10.1038/ni909
16. Sakaguchi S. Regulatory T cells: key controllers of immunologic self-tolerance. *Cell* (2000) 101(5):455–8. doi: 10.1016/s0092-8674(00)80856-9
17. Zhang D, Wang J, Li Z, Zhou M, Chen Q, Zeng X, et al. The activation of NF-kappaB in infiltrated mononuclear cells negatively correlates with treg cell

frequency in oral lichen planus. *Inflammation* (2015) 38(4):1683–9. doi: 10.1007/s10753-015-0145-x

18. Zhang D, Chia C, Jiao X, Jin W, Kasagi S, Wu R, et al. D-mannose induces regulatory T cells and suppresses immunopathology. *Nat Med* (2017) 23(9):1036–45. doi: 10.1038/nm.4375
19. Sun G, Hou Y, Gong W, Liu S, Li J, Yuan Y, et al. Adoptive induced antigen-specific treg cells reverse inflammation in collagen-induced arthritis mouse model. *Inflammation* (2018) 41(2):485–95. doi: 10.1007/s10753-017-0704-4
20. Tai X, Erman B, Alag A, Mu J, Kimura M, Katz G, et al. Foxp3 transcription factor is proapoptotic and lethal to developing regulatory T cells unless counterbalanced by cytokine survival signals. *Immunity* (2013) 38(6):1116–28. doi: 10.1016/j.immuni.2013.02.022
21. Tai X, Singer A. Basis of treg development in the thymus. *Cell Cycle* (2014) 13(4):501–2. doi: 10.4161/cc.27787
22. Tang M, Jia F, Nan F, Zuo F, Yuan Z, Zhang D. Role of cytokines in thymic regulatory T cell generation: Overview and updates. *Front Immunol* (2022) 13:883560. doi: 10.3389/fimmu.2022.883560
23. Chen F, Wei Z, Yin F, Hao Y, Tang F, Chen Q. Systemic and local changes of regulatory T cells in oral lichen planus. *Oral Dis* (2022) 28(8):2168–71. doi: 10.1111/odi.14031
24. Lewkowicz N, Lewkowicz P, Dzitko K, Kur B, Tarkowski M, Kurnatowska A, et al. Dysfunction of CD4+CD25high T regulatory cells in patients with recurrent aphthous stomatitis. *J Oral Pathol Med* (2008) 37(8):454–61. doi: 10.1111/j.1600-0714.2008.00661.x
25. Zhu Y, Li J, Bai Y, Wang X, Duan N, Jiang H, et al. Hydroxychloroquine decreases the upregulated frequencies of tregs in patients with oral lichen planus. *Clin Oral Investig* (2014) 18(8):1903–11. doi: 10.1007/s00784-013-1176-z
26. Tao XA, Xia J, Chen XB, Wang H, Dai YH, Rhodus NL, et al. FOXP3 T regulatory cells in lesions of oral lichen planus correlated with disease activity. *Oral Dis* (2010) 16(1):76–82. doi: 10.1111/j.1601-0825.2009.01608.x
27. Zhang D, Jin W, Wu R, Li J, Park SA, Tu E, et al. High glucose intake exacerbates autoimmunity through reactive-Oxygen-Species-Mediated TGF-beta cytokine activation. *Immunity* (2019) 51(4):671–81 e5. doi: 10.1016/j.immuni.2019.08.001
28. Konkel JE, Zhang D, Zanvit P, Chia C, Zangarle-Murray T, Jin W, et al. Transforming growth factor-beta signaling in regulatory T cells controls T helper-17 cells and tissue-specific immune responses. *Immunity* (2017) 46(4):660–74. doi: 10.1016/j.immuni.2017.03.015
29. Liu WZ, He MJ, Long L, Mu DL, Xu MS, Xing X, et al. Interferon-gamma and interleukin-4 detected in serum and saliva from patients with oral lichen planus. *Int J Oral Sci* (2014) 6(1):22–6. doi: 10.1038/ijos.2013.74
30. Wang H, Luo Z, Lei L, Sun Z, Zhou M, Dan H, et al. Interaction between oral lichen planus and chronic periodontitis with Th17-associated cytokines in serum. *Inflammation* (2013) 36(3):696–704. doi: 10.1007/s10753-013-9594-2
31. Park JY, Chung H, DiPalma DT, Tai X, Park JH. Immune quiescence in the oral mucosa is maintained by a uniquely large population of highly activated Foxp3 (+) regulatory T cells. *Mucosal Immunol* (2018) 11(4):1092–102. doi: 10.1038/s41385-018-0027-2



OPEN ACCESS

EDITED BY

Junji Xu,
Capital Medical University, China

REVIEWED BY

Debora Heller,
Universidade Cruzeiro do Sul, Brazil
Lei Hu,
Beijing Stomatological Hospital,
Capital Medical University, China

*CORRESPONDENCE

Dayong Liu
dyluiperio@tmu.edu.cn

[†]These authors have contributed
equally to this work

SPECIALTY SECTION

This article was submitted to
Mucosal Immunity,
a section of the journal
Frontiers in Immunology

RECEIVED 16 August 2022

ACCEPTED 13 October 2022

PUBLISHED 31 October 2022

CITATION

Meng Z, Yang T and Liu D (2022)
Type-2 epithelial-mesenchymal
transition in oral mucosal
nonneoplastic diseases.
Front. Immunol. 13:1020768.
doi: 10.3389/fimmu.2022.1020768

COPYRIGHT

© 2022 Meng, Yang and Liu. This is an
open-access article distributed under
the terms of the [Creative Commons
Attribution License \(CC BY\)](#). The use,
distribution or reproduction in other
forums is permitted, provided the
original author(s) and the copyright
owner(s) are credited and that the
original publication in this journal is
cited, in accordance with accepted
academic practice. No use,
distribution or reproduction is
permitted which does not comply with
these terms.

Type-2 epithelial-mesenchymal transition in oral mucosal nonneoplastic diseases

Zhaosong Meng^{1†}, Tianle Yang^{2†} and Dayong Liu^{3*}

¹Department of Oral and Maxillofacial Surgery, Tianjin Medical University Stomatology Hospital, Tianjin, Tianjin, China, ²School of Stomatology, Tianjin Medical University, Tianjin, China,

³Department of Endodontics & Laboratory for Dental Stem Cells and Endocrine Immunology, Tianjin Medical University School of Stomatology, Tianjin, China

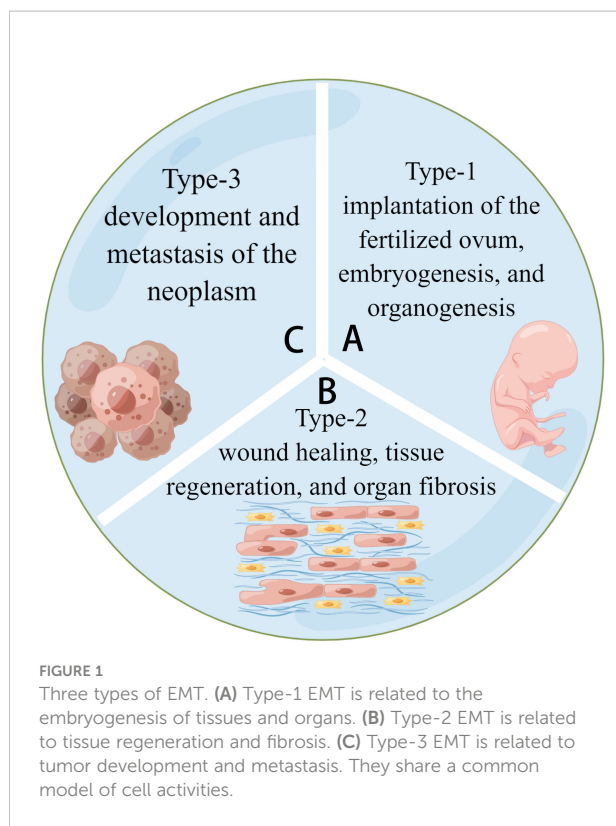
The oral mucosa is a membranous structure comprising epithelial and connective tissue that covers the oral cavity. The oral mucosa is the first immune barrier to protect the body against pathogens for systemic protection. It is frequently exposed to mechanical abrasion, chemical erosion, and pathogenic invasion, resulting in oral mucosal lesions, particularly inflammatory diseases. Epithelial-mesenchymal transition (EMT) is a crucial biological process in the pathogenesis of oral mucosal disorders, which are classified into three types (types 1, 2, and 3) based on their physiological consequences. Among these, type-2 EMT is crucial in wound repair, organ fibrosis, and tissue regeneration. It causes infectious and dis-infectious immunological diseases, such as oral lichen planus (OLP), oral leukoplakia, oral submucosal fibrosis, and other precancerous lesions. However, the mechanism and cognition between type-2 EMT and oral mucosal inflammatory disorders remain unknown. This review first provides a comprehensive evaluation of type-2 EMT in chronically inflammatory oral mucosal disorders. The aim is to lay a foundation for future research and suggest potential treatments.

KEYWORDS

epithelial-mesenchymal transition, craniofacial embryogenesis, oral mucosa alterations, keloid, fibrosis, immunological microenvironment

Introduction

In the 1980s, epithelial-mesenchymal transition (EMT) was identified as a feature of embryogenesis (1). Under different stimuli, epithelial cells lose polarity and cell-cell junctions and thus gain the ability to migrate, transforming into spindle-like mesenchymal cells. The reverse process of EMT is known as a mesenchymal-epithelial transition (MET). Both are crucial biological processes in embryonic development and tissue genesis in the dynamic balance of alteration (2). (Figure 1) Whether EMT or MET describes a process, quasi-mesenchymal cells are a type of transitional cell with



characteristics of both epithelial and mesenchymal cells. Cancer metastasis and invasion have been linked to hybrid cells. They undergo partial EMT and have unique properties such as collective cell migration (3).

EMT is classified into three types based on the biological environment in which it occurs: types 1, 2, and 3. Types 1 and 2

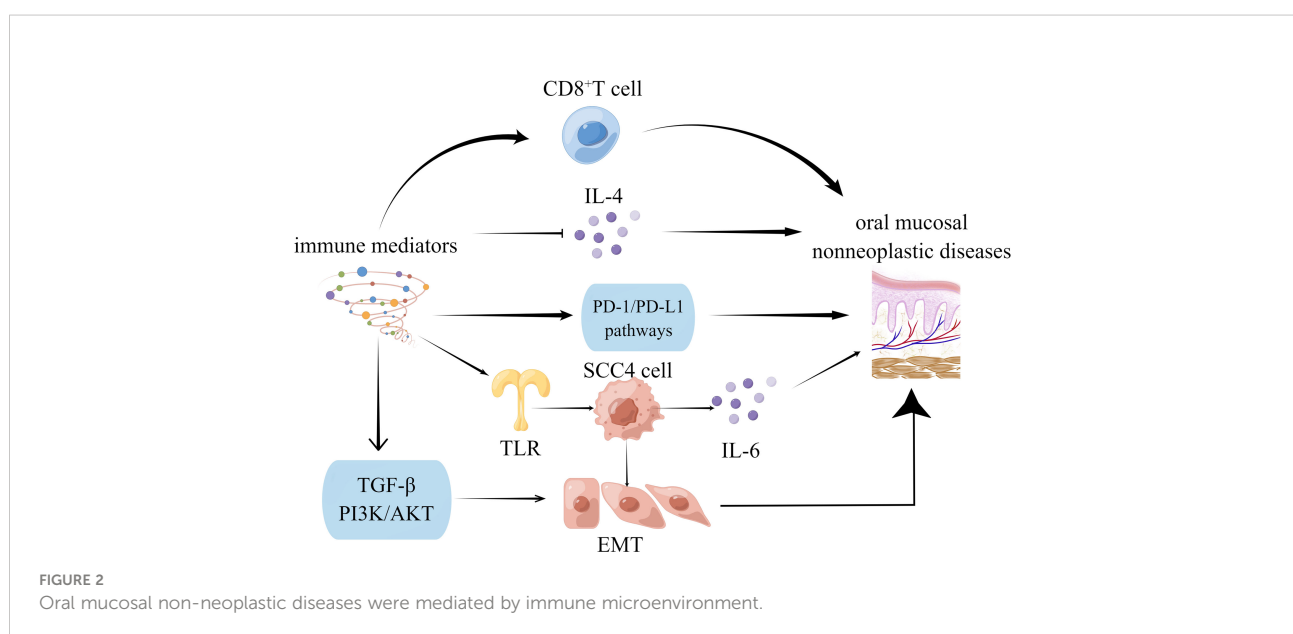
EMTs are associated with embryonic, regenerative, and pathological processes, respectively, with no abnormal cell proliferation (4, 5). Type-3 EMT is critical for tumor development and metastasis because it allows cancerous cells to generate, develop, and spread (6). (See Figure 2) Most current research focuses on Type-3 EMT, which is responsible for tumor genesis. However, types 1 and 2 EMTs have received little attention. Types 1 and 2 EMTs conclude the biological development of craniofacial tissues and organs from birth and the pathological processes of abnormal transition after the individual fully develops.

Fibrosis of the oral mucosa occurs in the inflammatory microenvironment of type-2 EMT. The immune microenvironment regulates cytokines and molecules in some signaling pathways, and the mechanisms are systematically generalized. Scientists have worked on EMT to treat degenerative diseases, repair injuries, rebuild tissue and organs, and delay senescence (7).

This review summarized the function and mechanism of type-1 and type-2 EMTs in oral mucosal nonneoplastic diseases. We proposed potential therapies for EMT-related diseases to lay a foundation for future clinical use in stomatology.

Type-2 EMT in oral mucosa

The oral cavity is protected by oral mucosa, primarily squamous epithelium, an immune system component. This review highlighted the oral mucosa as the human body's immune barrier to defend against pathogens for systematic protection. Innate and adaptive immunity combine to form oral mucosal immunity. The former includes the physical barrier of mucosal epithelium, which excretes defensin, interleukin (IL)-8, and tumor necrosis factor- α (TNF- α); the



normal flora, which alters the surrounding environment to inhibit the growth of potential pathogens; and the innate immune cells such as dendritic, Langerhans, and mast cells. The latter is known as the Mucosal Immune System (MIS). It produces secretory IgA in the Waldeyer's ring and connects the inducer and effector sites *via* cell homing. MIS is involved in the local adaptive immune response and can cause mucosal cytotoxicity.

Type-2 EMT occurs in wound healing, tissue regeneration, and organ fibrosis and may result in keloids in the repair of the human epithelium in the inflammatory microenvironment. In the oral mucosa, it has been reported that simple wound healing causes no scar, which differs from the skin (8). However, certain microbiomes and tobacco and alcohol use can cause the pathological formation of fibrosis and keloids in the oral mucosa *via* EMT, which may delay the ultimate healing of the oral mucosa. There is ample space for further investigation in this area, the details of which remain unknown.

EMT in oral mucosal wound repair and regeneration

When a wound occurs, the skin and mucosa go through hemostasis, inflammation, proliferation, and remodeling. Granulation tissue forms in the inflammatory microenvironment and then progresses to the proliferation stage, where keratinocytes and fibroblasts migrate to the wound bed. The former is in charge of barrier reconstruction, while the latter is in charge of secreting extracellular matrix and remodeling granulation tissue (9).

Oral health has long been closely linked to systemic health but has received little attention. The oral cavity, located at the beginning of the human digestive tract, is critical for mastication, digestion, pronunciation, and aesthetics. Even though the oral mucosa is often exposed to mechanical abrasion and tension, it heals much faster with less scarring than the skin (10). The reason might be that oral mucosal fibroblasts and dermal fibroblasts have different cell behaviors and responses to growth factors. When exposed to transforming growth factor- β (TGF- β 1), oral mucosal fibroblasts have a higher average proliferation rate, a lower shrinkage capacity, and synthesize more collagen (11).

Type-2 EMT is an after-birth reactivation recognized as a way to control inflammation and tissue regeneration. In recent decades, scientists have committed to identifying the factors initiating EMT. One explanation for the phenomenon is that in acute and mild trauma, wounded epithelial cells differentiate into fibroblast-like cells to reproduce tissues and organs, which is a reparative biological process (6). However, in the case of long-term continuing inflammation, the keloid is considered pathological fibrosis. It ceases once the repair is completed (12). The interaction between TGF- β 1 and pro-inflammatory cytokines can generate a microenvironment for autoregulatory

loops to strengthen the EMT. Polyriboinosinic: polyribocytidylic acid (Poly (I: C)) has been shown to accelerate collective HaCaT cell migration *via* autocrine/paracrine IL-8 secretions and EMT (13). It promotes leukocyte accumulation and improves chemokine expression during wound healing (14). Poly I: C induced IL-8 production by keratinocytes by stimulating Toll-like receptor 3 (TLR3), and TLR3 is a component of wound healing in regulating inflammation, during which NF- κ B is activated (15). Poly I: C can stimulate EMT and improve wound healing (16). Interestingly, it has also been found that excessive poly I: C stimulation contributes to delayed wound healing (17). The complicated mechanisms of the double effect of Poly I: C remain to be investigated further. Another explanation for activating EMT during a wound in the mucosa is that the loss of apical-basal polarity can initiate the transition. It has been demonstrated that normal apical-basal cell polarity inhibits EMT *via* SNAIL degradation mediated by the PAR complex (18). This points to the potential role of the cell-cell junction in regulating EMT.

EMT with oral mucosal dis-infectious diseases

Pathological processes associated with type 2 EMT include abnormal metastasis, keloid formation, and fibrosis. Scientists have reported the formation of keloids related to TGF- β 1, EGF, and fibroblast growth factor (FGF) signaling pathways (19). Keratinocytes and fibroblasts influence the keloid and fibrosis of abnormal tissue, causing oral leukoplakia (OLK) or oral submucous fibrosis (20). Fibrosis has also been linked to inflammation.

Oral leukoplakia (OLK) is the most common underlying precancerous lesion and potentially malignant disorder (21). EMT can cause OLK to progress into oral squamous cell carcinoma (OSCC), linked to smoking (22) and chewing tobacco (23). It has been observed that in non-smokers, OLK occurs in conjunction with an immunosuppressive microenvironment established by activation of the PD-1/PD-L1 pathway and recruitment of CD163+ tumor-associated macrophages (TAMs), which may function in the early and transforming stages of oral tumorigenesis. The findings demonstrate that EGFR and WNT pathway proteins are overexpressed in all OLK samples, triggered by chewing tobacco, and may be a risk factor for the type of proliferation. Remarkably, the lncRNA oral leukoplakia progressed associated 1 (LOLA1) has been found to promote oral mucosa epithelial migration, invasion, and EMT *via* the AKT/GSK-3 β pathway, thereby accelerating the progression of OLK (24). Elevated levels of some novel biomarkers, such as Snail and Axin2, with a high correlation to OLK malignant transformation, can predict oral tumorigenesis (25).

Oral submucous fibrosis (OSF) develops in a constant pro-inflammatory environment and has the characteristics of tissue

fibrosis and degeneration diseases in various tissues and organs (26). Patients with OSF have difficulty opening their mouths and have stiff oral mucosa. It is caused by EMT, which causes oral submucous fibrosis (27). Arecoline is known as the pathogenic factor of OSF and has been shown to increase Twist expression (28). Chewing areca causes microtrauma and activates a protective inflammatory response, releasing many growth factors such as TGF- β , platelet-derived growth factor, basic FGF, and cytokines such as IL-6 and TNF- α , which promote fibrosis (29). Hinokitiol has been shown to downregulate Snail, lowering α -SMA expression and myofibroblast properties as an anti-fibrosis agent (30).

The World Health Organization classifies OLP as a premalignant chronic inflammatory disease mediated by T-lymphocytes. Smad 3 expression in OLP is higher and statistically significant than in normal oral mucosa, consistent with apoptosis, inflammation, and EMT functions (31, 32). It has also been reported that in OLP, claudin-1, claudin-4, and E-cadherin are downregulated, disrupting the epithelial barrier and causing T-lymphocytes to migrate into epithelial cells (33). Furthermore, OLP liquefaction degeneration is an EMT result primarily induced by IFN- γ , which can improve the malignant transition (34). The current studies also illustrated that the submucosal infiltration of T and B lymphocytes is more distinct in OLP than in OLK, and the immunological response is also stronger in OLP (35).

EMT with oral mucosal infectious diseases

The oral cavity is a huge reservoir for microorganisms to grow, develop and manipulate. Millions of viruses, bacteria, and fungi colonize the mucosa epithelium forming a balanced biofilm. Once the equilibrium is disrupted, opportunistic pathogens take over and cause continuous inflammatory reactions. Oral microbiota has been found to manipulate cell migration by modulating the EMT process in such an inflammatory microenvironment. Microbiota degrades epithelial tight junction proteins, improves mesenchymal properties, and induces partial or complete EMT (36). It is frequently associated with oral mucosa infectious diseases such as gingivitis, oral candidiasis, herpes, and others. Pathogens in the oral cavity cause disease *via* different regulatory mechanisms of the EMT.

Porphyromonas gingivalis (*P. gingivalis*) degrades E-cadherin to regulate the epithelial function of the barrier (37). *NNMT*, *CCAT1*, and *GAS6* genes are involved in cell migration and invasion. These gene's messenger RNA (mRNA) levels are high in *P. gingivalis*-infected oral epithelial cells (38). It also modulates the β -catenin pathway and uncouples the β -catenin destruction complex in gingival epithelial cells, facilitating

nuclear translocation to activate TCF/LEF promoter elements in the following step (39).

Streptococcus gordonii suppresses FOXO1 and activates the TAK1-NLK negative regulatory pathway for ZEB2 induction resistance (40). Upregulation of partial EMT genes has been observed in *Fusobacterium nucleatum*-infected OSCC cells (41). The signal transducer and activator of the transcription-3 signaling pathway is activated, increasing the expression of EMT-associated genes such as *E-cadherin*, *Snail*, and *Twist*. The EMT has been widely debated over the years, particularly its role in cancer progression. However, the significance of EMT in embryogenesis, tissue regeneration, and fibrosis is rarely discussed. This review discusses the types 1 and 2 EMTs in craniofacial tissues and organs. Related disorders such as palatal cleft, dental defect, OLK, and OSF are also evaluated. There remains a long way to go to reduce the negative effects of EMT, such as the formation of keloid and fibrosis and the facilitation of neoplasm to provide theoretical support for the following research and applications of types 1 and 2 EMTs so that experimental trials of EMT can be used in the clinic and theoretical knowledge can transform from bench to bedside. Certain bacteria, lower PH, signaling molecules, loss of apical-basal polarity, and other approaches have been used to activate EMT. The EMT process, particularly type-2 EMT, strongly correlates with inflammation regulated by the immunological microenvironment. However, there remains a long way to go before determining the complete blueprint of the crosstalk among various cytokines and signaling pathways. As previously stated, we have concluded complicated mechanisms of types 1 and 2 EMTs. Many details of regulation and alteration remain unknown. It may be important for researchers to investigate the differential expression of cytokines and signaling pathways during both biological and pathological processes of EMT activities (Table 1).

EMT with immune regulation of the oral mucosa

Oral mucosal disease, particularly oral mucosal precancerous lesions, has been linked to changes in the immune microenvironment. The infiltration of high-grade CD8+ lymphocytes within the epithelium was linked to increased remission rates (43). Intraepithelial CD8+ lymphocytes are likely to serve as a biomarker of remission and a potential area of biomedical research regarding OLP's etiology and premalignant potential. The host immune system may bypass PD-L1-expressing dysplastic epithelial and recruited subepithelial cells in oral precancerous lesions. Furthermore, by inhibiting the PD-1/PD-L1 pathways, oral precancerous lesions can be prevented from transforming into cancer, and advanced cancer can be treated (44). According to previous research, OLP

TABLE 1 The mechanisms of Type-2 EMT in biological and pathological processes.

Type-2 EMT		Relative Cytokines	Signaling Pathways
Wound repair and tissue regeneration		TGF- β 1 (11), pro-inflammatory cytokines (13), IL-8 (13), SNAI1 (18)	NF- κ B (15), TGF- β (11)
Dis-infectious diseases	OLK	CD163+ TAMs (22, 23), lncRNA LOLA1 (24), Snail (25), Axin2 (25)	TGF- β 1, EGF (19), FGF (19), PD-1/PD-L1 (22, 23), WNT (42), AKT/GSK-3 β (24)
	OSF	Twist (28), TGF- β (29), TNF- α (29), PDGF (29), bFGF (29), IL-6 (29), Snail (30), α -SMA (30)	
	OLP	IFN- γ (34), Smad3 (31, 32), claudin-1 (33), claudin-4 (33), E-cadherin (33)	
Infectious diseases	P. gingivalis	NNMT (38), CCAT1 and GAS6 (38), TCF/LEF promoter (39), E-cadherin (41), Snail (41), Twist (41)	β -catenin (39)
	S. gordonii		FOXO1 (40), TAK1-NLK negative regulatory pathway (40)
	F. nucleatum		STAT3 (41)

lesions are caused by IL-4, which is produced by several factors. It also affects various cells, resulting in OLP lesions (45).

Immune mediators are not only directly linked to precancerous lesions, but they are also indirectly mediated by EMT. It has been reported that activated oncogenic Ras post-transcriptionally enhances premalignant cell mutations, intensifying malignancy and cell invasion. There is a significant change in mRNA levels, which correlates with protein abundance and is consistent with EMT. These proteins also changed following Ras transformation, suggesting that premalignant cells were primed to become malignant. Therefore, Ras-induced EMT-associated invasion in primed premalignant cells *via* post-transcriptional mechanisms (46). SCC-4 cells synthesize and release IL-6 independently, a process aided by TLR2/TLR6 agonists. In contrast to precancerous human tongue DOK cells, cancerous tongue SCC-4 cells exhibit a classic EMT profile (47). Beyond their immune function, CD4+ T cells are abundant in the dense stroma surrounding ductal epithelium in CP tissues associated with EMT. CD4+ T cells can induce EMT in premalignant cells (48). EMT is also facilitated by abnormal immune mediator expression in precancerous lesions. T cell dysfunction (49) or genetic changes (50) also contributes to developing immunosuppressive microenvironments during the malignant transformation of the oral mucosa by inducing EMT. The TGF- β (51) and PI3K-AKT (19) signaling pathways are critical in this transformation.

Prospect

EMT is a common physiological process during embryogenesis, wound healing, fibrosis, tumorigenesis, and cancer metastasis. It has been artificially divided into three types based on different biological backgrounds, but the boundaries are not always clear. It is recommended to command the differential

expressions of EMT in various situations to regulate the microenvironment to maintain equilibrium. EMT has applications in tissue regeneration and fibrosis inhibition, and we propose prospects. Concerning tooth tissue regeneration, two types of cells are indispensable: epithelial stem cells and mesenchymal stem cells (MSCs). They interact with and transform into one another under certain conditions. In dental tissue engineering, epithelial stem cells are primarily derived from embryonic tooth epithelium, while MSCs are derived from tooth germ and bone marrow stem cells.

EMT and traditional approaches to tissue engineering

The interaction between seed cells, scaffold materials, and the microenvironment is central to current tissue engineering. Wang et al. invented the new concept of bio-root and saw it through to completion (52). Fruitful research on tooth regeneration has been published in the last few decades (53), and it is attractive to realize the clinical transformation of bio-root. However, common cell culture approaches are somewhat complicated for incorporating both epithelial stem cells and MSCs into the regenerative system, and increasing the workload. As a result, an EMT-induced culture system might be advantageous. Only one type of seed cell is added, and another type can be transferred from the original one *via* the regulation of cytokines and other signaling pathways. This method simplifies the operation and may provide a solution to the cell source shortage.

Recent studies on EMT have demonstrated that three-dimensional models can better simulate the extracellular matrix microenvironment, improve cell vitality, and reduce mortality than two-dimensional models, particularly for cartilage formation (54). The hydrogel is a porous, jelly-like structure that provides a biocompatible and non-toxic

environment for cell growth, differentiation, and proliferation. It creates an environment for EMT/MET to occur by containing specific biomarkers and nutrient materials. The biocompatibility and histocompatibility of the ECM-derived hydrogel are higher (55). TGF- β 1 induces EMT within the three-dimensional system for the decreased epithelial markers (E-cadherin), increased mesenchymal markers (Vimentin and α -SMA), and enhanced migratory and invasion capacity (56). (Figure 3) Furthermore, the treated dentin matrix, hyaluronic acid, PCL, and ceramics are widely used; they can be chosen during various tissue engineering study processes involving EMT (57–61).

However, the use of EMT in traditional tissue engineering is restricted by a lack of experimental conditions, unknown mechanisms, and operating techniques. Moreover, the condition of unclear regulation can contribute to tumor genesis and make the process uncontrollable. There remains much work to be done before we can put these considerations into practice.

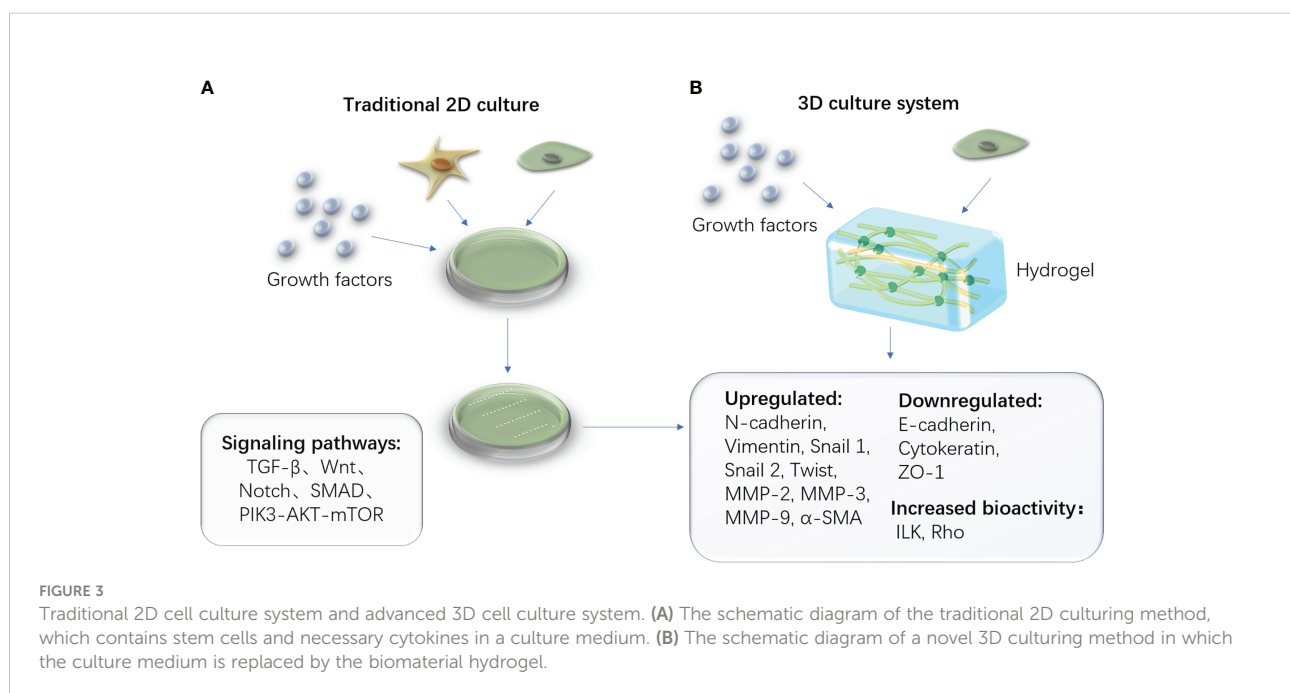
EMT in developmental biological regeneration

Unlike traditional tissue engineering, biological regeneration eliminates exogenous scaffolds and stimulates the organism's regrowth. It is safer, easier, and has fewer side effects (62). On the other hand, the high demands for immunological microenvironments pose challenges. Bacterial pathogens, acid microenvironment, growth factors, proteins of primary signaling pathways, loss of apical-basal polarity, hypoxia, and other factors

have all been implicated in the activation of EMT (18, 63–65). For instance, during long-term infection with the opportunistic pathogen *P. gingivalis*, human primary epithelial cells develop an EMT phenotype (66). Anaerobic periodontal pathogens have been shown to induce EMT in primary oral keratinocytes, destroying the periodontal barrier and contributing to periodontitis (63). EMT-associated transcription factors such as Slug, Snail, and Zeb1 showed significant increases in response to pathogen exposure. The treatment of EMT-related oral diseases may benefit from focusing on critical factors. The key to successful regeneration is determining how to precisely control these variables.

Coffee and EMT research has also received widespread attention. Coffee components can reverse EMT transitions or even rescue the functions of EMT inducers. For instance, Trigonelline extracted from natural coffee beans reduces renal fibrosis by inhibiting EMT (67). Chlorogenic acid derived from coffee has antitumor and anti-metastatic properties by interfering with the NF- κ B/EMT signaling pathway (68). They exert pharmacological functions as EMT inhibitors, but more studies for clinical transformation are needed. Furthermore, because low PH promotes EMT, an alkaline diet and anti-acid drugs may effectively prevent EMT in the craniofacial tissues and organs (64).

Different signaling pathways and molecules regulate EMT in various biological or pathological processes. As a result, additional research into the individual mechanisms of each process is required to achieve precise control. Otherwise, it is considering how to find a balance between promoting practical functions and maintaining cell vitality. We are now at tipping in



combining EMT and tissue engineering. They mutually aid in the advancement of regenerative medicine. The multi-discipline study is now the mainstream of research and has a promising future (69).

Methods of preventing dysfibrosis

It is challenging to reduce the negative effects of dysfibrosis and keloids. As previously elucidated, oral mucosa has less keloid and fibrosis and heals wounds faster than the skin. The mechanisms of improved mucosal quality are primarily concluded as follows (9, 10): 1. Fewer pro-inflammatory factors and less inflammatory response; 2. Reduced recruitment of neutrophils, macrophages, and T cells after injury; 3. Certain microorganisms activate the immune system for wound healing cascade; 4. the suitable environment of saliva, which provides a biomimetic idea of hydrogel, applies to skin healing to accelerate the process (70). By inhibiting EMT, we may be able to design a type of epithelium with high regenerative capacity and self-repair without many keloids in the future.

The anti-EMT mainstream of reducing fibrosis during tissue regeneration or OSF (71). One solution is to improve EMT inhibitors such as phosphatase and tensin homolog, which inhibits the PI3K/AKT pathway to reduce hypertrophic scar fibroblast proliferation and eliminate keloid and fibrotic scars (72).

Another option is to use MSCs, which have anti-fibrotic, anti-oxidative, and angiogenesis properties, indicating that the cell is an ideal anti-fibrotic target. The functioning mechanism is attributed to inhibiting the TGF- β 1 pathway via N-cadherin and vimentin downregulation (73, 74). MSCs are produced from epithelial cells through the continuous process of EMT. They have significantly higher levels of expression of several biomarkers, including CD105, CD73, and CD90 (75). Specific induction causes MSCs to differentiate into osteoblasts, adipocytes, and chondrocytes, differentiating into dental pulp stem cells (DPSCs), dental follicle stem cells (DFSCs), periodontal ligament stem cells (PDLSCs), and others. As a result, EMT serves as a unique source of seed cells for tissue regeneration.

MSCs are also critical in halting the process of OSF for immunomodulatory, anti-fibrotic, anti-oxidative, and angiogenic functions. Areca chewing can increase pro-inflammatory cytokines such as TNF- α and IL-6 in response to the microtrauma it causes, thereby promoting fibrosis progression (29). MSCs also suppress TNF- α expression via IL-10 secretion and downregulate TNF- α and IL-6 by inhibiting IFN- γ expression (76). MSCs also suppress the TGF- β pathway by secreting hepatocyte growth factor and TNF-stimulated gene 6 protein, which restores the TGF- β 1/TGF- β 3 balance for anti-fibrotic microenvironment production (77).

In this review, we present our expectations that in the future, we can apply EMT to regenerative medicine with or without scaffolding materials for profound progress in the following research. We owe the huge leap in the basic study of EMT to the progress made in the past few years. EMT significantly impact on scientific research and clinical transformation once the functional mechanisms are identified. We anticipate developing novel medicines for the treatment of EMT-related diseases in stomatology such as developmental malformation, wound repair, keloid and fibrosis, and other oral mucosa pathological alterations in the future.

Author contributions

ZM, and TY wrote this manuscript. DL revised this manuscript. All authors contributed to the article and approved the submitted version.

Funding

This research was funded by Tianjin Municipal Science and Technology Foundation grant number 21JCQNJC01190 and Tianjin Health Science and Technology Project grant number KJ20081. This research was also supported by the National Natural Science Foundation of China (82071079 to Dayong Liu)

Acknowledgments

Authors thank the *Bullet Edits* for revising the English language. Authors also thank *Figdraw* of *Home for Researchers*, which supported Figures drawing.

Conflict of interest

The authors declare that the research was conducted in the absence of any commercial or financial relationships that could be construed as a potential conflict of interest.

Publisher's note

All claims expressed in this article are solely those of the authors and do not necessarily represent those of their affiliated organizations, or those of the publisher, the editors and the reviewers. Any product that may be evaluated in this article, or claim that may be made by its manufacturer, is not guaranteed or endorsed by the publisher.

References

- Greenburg G, Hay ED. Epithelia suspended in collagen gels can lose polarity and express characteristics of migrating mesenchymal cells. *J Cell Biol* (1982) 95(1):333–9. doi: 10.1083/jcb.95.1.333
- Haensel D, Dai X. Epithelial-to-mesenchymal transition in cutaneous wound healing: Where we are and where we are heading. *Dev dynamics: an Off Publ Am Assoc Anatom* (2018) 247(3):473–80. doi: 10.1002/dvdy.24561
- Liao T-T, Yang M-H. Hybrid Epithelial/Mesenchymal state in cancer metastasis: Clinical significance and regulatory mechanisms. *Cells* (2020) 9(3):623. doi: 10.3390/cells9030623
- Zavadi J, Haley J, Kalluri R, Muthuswamy SK, Thompson E. Epithelial-mesenchymal transition. *Cancer Res* (2008) 68(23):9574–7. doi: 10.1158/0008-5472.CAN-08-2316
- Kalluri R, Weinberg RA. The basics of epithelial-mesenchymal transition. *J Clin Invest* (2009) 119(6):1420–8. doi: 10.1172/JCI39104
- Marconi GD, Fonticoli L, Rajan TS, Pierdomenico SD, Trubiani O, Pizzicannella J, et al. Epithelial-mesenchymal transition (EMT): The type-2 EMT in wound healing, tissue regeneration and organ fibrosis. *Cells* (2021) 10(7):1587. doi: 10.3390/cells10071587
- Thiery JP, Acloque H, Huang RYJ, Nieto MA. Epithelial-mesenchymal transitions in development and disease. *Cell* (2009) 139(5):871–90. doi: 10.1016/j.cell.2009.11.007
- Leavitt T, Hu MS, Marshall CD, Barnes LA, Lorenz HP, Longaker MT. Scarless wound healing: finding the right cells and signals. *Cell Tissue Res* (2016) 365(3):483–93. doi: 10.1007/s00441-016-2424-8
- Nikoloudaki G, Creber K, Hamilton DW. Wound healing and fibrosis: a contrasting role for periostin in skin and the oral mucosa. *Am J Physiol Cell Physiol* (2020) 318(6):C1065–C77. doi: 10.1152/ajpcell.00035.2020
- Waasdorp M, Krom BP, Bikker FJ, van Zijl PPM, Niessen FB, Gibbs S. The bigger picture: Why oral mucosa heals better than skin. *Biomolecules* (2021) 11(8):1161. doi: 10.3390/biom11081165
- Lee HG, Eun HC. Differences between fibroblasts cultured from oral mucosa and normal skin: implication to wound healing. *J Dermatol Sci* (1999) 21(3):176–82. doi: 10.1016/S0923-1811(99)00037-7
- López-Novoa JM, Nieto MA. Inflammation and EMT: An alliance towards organ fibrosis and cancer progression. *EMBO Mol Med* (2009) 1(6–7):303–14. doi: 10.1002/emmm.200900043
- Takada K, Komine-Aizawa S, Hirohata N, Trinh QD, Nishina A, Kimura H, et al. Poly I:C induces collective migration of HaCaT keratinocytes via IL-8. *BMC Immunol* (2017) 18(1):19. doi: 10.1186/s12865-017-0202-3
- Lin Q, Wang L, Lin Y, Liu X, Ren X, Wen S, et al. Toll-like receptor 3 ligand polyinosinic-polycytidylic acid promotes wound healing in human and murine skin. *J Invest Dermatol* (2012) 132(8):2085–92. doi: 10.1038/jid.2012.120
- Kawai T, Akira S. Toll-like receptor downstream signaling. *Arthritis Res Ther* (2005) 7(1):12–9. doi: 10.1186/ar1469
- Harada K, Sato Y, Ikeda H, Isse K, Ozaki S, Enomae M, et al. Epithelial-mesenchymal transition induced by biliary innate immunity contributes to the sclerosing cholangiopathy of biliary atresia. *J pathol* (2009) 217(5):654–64. doi: 10.1002/path.2488
- Grimstad O, Husebye H, Espevik T. TLR3 mediates release of IL-1 β and cell death in keratinocytes in a caspase-4 dependent manner. *J Dermatol Sci* (2013) 72(1):45–53. doi: 10.1016/j.jdermsci.2013.05.006
- Jung HY FL, Tsai JH, Kajimoto T, Chang Q, Newton AC, Yang J. Apical-basal polarity inhibits epithelial-mesenchymal transition and tumour metastasis by PAR-complex-mediated SNAI1 degradation. *Nat Cell Biol* (2019) 21(3):359–71. doi: 10.1038/s41556-019-0291-8
- Shetty SS, Sharma M, Fonseca FP, Jayaram P, Tanwar AS, Kabekkodu SP, et al. Signaling pathways promoting epithelial mesenchymal transition in oral submucous fibrosis and oral squamous cell carcinoma. *Jpn Dent Sci Rev* (2020) 56(1):97–108. doi: 10.1016/j.jdsr.2020.07.002
- Hahn JM, Glaser K, McFarland KL, Aronow BJ, Boyce ST, Supp DM. Keloid-derived keratinocytes exhibit an abnormal gene expression profile consistent with a distinct causal role in keloid pathology. *Wound Repair Regen* (2013) 21(4):530–44. doi: 10.1111/wrr.12060
- Lv Z, Cong R, Li J, Cao K, Bao Q, Li L, et al. PTHLH predicts the prognosis of patients with oral leukoplakia. *Oncotargets Ther* (2020) 13:10013–23. doi: 10.2147/OTT.S261124
- Teh M-T, Yagyu T, Funayama N, Imada M, Kirita T. Effect of smoking status and programmed death-ligand 1 expression on the microenvironment and malignant transformation of oral leukoplakia: A retrospective cohort study. *PLoS One* (2021) 16(4):e0250359. doi: 10.1371/journal.pone.0250359
- Bhattacharyya S, Ray S, Saha D, Mustafi SM, Alam N, Sarkar A, et al. Chewing tobacco may act as a risk factor for dysplastic transformation of squamous cells in oral leukoplakia- a cytochemistry based approach. *Pathol - Res Pract* (2021) 218:153287. doi: 10.1016/j.prp.2020.153287
- Liu W, Yao Y, Shi L, Tang G, Wu L. A novel lncRNA LOLA1 may predict malignant progression and promote migration, invasion, and EMT of oral leukoplakia via the AKT/GSK-3 β pathway. *J Cell Biochem* (2021) 122(10):1302–12. doi: 10.1002/jcb.29951
- Zhang X, Kim KY, Zheng Z, Kim HS, Cha IH, Yook JI. Snail and Axin2 expression predict the malignant transformation of oral leukoplakia. *Oral Oncol* (2017) 73:48–55. doi: 10.1016/j.oraloncology.2017.08.004
- Kheur S, Sanap A, Kharat A, Gupta AA, Raj AT, Kheur M, et al. Hypothesizing the therapeutic potential of mesenchymal stem cells in oral submucous fibrosis. *Med Hypotheses* (2020) 144:110204. doi: 10.1016/j.mehy.2020.110204
- Lien K, Mayer W, Herrera R, Roske K, Tugizov SM. HIV-1 proteins gp120 and tat induce the epithelial-mesenchymal transition in oral and genital mucosal epithelial cells. *PLoS One* (2019) 14(12):e0226343. doi: 10.1371/journal.pone.0226343
- Lee Y-H, Yang L-C, Hu F-W, Peng C-Y, Yu C-H, Yu C-C. Elevation of twist expression by arecoline contributes to the pathogenesis of oral submucous fibrosis. *J Formosan Med Assoc* (2016) 115(5):311–7. doi: 10.1016/j.jfma.2015.05.009
- Rajalalitha P, Vali S. Molecular pathogenesis of oral submucous fibrosis—a collagen metabolic disorder. *J Oral Pathol Med* (2005) 34(6):321–8. doi: 10.1111/j.1600-0714.2005.00325.x
- Yang HW, Lu MY, Chiu YW, Liao YW, Huang YF, Ju Chueh P, et al. Hinokitiol ablates myofibroblast activation in precancerous oral submucous fibrosis by targeting snail. *Environ Toxicol* (2018) 33(4):454–62. doi: 10.1002/tox.22531
- Karatsaidis A, Schreurs O, Axéll T, Helgeland K, Schenck K. Inhibition of the transforming growth factor- β /Smad signaling pathway in the epithelium of oral lichen. *J Invest Dermatol* (2003) 121(6):1283–90. doi: 10.1046/j.1523-1747.2003.12633.x
- Danielsson K, Wahlin YB, Coates PJ, Nylander K. Increased expression of smad proteins, and in particular Smad3, in oral lichen planus compared to normal oral mucosa. *J Oral Pathol Med* (2010) 39(8):639–44. doi: 10.1111/j.1600-0714.2010.00902.x
- Hamalainen L, Soini Y, Pasonen-Seppanen S, Siponen M. Alterations in the expression of EMT-related proteins claudin-1, claudin-4 and claudin-7, e-cadherin, TWIST1 and ZEB1 in oral lichen planus. *J Oral Pathol Med* (2019) 48(8):735–44. doi: 10.1111/jop.12917
- Liu Y, Liu G, Liu Q, Tan J, Hu X, Wang J, et al. The cellular character of liquefaction degeneration in oral lichen planus and the role of interferon gamma. *J Oral Pathol Med* (2017) 46(10):1015–22. doi: 10.1111/jop.12595
- Dafar A, Siarov A, Mostaghimi Y, Robledo-Sierra J, De Lara S, Giglio D, et al. Langerhans cells, T cells, and b cells in oral lichen planus and oral leukoplakia. *Int J Dent* (2022) 2022:5430309. doi: 10.1155/2022/5430309
- Bai H, Yang J, Meng S, Liu C. Oral microbiota-driven cell migration in carcinogenesis and metastasis. *Front Cell Infect Microbiol* (2022) 12:864479. doi: 10.3389/fcimb.2022.864479
- Abdulkareem AA, Shelton RM, Landini G, Cooper PR, Milward MR. Periodontal pathogens promote epithelial-mesenchymal transition in oral squamous carcinoma cells in vitro. *Cell Adh Migr* (2018) 12(2):127–37. doi: 10.1080/19336918.2017.1322253
- Geng F, Liu J, Guo Y, Li C, Wang H, Wang H, et al. Persistent exposure to porphyromonas gingivalis promotes proliferative and invasion capabilities, and tumorigenic properties of human immortalized oral epithelial cells. *Front Cell Infect Microbiol* (2017) 7:57. doi: 10.3389/fcimb.2017.00057
- Zhou Y, Sztukowska M, Wang Q, Inaba H, Potempa J, Scott DA, et al. Noncanonical activation of beta-catenin by porphyromonas gingivalis. *Infect Immun* (2015) 83(8):3195–203. doi: 10.1128/IAI.00302-15
- Ohshima J, Wang Q, Fitzsimonds ZR, Miller DP, Sztukowska MN, Jung YJ, et al. Streptococcus gordonii programs epithelial cells to resist ZEB2 induction by porphyromonas gingivalis. *Proc Natl Acad Sci United States America* (2019) 116(17):8544–53. doi: 10.1073/pnas.1900101116
- Shao W, Fujiwara N, Mouri Y, Kisoda S, Yoshida K, Yoshida K, et al. Conversion from epithelial to partial-EMT phenotype by fusobacterium nucleatum infection promotes invasion of oral cancer cells. *Sci Rep* (2021) 11(1):14943. doi: 10.1038/s41598-021-94384-1
- Yin X, Li J, Salmon B, Huang L, Lim WH, Liu B, et al. Wnt Signaling and Its Contribution to Craniofacial Tissue Homeostasis. *J Dent Res* (2015) 94(11):1487–94. doi: 10.1177/0022034515599772
- Enomoto A, Sato E, Yasuda T, Isomura T, Nagao T, Chikazu D. Intraepithelial CD8+ lymphocytes as a predictive diagnostic biomarker for the remission of oral lichen planus. *Hum pathol* (2018) 74:43–53. doi: 10.1016/j.humpath.2017.12.008

44. Yagyu T, Hatakeyama K, Imada M, Kurihara M, Matsusue Y, Yamamoto K, et al. Programmed death ligand 1 (PD-L1) expression and tumor microenvironment: Implications for patients with oral precancerous lesions. *Oral Oncol* (2017) 68:36–43. doi: 10.1016/j.oraloncology.2017.03.006
45. Mehrbani SP, Motahari P, Azar FP, Ahari MA. Role of interleukin-4 in pathogenesis of oral lichen planus: A systematic review. *Med Oral Patol Oral Cir Bucal* (2020) 25(3):e410–e5. doi: 10.4317/medoral.23460
46. Bisogno LS, Friedersdorf MB, Keene JD. Ras post-transcriptionally enhances a pre-malignantly primed EMT to promote invasion. *iScience* (2018) 4:97–108. doi: 10.1016/j.isci.2018.05.011
47. Karavayraki M, Porter RK. Evidence of a role for interleukin-6 in anoikis resistance in oral squamous cell carcinoma. *Med Oncol* (2022) 39(5):60. doi: 10.1007/s12032-022-01664-5
48. Goebel L, Grage-Griebenow E, Gorys A, Helm O, Genrich G, Lenk L, et al. CD4(+) T cells potently induce epithelial-mesenchymal-transition in premalignant and malignant pancreatic ductal epithelial cells-novel implications of CD4(+) T cells in pancreatic cancer development. *Oncoimmunology* (2015) 4(4):e1000083. doi: 10.1080/2162402X.2014.1000083
49. Wen L, Lu H, Li Q, Li Q, Wen S, Wang D, et al. Contributions of T cell dysfunction to the resistance against anti-PD-1 therapy in oral carcinogenesis. *J Exp Clin Cancer Res* (2019) 38(1):299. doi: 10.1186/s13046-019-1185-0
50. Rangel R, Pickering CR, Sikora AG, Spiotto MT. Genetic changes driving immunosuppressive microenvironments in oral premalignancy. *Front Immunol* (2022) 13:840923. doi: 10.3389/fimmu.2022.840923
51. Hao Y, Baker D, Ten Dijke P. TGF-beta-Mediated epithelial-mesenchymal transition and cancer metastasis. *Int J Mol Sci* (2019) 20(11):E2767. doi: 10.3390/ijms20112767
52. Wang S, Liu Y, Fang D, Shi S. The miniature pig: a useful large animal model for dental and orofacial research. *Oral Dis* (2007) 13(6):530–7. doi: 10.1111/j.1601-0825.2006.01337.x
53. Yang X, Ma Y, Guo W, Yang B, Tian W. Stem cells from human exfoliated deciduous teeth as an alternative cell source in bio-root regeneration. *Theranostics* (2019) 9(9):2694–711. doi: 10.7150/thno.31801
54. Pal M, Chen H, Lee BH, Lee JYH, Yip YS, Tan NS, et al. Epithelial-mesenchymal transition of cancer cells using bioengineered hybrid scaffold composed of hydrogel/3D-fibrous framework. *Sci Rep* (2019) 9(1):8997. doi: 10.1038/s41598-019-45384-9
55. Zhou J, Wu P, Sun H, Zhou H, Zhang Y, Xiao Z. Lung tissue extracellular matrix-derived hydrogels protect against radiation-induced lung injury by suppressing epithelial-mesenchymal transition. *J Cell Physiol* (2020) 235(3):2377–88. doi: 10.1002/jcp.29143
56. Yao Y, Chen R, Wang G, Zhang Y, Liu F. Exosomes derived from mesenchymal stem cells reverse EMT via TGF-beta1/Smad pathway and promote repair of damaged endometrium. *Stem Cell Res Ther* (2019) 10(1):225. doi: 10.1186/s13287-019-1332-8
57. Li R, Guo W, Yang B, Guo L, Sheng L, Chen G, et al. Human treated dentin matrix as a natural scaffold for complete human dentin tissue regeneration. *Biomaterials* (2011) 32(20):4525–38. doi: 10.1016/j.biomaterials.2011.03.008
58. Yang B, Chen G, Li J, Zou Q, Xie D, Chen Y, et al. Tooth root regeneration using dental follicle cell sheets in combination with a dentin matrix - based scaffold. *Biomaterials* (2012) 33(8):2449–61. doi: 10.1016/j.biomaterials.2011.11.074
59. Ferroni L, Gardin C, Sivoletta S, Brunello G, Berengo M, Piattelli A, et al. A hyaluronan-based scaffold for the *in vitro* construction of dental pulp-like tissue. *Int J Mol Sci* (2015) 16(3):4666–81. doi: 10.3390/ijms16034666
60. Park CH, Rios HF, Jin Q, Bland ME, Flanagan CL, Hollister SJ, et al. Biomimetic hybrid scaffolds for engineering human tooth-ligament interfaces. *Biomaterials* (2010) 31(23):5945–52. doi: 10.1016/j.biomaterials.2010.04.027
61. Nam S, Won JE, Kim CH, Kim HW. Odontogenic differentiation of human dental pulp stem cells stimulated by the calcium phosphate porous granules. *J Tissue Eng* (2011) 2011:812547. doi: 10.4061/2011/812547
62. Park HM, Kim SH, Choi BH, Park SH. Effects of induction culture on osteogenesis of scaffold-free engineered tissue for bone regeneration applications. *Tissue Eng Regen Med* (2022) 19(2):417–29. doi: 10.1007/s13770-021-00418-0
63. Abdulkareem AA, Shelton RM, Landini G, Cooper PR, Milward MR. Potential role of periodontal pathogens in compromising epithelial barrier function by inducing epithelial-mesenchymal transition. *J Periodontol Res* (2018) 53(4):565–74. doi: 10.1111/jre.12546
64. Suzuki A MT, Baba Y, Shimamura K, Kato Y. Acidic extracellular pH promotes epithelial mesenchymal transition in Lewis lung carcinoma model. *Cancer Cell Int* (2014) 14(1):129. doi: 10.1186/s12935-014-0129-1
65. Jiao M, Nan KJ. Activation of PI3 kinase/Akt/HIF-1alpha pathway contributes to hypoxia-induced epithelial-mesenchymal transition and chemoresistance in hepatocellular carcinoma. *Int J Oncol* (2012) 40(2):461–8. doi: 10.3892/ijo.2011.1197
66. Lee J, Roberts JS, Atanasova KR, Chowdhury N, Han K, Yilmaz O. Human primary epithelial cells acquire an epithelial-Mesenchymal-Transition phenotype during long-term infection by the oral opportunistic pathogen, *porphyromonas gingivalis*. *Front Cell Infect Microbiol* (2017) 7:493. doi: 10.3389/fcimb.2017.00493
67. Peerapen P, Thongboonkerd V. Protective roles of trigonelline against oxalate-induced epithelial-to-mesenchymal transition in renal tubular epithelial cells: An *in vitro* study. *Food Chem Toxicol* (2020) 135:110915. doi: 10.1016/j.fct.2019.110915
68. Zeng A, Liang X, Zhu S, Liu C, Wang S, Zhang Q, et al. Chlorogenic acid induces apoptosis, inhibits metastasis and improves antitumor immunity in breast cancer via the NFkappaB signaling pathway. *Oncol Rep* (2021) 45(2):717–27. doi: 10.3892/or.2020.7891
69. Abdallah BM, Khattab HM. Recent approaches to isolating and culturing mouse bone marrow-derived mesenchymal stromal stem cells. *Curr Stem Cell Res Ther* (2021) 16(5):599–607. doi: 10.2174/1574888X15666200708134337
70. Kong X, Fu J, Shao K, Wang L, Lan X, Shi J. Biomimetic hydrogel for rapid and scar-free healing of skin wounds inspired by the healing process of oral mucosa. *Acta Biomater* (2019) 100:255–69. doi: 10.1016/j.actbio.2019.10.011
71. Li M, Luan F, Zhao Y, Hao H, Zhou Y, Han W, et al. Epithelial-mesenchymal transition: An emerging target in tissue fibrosis. *Exp Biol Med* (2015) 241(1):1–13. doi: 10.1177/1535370215597194
72. Guo L, Chen L, Bi S, Chai L, Wang Z, Cao C, et al. PTEN inhibits proliferation and functions of hypertrophic scar fibroblasts. *Mol Cell Biochem* (2012) 361(1–2):161–8. doi: 10.1007/s11010-011-1100-2
73. Tsuji K, Kitamura S, Wada J. Immunomodulatory and regenerative effects of mesenchymal stem cell-derived extracellular vesicles in renal diseases. *Int J Mol Sci* (2020) 21(3):E756. doi: 10.3390/ijms21030756
74. Usunier B, Benderitter M, Tamarat R, Chapel A. Management of fibrosis: The mesenchymal stromal cells breakthrough. *Stem Cells Int* (2014) 2014:1–26. doi: 10.1155/2014/340257
75. Harrell CR, Djonov V, Volarevic V. The cross-talk between mesenchymal stem cells and immune cells in tissue repair and regeneration. *Int J Mol Sci* (2021) 22(5):2472. doi: 10.3390/ijms22052472
76. Sotiropoulou PA, Perez SA, Gritzapis AD, Baxevanis CN, Papamichail M. Interactions between human mesenchymal stem cells and natural killer cells. *Stem Cells* (2006) 24(1):74–85. doi: 10.1634/stemcells.2004-0359
77. Qi Y, Jiang D, Sindrilaru A, Stegemann A, Schatz S, Treiber N, et al. TSG-6 released from intradermally injected mesenchymal stem cells accelerates wound healing and reduces tissue fibrosis in murine full-thickness skin wounds. *J Invest Dermatol* (2014) 134(2):526–37. doi: 10.1038/jid.2013.328



OPEN ACCESS

EDITED BY

Junji Xu,
Capital Medical University, China

REVIEWED BY

Zhenlai Zhu,
Fourth Military Medical University,
China
Ahmet Eken,
Erciyes University, Turkey

*CORRESPONDENCE

Corinna L. Seidel
corinna.seidel@uk-erlangen.de;
corinna.seidel@med.uni-muenchen.de

SPECIALTY SECTION

This article was submitted to
Mucosal Immunity,
a section of the journal
Frontiers in Immunology

RECEIVED 14 September 2022

ACCEPTED 20 October 2022

PUBLISHED 16 November 2022

CITATION

Seidel CL, Percivalle E, Tschaftari M,
Weider M, Strobel K, Willershausen I,
Unertl C, Schmetzer HM, Weber M,
Schneider M, Frey B, Gaipf US,
Beckmann MW and Götz L (2022)
Orofacial clefts lead to increased
pro-inflammatory cytokine levels
on neonatal oral mucosa.
Front. Immunol. 13:1044249.
doi: 10.3389/fimmu.2022.1044249

COPYRIGHT

© 2022 Seidel, Percivalle, Tschaftari,
Weider, Strobel, Willershausen, Unertl,
Schmetzer, Weber, Schneider, Frey,
Gaipf, Beckmann and Götz. This is an
open-access article distributed under
the terms of the [Creative Commons
Attribution License \(CC BY\)](#). The use,
distribution or reproduction in other
forums is permitted, provided the
original author(s) and the copyright
owner(s) are credited and that the
original publication in this journal is
cited, in accordance with accepted
academic practice. No use,
distribution or reproduction is
permitted which does not comply with
these terms.

Orofacial clefts lead to increased pro-inflammatory cytokine levels on neonatal oral mucosa

Corinna L. Seidel^{1*}, Elena Percivalle¹, Marco Tschaftari¹,
Matthias Weider¹, Karin Strobel¹, Ines Willershausen¹,
Christoph Unertl¹, Helga M. Schmetzer², Manuel Weber³,
Michael Schneider⁴, Benjamin Frey^{5,6}, Udo S. Gaipf^{5,6},
Matthias W. Beckmann⁴ and Lina Götz¹

¹Department of Orthodontics and Orofacial Orthopedics, Universitätsklinikum Erlangen, Friedrich-Alexander-Universität (FAU) Erlangen-Nürnberg, Erlangen, Germany, ²Med III, University Hospital of Munich, Workgroup: Immune modulation, Munich, Germany, ³Department of Oral and Cranio-Maxillofacial Surgery, Friedrich-Alexander-Universität (FAU) Erlangen-Nürnberg, Erlangen, Germany, ⁴Department of Gynecology and Obstetrics, Comprehensive Cancer Center (CCC) Erlangen-EMN, Universitätsklinikum Erlangen, Friedrich-Alexander-Universität (FAU) Erlangen-Nürnberg, Erlangen, Germany, ⁵Translational Radiobiology, Department of Radiation Oncology, Universitätsklinikum Erlangen and Friedrich-Alexander-Universität (FAU) Erlangen-Nürnberg, Erlangen, Germany, ⁶Medical Immunology Campus Erlangen, FAU Erlangen-Nürnberg, Erlangen, Germany

Orofacial clefts (OFC) are frequent congenital malformations characterized by insufficient separation of oral and nasal cavities and require presurgical infant orthopedics and surgical interventions within the first year of life. Wound healing disorders and higher prevalence of gingivitis and plaque levels are well-known challenges in treatment of children with OFC. However, oral inflammatory mediators were not investigated after birth using non-invasive sampling methods so far. In order to investigate the impact of OFC on oral cytokine levels, we collected tongue smear samples from 15 neonates with OFC and 17 control neonates at two time points (T), T0 at first consultation after birth, and T1, 4 to 5 weeks later. The samples were analyzed using multiplex immunoassay. Overall, we found significantly increased cytokine levels (TNF, IL-1 β /-2/-6/-8/-10) in tongue smear samples from neonates with OFC compared to controls, especially at T0. The increase was even more pronounced in neonates with a higher cleft severity. Further, we detected a significant positive correlation between cleft severity score and distinct pro-inflammatory mediators (GM-CSF, IL-1 β , IL-6, IL-8) at T0. Further, we found that breast-milk (bottle) feeding was associated with lower levels of pro-inflammatory cytokines (IL-6/-8) in neonates with OFC compared to formula-fed neonates. Our study demonstrated that neonates with OFC, especially with high cleft severity, are characterized by markedly increased inflammatory mediators in tongue smear samples within the first weeks of life

potentially presenting a risk for oral inflammatory diseases. Therefore, an inflammatory monitoring of neonates with (severe) OFC and the encouragement of mother to breast-milk (bottle) feed might be advisable after birth and/or prior to cleft surgery.

KEYWORDS

orofacial clefts, cleft lip and palate, neonates, cytokines, oral, oral inflammation, mucosal immunity, mucosal homeostasis

1 Introduction

With an average occurrence of 1 in 700 newborns worldwide, orofacial clefts (OFC) are considered one of the most frequent malformations of craniofacial development (1, 2). OFCs develop between the 5th and the 12th week of embryogenesis due to disturbances in the fusion of the medial/lateral nasal and maxillary processes (3). These defective processes were associated with genetic predisposition (4), e.g., candidate loci 8q24, 1p22 and 10q25 (5, 6), or environmental factors, e.g., maternal smoking, folate deficiency and excessive alcohol consumption (7–9). OFCs present phenotypic variability and severity (10), e.g. unilateral cleft lip and palate (UCLP), bilateral cleft lip and palate (BCLP), isolated cleft palate (CPo) and isolated cleft lip (CLO) (11), leading to altered orofacial anatomical features and functional challenges. Within the first year of life, neonates with OFC require presurgical infant orthopaedics (PSIO), which aims to support preoperative growth of the palatal segments, normalize feeding and reduce asymmetries using palate plates (12, 13) before surgical lip and/or palate repair (12, 13). Even though, feeding difficulties like chronic aspiration and choking can pose a challenge and impede breast-feeding (14, 15) and, therefore, feeding alternatives like Haberman feeders are recommended and applied (16, 17).

In addition to these functional challenges, it is known that infants and adolescents suffer from aggravated oral health compared to controls, e.g., increased plaque levels, enhanced gingival inflammation and deeper periodontal pockets (18). Further, it was recently shown that neonates with OFC suffer from oral dysbiosis with increased levels of potentially pathogenic bacteria, e.g., *Enterobacteriaceae* (*Citrobacter*, *Enterobacter*, *Escherichia-Shigella*, *Klebsiella*), *Enterococcus*, *Bifidobacterium*, *Corynebacterium*, *Lactocaseibacillus*, *Staphylococcus*, *Acinetobacter* and *Lawsonella* (19). In infants and children with OFC, pre- and post-operative oral inflammation pose a main risk for wound healing disorders and failure of surgery (20), yet, preventive strategies, e.g. antibiotics prior to cleft lip surgery, did not achieve the desired results (21). Besides, early life inflammation was shown to increase the risk for other inflammation-associated

diseases, e.g. autoimmunity (22). Hence, further knowledge about inflammatory processes associated with clefting are necessary, especially in neonates within the first year of life before surgical cleft closure. However, for investigation of oral local inflammation within the first year of life, solely an invasive method was used for investigation of cytokine levels so far: collection of lip tissue from infants with OFC during cleft surgery (3 to 18 months of age) (23, 24). Interestingly, the authors found positive correlations between certain pro-inflammatory cytokines in lip tissue from neonates with OFC (without a control group) (23). Further, overall higher concentrations of cytokines were found in lip tissue from neonates with OFC compared to a non-age-matched and site-matched control group (tissue from extraction site of adolescents) (24). Since the invasive collection of lip tissue (23, 24) is ethically unacceptable in neonates without OFC, non-invasive methods for oral sample collection in neonates are necessary to ensure an age- and site-matched control group. It was recently shown that non-invasive sampling methods were suitable for cytokine and microbiota analyses in oral niches from adults (smear samples from tongue, hard palate, cheek and sublingual area, spitting method for collection of saliva, plaque sampling and collection of gingival crevicular fluid using paper strips) (25) and non-invasive collection of tongue and smear samples for microbiota analyses in neonates with and without OFC (19). Since smear samples from the cheek presented lowest cytokine concentrations in adults (high saliva flow rate: small salivary glands in the cheek) (25) and since no significant microbial differences were seen between niche tongue and cheek (19), non-invasive sampling of tongue smear samples might be the most suitable representative of the oral cavity for cytokine analyses in neonates.

Therefore, the aim of this study was to prove that a non-invasive collection methodology using tongue smear samples from neonates for investigation of cytokines is applicable. We aimed to analyse distinct cytokines (GM-CSF, INF- γ , TNF, IL-1 β /-2/-4/-6/-8/-10), that were shown to have anti- or pro-inflammatory functions in wound healing processes, inflammatory pathways and mucosal immunity (Table 1), in neonates with OFC compared to neonates without OFC at first

TABLE 1 Measured cytokines and their main functions in wound healing, inflammatory pathways and in mucosal immunity.

Cytokine abbreviation	Source	Functions in wound healing	Functions in inflammatory pathways	Functions on mucosal immunity	References
'pro-inflammatory' cytokines					
Granulocyte-macrophage colony-stimulating factor (GM-CSF)	Macro-phages T cells	GM-CSF activated phagocytes cause tissue damage (26)	GM-CSF upregulates CCL17 pathway in inflammation (27) GM-CSF stimulates TNF production (28)	Role in inflammatory signaling and dendritic cell recruitment into mucosa (29)	(26–29)
Interferon gamma (INF- γ)	B/NK/NKT/T cells APCs	activation of antimicrobial and antiviral pathways (30); increase of inflammation-induced tissue damage (31)	leukocyte adhesion, differentiation of immune cells, stimulation of macrophages (30, 32); negatively regulated by IL-4/-10 (30)	weakening of epithelial integrity (migration of bacteria through altered barrier) (30, 31)	(30, 31) (33)
Tumor necrosis factor (TNF)	Macrophages, T cells, NK cells, mast cells	high levels of TNF were associated with surgical site infection (34); TNF inhibitor treatment slightly reduced surgical site infection (35, 36)	Primary pro-inflammatory cytokine (37): vasodilatation, oedema formation, leukocyte adhesion (28); cross-regulation between IL-8, IL-1 β and TNF (37, 38); stimulated by GM-CSF (28)	Stimulation of IL-8 production by mucosal neonatal epithelial cells (39); high levels were associated with worsening of the mucosal epithelial barrier function (40, 41)	(28, 34–36, 38, 40, 42) (43) (37, 39)
Interleukin-1 β (IL-1 β)	Monocytes macrophages	Primary host defense, response to injury, enhancement of tissue damage in injury-associated mechanisms (44)	Primary pro-inflammatory reactions by the innate immune system, activation of IL-8 (37)	Stimulation of IL-8 production by mucosal neonatal epithelial cells (39); capable to compromise mucosal barrier function (41)	(37, 39, 41, 44)
Interleukin-6 (IL-6)	T cells, macrophages, mast cells	promoting migration of immune cells to the damaged site/wound (45); increased levels were shown to alter tissue integrity (41)	high levels (in plasma) were associated with severity of infectious neonatal diseases (33); produced after IL-1 β , TNF and INF- γ stimulation (32)	capable to compromise mucosal barrier function (41)	(32, 41, 46) (45) (33)
Interleukin-8 (IL-8)	Phagocytes mesenchymal cells mast cells	promotion of tissue destruction (neutrophil accumulation and granules release) (47, 48); reduced IL-8 production associated with scarless wound healing (49)	Secondary pro-inflammatory cytokine in inflammatory reactions by the innate immune system after IL-1 β trigger and TNF stimulus (37, 38)	produced under the stimulus of TNF and IL-1 β by neonatal nasal mucosa epithelial cells (39); capable to compromise mucosal barrier function (41)	(32, 38, 41, 47–49) (26) (39)
'pro- and anti-inflammatory' cytokines					
Interleukin-2 (IL-2)	CD4 ⁺ T cells	<i>anti-inflammatory</i> : treatment with IL-2 promotes tissue integrity, defense, tolerance and strengthens the wound (43, 45, 50)	important regulator in communication of innate and adaptive immunity; activation of T/B/NK cells (32); stimulation of CD8 ⁺ cytotoxicity (32);	regulation of oral mucosal inflammation (activation of NF- κ B pathway) (51)	(32, 43, 45, 50, 51)
Interleukin-10 (IL-10)	CD4 ⁺ T cells B cells monocytes dendritic cells	<i>anti-inflammatory</i> : controlling the extend and duration of inflammation in wound healing (major suppressor of immune responses) (52, 53)	<i>pro-inflammatory</i> : in a comprised micro-environment (54), upregulated during inflammation when other pro-inflammatory cytokines, e.g., TNF and IL-6, increase (33) IL-10 inhibits the production of IL-1 β and TNF (32) high levels (in plasma) were associated with severity of infectious neonatal diseases (33)	promoting oral tolerance (55) anti-inflammatory in mucosal inflammation (down regulation of immune responses to pathogens/microbiota) (52) upregulated during inflammation when other pro-inflammatory cytokines increase, e.g. IL-2, INF- γ in gingival crevicular fluid (56, 57)	(32, 52, 54, 55) (58) (33, 54)
'anti-inflammatory' cytokine					
Interleukin-4 (IL-4)	Mast cells, CD4 ⁺ T cells, Baso-phils, Eosino-phils	important role in wound healing (activation of fibroblasts, keratinocytes, neoangiogenesis and reepithelization) (46) application of IL-4 accelerates wound healing (59)	decreased levels of IL-4 were correlated to progression of inflammatory diseases (60); antagonistic effects in inflammatory diseases: IL-4 inhibits TNF and IL-1 β production (61)	mucosal wound healing was associated with increased IL-4 levels (62); Anti-inflammatory and immunoregulatory functions in mucosal immune reactivity (60)	(32, 46, 59–62)

APC, antigen presenting cell; NK cell, natural killer cell; NKT cell, natural killer T cell; CD, cluster of differentiation.

consultation after birth and 4 to 5 weeks later. Moreover, the impact of cleft phenotype and severity on cytokine levels were determined. The overarching goal was to increase knowledge about inflammatory changes within the first weeks of life and to identify neonates at risk for oral inflammation and wound healing disorders.

2 Material and methods

2.1 Study design

This study was designed as a prospective, exploratory observational clinical trial and has been approved by the local ethics committee of the Friedrich-Alexander-University Erlangen-Nürnberg (Krankenhausstraße 12, 91054 Erlangen, Vote number: 168_20 B, 28.04.2020) prior to the beginning of the study. The trial was performed in accordance to the declaration of Helsinki. Patients were recruited following predefined inclusion criteria: I) Neonates with non-syndromic orofacial cleft with their first consultation at the Department of Orthodontics and Orofacial Orthopedics within the first days and weeks of life, II) neonates without orofacial cleft (born in the Department of Gynecology and Obstetrics Erlangen with ongoing regular consultations in local pediatric practices) and III) written informed consent by the parents and/or legal guardians. Exclusion criteria were defined as the following: I) Neonates with syndromic cleft lip and palate, II) preterm birth (< 37 weeks gestational age), III) neonates with underweight at birth (<2500g), IV) neonates with systemic and metabolic or autoimmune diseases, V) neonates with antibiotic intake, VI) revoked written informed consent by the parents and/or legal guardians. Two informed consent forms for participation in the trial and for utilization of tongue smear samples, data protection sheets and information material explaining the study in adequate language were provided. Written informed consent forms and data protection sheets by the parents and/or legal guardians were mandatory for enrollment in the trial. Moreover, written questionnaires were given to the parents and/or legal guardian to collect information about neonates' clinical parameters including weight and height at birth, nutrition protocol, intake of antibiotics and/or supplements as well as to collect information about the mother including information type of birth and intake of antibiotics intrapartum (Table 2). Neonates were included regardless of birth type (vaginal birth or *via* C-section) and, hence, neonates whose mothers received intrapartum antibiotics due to C-section, were not excluded.

2.2 Recruitment

After eligibility screening, a total of 40 study participants were enrolled in this study and divided into two groups

(Figure 1). The study group, neonates (n=18) with orofacial clefts, was recruited at the Department of Orthodontics and Orofacial Orthopedics, Universitätsklinikum Erlangen, Friedrich-Alexander Universität (FAU) Erlangen-Nürnberg. The control group, neonates without orofacial clefts (n=22), was recruited at the Department of Gynaecology and Obstetrics, Universitätsklinikum Erlangen, FAU Erlangen-Nürnberg. Dropouts were registered due to the following reasons: 1) Failure to appear to the consultation and study appointments (n=1), 2) revoke of consent by the parents and/or legal guardians (n=4) or 3) meeting the exclusion criteria during the course of the study (n=3) (e.g. diagnosis of a syndrome or acute systemic or metabolic disease). In total, the dropout rate was 15% (n=8 in total, n=3 CLP patients and n=5 controls) with a final sample size of 15 study participants in the CLP group and 17 study participants in the control group (Figure 1).

2.3 Sample collection

Overall, 132 tongue smear samples were collected during a timespan ranging from June 2020 to June 2021. Tongue smear were obtained using sterile swabs and wiping carefully over the middle and anterior part of the tongue several times for about 10 seconds. Parents were instructed to pause feeding their infants 2-3 hours prior to sample collection and inform the study leader, if medical treatment (e.g., antibiotic treatment) was performed prior to sample collection or during the study course leading to an exclusion of the study participant. For the control group, sample collection was performed during routine appointments at the Department of Gynaecology and Obstetrics, Universitätsklinikum Erlangen, FAU Erlangen-Nürnberg (U2 = T0) as well as at local pediatricians: (U3 = T1). For the OFC group, the sample collection was performed at the Department of Orthodontics and Orofacial Orthopedics during initial consultation (T0) and during regular appointments (T1). For sufficient preservation, samples were stored on dry ice within seconds after sample collection performed on neonates and then either immediately frozen at -80° C or stored in freezers at -20°C for a maximum of 5 days and subsequently transferred to a ultra-low freezing unit at -80° C for definite storage. An uninterrupted cold chain was preserved permanently. Storage as well as further processing was conducted in the research laboratory of the Department of Orthodontics and Orofacial Orthopedics, Universitätsklinikum Erlangen, FAU Erlangen-Nürnberg.

2.4 Study population

Male and female subjects were distributed equally in both groups (Tables 2, 3). The average age at T0 is slightly different

between the OFC and the control group since initial clinical surveillance at orthodontists for treatment of OFC neonates is often slightly later than the initial consultation (U2) at gynaecologists (median age OFC neonates = 3 days; control neonates = 2 days) (Tables 2, 3). Samples at T1 were collected at a median age of 32 days (CLP group) and 31 days (control group), hence, there were no differences in the distribution between the two groups (Tables 2, 3). With a median weight of 3480 g, the control group was consistent with the European average 26, whereas orofacial cleft patients' weight was

significantly lower with a median weight of 3120 g (Table 3) which is in line with previous studies presenting evidence for reduced birth weight and height at birth 27 and belated growth and development mostly due to feeding difficulties 28–30. Similarly, there is a mild almost significant difference regarding the height at birth in both groups that is in average 51 cm for orofacial cleft patients and 53 cm for the control group (Table 3). The mode of birth (vaginal and caesarean) and antibiotic intake by mothers intrapartum were equally distributed in both groups (Table 3). However, in contrast to

TABLE 2 Characteristics of Study population.

Characteristics of the control group

#	Age at T0 (d)	Age at T1 (d)	Gender	Weight T0 (g)	Height T0 (cm)	Type of birth ¹	PROM*	Antibiotics ²	Nutrition ³
001	2	36	f	3350	52	1	0	2	0
002	2	34	m	3800	53	1	0	2	0
003	2	27	m	4120	55	1	0	2	0
004	2	23	f	3150	50	1	1	2	0
005	2	32	m	3340	50	0	0	0	0
008	3	29	f	3180	51	0	1	0	0
009	2	35	m	4030	54	0	0	0	0
010	2	38	m	3640	53	0	0	0	0
011	2	31	m	3050	50	0	1	0	0
012	2	20	f	2930	50	0	1	0	0
013	3	32	m	3670	54	0	1	0	0
015	3	34	f	3200	50	0	1	0	0
016	2	42	m	3940	53	1	1	2	0
018	2	24	f	3570	54	0	0	0	0
020	3	36	f	4200	56	1	0	2	0
021	3	22	m	3480	54	1	0	2	0
022	3	24	m	2950	50	0	0	0	0

Characteristics of the study group (CLP)

#	Age at T0 (d)	Age at T1 (d)	Gender	Weight T0 (g)	Height T0 (cm)	Type of birth ¹	PROM*	Anti-biotics ²	Nutrition ³
001	7	24	m	2590	48	0	0	2	2
002	n.d.	19	m	3130	44	1	0	1	2,4
003	3	38	m	3040	51	1	0	1	2
004	5	n.d.	f	2980	51	0	0	0	0
005	2	37	f	2940	51	0	0	0	1
007	2	29	m	3220	51	0	0	0	1
009	3	29	m	3240	49	0	0	1	3
010	3	38	m	3320	51	1	0	1	3,4
011	3	34	m	3350	53	0	0	0	1
012	3	25	m	3900	51	0	0	0	2,4
014	2	31	m	3120	47	1	0	1	2
015	1	22	f	2800	51	0	0	0	2
016	11	39	f	3120	51	0	0	0	1,4
017	14	40	m	2860	50	0	0	0	3
018	8	34	f	3890	51	0	0	0	0

(Continued)

TABLE 2 Continued

Special characteristics of the study group: classification, severity, type of treatment

#	Etiology ⁴	BCLP*	UCLP*	CPo*	CLO*	LAHSHAL Code ⁵	LAHSHAL Severity ⁶	Severity Score ⁷	pAM*
001	ps	0	1	0	0	- - - SHAL	0002222	8	1
002	s	0	0	1	0	- - hSh - -	0012100	4	0
003	ps	0	1	0	0	- - - SHAL	0002222	8	1
004	s	0	0	1	0	- - hSh - -	0012100	4	0
005	s	0	0	1	0	- - HSH - -	0022200	6	1
007	ps	0	1	0	0	- - - SHAL	0002221	7	1
009	ps	1	0	0	0	LAHS - - 1	1222001	8	1
010	ps	1	0	0	0	LAHSHAL	2222222	14	1
011	ps	0	1	0	0	LAHS - - -	2222000	8	1
012	ps	1	0	0	0	LAHSHAL	2222222	14	1
014	ps	0	1	0	0	LAHS - - -	1222000	7	1
015	ps	1	0	0	0	laHSHAL	1122222	12	1
016	s	0	0	1	0	- - HSH - -	0022200	6	1
017	s	0	0	1	0	- - HSH - -	0022200	6	1
018	p	0	0	0	1	la - - - - -	1100000	2	0

s, cleft of the secondary palate; p, cleft of the primary palate; ps, cleft of the primary and secondary palate; d, days; g, grams; cm, centimeter; f, female; m, male; n.d., not done

* 0, no; 1, yes; ¹ v, vaginal; c, caesarian.² 0 = no antibiotic intake of neonates or mother before birth, 1 = mother before birth, 2 = neonates after birth.³ 0 = breastfeeding, 1 = bottle feeding breast milk, 2 = bottle feeding partly breast milk, partly artificial formula, 3 = bottle feeding artificial formula, 4 = postnatal tube feeding for <1 week (=T0).⁴ p = cleft of the primary palate, s = cleft of the secondary palate, c = combined clefting of the primary and secondary palate.⁵ LAHSHAL Code: minus sign (-) = not affected, small letter = incompletely affected, capital letter = completely affected.⁶ LAHSHAL Severity: 0 = not affected, 1 = incompletely affected, 2 = completely affected.⁷ LAHSHAL Score, sum of the LAHSHAL Severity.

the mainly breast-fed control group, neonates with OFC were mostly fed with bottles (breast milk, mixed nutrition, exclusively formula-fed) and some required tube feeding after birth, which was expected due to the explained feeding issues in neonates with OFCs 14–17. The LAHSHAL classification scheme by Kriens et al. 10 uses letters to describe the cleft phenotype. Based on the LAHSHAL code 10, we created a severity score for subgroup investigations. Capital letters representing complete affection of the anatomical structure 10 were given by the value two (2), while small letters representing incomplete affection 10 were given the value one (1) and minus signs representing not-affected parts 10 were given the value zero (0). At the end, all numbers were summed up for each individual patient and the final sum value was used as severity score (the higher the final number, the more severe was the clefting) (Table 2).

2.5 Cytokine analysis

For the measurement of cytokine concentrations, collected tongue smear samples were isolated from swabs by centrifugation at $21.130 \times g$ (1 minute at 4°C) as previously

described by Seidel CL et al. (25). Then the samples' volume was measured and diluted with diluent 43 (Mesoscale Discovery, R50AG-2) to a volume of >50 µL. A few samples needed to be diluted more than 14-fold, due to their very small initial volume ($\leq 4\mu\text{L}$). For some of these high diluted samples the cytokine-measurement failed because they resulted below the detection range. These not reliable concentration-values were filtered and excluded from the analysis. In particular, regarding the CLP group at T0, sample 018 was diluted 37-fold and excluded from GM-CSF, IL-10 and IL-4 analysis; sample 015 was diluted 28 times and excluded from IL-4 measurements. In the control group at T0 the sample 008 was diluted 37-fold and excluded from IL-4 measurements. In the control group at T1 the samples 009 and 010, diluted 22-fold, were included only for IL-8 and IL-1β analysis, 003 was excluded from IL-4, IL-10 and TNF measurement. Cytokine concentrations were analyzed by multiplex immunoassay in 96 well plates with a U-PLEX Biomarker Group 1 (hu) assay (Mesoscale discovery; K15067L-2) on a MESO QuickPlex SQ 120 instrument (Mesoscale discovery). The assay was performed according to the manufacturer's instructions. The elaboration of the data was made with the Program Mesoscale Discovery Workbench.

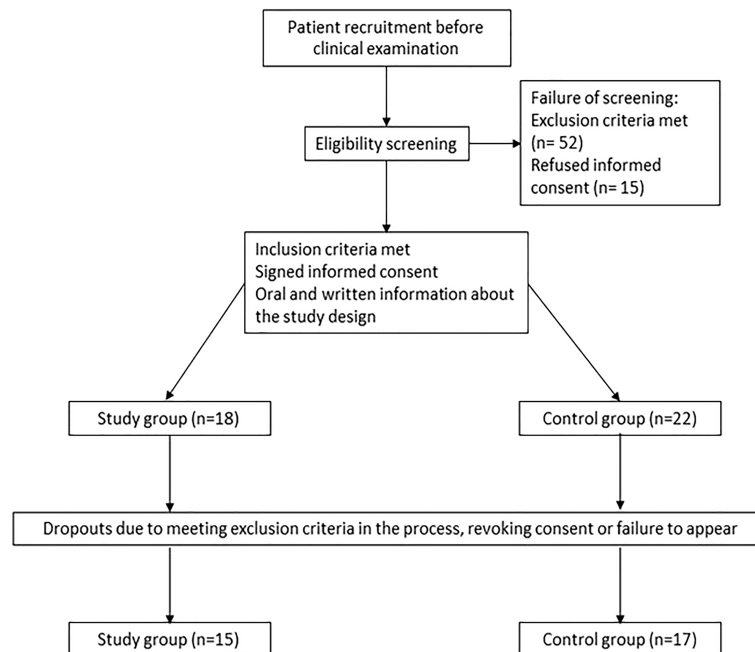


FIGURE 1
Flow of patients.

2.6 Statistics

The calculation of cytokine concentrations and statistical analyses was done with Microsoft Excel 2016 (Microsoft, Redmond, WA, USA) and GraphPad Prism 9 statistical software (GraphPad Software, San Diego, CA, USA). The data sets were analyzed by using the Mann-Whitney U-test, Chi Square test, Kruskal–Wallis test and Dunn’s multiple comparisons test. Differences were considered significant with p -values ≤ 0.05 . Correlations between cytokines and severity-score were calculated with Pearson’s correlation coefficient.

3 Results

3.1 CLP neonates present significantly higher levels of pro-inflammatory mediators compared to controls

The concentration of nine inflammatory mediators (GM-CSF, INF- γ , TNF, IL-1 β /-2/-4/-6/-8/-10) in tongue smear samples was measured with multiplex immunoassay in each of the following four groups (Figures 2A–H): CLP patients (CLP) and healthy controls (ctrl) at T0 and T1. TNF, IL1- β , IL-6, IL-8 and IL-10 concentration were significantly higher in the CLP group compared to the control group at both time points (Figures 2C, D, G–I). The concentration of IL-2 and IL-4 was

significantly higher in the CLP group, however only at T0 (Figures 2E, F). Considering the CLP group, the concentration of the pro-inflammatory cytokines IL-1 β and IL-8 and the anti-inflammatory cytokine IL-4 decreased significantly from T0 to T1 (Figures 2D, F, H). Regarding the control group, the concentrations of pro-inflammatory cytokines (GM-CSF, IL-1 β , IL-6 and IL-8) declined significantly from T0 to T1 (Figures 2A, D, G, H), while anti-inflammatory cytokines (IL-2 and IL-4) increased significantly from T0 to T1 (Figures 2E, F) resulting in higher levels of IL-4 at T1 in the control group than in the CLP group (Figure 2F).

To conclude, a general reduction of cytokine levels was observed in tongue smear samples within the first weeks of life in neonates. Moreover, several pro-inflammatory cytokines showed significantly higher concentrations in the CLP group compared to controls, while controls were characterized by highest levels of anti-inflammatory IL-4 after the first weeks of life.

3.2 Defining a numerical classification scheme to differentiate CLP neonates into low and high cleft severity

In order to investigate the impact of cleft severity numerically, we created a severity score according to the LAHSAL classification 10 (Table 2, Supplementary Figure 1).

TABLE 3 Descriptive statistics and statistical comparisons between CLP group and Control group.

	CLP group (n=15)	Ctrl group (n=17)	p-value
Age in days, median (IQR):			
At T0	3 (2-7.25)	2 (2-3)	0.046^a
At T1	32 (24.75-38)	31 (24-35.5)	0.717 ^a
Gender:			
Female, n (%)	5 (33)	7 (41)	0.789 ^b
Male, n (%)	10 (67)	10 (59)	0.561 ^b
Birth weight (grams) median (IQR):	3120 (2920-3328)	3480 (3165-3870)	0.024^a
Birth height (cm) median (IQR):	51 (49.75-51)	53 (50-54)	0.051^a
Mode of Delivery:			
Vaginal, n (%)	11 (73)	10 (59)	0.659 ^b
Caesarean section, n (%)	4 (27)	7 (41)	0.485 ^b
Antibiotics:			
None, n (%)	9 (47)	10 (59)	0.638 ^b
Mother before birth, n (%)	5 (33)	7 (41)	0.718 ^b
Neonate after birth, n (%)	1 (7)	0 (0)	0.287 ^b
Nutrition:			
Breastfeeding, n (%)	2 (13)	17 (100)	0.001^b
Bottle feeding breast milk, n (%)	3 (20)	0	0.065 ^b
Bottle feeding partly breast milk, partly artificial baby food, n (%)	4 (27)	0	0.033^b
Bottle feeding artificial baby food	2 (13)	0	0.132 ^b
Postnatal tube feeding for <1week=T0, n (%)	4 (27)	0	0.033^b

^aMann-Whitney Test; ^bchi-square Test. Bold font = $p \leq 0.05$.

The higher the sum of the LAHSHAL code, the more anatomical parts were completely affected by clefting, while low values indicate that solely the lip or the palate were affected by clefting (Table 2, Supplementary Figure 1). A heatmap analyses in accordance to severity score was performed (Figure 3). Interestingly, a trend of higher cytokine concentrations was seen in tongue smear samples from CLP neonates with higher severity score in comparison to CLP neonates with lower severity score at T0 (Figure 3) depicting a visual separation into CLP neonates with severity scores greater than value 7 and neonates with severity scores up to the value 7 (Figure 3 red line). In accordance to the results found in the heatmap, we defined a cut-off value dividing CLP patients in high cleft severity (severity score 8-14) and low cleft severity (severity score 2-7) for further investigations.

3.3 Neonates with high cleft severity present significantly higher levels of pro-inflammatory mediators compared to low cleft severity after birth

Interestingly, significantly higher pro-inflammatory cytokine concentrations (GM-CSF, IL-1 β and IL-8) were seen in tongue smear samples from neonates with high cleft severity compared to low severity at T0 (Figures 4A, D, H). All other

measured cytokines (except for IFN- γ) also presented elevated levels in the high severity group compared to the low severity group (Figure 4). Moreover, in CLP neonates with high cleft severity, most measured cytokines (TNF, IL-1 β -2/-4/-6/-8, GM-CSF) showed a significant reduction from T0 to T1 (Figures 4A, C-H), while in neonates with low severity solely IL-6 decreased significantly (Figure 4G).

3.4 Distinct cytokine correlation clusters were found in each group for each time point

To investigate the relationship between cytokine concentrations in tongue smear samples and orofacial cleft severity, Pearson correlation analysis was performed for both groups (CLP, ctrl) and both time points (T0, T1). Regarding the CLP group at T0, positive correlations were seen for: 1) GM-CSF, IL-2/-4/-8; 2) TNF, IL-1 β -6/-10 (Figure 5A). Considering the control group at T0, the following positive correlations were detected: 1) TNF, IL-6/-8/-10; 2) IL-2/-4/-10; 3) IL-4, IFN- γ ; 4) IL-1 β -6 (Figure 5B). As for the CLP group at T1, IL-8 correlated positively with all measured cytokines (GM-CSF, IFN- γ , IL-1 β , -2, -4, -6, -10) except for TNF (Figure 5C) and IL-4 correlated with all measured cytokines (GM-CSF, IFN- γ , IL-1 β , -4, -6) except for TNF, IL-2 and IL-10 (Figure 5C).

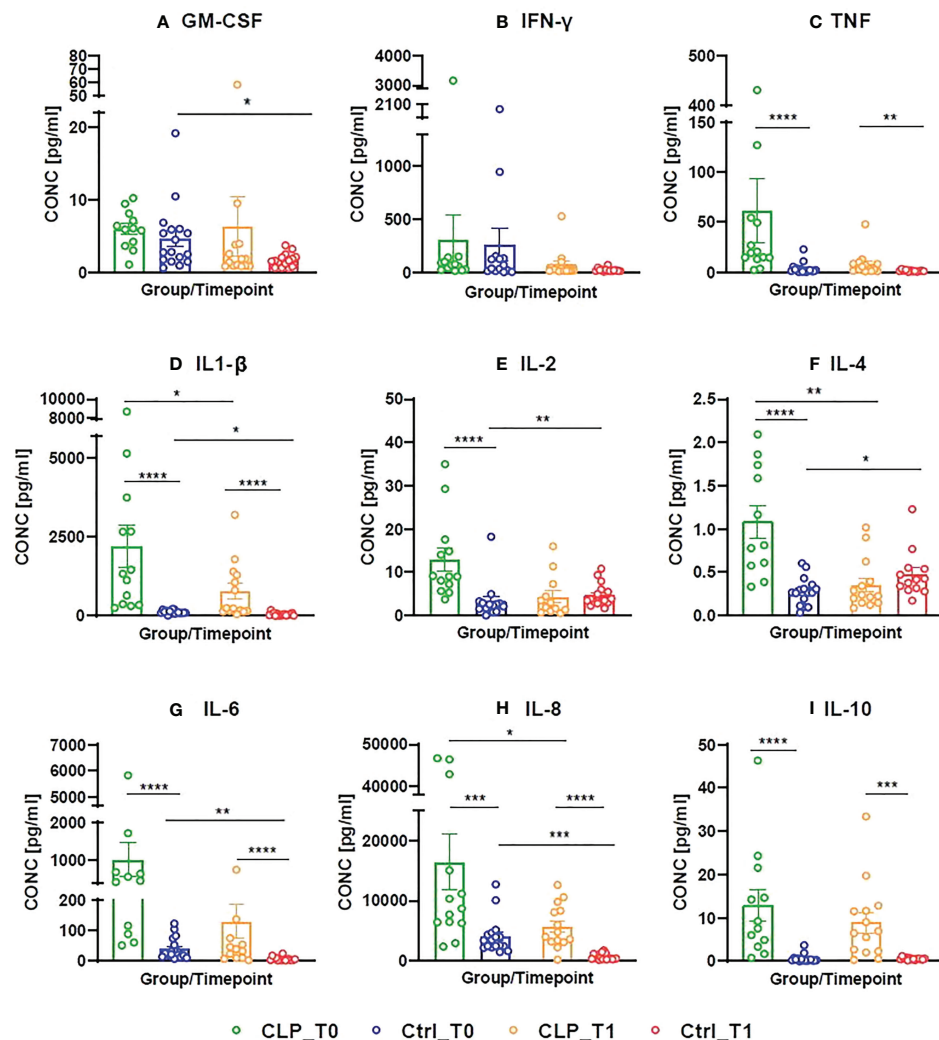


FIGURE 2

Concentrations (pg/ml) of measured cytokines (Granulocyte-macrophage colony-stimulating factor = GM-CSF, Interferon gamma = INF- γ , Tumor-necrosis-factor = TNF, Interleukin (IL)-1 β -2/-4/-6/-8/-10) in cleft patients (CLP) compared to controls (Ctrl) at both time points (T0 = after birth, T1 = 4-5 weeks after birth). A color scheme represents each group – time point – combination (CLP-T0: = green, Ctrl-T0 = blue, CLP-T1 = orange, Ctrl T1 = red). Histograms presenting the cytokine concentrations are given for each measured cytokine (A-I), both groups (CLP vs. ctrl) and both time points (T0 vs. T1). Each histogram is a scatter dot plot with the mean and standard error of mean (SEM). The cytokine concentration in pg/ml is given on the Y axis, while the X axis represents the four groups: CLP_T0, Ctrl_T0, CLP_T1, Ctrl_T1. The comparisons were statistically analyzed with t test and Mann-Whitney U-test, statistically significant comparisons are indicated by *p ≤ 0.05, **p ≤ 0.01, ***p ≤ 0.001, ****p ≤ 0.0001.

Furthermore, correlations were seen for: 1) TNF, IL-1 β ; 2) IL-2/-10 (Figure 5C). Considering the control group at T1, positive correlations were seen for GM-CSF, TNF, IL-2/-4/-10 (Figure 5D), while the pro-inflammatory mediators IL-1 β -6/-8 correlated negatively with all measured cytokines (Figure 5D). Considering the severity score in the CLP group, positive correlations with pro-inflammatory mediators (GM-CSF, IL-1 β) were seen at T0 (Figure 4A).

3.5 Breast-milk (bottle) feeding correlated with reduced levels of pro-inflammatory cytokines IL-6 and IL-8 in neonates with orofacial clefts

In contrast to control neonates, most neonates with CLP suffer from feeding difficulties and require bottle feeding and in very severe cases even postnatal tube feeding after birth. Overall,

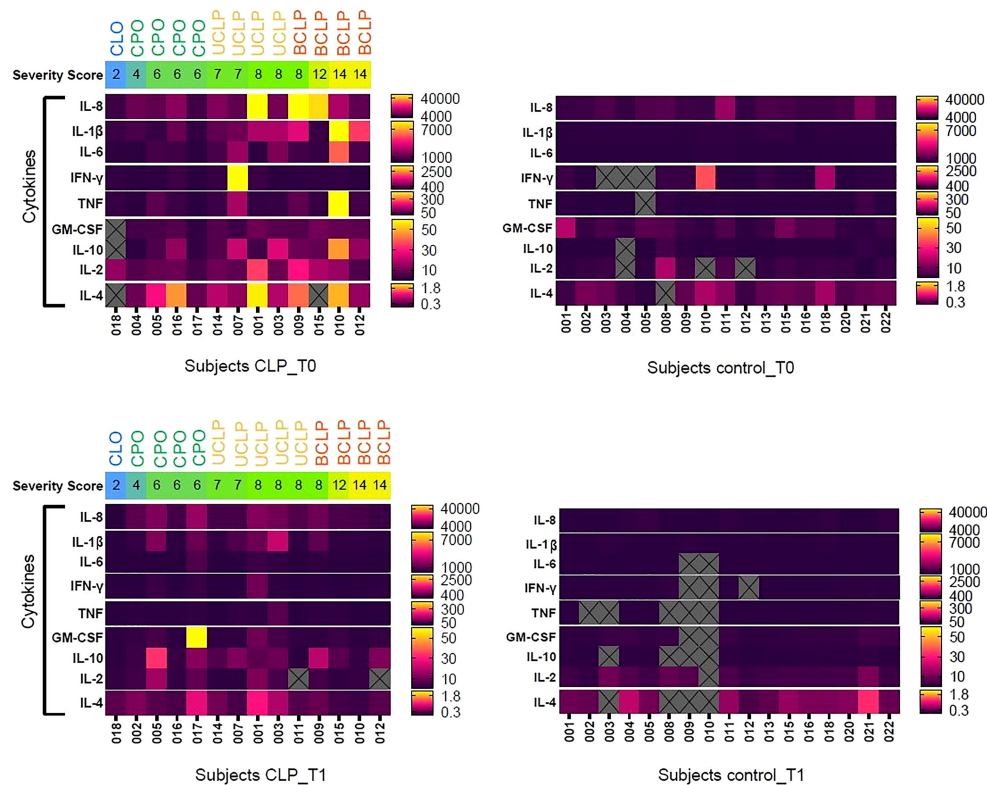


FIGURE 3

Heat map representing the cytokine concentrations (pg/ml) of measured cytokines (Granulocyte-macrophage colony-stimulating factor = GM-CSF, Interferon gamma = IFN- γ , Tumor-necrosis-factor = TNF, Interleukin (IL)-1 β -2/-4/-6/-8/-10) for each subject in the cleft patients (CLP) group compared to the control (Ctrl) group at both time points (T0 = after birth, T1 = 4-5 weeks after birth). The subjects in the CLP group are organized left to right from the lowest severity score (severity score 2) to the higher (severity score 14). The severity score and the cleft type for each individual subject are ordered horizontally for each patient and are represented by color scheme: severity score is given by a color gradient from low (blue) to medium (green) to highest (yellow) cleft severity; cleft phenotype is given above: Cleft lip only (CLo) = blue letters, Cleft palate only (CPo) = green letters, unilateral cleft lip palate (UCLP) = yellow letters, bilateral cleft lip palate (BCLP) = orange letters. The red line represents the cut-off between low and high severity score. The range of concentration for each cytokine (pg/ml) is given on the right side and the measured cytokines are organized vertically from highest to lowest concentration. A double gradient map represents the levels of cytokines for each subject (yellow = highest concentration, pink = intermediate concentration, dark violet = lowest concentration). The gray squares with X are excluded multiplex-cytokine measurements due to concentrations below the detection range.

a trend to higher cytokine levels in tongue smear samples was seen in bottle-fed neonates receiving mixed baby food (MF) and artificial food (AF) compared to the breast-milk (bottle) fed group (BM) at T0, while differences were only significant for IL-8 (Supplementary Figure 3). At T1, IL-6 displayed significantly higher levels in tongue smear samples from neonates receiving artificial baby food compared to breast-milk (bottle) feeding (Supplementary Figure 3). Notably, one neonate (LKG_017) with CPo presented a peak of GM-CSF at T1 (Figure 3), which received AF exclusively (Table 2).

4 Discussion

OFCs present different phenotypes and severities (10, 11) and are characterized by an insufficient separation of oral and

nasal cavity (10, 11) hereby presenting a risk for intraoral inflammation (20). However, characterisation of local oral cytokine milieu in non-invasively collected tongue smear samples has neither been performed in healthy neonates nor in neonates with OFC. In order to identify inflammatory alterations and potential risk factors for wound healing disorders, we investigated cytokine concentrations in tongue smear samples from neonates with OFC compared to controls and correlated them with cleft phenotypes and severity.

The non-invasive sampling method using tongue smear samples was chosen due to several reasons. So far, two invasive methods were used to analyse cytokine concentrations in infants with OFC: 1) Two previous studies (23, 24) collected lip tissue during cleft surgery in infants (3-18 months of age) to investigate cytokine concentrations, but lacked an adequate control group since surgical collection of lip tissue from

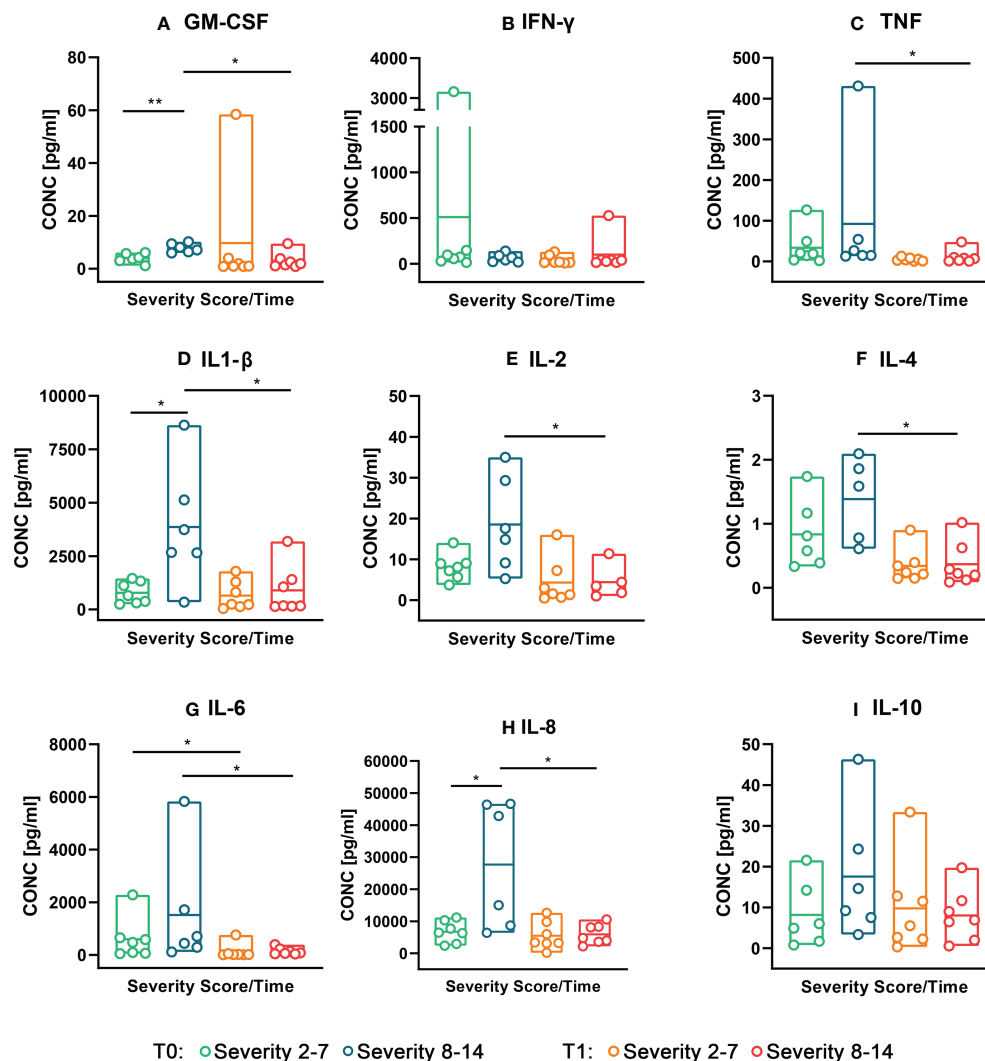


FIGURE 4

Concentrations (pg/ml) of measured cytokines (Granulocyte-macrophage colony-stimulating factor = GM-CSF, Interferon gamma = INF-γ, Tumor-necrosis-factor = TNF, Interleukin (IL)-1β/-2/-4/-6/-8/-10) in neonates with low cleft severity (Severity 2-7) compared to neonates with high cleft severity (Severity 8-14) at both time points (T0 = after birth, T1 = 4-5 weeks after birth). A colour scheme represents each group – time point – combination (Severity 2-7 T0 = green, Severity 8-14 T0 = blue, Severity 2-7 T1 = orange, Severity 8-14 T1 = red). The concentrations (pg/ml) of the measured cytokines (GM-CSF, INF-γ, TNF, IL-1β/-2/-4/-6/-8/-10) are given from the top left to the bottom right histogram (A-I). Floating bars (max to min) with dots represent the cytokine concentration distributed in two subsets (Severity 2-7 and Severity 8-14) and both time points (T0 vs. T1). The horizontal line in the bars represents the mean. The statistical analysis was made with Mann-Whitney U-Test, *p value ≤ 0.05, **p ≤ 0.01.

healthy neonates would be ethically unacceptable. 2) One study investigated cytokine concentrations and osteocalcin in peripheral blood samples collected from children with OFC (0-12 months, 1-3 years, 4-9 years, 10-15 years; n=80) compared to an age-matched control group (n=10/per age group) (63). The authors detected significantly higher pro-inflammatory cytokine concentrations in OFC children and distinct age-related correlations between IL-4 and osteocalcin with a focus on immune-skeletal interactions and postnatal osteogenesis (63), however, they did not detect differences

between different cleft phenotypes and did not correlate their results to oral parameters. With respect to non-invasive methods to investigate cytokine concentrations in the oral cavity, several methods were used in patients with OFC: 1) Collection of stimulated saliva (64) or unstimulated saliva (65) using the spitting method: patients are asked to collect saliva in their mouth in an upright position with the head slightly tilted forward (unstimulated saliva: without moving the head or regurgitation) and to spit the collected saliva in a sterile tube several times until the required amount of saliva is collected (65);

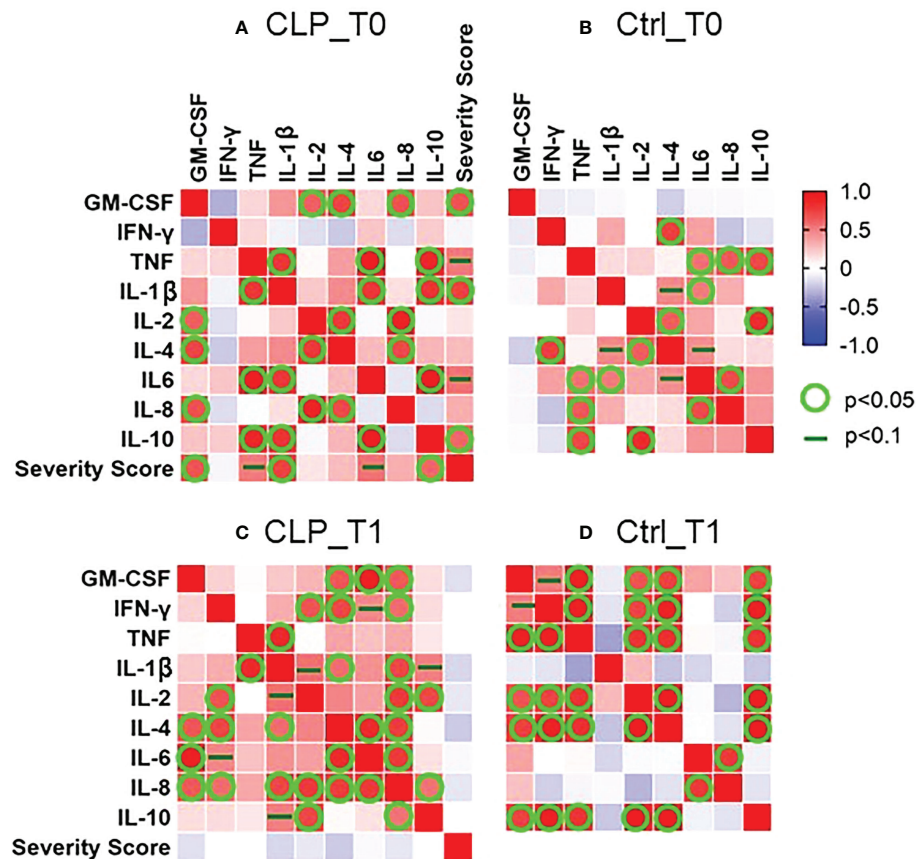


FIGURE 5

Pearson correlation matrix between concentrations (pg/ml) of measured cytokines (Granulocyte-macrophage colony-stimulating factor = GM-CSF, Interferon gamma = INF- γ , Tumor-necrosis-factor = TNF, Interleukin-1 β , IL-2, IL-4, IL-6, IL-8, IL-10) and severity score for cleft patients (CLP) compared to controls (Ctrl) at both time points (T0 = after birth, T1 = 4-5 weeks after birth). The heat maps represent the correlation matrix for the CLP group at T0 (A) and T1 (C) and the controls at T0 (B) and T1 (D). The correlations were calculated between the measured cytokines (GM-CSF, INF- γ , TNF, IL-1 β , IL-2, IL-4, IL-6, IL-8, IL-10) and the severity score. A color scheme represents the Pearson's r for each combination of variables. Red presents a perfect positive correlation ($r = 1$) and blue a perfect inverse correlation ($r = -1$). No correlation ($r = 0$) is represented with white color. A statistically significant correlation ($p < 0.05$) is represented by a green circle and a dark green line indicates a tendentially significant correlation ($p < 0.1$).

2) Usage of sterile swabs to collect smear of defined areas, e.g., wiping over the tongue or the palate several times (areas with low saliva flow rate) or wiping over the cheek or sublingual area (high saliva flow rate) (25); 3) Sampling of gingival crevicular fluid by putting sterile paper strips in gingival pockets for a defined amount of time (in dentulous individuals) (25, 66–70); 4) Gathering of dental biofilm [supragingival plaque (25) or subgingival plaque (71)] with sterile dental instruments (in dentulous individuals). Some authors used the term 'saliva swab' referring to non-invasive methods described above, e.g., the spitting methods (72, 73), or mixing up different methods, e.g., stimulation of saliva by coughing and wiping over tongue, cheek, palate and gums afterwards (74). A previous study detected distinct differences and similarities between the cytokine concentration in different oral niches and defined immunological metaniches (plaque and gingival crevicular

fluid; tongue and hard palate; sublingual area and cheek) (25). We chose tongue smear samples as a representative of the metaniche 'tongue and hard palate', since the tooth-associated metaniche 'plaque and gingival crevicular fluid' is cannot be found in neonates and since metaniche 'sublingual area and cheek' was characterized by overall lowest cytokine concentrations due to the high saliva flow rate in this area (25). Moreover, neither the collection of unstimulated or stimulated saliva would be possible in neonates due to well-known cooperation difficulties in this age. The advantage of the collection of tongue smear samples is the applicability in neonates, the repeatability due to the defined methodology, the non-invasiveness and the local investigation of cytokine samples in the oral cavity.

As to cytokine detection using tongue smear samples from neonates, all the analyzed cytokines (GM-CSF, INF- γ , TNF, IL-

1 β /-2/-4/-6/-8/-10) were detected presenting a broad spectrum of concentrations ranging from the highest values represented by IL-8 (10000-40000 pg/ml) to lowest values represented by IL-4 (0.3-0.9 pg/ml). Similarly, a previous study detected highest concentrations of IL-8 and lowest concentrations of IL-4 in tongue samples from young adults with periodontal health (25). Using a more invasive sampling method (collection of lip tissue during cleft surgery) and an elderly study population (4-13 months of age) without a control group, Pilmane et al. (23) found lower concentrations relatively highest concentrations of TNF (36.93 pg/mL) and low cytokine concentrations of all other measured cytokines (IL-2 1.58 pg/mL, IL-4 1.06 pg/mL, IL-6 0.59 pg/mL, IL-10 1.13 pg/mL, INF- γ 0.79 pg/mL, GM-CSF 0.70 pg/mL), which is partly in contrast to our results investigating tongue smear samples. Taken together, our non-invasive sampling method and our measurements were sensitive enough to analyze small sample volumes (with some limitations in volumes below 4 μ l requiring high dilution, mostly IL-4 and IL-10) and were able to detect even higher concentrations of cytokines compared to invasive sampling methods (23).

The oral mucosa, including the tongue mucosa, constantly interacts with the external environment and plays a pivotal role in maintaining the tolerance with the local symbiotic bacteria on the one hand and as a defense against pathologic microbes on the other (75). Thereby, epithelial cells of the oral and tongue mucosa and tissue specific immune cells communicate *via* cytokines and soluble mediators to maintain the physiological oral homeostasis (75) (Table 1). Considering healthy neonates without OFC, we found a similar order of magnitude considering cytokine concentrations at T1 compared to detected cytokines in smear samples from the tongue of orally healthy adults (25): As to longitudinal changes of the cytokine levels in tongue smear samples, we found that the concentration of most measured cytokines decreased significantly from T0 to T1 in both the CLP and the control group. In a mice model, it was reported that the oral epithelium thickened gradually after birth due to keratinization and exhibited adult features within the first month after birth resulting in less permeability and less vulnerability to microbial infections and that saliva flow was upregulated (76, 77). Further, longitudinal changes in microbial alpha diversity [species richness or evenness (78, 79)] and beta diversity [variance in species composition (78, 79)] were observed in neonates within the first weeks of life (19). Notably, while we observed a decline of cytokine levels from T0 to T1 in both groups, alpha diversity increased significantly from T0 to T1 (19). Further, while we found that differences between the OFC and control group regarding cytokine levels were more significant at T0, the distinction between both groups became more evident at T1 regarding beta diversity (19). Hence, the observed reduction of cytokine concentrations in tongue smear samples might be due to a gradual epithelium remodeling process and increased saliva flow rate changes. Interestingly, the

observed attenuated immunological reaction from T0 to T1 was contrariwise to reported increased microbial changes from T0 to T1 (19) indicating that postnatal immunological and microbial processes in the oral cavity do not always depend on each other.

Further, a significant increase of IL-2 and IL-4 from T0 to T1 was found resulting in highest levels of IL-4 at T1 in neonates without OFC. Regarding age-related changes of cytokine levels (in peripheral blood), children without OFC were characterized by a significant increase of IL-4 between 1 year and 3 years of age (63). IL-2 is an important regulator in communication of innate and adaptive immunity, e.g., by activation of T/B/NK cells (32); promotes tissue integrity, defense and tolerance in wound healing processes (50) and is a key regulator of regulation of oral mucosal inflammation (51). IL-4 is well-known for antagonistic effects in inflammatory diseases (inhibition of pro-inflammatory cytokines) (61) and enholds anti-inflammatory and immunoregulatory functions in mucosal immune reactivity (60) (Table 1). Further, IL-4 has a main role in wound healing by activation of fibroblasts, keratinocytes, neoangiogenesis and reepithelization (46) and, notably, high levels of IL-4 (or application of IL-4) were associated with accelerated mucosal wound healing (59, 62), hereby strengthening the wound (Table 1). Contemplating, the increase of IL-2 and IL-4 in healthy neonates might play an important role in maintaining oral mucosal homeostasis within the first weeks of life when neonates cope with an increase of microbiota in the oral cavity (19).

Regarding local cytokine concentrations in tongue smear samples from neonates with OFC, we found significantly higher levels of TNF, IL1- β , IL-6, IL-8 and IL-10 compared to controls at both time points. A study comparing lip tissue from infants with OFC (3-18 months) during cleft surgery compared to mucosal tissue gained during extraction therapy from adolescents with hyperdontia (non-age-matched control) showed a higher concentration of TNF in lip tissue from neonates with OFC compared to adolescent controls without OFC (24). Another study investigating lip tissue from infants with OFC (4-14 months) during cleft surgery without a control group, found overall highest concentrations of TNF compared to other measured cytokines in lip tissue from neonates with OFC (23). Considering systemic cytokine levels (in peripheral blood), infants with OFC (0-12 months) presented significantly increased levels of IL-17 and INF- γ compared to an age-matched control group, however, levels of IL-6 and IL-8 were similar in both groups (63), which is in contrast to our results found in tongue smear samples. TNF is a primary pro-inflammatory cytokine (37) and promotes vasodilatation, edema formation, leukocyte adhesion, regulation of blood coagulation (28). Remarkably, high levels of TNF were associated with surgical site infection (34) and worsening of the mucosal epithelial barrier function (40, 41), while TNF inhibitor treatment was shown to reduce surgical site infection (35, 36) (Table 1). IL1- β triggers primary pro-inflammatory

reactions by the innate immune system, e.g., by activation of IL-8 (37), primary host defence responses to injury as well as enhancement of tissue damage in injury-associated mechanisms (44) (Table 1). IL-6 promotes migration of immune cells to damaged sites (45) and increased levels were shown to alter tissue integrity (41) (Table 1). IL-8 is a secondary pro-inflammatory cytokine in inflammatory reactions by the innate immune system stimulated by IL-1 β and TNF (37, 38), induces tissue destruction by neutrophil accumulation and granules release (47, 48) and reduced IL-8 production was associated with almost scarless wound healing (49). IL-10 is commonly known as anti-inflammatory cytokine promoting oral tolerance (55), controlling the extend of inflammation in wound healing (52, 53) and down regulation of immune responses to pathogens/microbiota in mucosal inflammation (52), but it was also shown to have pro-inflammatory effects in a compromised immune-environment (54) and was shown to be upregulated during inflammatory processes and gingival inflammation when other pro-inflammatory cytokines increase, e.g. IL-2, INF- γ in gingival crevicular fluid (33, 56, 57) (Table 1). Therefore, higher levels of TNF and IL-1 β -6/-8 found in neonates with OFC might contribute to altered mucosal barrier and tissue integrity hereby increasing the risk for impaired wound healing. Notably, IL-10 seems to be upregulated next to other pro-inflammatory cytokines in the altered oral milieu of neonates with OFC.

Concerning different cleft phenotypes and severities, we detected higher levels of GM-CSF, TNF, IL-1 β -6/-8 in neonates with high cleft severity (complete UCLP/BCLP) compared to low cleft severity (CPo) at T0. Further, neonates with CPo presented significantly lower levels of IL-2 compared to UCLP/BCLP. Differences between different cleft phenotypes and severities diminished at T1 probably due to the significant reduction of cytokine levels in the BCLP group. Pilmane et al. (23) detected higher levels of IL-2, GM-CSF and TNF in lip tissue (collected during lip surgery) of neonates with UCLP/BCLP neonates compared to neonates with CPo, however, those differences were found at a later time point (4-18 months of age) and are not comparably to T0 or T1. As discussed above, both TNF, IL-1 β , IL-6 and IL-8 levels were shown to compromise mucosal barrier function (40, 41) and high levels were associated with wound healing disorders (34, 44, 49) (Table 1). GM-CSF is key player in inflammatory signaling and dendritic cell recruitment into mucosa (29) and GM-CSF activated phagocytes cause tissue damage during wound healing (26). IL-2 is an important regulator in the communication of innate and adaptive immunity, holds both anti- and pro-inflammatory functions (32), regulates oral mucosal inflammation and increases migration of immune cells, fibroblasts and capillaries into damaged tissue (hereby strengthening the wound) (45). Interestingly, treatment with IL-2 was shown to promote tissue integrity, defense, tolerance and strengthens the wound (43, 45, 50) (Table 1). Hence, neonates with high severity score and with

clefts affecting the lip and alveolus (BCLP/UCLP) presenting higher levels of GM-CSF, TNF, IL-1 β -6/-8 on tongue smear samples might therefore be more at risk for progression of inflammatory processes than neonates with low severity score or cleft of the palate only (CPo). Whereas in CPo neonates, the lack of IL-2 might be associated to surgical site infection presenting a risk for residual clefts or fistulas in the hard palate. The higher cytokine concentrations found in UCLP/BCLP neonates compared to CPo neonates might be explicated by the affection of extraoral structures hereby leading to an altered microenvironment considering different aspects: 1) The affection of extraoral structures leads to an incompetent mouth closure and increases the airflow in the oral cavity. This might not only lead to altered immune reactions, but also to more 'evaporation or dehydration'. A previous study investigating the saliva of 5-year-old children with OFC did not detect differences in saliva secretion rate (mL/min) between children with OFC compared to controls without OFC (80), however, so far no study evaluated saliva flow rate in newborns, which is probably due to the missing compliance for usual methods to measure saliva secretion rate (measuring the amount of time for collection of a defined amount of saliva using the spitting method). 2) Differences detected between CPo and UCLP/BCLP neonates regarding cytokine concentrations can be explained by altered oral microbiota in both phenotypes. Significant differences between neonates with high cleft severity (UCLP/BCLP) and low cleft severity (CPo) were found regarding beta diversity, which were more distinct at T1, and alpha diversity, presenting lowest alpha diversity in neonates with high cleft severity (UCLP/BCLP) at T0 (19). Since low alpha diversity is linked to higher inflammation levels, the low alpha diversity in UCLP/BCLP neonates might explain the higher concentrations of pro-inflammatory cytokines in neonates with UCLP/BCLP. Taken together, evaporation might play a role, but the high cytokine concentrations in UCLP/BCLP can also be elucidated by other factors, e.g., the interplay with oral microbiota.

Considering correlations between cytokines in neonates with OFC, we found strong positive correlations between 1) GM-CSF and IL-6/-8, 2) IL-1 β and TNF and 3) IL-6/-10 and TNF at T0. Notably, the cleft severity score correlated positively also with GM-CSF, IL-1 β and IL-10 at T0. During inflammatory reactions by the innate immune system, GM-CSF is capable to stimulate TNF production (28), while TNF and IL-1 β were shown to stimulate IL-8 production in mucosal cells (38, 39) and IL-6 is produced after IL-1 β , TNF and INF- γ stimulation (32) (Table 1). IL-10 was shown to inhibit the production of IL-1 β and TNF (32), however, it holds also pro-inflammatory functions in a comprised micro-environment (54) (Table 1). Similar to a previous study presenting positive correlations between IFN- γ and IL-2 as well as IL-4 with IFN- γ in lip tissue of infants with OFC (23), we also detected positive correlations between IL-2 and INF- γ and between IL-4 and IFN- γ at T1 in

OFC neonates. Control neonates were characterized by negative correlations between GM-CSF and all other cytokines at T0 and between IL-1 β -6/-8 with all other cytokines. During inflammation, a stimulation between GM-CSF and IL-1 β -6/-8 (28, 32, 38, 39) was observed (Table 1). Taken together, the cross-upregulation mechanisms between IL-1 β -6/-8 (and IL-10), TNF and GM-CSF might be linked to activation of inflammatory pathways in neonates with OFC shortly after birth, especially in neonates with high cleft severity, while in neonates without OFC a cross-regulation between those primary and secondary cytokines was not observed. Notably, while correlations between cytokine concentrations were mainly seen at T0, a previous study that microbial differences between neonates with OFC compared to controls were more distinct at T1 (19). Hence, we suppose that those cytokine interactions might be linked to prenatal or very early immunological reactions shortly after birth.

With regard to nutrition methods, the control group received breast-feeding only, while neonates with OFC presented individual nutrition modes due to feeding issues (14–17). Different nutrition methods were distributed equally with regard to cleft phenotype and severity (Table 2). Significantly higher pro-inflammatory cytokine levels (e.g., IL-6 and IL-8) were seen in bottle-fed neonates receiving mixed and completely artificial baby food compared to the breast-milk (bottle) fed group (data not shown). Breast milk encloses anti-inflammatory cytokines, e.g., TGF- β , IL-4/10, that can have an effect on oral tolerance and regulate immune responses (81). Hence, a positive impact of breast-milk (bottle) feeding on oral immunity can be supposed, however, larger sample sizes are needed in future studies and eventually further inflammatory mediators should be evaluated.

To conclude, this study showed that the sampling methodology using swabs is suitable for the detection of oral cytokine concentrations in neonates and presents a non-invasive alternative compared to tissue sampling. Further, early life physiological immune responses in the oral cavity seem to be characterized by high levels of oral inflammatory mediators after birth. Within the first weeks of life a significant decrease is detectable probably due to adaptation processes due to gradual epithelium remodeling. While a reduction of cytokine concentrations was found, a previous study detected an increase of microbial alpha and beta diversity was found in neonates within the first weeks of life (19). Hence, future studies should focus on the dissimilarities between the postnatal immunological and microbial reactions in the oral cavity within the first weeks of life and investigate whether possible prenatal immunological alterations might help to explain the presented high cytokine concentrations within the first days after birth. Interestingly, neonates without OFC were characterized by an elevation of IL-2 and IL-4 from T0 to T1 indicating that these patterns might be representable for physiological oral homeostasis (75) and ‘symbiosis’ (58, 82). Our results have high clinical relevance as we found that neonates with OFC (especially with high cleft severity) presented higher levels of pro-inflammatory cytokines. Further, pre-operative oral inflammation was associated with

failure of intraoral surgeries (20), hence, the high inflammation found in neonates with OFC in early life might be a major risk factor for pre-operative inflammation prior to lip surgery with 6–7 months of age. Since prophylactic use of antibiotics prior to cleft lip surgery did not reduce the risk for wound healing disorders (21), we assume that preventive strategies to reduce pre-surgical inflammation should start after birth or at least as long as necessary to reduce the inflammatory state. Future studies should investigate oral cytokine concentrations using the non-invasive sampling method described here to investigate cytokine concentrations prior to and after surgical lip and/or palate closure to identify subjects with enhanced risk for wound healing disorders. Further, it would be interesting to analyse whether cytokine levels remain elevated after surgical lip and palate closure since a higher prevalence for gingivitis and periodontitis was found in children and adolescents with OFC (83, 84). In case that those studies would identify neonates at risk for wound healing disorders or an association with oral diseases later in life, new preventive strategies should investigate methods to reduce oral inflammation and to guide oral immune responses towards oral homeostasis. The encouragement of mothers of neonates with OFC to bottle feed their neonates with breast-milk rather than with artificial baby food might also be beneficial especially in severe cleft cases favoring an anti-inflammatory cytokine profile and the development of oral homeostasis.

Data availability statement

The original contributions presented in the study are included in the article/Supplementary Material, further inquiries can be directed to the corresponding author.

Ethics statement

This study has been approved by the local ethics committee of the Friedrich-Alexander-University Erlangen-Nürnberg (Krankenhausstraße 12, 91054 Erlangen, Vote number: 168_20 B, 28.04.2020) prior to the beginning of the study. Written informed consent to participate in this study was provided by the participants’ legal guardian/next of kin.

Author contributions

Conceptualization, CS and LG; methodology, CS, EP, MatW; formal analysis, CS, MatW and EP; recruitment and sample collection CS, KS, MT and CU; clinical examination CS and KS; resources BF, UG and LG; cytokine analyses EP and CS; supervision of data analyses and definition of group/subgroup analyses CS; writing—original draft preparation CS and ES; review and critical discussion of cytokine-associated

statements HS; writing—review MatW, IW, ManW, MS, BF, UG, MB. and LG; supervision LG; project administration CS and KS. All authors contributed to the article and approved the submitted version.

Funding

This research funded by internal financial funding (ELAN) by the IZFK (Interdisziplinäres Zentrum für Klinische Forschung) by the Friedrich-Alexander Universität (FAU) Erlangen-Nürnberg (Grant holder: CS, Project number: P086).

Acknowledgments

The authors thank all study participants and their parents and/or legal guardians for the participation in this study. A particular debt of gratitude is owed to Prof. Dr. M. Beckmann for the ability to recruit the control group in his Department as well as all doctors and nurses helping in the recruitment process. Special thanks should also be expressed to all the local pediatricians (Erlangen), who allowed, performed and helped with the sample collections during their routine investigations: PD. Dr. C. Plank; Prof. Koch and Dr. Gerdemann; Dr. Christian Döbig; Dr. Andrea Seiler, Dr. Jasmin Pletl-Maar and Dr. Gabriele Graf; Dr. Paul Wolf; Dr. Ulrike Lehnert; Dr. Karsten Naumann; Dr. Ulrike Scharnweber; Dr. Dorothea Schmitt-Colberg; Dr. Beate Kevekordes-Stade. Moreover, we thank Dr. Fabienna Mittermeier, Dr. Karoline März-Kalb as well as all doctors and nurses helping in the recruitment process in the Department of Orthodontics and Orofacial Orthopedics.

Conflict of interest

The authors declare that the research was conducted in the absence of any commercial or financial relationships that could be construed as a potential conflict of interest.

Publisher's note

All claims expressed in this article are solely those of the authors and do not necessarily represent those of their affiliated organizations, or those of the publisher, the editors and the reviewers. Any product that may be evaluated in this article, or

claim that may be made by its manufacturer, is not guaranteed or endorsed by the publisher.

Supplementary material

The Supplementary Material for this article can be found online at: <https://www.frontiersin.org/articles/10.3389/fimmu.2022.1044249/full#supplementary-material>

SUPPLEMENTARY FIGURE 1

Schematic drawing of the LAHSHAL classification scheme and different cleft phenotypes is given: a) LAHSHAL scheme, b) Cleft Palate only (CPo), c) unilateral cleft lip and palate (UCLP) and b) bilateral cleft lip and palate (BCLP). The schematic drawing represents an occlusal view on the maxilla and a bottom view of the nose. The nose is presented on top of the scheme, followed by the lip, the vestibulum, the alveolus and the hard and soft palate and the pharynx on the bottom of the scheme. The parts affected by clefting are presented by discontinuities of the presented anatomical parts. The LAHSHAL scheme uses letters to describe the affected anatomical parts (L = lip; A = alveolus, H = hard palate, S = soft palate).

SUPPLEMENTARY FIGURE 2

Concentrations (pg/ml) of measured cytokines (Granulocyte-macrophage colony-stimulating factor = GM-CSF, Interferon gamma = INF- γ , Tumor-necrosis-factor = TNF, Interleukin (IL)-1 β -2/-4/-6/-8/-10) in different cleft types (bilateral cleft lip palate = BCLP, unilateral cleft lip palate = UCLP, cleft palate only = CPo) at both time points (T0 = after birth, T1 = 4-5 weeks after birth). A color scheme represents each cleft phenotype – time point – combination (BCLP-T0: = blue, UCLP-T0 = dark green, CPo-T0 = light green, BCLP-T1 = red, UCLP T1 = orange, CPo T1 = bright orange). The concentrations (pg/ml) of the measured cytokines (GM-CSF, INF- γ , TNF, IL-1 β -2/-4/-6/-8/-10) are represented in this panel from the top left to the bottom right histogram (a to i). Floating bars (max to min) with dots (row data) represent the cytokine concentration distributed in each CLP subset (BCLP vs. UCLP vs. CPo; n = 4-5) at each time point (T0 vs. T1). The line in the bars represents the mean. The statistical analysis between the subsets at T0 and T1 was made with the Kruskal-Wallis test. The Mann-Whitney U-Test was applied for comparison between the two time points. Differences were considered significant with p-values ≤ 0.05 .

SUPPLEMENTARY FIGURE 3

Concentrations (pg/ml) of measured cytokines (Granulocyte-macrophage colony-stimulating factor = GM-CSF, Interferon gamma = INF- γ , Tumor-necrosis-factor = TNF, Interleukin (IL)-1 β -2/-4/-6/-8/-10) in neonates with orofacial clefts at both time points (T0 = after birth, T1 = 4-5 weeks after birth) considering different nutrition modes (breast-milk (bottle) feeding (BM), mixed baby food (MF), artificial baby food (AF)). A color scheme represents each group – time point – combination (BM-T0: = green, MF-T0 = light blue, AF-T0 = dark blue, BM-T1 = orange, MF T1 = rose, AF T1 = red). The concentration of the cytokines GM-CSF, INF- γ , TNF, IL-1 β -2/-4/-6/-8/-10 is represented in this panel from the top left graph to the bottom right. Each histogram, from top to the bottom, shows the concentration of a cytokine (pg/ml) in defined group-time point-combinations. Each histogram has floating bars (mean with max to min). The circles represent the row data. The statistical analysis was made with Kruskal-Wallis test (no statistical significance) and Mann-Whitney U-Test (dotted lines). Differences were considered significant with p-values ≤ 0.05 .

References

- Emodi O, Capucha T, Shilo D, Ohayon C, Ginini JG, Ginsberg Y, et al. Trends in cleft palate incidence in the era of obstetric sonography and early detection. *J Matern Fetal Neonatal Med* (2022) 6:1–6. doi: 10.1080/14767058.2022.2032635
- Garland MA, Reynolds K, Zhou CJ. Environmental mechanisms of orofacial clefts. *Birth Defects Res* (2020) 112:1660–98. doi: 10.1002/bdr2.1830
- Voigt A, Radlanski RJ, Sarioglu N, Schmidt G. Lippen-Kiefer-Gaumen-Spalten. *Der Pathologe* (2017) 38:241–7. doi: 10.1007/s00292-017-0313-x
- Nasreddine G, El Hajj J, Ghassibe-Sabbagh M. Orofacial clefts embryology, classification, epidemiology, and genetics. *Mutat Res Rev Mutat Res* (2021) 787:108373. doi: 10.1016/j.mrrev.2021.108373
- Mangold E, Ludwig KU, Nöthen MM. Breakthroughs in the genetics of orofacial clefting. *Trends Mol Med* (2011) 17:725–33. doi: 10.1016/j.molmed.2011.07.007
- Leslie EJ, Marazita ML. Genetics of cleft lip and cleft palate. *Am J Med Genet C Semin Med Genet* (2013) 163C:246–58. doi: 10.1002/ajmg.c.31381
- Dixon MJ, Marazita ML, Beaty TH, Murray JC. Cleft lip and palate: understanding genetic and environmental influences. *Nat Rev Genet* (2011) 12:167–78. doi: 10.1038/nrg2933
- Bell JC, Raynes-Greenow C, Turner RM, Bower C, Nassar N, O'Leary CM. Maternal alcohol consumption during pregnancy and the risk of orofacial clefts in infants: a systematic review and meta-analysis. *Paediatr Perinat Epidemiol* (2014) 28:322–32. doi: 10.1111/ppe.12131
- Xuan Z, Zhongpeng Y, Yanjun G, Jiaqi D, Yuchi Z, Bing S, et al. Maternal active smoking and risk of oral clefts: a meta-analysis. *Oral Surg Oral Med Oral Pathol Oral Radiol* (2016) 122:680–90. doi: 10.1016/j.oooo.2016.08.007
- Kriens O. *What is a cleft lip and palate? proceedings of an advanced workshop*. Kriens O, editor (1989). Available at: https://openlibrary.org/books/OL21319105M/What_is_a_cleft_lip_and_palate.
- Reiter R, Haase S, Brosch S. [Orofacial clefts]. *Laryngorhinootologie* (2012) 91:84–95. doi: 10.1055/s-0031-1285886
- Hotz M, Gnoinski W. Comprehensive care of cleft lip and palate children at zürich university: a preliminary report. *Am J Orthod* (1976) 70:481–504. doi: 10.1016/0002-9416(76)90274-8
- Hotz MM, Gnoinski WM. Effects of early maxillary orthopaedics in coordination with delayed surgery for cleft lip and palate. *J Maxillofac Surg* (1979) 7:201–10. doi: 10.1016/s0301-0503(79)80041-7
- Kucukguven A, Calis M, Ozgur F. Assessment of nutrition and feeding interventions in Turkish infants with cleft lip and/or palate. *J Pediatr Nurs* (2020) 51:e39–44. doi: 10.1016/j.pedn.2019.05.024
- Miller CK. Feeding issues and interventions in infants and children with clefts and craniofacial syndromes. *Semin Speech Lang* (2011) 32:115–26. doi: 10.1055/s-0031-1277714
- Goyal M, Chopra R, Bansal K, Marwaha M. Role of obturators and other feeding interventions in patients with cleft lip and palate: a review. *Eur Arch Paediatr Dent* (2014) 15:1–9. doi: 10.1007/s40368-013-0101-0
- Palaska PK, Antonarakis GS, Suri S. A retrospective longitudinal treatment review of multidisciplinary interventions in nonsyndromic robin sequence with cleft palate. *Cleft Palate Craniofac J* (2021) 59(7):882–90. doi: 10.1177/10556656211026477
- Marzouk T, Youssef M, Tsigarida A, McKinney C, Wong C, DeLucia L, et al. Association between oral clefts and periodontal clinical measures: A meta-analysis. *Int J Paediatr Dent* (2022) 32(4):558–75. doi: 10.1111/ipd.12934
- Seidel CL WM, Tschafertari M, Strobel K, Willershausen I, Rodrian G, Unertl C, et al. Orofacial clefts alter early life oral microbiome maturation towards dysbiosis. *NPJ Biofilms Microbiomes* (2022). doi: 10.1021/2022.00000v1. online PrePrint ResearchSquare, Version 1.
- Liu L, Zhang Q, Lin J, Ma L, Zhou Z, He X, et al. Investigating oral microbiome profiles in children with cleft lip and palate for prognosis of alveolar bone grafting. *PLoS One* (2016) 11:e0155683. doi: 10.1371/journal.pone.0155683
- Wu M, Zhu ZB, Shi B, Gong CX, Li Y. Effect of the prophylactic use of antibiotics on wound infection after cleft lip surgery. *Hua Xi Kou Qiang Yi Xue Za Zhi* (2021) 39:709–11. doi: 10.7518/hxkq.2021.06.013
- Misra R, Mulligan JK, Rowland-Jones S, Zemlin M. Editorial: Autoimmunity and chronic inflammation in early life. *Front Immunol* (2021) 12:761160. doi: 10.3389/fimmu.2021.761160
- Pilmane M, Jain N, Jain S, Akota I, Kroica J. Quantification of cytokines in lip tissue from infants affected by congenital cleft lip and palate. *Children (Basel)* (2021) 8(2):140. doi: 10.3390/children8020140
- Reiser SC, Tellermann J, Akota I, Pilmane M. Profiling and characterization of localized cytokine response in congenital cleft affected lip tissue. *Life (Basel)* (2021) 11(6):556. doi: 10.3390/life11060556
- Seidel CL, Gerlach RG, Wiedemann P, Weider M, Rodrian G, Hader M, et al. Defining metaniches in the oral cavity according to their microbial composition and cytokine profile. *Int J Mol Sci* (2020) 21(21):8218. doi: 10.3390/ijms21218218
- Becher B, Tugues S, Greter M. GM-CSF: From growth factor to central mediator of tissue inflammation. *Immunity* (2016) 45:963–73. doi: 10.1016/j.immuni.2016.10.026
- Hamilton JA. GM-CSF in inflammation. *J Exp Med* (2020) 217(1):e20190945. doi: 10.1084/jem.20190945
- Zelová H, Hošek J. TNF- α signalling and inflammation: interactions between old acquaintances. *Inflammation Res* (2013) 62:641–51. doi: 10.1007/s00011-013-0633-0
- Hirata Y, Egea L, Dann SM, Eckmann L, Kagnoff MF. GM-CSF-facilitated dendritic cell recruitment and survival govern the intestinal mucosal response to a mouse enteric bacterial pathogen. *Cell Host Microbe* (2010) 7:151–63. doi: 10.1016/j.chom.2010.01.006
- Schroder K, Hertzog PJ, Ravasi T, Hume DA. Interferon-gamma: an overview of signals, mechanisms and functions. *J Leukoc Biol* (2004) 75:163–89. doi: 10.1189/jlb.0603252
- Ye L, Schnepf D, Staeheli P. Interferon- λ orchestrates innate and adaptive mucosal immune responses. *Nat Rev Immunol* (2019) 19:614–25. doi: 10.1038/s41577-019-0182-z
- Nesin M, Cunningham-Rundles S. Cytokines and neonates. *Am J Perinatol* (2000) 17:393–404. doi: 10.1055/s-2000-13457
- Ng PC, Li K, Wong RP, Chui K, Wong E, Li G, et al. Proinflammatory and anti-inflammatory cytokine responses in preterm infants with systemic infections. *Arch Dis Child Fetal Neonatal Ed* (2003) 88:F209–213. doi: 10.1136/fn.88.3.f209
- Saika S. Yin and yang in cytokine regulation of corneal wound healing: roles of TNF- α . *Cornea* (2007) 26:S70–74. doi: 10.1097/ICO.0b013e31812f6d14
- Ksontini R, MacKay SL, Moldawer LL. Revisiting the role of tumor necrosis factor alpha and the response to surgical injury and inflammation. *Arch Surg* (1998) 133:558–67. doi: 10.1001/archsurg.133.5.558
- Berksoy Hayta S, Durmuş K, Altuntaş EE, Yıldız E, Hisarciklio M, Akyol M. The reduction in inflammation and impairment in wound healing by using strontium chloride hexahydrate. *Cutaneous Ocular Toxicol* (2018) 37:24–8. doi: 10.1080/15569527.2017.1326497
- Tetyczka C, Hartl S, Jeitler R, Absenger-Novak M, Meindl C, Fröhlich E, et al. Cytokine-mediated inflammation in the oral cavity and its effect on lipid nanocarriers. *Nanomaterials (Basel)* (2021) 11(5):1330. doi: 10.3390/nano11051330
- Mitsuyama K, Toyonaga A, Sasaki E, Watanabe K, Tateishi H, Nishiyama T, et al. IL-8 as an important chemoattractant for neutrophils in ulcerative colitis and crohn's disease. *Clin Exp Immunol* (1994) 96:432–6. doi: 10.1111/j.1365-2249.1994.tb06047.x
- Miller D, Turner SW, Spiteri-Cornish D, McInnes N, Scaife A, Danielian PJ, et al. Culture of airway epithelial cells from neonates sampled within 48-hours of birth. *PLoS One* (2013) 8:e78321. doi: 10.1371/journal.pone.0078321
- Droessler L, Cornelius V, Markov AG, Amasheh S. Tumor necrosis factor alpha effects on the porcine intestinal epithelial barrier include enhanced expression of TNF receptor 1. *Int J Mol Sci* (2021) 22(16):8746. doi: 10.3390/ijms22168746
- Kim HJ, Li H, Collins JJ, Ingber DE. Contributions of microbiome and mechanical deformation to intestinal bacterial overgrowth and inflammation in a human gut-on-a-chip. *Proc Natl Acad Sci United States America* (2016) 113:E7–15. doi: 10.1073/pnas.1522193112
- Shinozaki M, Okada Y, Kitano A, Ikeda K, Saika S, Shinozaki M. Impaired cutaneous wound healing with excess granulation tissue formation in TNF α -null mice. *Arch Dermatol Res* (2009) 301:531–7. doi: 10.1007/s00403-009-0969-z
- Doersch KM, DelloStritto DJ, Newell-Rogers MK. The contribution of interleukin-2 to effective wound healing. *Exp Biol Med* (2016) 242:384–96. doi: 10.1177/1535370216675773
- Lopez-Castejon G, Brough D. Understanding the mechanism of IL-1 β secretion. *Cytokine Growth Factor Rev* (2011) 22:189–95. doi: 10.1016/j.cytogfr.2011.10.001
- DeCunzio LP, Mackenzie JW, Marafino BJ Jr., Devereux DF. The effect of interleukin-2 administration on wound healing in adriamycin-treated rats. *J Surg Res* (1990) 49:419–27. doi: 10.1016/0022-4804(90)90190-d

46. Komi DEA, Khomtchouk K. & Santa maria, p. l. a review of the contribution of mast cells in wound healing: Involved molecular and cellular mechanisms. *Clin Rev Allergy Immunol* (2020) 58:298–312. doi: 10.1007/s12016-019-08729-w
47. Baggiolini M, Clark-Lewis I. Interleukin-8, a chemotactic and inflammatory cytokine. *FEBS Lett* (1992) 307:97–101. doi: 10.1016/0014-5793(92)80909-z
48. Lacy P. Mechanisms of degranulation in neutrophils. *Allergy Asthma Clin Immunol* (2006) 2:98–108. doi: 10.1186/1710-1492-2-3-98
49. Liechty KW, Crombleholme TM, Cass DL, Martin B, Adzick NS. Diminished interleukin-8 (IL-8) production in the fetal wound healing response. *J Surg Res* (1998) 77:80–4. doi: 10.1006/jsre.1998.5345
50. Pickard JM, Zeng MY, Caruso R, Núñez G. Gut microbiota: Role in pathogen colonization, immune responses, and inflammatory disease. *Immunol Rev* (2017) 279:70–89. doi: 10.1111/imr.12567
51. Li M, Li R. IL-2 regulates oral mucosa inflammation through inducing endoplasmic reticulum stress and activating the NF- κ B pathway. *J Recept Signal Transduct Res* (2020) 40:187–93. doi: 10.1080/10799893.2020.1725570
52. Wei H-X, Wang B, Li B. IL-10 and IL-22 in mucosal immunity: Driving protection and pathology. *Front Immunol* (2020) 11:1315. doi: 10.3389/fimmu.2020.01315
53. Saraiva M, Vieira P, O'Garra A. Biology and therapeutic potential of interleukin-10. *J Exp Med* (2020) 217(1):e20190418. doi: 10.1084/jem.20190418
54. Melgar S, Yeung MM, Bas A, Forsberg G, Suhr O, Oberg A, et al. Over-expression of interleukin 10 in mucosal T cells of patients with active ulcerative colitis. *Clin Exp Immunol* (2003) 134:127–37. doi: 10.1046/j.1365-2249.2003.02268.x
55. Strobel S, Mowat AM. Immune responses to dietary antigens: oral tolerance. *Immunol Today* (1998) 19:173–81. doi: 10.1016/s0167-5699(97)01239-5
56. Azatyan V, Yessayan L, Shmavonyan M, Melik-Andreasyan G, Perikhanian A, Porkshenyan K. Evaluation of IL-2, IL-10, IL-4 and γ -interferon levels in the oral fluids of patients with hepatitis C, B and HIV. *J Infect Dev Ctries* (2019) 13:69s–74s. doi: 10.3855/jidc.10919
57. Fenol A, Sasidharan RK, Krishnan S. Levels of interleukin -10 in gingival crevicular fluid and its role in the initiation and progression of gingivitis to periodontitis. *J Oral Hygiene Health* (2014) 2014:1–7. doi: 10.4172/2332-0702.1000135
58. Hajishengallis G. Periodontitis: from microbial immune subversion to systemic inflammation. *Nat Rev Immunol* (2015) 15:30–44. doi: 10.1038/nri3785
59. Salmon-Ehr V, Ramont L, Godeau G, Birembaut P, Guenounou M, Bernard P, et al. Implication of interleukin-4 in wound healing. *Lab Invest* (2000) 80:1337–43. doi: 10.1038/labinvest.3780141
60. West GA, Matsuura T, Levine AD, Klein JS, Fiocchi C. Interleukin 4 in inflammatory bowel disease and mucosal immune reactivity. *Gastroenterology* (1996) 110:1683–95. doi: 10.1053/gast.1996.v110.pm8964392
61. Woodward EA, Prêle CM, Nicholson SE, Kolesnik TB, Hart PH. The anti-inflammatory effects of interleukin-4 are not mediated by suppressor of cytokine signalling-1 (SOCS1). *Immunology* (2010) 131:118–27. doi: 10.1111/j.1365-2567.2010.03281.x
62. Slomiany BL, Piotrowski J, Slomiany A. Role of endothelin-1 and interleukin-4 in buccal mucosal ulcer healing: effect of chronic alcohol ingestion. *Biochem Biophys Res Commun* (1999) 257:373–7. doi: 10.1006/bbrc.1999.0483
63. Nesterova I, Mitropanova M, Chudilova G, Lomtadze L. Osteocalcin and regulatory cytokine imbalance in children with congenital cleft lip and palate. *Immunol Med* (2020) 43:130–4. doi: 10.1080/25785826.2020.1775465
64. Syrjäläinen S, et al. Salivary cytokine biomarker concentrations in relation to obesity and periodontitis. *J Clin Med* (2019) 8(12):2152. doi: 10.3390/jcm8122152
65. Justino AB, Teixeira RR, Peixoto LG, Jaramillo OLB, Espindola FS. Effect of saliva collection methods and oral hygiene on salivary biomarkers. *Scand J Clin Lab Invest* (2017) 77:415–22. doi: 10.1080/00365513.2017.1334261
66. Barros SP, Williams R, Offenbacher S, Morelli T. Gingival crevicular fluid as a source of biomarkers for periodontitis. *Periodontol* (2016) 70:53–64. doi: 10.1111/prd.12107
67. Tsuchida S, Satoh M, Takiwaki M, Nomura F. Current status of proteomic technologies for discovering and identifying gingival crevicular fluid biomarkers for periodontal disease. *Int J Mol Sci* (2018) 20:86. doi: 10.3390/ijms20010086
68. Delima AJ, Karatzas S, Amar S, Graves DT. Inflammation and tissue loss caused by periodontal pathogens is reduced by interleukin-1 antagonists. *J Infect Dis* (2002) 186:511–6. doi: 10.1086/341778
69. Thunell DH, Tymkiw KD, Johnson GK, Joly S, Burnell KK, Cavanaugh JE, et al. A multiplex immunoassay demonstrates reductions in gingival crevicular fluid cytokines following initial periodontal therapy. *J periodontal Res* (2010) 45:148–52. doi: 10.1111/j.1600-0765.2009.01204.x
70. Holmlund A, Hånström L, Lerner UH. Bone resorbing activity and cytokine levels in gingival crevicular fluid before and after treatment of periodontal disease. *J Clin periodontol* (2004) 31:475–82. doi: 10.1111/j.1600-051X.2004.00504.x
71. Buchbender M, et al. Investigation of the expression of inflammatory markers in oral biofilm samples in patients with systemic sclerosis and the association with clinical periodontal parameters—a preliminary study. *Life (Basel)* (2021) 11(11):1145. doi: 10.3390/life11111145
72. Lai J, German J, Hong F, Tai SS, McPhaul KM, Milton DK, et al. Comparison of saliva and midturbinate swabs for detection of SARS-CoV-2. *Microbiol Spectr* (2022) 10:e0012822. doi: 10.1128/spectrum.00128-22
73. Abasiyanik MF, Flood B, Lin J, Ozcan S, Rouhani SJ, Pyzer A, et al. Sensitive detection and quantification of SARS-CoV-2 in saliva. *Sci Rep* (2021) 11:12425. doi: 10.1038/s41598-021-91835-7
74. Kojima N, Turner F, Slepnev V, Bacelar A, Deming L, Kodeboyina S, et al. Self-collected oral fluid and nasal swabs demonstrate comparable sensitivity to clinician collected nasopharyngeal swabs for coronavirus disease 2019 detection. *Clin Infect Dis* (2020) 73:e3106–9. doi: 10.1093/cid/ciaa1589
75. Şenel S. An overview of physical, microbiological and immune barriers of oral mucosa. *Int J Mol Sci* (2021) 22(15):7821. doi: 10.3390/ijms22157821
76. Koren N, Zubeidat K, Saba Y, Horev Y, Barel O, Wilharm A, et al. Maturation of the neonatal oral mucosa involves unique epithelium-microbiota interactions. *Cell Host Microbe* (2021) 29:197–209.e195. doi: 10.1016/j.chom.2020.12.006
77. Zenobia C, Luo XL, Hashim A, Abe T, Jin L, Chang Y, et al. Commensal bacteria-dependent select expression of CXCL2 contributes to periodontal tissue homeostasis. *Cell Microbiol* (2013) 15:1419–26. doi: 10.1111/cmi.12127
78. Walters KE, Martiny JBH. Alpha-, beta-, and gamma-diversity of bacteria varies across habitats. *PLoS One* (2020) 15:e0233872. doi: 10.1371/journal.pone.0233872
79. Whittaker RH. Vegetation of the siskiyou mountains, Oregon and California. *Ecol Monogr* (1960) 30:279–338. doi: 10.2307/1943563
80. Sundell AL, Ullbro C, Dahlén G, Marcusson A, Twetman S. Salivary microbial profiles in 5-year old children with oral clefts: a comparative study. *Eur Arch Paediatr Dent* (2018) 19:57–60. doi: 10.1007/s40368-018-0326-z
81. Dawod B, Marshall JS. Cytokines and soluble receptors in breast milk as enhancers of oral tolerance development. *Front Immunol* (2019) 10:16. doi: 10.3389/fimmu.2019.00016
82. Hajishengallis G. Immunomicrobial pathogenesis of periodontitis: keystones, pathobionts, and host response. *Trends Immunol* (2014) 35:3–11. doi: 10.1016/j.it.2013.09.001
83. Passinato Gheller SA, Porto AN, Borba AM, Veiga KA, Aranha AMF. Periodontal findings in children and adolescents with cleft lip and/or palate: A case-control study. *Pediatr Dent* (2021) 43:133–9.
84. Veiga KA, Porto AN, Matos FZ, de Brito PC, Borges ÁH, Volpato LE, et al. Caries experience and periodontal status in children and adolescents with cleft lip and palate. *Pediatr Dent* (2017) 39:139–44.

Glossary

A	Alveolous (LAHSHAL code)
BCLP	Bilateral cleft lip and cleft palate
C	caesarian
CCA	constrained correspondence analysis
CLo	Cleft lip only
CLP	Cleft lip and cleft palate
cm	centimeter
CPo	Cleft palate only
d	days
d.n.s.	data not shown
f	female
g	grams
GM-CSF	Granulocyte-macrophage colony-stimulating factor
H	Hard Palate (LAHSHAL code)
IL	Interleukin
INF- γ	Interferon gamma
L	Lip (LAHSHAL code)
m	male
n	number
NAM	Nasoalveolar Molding
NGS	next generation sequencing
OFC	Orofacial clefts
p	Cleft of the primary palate
pAM	Passive Alveolar Molding
ps	cleft of the primary and secondary palate
s	Cleft of the secondary palate
S	Soft Palate (LAHSHAL code)
T	Tongue
T0	Time Point T0 after birth
T1	Time point T1 4-5 weeks after birth
TNF	tumor necrosis factor
UCLP	Unilateral cleft lip and cleft palate
v	vaginal



OPEN ACCESS

EDITED BY

Xiuzhen Sheng,
Ocean University of China, China

REVIEWED BY

Dayong Liu,
Tianjin Medical University, China
Jian Li,
National Institutes of Health (NIH),
United States

*CORRESPONDENCE

Dunfang Zhang
✉ izdf@163.com

SPECIALTY SECTION

This article was submitted to
Mucosal Immunity,
a section of the journal
Frontiers in Immunology

RECEIVED 19 December 2022

ACCEPTED 23 January 2023

PUBLISHED 02 February 2023

CITATION

Zhan Q, Zhang J, Lin Y, Chen W, Fan X and
Zhang D (2023) Pathogenesis and
treatment of Sjogren's syndrome:
Review and update.
Front. Immunol. 14:1127417.
doi: 10.3389/fimmu.2023.1127417

COPYRIGHT

© 2023 Zhan, Zhang, Lin, Chen, Fan and
Zhang. This is an open-access article
distributed under the terms of the [Creative
Commons Attribution License \(CC BY\)](#). The
use, distribution or reproduction in other
forums is permitted, provided the original
author(s) and the copyright owner(s) are
credited and that the original publication in
this journal is cited, in accordance with
accepted academic practice. No use,
distribution or reproduction is permitted
which does not comply with these terms.

Pathogenesis and treatment of Sjogren's syndrome: Review and update

Qipeng Zhan, Jianan Zhang, Yubin Lin, Wenjing Chen,
Xinzou Fan and Dunfang Zhang*

State Key Laboratory of Biotherapy and Cancer Center, Department of Biotherapy, Collaborative
Innovation Center of Biotherapy, West China Hospital, Sichuan University, Chengdu, Sichuan, China

Sjogren's syndrome (SS) is a chronic autoimmune disease accompanied by multiple lesions. The main manifestations include dryness of the mouth and eyes, along with systemic complications (e.g., pulmonary disease, kidney injury, and lymphoma). In this review, we highlight that IFNs, Th17 cell-related cytokines (IL-17 and IL-23), and B cell-related cytokines (TNF and BAFF) are crucial for the pathogenesis of SS. We also summarize the advances in experimental treatment strategies, including targeting Treg/Th17, mesenchymal stem cell treatment, targeting BAFF, inhibiting JAK pathway, et al. Similar to that of SLE, RA, and MS, biotherapeutic strategies of SS consist of neutralizing antibodies and inflammation-related receptor blockers targeting proinflammatory signaling pathways. However, clinical research on SS therapy is comparatively rare. Moreover, the differences in the curative effects of immunotherapies among SS and other autoimmune diseases are not fully understood. We emphasize that targeted drugs, low-side-effect drugs, and combination therapies should be the focus of future research.

KEYWORDS

sjogren's syndrome, foxp3 + treg, th17 cells, JAK pathway, tumor necrosis factor, interferon

1 Introduction

Sjogren's syndrome (SS) is a chronic autoimmune disease associated with functional disorders of the exocrine glands (e.g., parotid and lacrimal glands) and extraglandular manifestations. In 1892, JH Mikulicz reported the first case of SS. In 1933, the Danish ophthalmologist Sjogren reported on 19 female patients with dryness of the mouth and eyes, 13 of whom had rheumatoid arthritis (RA). To distinguish this ailment from xerophthalmia (vitamin A-deficiency-related dryness of the eyes), Sjogren defined the syndrome as keratoconjunctivitis sicca. KJ Bloch presented the clinical features of the currently recognized syndrome and introduced primary Sjogren's syndrome and secondary Sjogren's syndrome, which presents without and with an independent connective tissue disease (CTD), respectively (1).

According to a worldwide epidemiological study based on PubMed and Embase data, the incidence rate of SS is 6.92 per 100 000 person-years and the prevalence rate is 60.82 cases per 100 000 inhabitants, or 1 case per 1644 persons. Moreover, the age of patients peaks at 56. In

the last 15 years, the disease has affected females more than males (2). Patients with SS experience an enduring and intolerable pain with multiple physical symptoms, such as dental caries, vaginal dryness, and arthralgia (3).

Given the immense social and economic burden caused by SS, we aimed in this review to characterize the current paradigm of the pathogenesis and treatment of SS to motivate and inform the development of efficient treatment strategies, particularly immunological treatments.

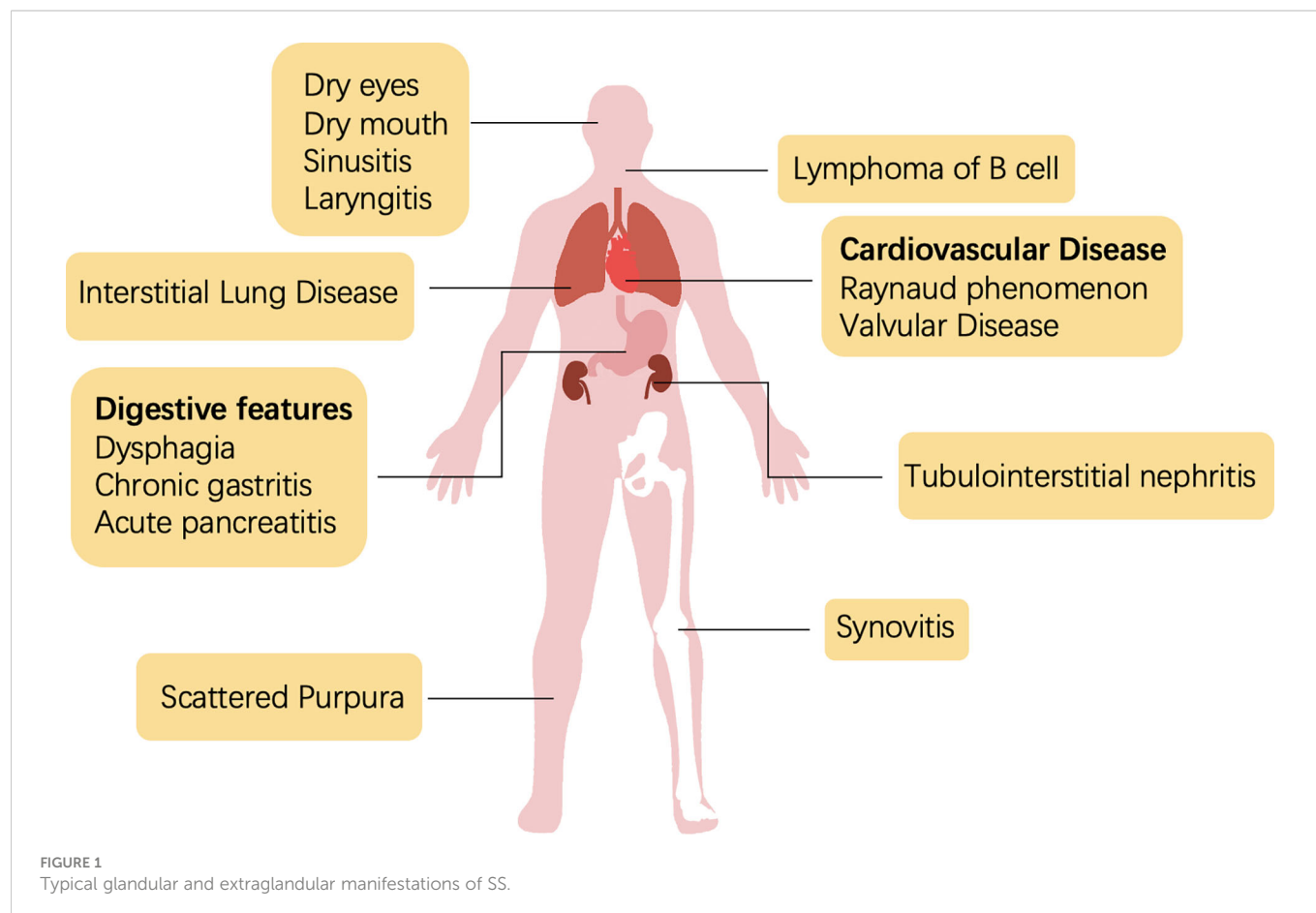
2 Brief review of clinical manifestations

Sjogren's syndrome is a systemic disease with heterogeneous manifestations that involve disorders or damage to the tissues of the exocrine glands (Figure 1). The diagnosis of SS is a multistep process, including the evaluation of oral and ocular dryness, detection of anti-SSA/Ro and anti-SSB/La antibodies, and glandular biopsy. Dryness of the eyes and mouth, which is caused by the dysfunction of salivary and lacrimal glands, is the most salient and common clinical symptom. Severe sicca symptoms of the eyes and mouth profoundly impede quality of life. An aqueous-deficient mouth has a severe effect on oral health and is associated with an increased risk of developing caries (4). A recent study reported that the oral microbiome of patients with SS who have salivary hypofunction was under stress and dysregulated; *Veillonella parvula* is a potential biomarker of Sjogren's syndrome (5).

Because SS presents with multiple extraglandular manifestations (Figure 1), the European Alliance of Associations for Rheumatology (EULAR) developed The EULAR SS disease activity index (ESSDAI) to assess disease activity in patients with sicca symptoms and simplify diagnosis. ESSDAI evaluates the severity of disease within 12 clinical domains (i.e., constitutional, lymphadenopathy, glandular, articular, cutaneous, pulmonary, renal, muscular, peripheral nervous system, central nervous system, hematological, biological), and it aims to obtain a standardized evaluation in clinical trials and practice (6).

The involvement of the nervous system was first reported in the 1980s (7). Several neurological diseases have since been associated with SS (8–12), which indicates the importance of precise neurological diagnostic assessments. Interstitial lung disease (ILD) is the most frequent and severe pulmonary complication of SS and contributes substantially to morbidity and mortality. In an Italian cohort, approximately 20% of patients with comorbid SS presented with ILD, and approximately 10% presented with amyloidosis and primary lung lymphoma (13). Efficient clinical examination, including lung biopsy or screening of serological markers, could assist in the early diagnosis and intervention of SS-ILD (13). Unfortunately, no effective treatment strategy exists for SS-ILD (14). As an autoimmune disease, SS can also lead to synovitis and RA, with the latter causing structural damage. A previous study showed that the medication strategy of RA had some success in SS, but the best-performing regimen is unclear (15).

Renal complications have only been observed in less than 10% of patients with SS. Tubulointerstitial nephritis (TIN), caused by



lymphocyte infiltration around the renal tubes, occurs in two-thirds of patients with SS and renal dysfunction (16, 17). However, the low prevalence of renal manifestations may be an artefact of the ineffective diagnosis of TIN (18). Non-Hodgkin's lymphoma (NHL) is the most severe extraglandular complication of SS, with the B cell type being predominant (occurs in approximately 5% of SS cases) (19). Hypergammaglobulinemia or the aberrant expression of other antigens in the blood stimulate the expansion of rheumatoid factor-reactive B cells (20). Meanwhile, B lymphocyte-activating factor (BAFF) and germinal center (GC)-like structures amplify the activation of B cells (21, 22). Some studies have reported that SS-NHL is also associated with abnormal activation of nuclear factor kappa B (NF- κ B) (23, 24). Additionally, a multicenter clinical study showed that more than a quarter of patients with SS presented systemic symptoms beyond the current ESSDAI classification, including cardiovascular; digestive; pulmonary; ear, nose, and throat (ENT); cutaneous; and urological features (25).

3 Pathogenesis

3.1 Brief introduction

In a 2013 review by G Nocturne and X Mariette of the pathogenesis of SS (26), three key steps were identified based on the initial genome-wide association study (GWAS): aberrant activation of the innate immune response, especially through the interferon (IFN) and NF- κ B pathways, atypical recruitment to lymphoid follicles mediated by CXCR5, and T cell activation with ascending HLA susceptibility along the IL-12-IFN- γ axis. BAFF was considered to be vital in coordinating the innate and adaptive immune responses to the disease. They also highlighted the pathophysiological role of natural killer (NK) and epithelial cells as well as the dysfunction of the neuroendocrine system.

Mavragani et al. reviewed the treatment strategies and molecular targets of the innate and adaptive immunity pathways (27). Regarding the regulation of innate immunity, previous research focused on inhibiting the production of proinflammatory factors, such as IL-1, IL-6, and tumor necrosis factor- α (TNF- α), which has proven to be effective in other autoimmune diseases. IFN-associated pathway inhibitors were another research topic of interest. For example, downregulating the expression of the primary dendritic cell surface receptor ILT7 to reduce TLR7/9-mediated IFN production was considered a potential treatment route. Regarding adaptive immunity, previous research focused on antigen presentation, co-stimulation, B-cell activation, T-cell proliferation, and germinal center formation. Overall, most strategies were aimed at regulating aberrant inflammation.

3.2 IFN

IFN is an immunoregulatory protein that promotes innate and acquired immunity and antiviral activation. IFN is categorized into three types based on structure and origin, i.e., I, II, and III. In 1981, researchers detected type-I IFN in the blood of patients with

autoimmune disease, and linked its expression to the clinical manifestations (28). IFN-I plays an important role in the progression of SS by promoting the activity of immune cells, such as NK cells, CD8⁺ T cells, and even macrophages. In addition, dendritic cells, the main producers of IFN-I, were observed in the salivary glands of patients with SS, which suggests a role for IFN-I in the formation of salivary gland lesions (29, 30) (31, 32).

IFN activates the overexpression of canonical interferon-stimulated genes (ISGs) through the Janus kinase (JAK)-STAT signaling pathway, which is defined as the "interferon signature." IFN phosphorylates STAT1, STAT2, STAT3, and STAT5, which activate downstream signals leading to the activation of immune cells (33–35). This signature in gene expression is considered a biomarker of autoimmune diseases (36).

Under physiological conditions, *in vitro*-derived pathogens or *in vivo*-derived apoptotic cells can trigger a rapid innate immune response through pattern recognition receptors (PRRs), including TLRs, RLRs, and NLRs (37). PRRs can recognize nucleic acids and induce the production of numerous proinflammatory cytokines and type I IFNs; thus, aberrant activation of the self-antigen recognition Toll-like receptor (TLR) leads to the development of autoimmune disease (38).

Some studies have reported the enhanced expression of the cell adhesion molecules VACM-1, ICAM-1, and programmed death ligand-1 (PD-L1) in patients with SS (39–41). The aberrant expression of these cytokines is mediated by IFN-I and IFN-II through the JAK-STAT pathway (42, 43). A recent study used reactive oxygen species (ROS) and N-acetylcysteine (NAC) to induce or block the expression of ICAM-1 and PD-L1 and revealed that the IFN signature that regulates the expression of ICAM-1 and PD-L1 in SS was related to oxidative stress (43–45).

Several recent studies have suggested that IFN-III contributes to SS. Type III IFNs, which consist of IFN- λ 1, IFN- λ 2, IFN- λ 3, and IFN- λ 4, are mainly produced by plasmacytoid dendritic cells (pDCs) (46, 47). pDCs respond to the secretion of IFN-III and show improved survival under stimulation with IFN-III *in vitro*. IFN-III enhances the production of IFN-I and TNF- α in pDCs and promotes the expression of CD80 and CD86, which contribute to the maturation of pDCs (35). IFN-III regulates the immune response by upregulating the polarization of Th1 and CD8⁺ T cells and downregulating Th2 cytokines and Tregs (48).

3.3 Genome loci associated with SS

Etiological research has revealed the pathogenesis of SS at the genomic level. A GWAS of autoimmune diseases identified an association between HLA regions and SS, including HLA-DR, HLA-DQB1, and HLA-DQA1 (Table 1). The allele with the strongest association was HLA-DQB1*0201 ($P_{\text{meta}} = 1.38 \times 10^{-95}$). All HLA alleles were correlated with the expression of rs115575857. In addition, six non-HLA regions that surpassed the suggestive threshold ($P_{\text{meta}} < 5 \times 10^{-5}$) were also shown to be involved in SS, including *IRF5*, *STAT4*, *BLK*, *IL-12A*, *TNIP1*, and *CXCR5*, with the expression of *IRF5* and *STAT4* being the most significant contributors after HLA regions (Table 1) (49).

TABLE 1 Genome loci associated with SS.

Gene loci	SNP	Encoding protein	Effect pathway	P value of Meta-analysis
HLA	rs112357081	MHC-II	Antigen presentation	$7.65 \times 10^{-114} \sim 1.37 \times 10^{-85}$
	rs3135394			
	rs115575857			
	rs3129716			
	rs116232857			
	rs9271588			
IRF5	rs3757387	Interferon regulatory factor 5	Activate IFN	$2.73 \times 10^{-19} \sim 3.20 \times 10^{-6}$
	rs4728142			
	rs17339836			
	rs17338998			
	rs10954213			
IL-12A	rs485497 rs583911	Interleukin-12 α	T-cell-independent production of IFN	$1.17 \times 10^{-10} \sim 9.88 \times 10^{-9}$
BLK	rs2736345	B lymphocyte kinase	Activate B cells	$4.97 \times 10^{-10} \sim 7.96 \times 10^{-8}$
	rs2729935			
	rs6998387			
CXCR5	rs7119038	CXC chemokine receptor 5	Mediate migration of B cells	$1.10 \times 10^{-8} \sim 6.82 \times 10^{-8}$
	rs4936443			
TNIP1	rs6579837	TNFAIP3-interacting protein 1	Regulate NF- κ B	$3.30 \times 10^{-8} \sim 5.32 \times 10^{-7}$
	rs7732451			
STAT4	rs10553577	signal transducer and activator of transcription 4	Regulate differentiation of helper T cells	$6.80 \times 10^{-15} \sim 9.45 \times 10^{-9}$
	rs13426947			

Various genome loci were reported to be associated with the pathogenesis of SS. Both HLA regions (HLA-DR, HLA-DQB1, HLA-DQA1) and non-HLA regions (IRF5, STAT4, BLK, IL-12A, TNIP1, and CXCR5) were established as risk loci.

3.4 Type 17 helper T (Th17) cells/IL-17

Th17 cells are distinct from Th1/Th2 cells and regulate immune responses independently (50, 51). Th17 cells polarize naïve T cells after stimulation by TGF- β and IL-6 from antigen-presenting cells (APCs). IL-1 β secreted from the ductal epithelium and IL-23 secreted from DCs also participate in Th17 cell polarization. IL-17 and IL-22 are produced by and are the main effective cytokines of Th17 cells. Th17 cells mediate inflammation by producing the proinflammatory cytokines TNF- α and IL-6 (52). Previous research revealed that IL-17/IL-23 expression was enhanced in mouse models with SS, indicating that Th17 participated in lymphocytic infiltration of salivary glands and contributed to lesion formation (53, 54). Another study showed that IL-22, IL-23, and IL-17 were increased in the peripheral blood of patients with SS, both at the protein and mRNA levels. Notably, in addition to Th17 cells, NKp44⁺ NK cells can also produce IL-17 in patients with SS (55). Besides, Th17 cells are potent inducers of matrix metalloproteinase 1 (MMP1) and MMP3 (56), and a study has shown that SS is related to disorders of MMP3/tissue inhibitor of metalloproteinase 1 (TIMP1) and MMP9/TIMP1 ratios (57).

Both Treg and Th17 cells can be induced by TGF- β from activated T cells, indicating that there might be a balance between these opposing inflammation-related cells. An imbalance in the Th17/Treg ratio has

been reported in several other autoimmune diseases, including inflammatory bowel disease (IBD) (58, 59), autoimmune thyroid disease (AITD) (60), psoriasis (61), multiple sclerosis (62), and RA (63, 64). In these diseases, function and stability of Treg cells are impaired, and the aberrant induction and proliferation of Th17 cells result in the activation of other immune cells, which then drive an acute autoimmune response. Metabolic pathways play an important role in the regulation of the Th17-Treg cell network. Th17 cells are glycolysis-dependent; thus, by inhibiting the mammalian target of rapamycin (mTOR) pathway with rapamycin, glycolysis is inhibited and the polarization of Th17 cells is decreased, whereas the expression of Treg cells is increased (65). Tregs tend to increase glycolysis and enhance fatty acid oxidation, while Th17 cells rely on fatty acid synthesis (66). However, current metabolic models of Th17/Treg cell regulation through the glycolysis pathway are inconclusive. Fortunately, Compass (67), a powerful algorithm based on scRNA-sequencing and flux balance analysis, was recently produced to predict the relationship between cellular metabolic states and pathogenicity, and has already been utilized in research on the Th17-Treg network.

Type 17 follicular helper T (Tfh17) and IL-17-producing B (B17) cells also contribute to IL-17 production. A recent study revealed that the number of IL-17-producing cells increased in the peripheral blood and spleen of NOD/ShiLtJ mice with STZ-induced type I diabetes and

SS. Surprisingly, the infiltration of IL-17-producing cells in the salivary glands increased in metabolically disordered murine models, and was also associated with greater severity of SS (68). It was subsequently found that the aberrant expression of IL-17 induced by metabolic abnormalities contributed to cell lesions and inhibition of tissue recovery in the salivary glands of patients with SS. Furthermore, retinoic A deficiency can exacerbate the imbalance in the Th17/Treg ratio in patients with SS (69).

3.5 TNF/BAFF

TNF- α is predominantly produced by macrophages and T cells in two forms: soluble TNF- α (sTNF- α) and transmembrane TNF- α (Tm TNF- α). sTNF- α is an effective regulator of inflammation and autoimmune diseases (70). TNF- α can bind with TNFR1 or TNFR2 and mediate inflammation by activating the NF- κ B pathway and mitogen-activated protein kinases (MAPKs) (71).

BAFF (or BLyS) is a member of the TNF family that plays a vital role in B cell survival. Usually, BAFF is produced by neutrophils, macrophages, monocytes, DCs, and follicular DCs (72). Increased levels of IFN- γ , IL-10, and G-CSF can induce the expression of BAFF, while TLR3, TLR4, or TLR9 participate in BAFF production (73, 74). B cells express BAFF receptors (BAFF-R or BR3), as well as TACI and BCMA. A previous study reported that BAFF binds to BAFF-R and enhances the conversion of NF- κ B2/p100 to p52 (75). Additionally, BAFF binds to BAFF-R, activating the PI3K-AKT1 pathway, which regulates the activation of myeloid cell leukemia sequence 1 (MCL1) and inhibits BCL-2-interacting mediator of cell death (BIM). TNF receptor-associated factor 3 (TRAF3) and TRAF2 are intracellular signaling molecules that bind to BAFF-R or TACI. BAFF-R interacts with BAFF and recruits TRAF3, resulting in the degradation of TRAF3 and inhibition of the NF- κ B pathway. Nevertheless, the binding of TACI and BAFF results in the recruitment of TRAF2 or TRAF6 and promotes the activation of the NF- κ B pathway (72).

BAFF participates in the pathogenesis of various autoimmune diseases, including RA (76), SLE (77), Graves' disease (78), and anti-GBM disease (79). Overexpression of BAFF elevates MHC-II expression, enhances lymphocytic infiltration, and increases the number of germinal center (GC)-like structures in SS murine models (80). Increased GC-like structures are associated with enhanced production of rheumatoid factor, anti-RO/SSA, anti-La/SSB, and IgG in patients with SS (81). However, another study claimed that BAFF is unable to mediate the differentiation of B cells from GCs, which suggests the involvement of the inhibitory BAFF-TACI pathway (80). Furthermore, BAFF stimulates monocyte through binding with BAFF-R and fosters the production of IL-6, which induces the aberrant production of IgG from B cells in SS (82).

3.6 Wingless/integrated signaling pathway

The Wnt signaling pathway is involved in several biological processes, including cellular migration, proliferation, differentiation, apoptosis, tissue homeostasis and regeneration, and stem cell self-renewal (83). Dysregulation of the Wnt/ β -catenin pathway plays a vital role in the pathogenesis of many cancers and autoimmune diseases (84, 85).

The role of the Wnt signaling pathway in T cell differentiation and immune regulation has been elucidated (86–88). The disorder of Wnt signaling inhibitors in autoimmune diseases was also noticed. Proinflammatory cytokines promote bone damage by fostering the production of Wnt signaling inhibitors, including secreted frizzled-related, Wnt inhibitory factor 1, sclerostin, and Dickkopf (DKK) family proteins (89–91). However, it was found that the role of DKK-1 is different in various autoimmune diseases (92). In a clinical study of 98 SS patients and 165 healthy volunteers, three Wnt/ β -catenin signaling pathway-related genes, LRP5, FRZB, and ADIPOQ, were shown to increase the risk of SS, although the biological functions of these genes have not yet been established (91). It implicates Wnt pathway might be involved in the pathogenesis of SS. However, not all studies support this idea. A clinical study reported that serum Dkk-1 and sclerostin levels were decreased in SS and SLE, and the Wnt1 and Wnt3a levels had no significant changes (93).

3.7 IL-33/ST-2

The IL-33-ST2 axis participates in the pathogenesis of SS by promoting transcriptional activation of CD86 and CCL2 in salivary epithelial cells and activation of the NF- κ B pathway. IL-33, combined with IL-12 and IL-23, participates in the production of CD4⁺ T cell-derived and NK/NKT-derived IFN- γ (89, 94). An increase in serum levels of IL-33 and ST2 has been reported in patients with SS (95). IL-33 is a member of the IL-1 family and ST2 is one important member of IL-1 receptor family (90). IL-33 induces phosphorylation of the NF- κ B pathway and activates MAP kinases by interacting with ST2 to stimulate downstream Th2-related immune responses. A recent review described IL-33 as an alarmin, that is, a DAMP. Local increases in IL-33 expression can induce an immune response and result in organ lesions (91). The IL-33-ST2 axis is a novel mode in the pathogenesis of SS and a potential therapeutic target in related salivary gland disorders.

4 Experimental therapeutic strategies of SS

4.1 Targeting the Treg/Th17

The Treg/Th17 plays a crucial role in the pathogenesis of autoimmune diseases. Various drugs have been designed to target the molecular mechanisms involved in the polarization and activation of the Treg/Th17, including IL-17-related molecules (IL-17, IL-23), transcription factors (ROR γ t, STAT3, Foxp3, and FoxO1), and intracellular signaling pathways (ROCK and MAPK) (96). However, compared to RA, SLE, IBD, and psoriasis, clinical or preclinical drugs for SS are rare. Nevertheless, previous pharmacological exploration and clinical trials have provided promising results for SS therapy.

IL-38—a member of the IL-1 family and, which was named as IL-1F10 (97)—inhibits the secretion of Th17 cell-related cytokines, including IL-6, IL-8, IL-17, IL-22, and IL-23, by binding with IL-36 receptors (98). A previous clinical study reported a selective anti-IL-17A mAb, secukinumab, that can alleviate the symptoms of psoriasis by blocking the expression of IL-17A, while that of IL-1 receptor antagonist (IL-1ra) and IL-38 was downregulated (Figure 2) (99).

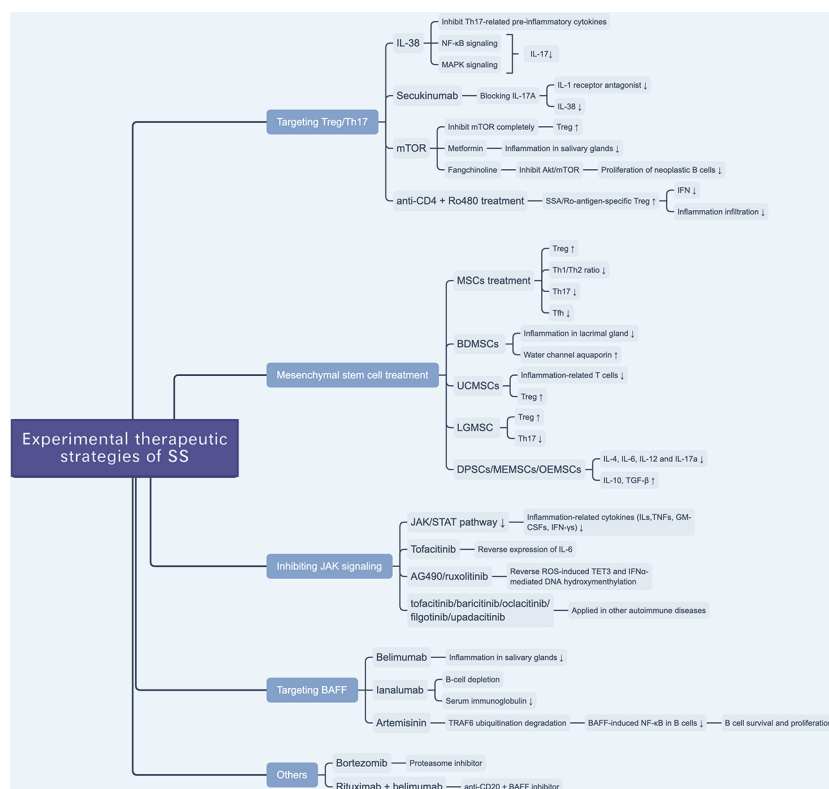


FIGURE 2

Overview of novel experimental therapeutic strategies of SS. There are various experimental drugs (e.g. JAK inhibitors) or schemes (e.g. targeting Treg/Th17 and BAFF) being investigated for SS treatment. Besides, mesenchymal stem cell treatment is reported to be a promising scheme to treat SS.

A previous study tested the effect of IL-38 treatment on Th17 cell activity and found that the expression levels of IL-17 and IL-23 were decreased in a murine model of SS; IL-38 inhibited IL-17 expression through the NF- κ B and MAPK signaling pathways (Figure 2). They also found that IL-17 can upregulate the expression of IL-38 (54). This hints at a potential approach for the treatment of SS.

mTOR, a member of the phosphoinositol 3-kinase (PI3K) family, is an atypical serine/threonine kinase that plays a vital role in cellular metabolism and activity (100). mTOR likely prevents anergy induction by IL-2 expression in T cells. A previous study found that by blocking mTOR with rapamycin, the cell cycle of clonal T cells was inhibited, while it induced cell anergy even with costimulations (101). In the process of naïve T cell differentiation, mTOR mediates the transformation to Th17 or Treg cells by altering the sensitivity of T cells to TGF- β , which influences the effects of STAT3 signaling (102). The inhibition of different mTOR complexes (including mTORC1 and mTORC2) would activate different pathways of polarization to Th17 cells, whereas a complete inhibition of mTOR can promote polarization to Treg cells (103). mTOR plays a role in Th17/Treg balance, given that mTOR inhibitors interfere with the Th17/Treg ratio, which suggests a potential therapeutic target to ameliorate glandular lesions in patients with SS. Given the anti-inflammatory and immunomodulatory effects of metformin—an AMPK-dependent mTOR-STAT3 inhibitor—researchers examined its therapeutic effect in SS murine models and found that it ameliorated inflammation in the salivary glands and, based on flow cytometry, regulated the Th17/Treg ratio (Figure 2) (104). Yu et al. reported that an alkaloid extracted from the traditional Chinese

herbal medicine *Stephania tetrandra* S. Moore, fangchinoline, can be used to treat SS by inhibiting the Akt/mTOR pathway, which inhibits the proliferation of neoplastic B lymphocytes (Figure 2) (105).

More than that, a recent study reported that SSA/Ro-antigen-specific Treg cells can downregulate the production of CD4⁺ T cell-derived IFN- γ and suppress inflammatory infiltration of the salivary gland (106). Researchers reported that the combination treatment with anti-CD4 mAb and autoantigen-specific peptide Ro480 induces SSA/Ro-antigen-specific Treg cells *in vivo* and suppresses CD4⁺ T cell-related IFN- γ production in salivary glands, providing a potential novel immunotherapeutic strategy for the treatment of SS (Figure 2) (106).

4.2 Mesenchymal stem cell treatment

Mesenchymal stem cells (MSCs) exert immunomodulatory effects on both adaptive and innate pathways. MSC can manipulate the balance between suppressive Treg cells and inflammatory T helper cells (Th1, Th2, Th17, and Tfh) and ameliorate inflammatory infiltration in the salivary glands (107, 108).

Xu et al. revealed that immunomodulatory functions of MSCs are impaired in SS-like murine models, and allogeneic bone marrow mesenchymal stem cells (BMMSCs) infusion can suppress SS-like inflammation, showing therapeutic effects of BMMSCs on SS (109). Furthermore, they also elucidated that the stromal cell-derived factor-1 (SDF-1)/C-X-C chemokine receptor 4 (CXCR4) axis plays an important role in MSC migration and restoration of salivary glands. More than that, they also treated twenty-four SS patients with umbilical cord-MSCs

(UCMSCs), and all patients showed alleviation of SS symptoms and well tolerance of allogeneic UCMSCs (Figure 2) (109).

Zoukhri et al. revealed that a biotherapeutic strategy involving bone-derived MSCs (BDMSCs) alleviated lacrimal glandular manifestation in a SS murine model by inhibiting inflammation and promoting the expression and activation of water channel aquaporin 5 (Figure 2) (110). Li et al. verified the immunomodulatory effects of UCMSCs and found that UCMSCs induced CD4⁺FoxP3⁺ Treg cells *in vitro* and caused anergy of inflammation-related T cells *in vivo*, accompanied by an increase in Treg cells (111). Hua et al. assessed the effects of labial gland-derived MSCs (LGMSCs) and their exosomes on SS, and found that they ameliorated salivary gland inflammatory infiltration by inhibiting the polarization of Th17 cells and promoting the proliferation of Treg cells (Figure 2) (112). Furthermore, dental pulp stem cells (DPSC) (113), murine embryonic MSCs (MEMSCs) (114), and olfactory ecto-MSCs (OEMSCs) (115) can be used to treat SS by interfering with inflammation-related cytokines (IL-4, IL-6, IL-12, and IL-17a) and suppressive cytokines (IL-10 and TGF- β) (Figure 2) (116).

4.3 Inhibiting JAK pathway

JAK enzymes are involved in the JAK/STAT pathway through the phosphorylation of STAT, which leads to the activation of signals transferred to the nucleus. The JAK family consists of four members, JAK1, JAK2, JAK3, and TYK2 (117). Membrane receptor subunits usually bind to a specific JAK. For example, JAK3 can only selectively binds to the γ c chain, which is a common receptor chain of IL-2, IL-4, IL-9, IL-15, and IL-21 (118).

The JAK/STAT pathway regulates the production of ILs, TNFs, GM-CSFs, and IFN- γ s, which are associated with inflammation and autoimmunity (119). The JAK inhibitors tofacitinib (120), baricitinib (120), oclacitinib (121), filgotinib (122), and upadacitinib (123) have been applied in the treatment of autoimmune diseases (Figure 2). Renaudineau et al. reported that AG490 and ruxolitinib, two JAK1/2 inhibitors, can reverse ROS-induced production of ten-eleven translocation 3 (TET3)

and IFN α -mediated DNA hydroxymethylation and could potentially treat SS (Table 2) (45, 132). Tofacitinib is also a candidate drug for SS, given that it can reverse the expression of IL-6 in ATG5-deficient 3D-acini, which leads to the inhibition of inflammation (Table 2) (133).

4.4 Targeting BAFF

Belimumab is an anti-BAFF monoclonal antibody and a potential biotherapeutic drug for SLE and SS (Table 2) (125, 135). A bi-centric clinical trial reported that, after a 28-week regimen of belimumab (10 mg/kg, at weeks 0, 2, 4, and then every 4 weeks), 18 out of 30 patients achieved two of five primary endpoints. The mean and standard deviation of ESSDAI and EULAR Sjogren's Syndrome Patients Reported Index (ESSPRI) were both reduced (Figure 2) (125).

Ianalumab is a BAFF-blocking monoclonal antibody that leads to B-cell depletion (Figure 2). A previous clinical study found that, in SS, ianalumab reduced the ESSDAI, ESSPRI, and serum immunoglobulin levels (Table 2) (129).

Besides, Zheng et al. reported a Chinese herb-derived drug, Artemisinin (ART), which is used to treat chloroquine-resistant malaria originally, has immunosuppressive effects in the SS-like murine model (Figure 2) (126). The study demonstrated that ART downregulates BAFF-induced NF- κ B activity in B cells through targeting TRAF6 ubiquitination, which results in the inhibition of B cell survival and proliferation. Therefore, the levels of B lymphocyte-related immunoglobulin and autoantibody in the SS-like murine model were attenuated and lymphocytic infiltration in the salivary gland was ameliorated (Table 2) (126).

4.5 Others

Bortezomib is a proteasome inhibitor used in the treatment of multiple myeloma (Table 2). A Mexican case report described a female patient that suffered from SS for 16 years and presented with sicca complex, extreme fatigue, Raynaud phenomenon, generalized

TABLE 2 Experimental Biotherapeutic Drugs of SS.

Drug	Effect target	Mechanism	Feasibility*	References
Rituximab	CD20	Induce ADCC and CDC	-	(124)
Belimumab	BAFF	Inhibit the combination of BLyS and B cells	+	(125)
Artemisinin	BAFF	Downregulate the BAFF-induced NF- κ B activity	+	(126)
Iscalimab	CD40	Inhibit the combination of CD40 and CD40L	-	(127)
Tocilizumab	IL-6 receptor	Block IL-6R	-	(128)
Ianalumab	BAFF receptor	Block BAFF receptor	+	(129, 130)
Abatacept	CD80&CD86	Inhibit activation of T cells	+	(131)
Ruxotinib	JAK/STAT pathway	Inhibit IFN and ROS related DNA hydroxymethylation	*	(45, 132)
AG490	JAK/STAT pathway	Inhibit IFN and ROS related DNA hydroxymethylation	*	(45, 132)
Tofacitinib	JAK/STAT pathway	Decrease expression of IL-6	*	(133)
Bortezomib	Proteasome pathway	Inhibit activation and nuclear translocation of NF- κ B	+	(134)

* Experimental effects on treating SS. "-" means none or low effect. "+" means promising effect. "*" means unclear.

arthralgia, and heavy headaches. After ineffective conventional glucocorticoid and rituximab therapy, doctors administered an experimental regimen of bortezomib at a dose of 1.3 mg/m² (2.0 mg/dose) at days 1, 4, 8, 11, 22, 29, 36, 43, 50, and 57. Surprisingly, the patient's headaches and fatigue were resolved after three months, and serum globulin levels and viscosity decreased significantly (Table 2) (134). However, the efficacy and safety of bortezomib for the treatment of SS are still unconfirmed (Figure 2).

Rituximab—a chimeric monoclonal anti-CD20 antibody—has been reported to induce B-cell depletion and has been used to treat autoimmune diseases (136, 137). It has also been used to treat SS over the last 20 years, but with limited clinical efficacy (Table 2) (124, 138). Researchers have investigated a combination therapy with the anti-BAFF and anti-CD20 [NCT02631538]—belimumab and rituximab. The results of the clinical trial provide evidence that simultaneous targeting of the BAFF axis and B cells is a promising treatment strategy for SS (Figure 2) (139). The drugs in development for SS treatment are summarized in Table 2.

Various biotherapeutic drugs have been used to treat SS experimentally. Some of them have been used to treat other autoimmune diseases (e.g. Rituximab), and the others are novel drugs targeting inflammation-related signaling pathways (e.g. AG490). However, not all of them have prospective effects on treating SS (e.g. Iscalimab, Tocilizumab).

5 Conclusion & discussion

As a systemic autoimmune disease, SS causes multiple organ lesions, especially in salivary and lacrimal glands, which limits endocrine function. Besides focal inflammation in the salivary gland, acinar atrophy, duct dilation, and fibrosis are commonly observed in SS patients. Due to a high disease specificity and limited invasiveness, labial salivary gland biopsy is widely accepted as the best method to diagnose SS currently (140). Lymphocytic infiltration around the striated ducts in salivary glands, or so-called periductal foci, is a critical hallmark for the diagnosis of SS (141). Since adipose tissue replacement in the salivary gland is related to the stages of SS, and adipocytes are detected in IL-6-rich regions, detecting the degree of adipose tissue replacement provides aid to improve diagnosis accuracy (142). In addition, comorbidities, such as secondary pulmonary disease, kidney injury, and lymphoma, further reduce the quality of life of patients. The pathogenesis of SS is characterized by the production of inflammatory cytokines and lymphocyte infiltration. IFN and IL-17/IL-23 play pivotal roles in the formation of inflammatory lesions, and B cells are crucial for infiltrative injury. Th17, B, and dendritic cells play critical roles in the aberrant regulation of the immune system.

Similar to other autoimmune diseases, such as SLE, RA, and psoriasis, the traditional therapeutic strategy for SS is disease-modifying antirheumatic drugs (DMARDs), such as glucocorticoids, while novel biotherapeutic approaches take advantage of neutralizing antibodies and inflammation-related receptor blockers. Compared with the traditional strategy, this new scheme is more targeted, which can promote safety and efficacy. Although considerable progress has recently been made in the treatment of SS, disease-specific drugs are rare. Many SS drugs are currently undergoing clinical trials. As Th17 and B cells play important roles in the pathogenesis of SS, the targeting of Th17 cell- and

B cell-related signaling pathways and molecular events has drawn increasing attention.

Research on SS therapies is limited by a lack of systematic clinical trials compared with other autoimmune diseases, such as SLE, RA, and MS. Many potential therapeutic targets have been identified in the pathogenesis of SS, and some targeted drugs have shown reasonable efficacy under experimental conditions *in vitro* or *in vivo*. Unfortunately, the translation of these drugs to clinical use is rare. Additionally, it is unclear why immune inhibitors lack pharmacological effect in SS compared to SLE, RA, and MS. Nevertheless, immune inhibitors can be used in the management of complications to improve the prognosis and quality of life of patients with SS. For example, BAFF receptor blockers not only prevent inflammatory lesions but also protect against B-cell lymphoma; however, such therapeutic strategies are rare. Combination therapies have shown some efficacy; however, inappropriate combinations of drugs may cause excessive inhibition of the immune system, resulting in unexpected complications, such as secondary infections. Thus, targeted and low-side-effect drugs should be the focus of future research.

Author contributions

QZ drafted the manuscript. JZ, YL, WC and XF edited the manuscript. DZ supervised the work and edited the manuscript. All authors contributed to the article and approved the submitted version.

Funding

This work was supported by the Key Project of the Science and Technology Department of Sichuan Province (NO. 2022YFH0100), the National Natural Science Foundation of China (NO. 82171829), the 1-3-5 Project for Disciplines of Excellence, West China Hospital, Sichuan University (NO. ZYYC21012), and the Fundamental Research Funds for the Central Universities (20822041E4084).

Acknowledgments

DZ sincerely wants to commemorate Dr. Sang-A Park, who passed away suddenly on January 22, 2018.

Conflict of interest

The authors declare that the research was conducted in the absence of any commercial or financial relationships that could be construed as a potential conflict of interest.

Publisher's note

All claims expressed in this article are solely those of the authors and do not necessarily represent those of their affiliated organizations, or those of the publisher, the editors and the reviewers. Any product that may be evaluated in this article, or claim that may be made by its manufacturer, is not guaranteed or endorsed by the publisher.

References

- Bloch KJ, Buchanan Ww, Wohl Mj, Bunim Jj. SJÖGREN'S SYNDROME: A clinical, pathological, and serological study of sixty-two cases. *Medicine* (1965) 44(3):187–231. doi: 10.1097/00005792-196505000-00001
- Qin B, Wang J, Yang Z, Yang M, Ma N, Huang F, et al. Epidemiology of primary sjogren's syndrome: a systematic review and meta-analysis. *Ann Rheum Dis* (2015) 74 (11):1983–9. doi: 10.1136/annrheumdis-2014-205375
- Cornec D, Devauchelle-Pensec V, Mariette X, Jousse-Joulin S, Berthelot JM, Perdriger A, et al. Severe health-related quality of life impairment in active primary sjogren's syndrome and patient-reported outcomes: Data from a Large therapeutic trial. *Arthritis Care Res (Hoboken)* (2017) 69(4):528–35. doi: 10.1002/acr.22974
- Berman N, Vivino F, Baker J, Dunham J, Pinto A. Risk factors for caries development in primary sjogren syndrome. *Oral Surg Oral Med Oral Pathol Oral Radiol* (2019) 128(2):117–22. doi: 10.1016/j.oooo.2019.04.011
- Singh M, Teles F, Uzel NG, Papas A. Characterizing microbiota from sjogren's syndrome patients. *JDR Clin Trans Res* (2021) 6(3):324–32. doi: 10.1177/2380084420940623
- Seror R, Bowman SJ, Brito-Zeron P, Theander E, Bootsma H, Tzioufas A, et al. EULAR sjogren's syndrome disease activity index (ESSDAI): a user guide. *RMD Open* (2015) 1(1):e000022. doi: 10.1136/rmdopen-2014-000022
- Alexander EL, Provost TT, Stevens MB, Alexander GE. Neurologic complications of primary sjogren's syndrome. *Med (Baltimore)* (1982) 61(4):247–57. doi: 10.1097/00005792-198207000-00004
- Alexander EL, Malinow K, Lejewski JE, Jerdan MS, Provost TT, Alexander GE. Primary sjogren's syndrome with central nervous system disease mimicking multiple sclerosis. *Ann Intern Med* (1986) 104(3):323–30. doi: 10.7326/0003-4819-104-3-323
- Fauchais AL, Magy L, Vidal E. Central and peripheral neurological complications of primary sjogren's syndrome. *Presse Med* (2012) 41(9 Pt 2):e485–93. doi: 10.1016/j.lpm.2012.06.002
- Fox RJ. The prevalence of sjogren syndrome in patients with primary progressive multiple sclerosis. *Neurology* (2002) 58(10):1576. doi: 10.1212/wnl.58.10.1576
- Griffin JW, Cornblath DR, Alexander E, Campbell J, Low PA, Bird S, et al. Ataxic sensory neuropathy and dorsal root ganglionitis associated with sjogren's syndrome. *Ann Neurol* (1990) 27(3):304–15. doi: 10.1002/ana.410270313
- Misterska-Skora M, Sebastian A, Dziegiel P, Sebastian M, Wiland P. Inclusion body myositis associated with sjogren's syndrome. *Rheumatol Int* (2013) 33(12):3083–6. doi: 10.1007/s00296-012-2556-4
- Sambataro G, Ferro F, Orlandi M, Sambataro D, Torrisi SE, Quartuccio L, et al. Clinical, morphological features and prognostic factors associated with interstitial lung disease in primary sjogren's syndrome: A systematic review from the Italian society of rheumatology. *Autoimmun Rev* (2020) 19(2):102447. doi: 10.1016/j.autrev.2019.102447
- Luppi F, Sebastiani M, Silva M, Sverzellati N, Cavazza A, Salvarani C, et al. Interstitial lung disease in sjogren's syndrome: a clinical review. *Clin Exp Rheumatol* (2020) 38 Suppl 126(4):291–300.
- Mirouse A, Seror R, Vicaut E, Mariette X, Dougados M, Fauchais AL, et al. Arthritis in primary sjogren's syndrome: Characteristics, outcome and treatment from French multicenter retrospective study. *Autoimmun Rev* (2019) 18(1):9–14. doi: 10.1016/j.autrev.2018.06.015
- Bossini N, Savoldi S, Franceschini F, Mombelloni S, Baronio M, Cavazzana I, et al. Clinical and morphological features of kidney involvement in primary sjogren's syndrome. *Nephrol Dial Transplant* (2001) 16(12):2328–36. doi: 10.1093/ndt/16.12.2328
- Maripuri S, Grande JP, Osborn TG, Ferenza FC, Matteson EL, Donadio JV, et al. Renal involvement in primary sjogren's syndrome: a clinicopathologic study. *Clin J Am Soc Nephrol* (2009) 4(9):1423–31. doi: 10.2215/CJN.00980209
- Baldini C, Pepe P, Quartuccio L, Priori R, Bartoloni E, Alunno A, et al. Primary sjogren's syndrome as a multi-organ disease: impact of the serological profile on the clinical presentation of the disease in a large cohort of Italian patients. *Rheumatol (Oxford)* (2014) 53(5):839–44. doi: 10.1093/rheumatology/kes427
- Alunno A, Leone MC, Giacomelli R, Gerli R, Carubbi F. Lymphoma and lymphomagenesis in primary sjogren's syndrome. *Front Med (Lausanne)* (2018) 5:102. doi: 10.3389/fmed.2018.00102
- Koh JH, Park Y, Lee J, Park SH, Kwok SK. Hypergammaglobulinaemia predicts glandular and extra-glandular damage in primary sjogren's syndrome: results from the KISS cohort study. *Clin Exp Rheumatol* (2021) 39 Suppl 133(6):114–22. doi: 10.55563/clinexpheumatol/volsh1
- Quartuccio L, Salvin S, Fabris M, Maset M, Pontarini E, Isola M, et al. BlyS upregulation in sjogren's syndrome associated with lymphoproliferative disorders, higher ESSDAI score and b-cell clonal expansion in the salivary glands. *Rheumatol (Oxford)* (2013) 52(2):276–81. doi: 10.1093/rheumatology/kes180
- Song H, Tong D, Cha Z, Bai J. C-X-C chemokine receptor type 5 gene polymorphisms are associated with non-Hodgkin lymphoma. *Mol Biol Rep* (2012) 39 (9):8629–35. doi: 10.1007/s11033-012-1717-6
- Nordmark G, Wang C, Vasaitis L, Eriksson P, Theander E, Kvarnstrom M, et al. Association of genes in the NF-kappaB pathway with antibody-positive primary sjogren's syndrome. *Scand J Immunol* (2013) 78(5):447–54. doi: 10.1111/sji.12101
- Johnsen SJ, Gudlaugsson E, Skaland I, Janssen EA, Jonsson MV, Helgeland L, et al. Low protein A20 in minor salivary glands is associated with lymphoma in primary sjogren's syndrome. *Scand J Immunol* (2016) 83(3):181–7. doi: 10.1111/sji.12405
- Retamozo S, Acar-Denizli N, Rasmussen A, Horvath IF, Baldini C, Priori R, et al. Systemic manifestations of primary sjogren's syndrome out of the ESSDAI classification: prevalence and clinical relevance in a large international, multi-ethnic cohort of patients. *Clin Exp Rheumatol* (2019) 37 Suppl 118(3):97–106.
- Nocturne G, Mariette X. Advances in understanding the pathogenesis of primary sjogren's syndrome. *Nat Rev Rheumatol* (2013) 9(9):544–56. doi: 10.1038/nrrheum.2013.110
- Mavragani CP, Moutsopoulos HM. Sjogren's syndrome: Old and new therapeutic targets. *J Autoimmun* (2020) 110:102364. doi: 10.1016/j.jaut.2019.102364
- Hooks JJ, Moutsopoulos HM, Notkins AL. Circulating interferon in human autoimmune diseases. *Tex Rep Biol Med* (1981) 41:164–8.
- Bave U, Nordmark G, Lovgren T, Ronnelid J, Cajander S, Eloranta ML, et al. Activation of the type I interferon system in primary sjogren's syndrome: a possible etiopathogenic mechanism. *Arthritis Rheum* (2005) 52(4):1185–95. doi: 10.1002/art.20998
- Hjelmervik TO, Petersen K, Jonassen I, Jonsson R, Bolstad AI. Gene expression profiling of minor salivary glands clearly distinguishes primary sjogren's syndrome patients from healthy control subjects. *Arthritis Rheum* (2005) 52(5):1534–44. doi: 10.1002/art.21006
- Jiang J, Zhao M, Chang C, Wu H, Lu Q. Type I interferons in the pathogenesis and treatment of autoimmune diseases. *Clin Rev Allergy Immunol* (2020) 59(2):248–72. doi: 10.1007/s12016-020-08798-2
- Yao Y, Liu Z, Jallal B, Shen N, Ronnblom L. Type I interferons in sjogren's syndrome. *Autoimmun Rev* (2013) 12(5):558–66. doi: 10.1016/j.autrev.2012.10.006
- Yin Z, Dai J, Deng J, Sheikh F, Natalia M, Shih T, et al. Type III IFNs are produced by and stimulate human plasmacytoid dendritic cells. *J Immunol* (2012) 189(6):2735–45. doi: 10.4049/jimmunol.1102038
- Finotti G, Tamassia N, Calzetti F, Fattovich G, Cassatella MA. Endogenously produced TNF-alpha contributes to the expression of CXCL10/IP-10 in IFN-lambda3-activated plasmacytoid dendritic cells. *J Leukoc Biol* (2016) 99(1):107–19. doi: 10.1189/jlb.3VMA0415-144R
- Finotti G, Tamassia N, Cassatella MA. Interferon-lambdas and plasmacytoid dendritic cells: A close relationship. *Front Immunol* (2017) 8:1015. doi: 10.3389/fimmu.2017.01015
- Barrat FJ, Crow MK, Ivashkiv LB. Interferon target-gene expression and epigenomic signatures in health and disease. *Nat Immunol* (2019) 20(12):1574–83. doi: 10.1038/s41590-019-0466-2
- Apostolou E, Tzioufas AG. Type-III interferons in sjogren's syndrome. *Clin Exp Rheumatol* (2020) 38 Suppl 126(4):245–52.
- Barrat FJ, Elkon KB, Fitzgerald KA. Importance of nucleic acid recognition in inflammation and autoimmunity. *Annu Rev Med* (2016) 67:323–36. doi: 10.1146/annurev-med-052814-023338
- Saito I, Terauchi K, Shimuta M, Nishiimura S, Yoshino K, Takeuchi T, et al. Expression of cell adhesion molecules in the salivary and lacrimal glands of sjogren's syndrome. *J Clin Lab Anal* (1993) 7(3):180–7. doi: 10.1002/jcla.1860070309
- Zhou J, Jin JO, Kawai T, Yu Q. Endogenous programmed death ligand-1 restrains the development and onset of sjogren's syndrome in non-obese diabetic mice. *Sci Rep* (2016) 6:39105. doi: 10.1038/srep39105
- Kobayashi M, Kawano S, Hatachi S, Kurimoto C, Okazaki T, Iwai Y, et al. Enhanced expression of programmed death-1 (PD-1)/PD-L1 in salivary glands of patients with sjogren's syndrome. *J Rheumatol* (2005) 32(11):2156–63.
- Traore K, Sharma RB, Burek CL, Trush MA. Role of ROS and MAPK in TPA-induced ICAM-1 expression in the myeloid ML-1 cell line. *J Cell Biochem* (2007) 100 (4):1010–21. doi: 10.1002/jcb.21101
- Di Dalmazi G, Hirshberg J, Lyle D, Freij JB, Caturegli P. Reactive oxygen species in organ-specific autoimmunity. *Auto Immun Highlights* (2016) 7(1):11. doi: 10.1007/s13317-016-0083-0
- Roux C, Jafari SM, Shinde R, Duncan G, Cescon DW, Silvester J, et al. Reactive oxygen species modulate macrophage immunosuppressive phenotype through the up-regulation of PD-L1. *Proc Natl Acad Sci U.S.A.* (2019) 116(10):4326–35. doi: 10.1073/pnas.1819473116
- Charras A, Arvaniti P, Le Dantec C, Dalekos GN, Zachou K, Bordron A, et al. JAK inhibitors and oxidative stress control. *Front Immunol* (2019) 10:2814. doi: 10.3389/fimmu.2019.02814
- Coccia EM, Severa M, Giacomini E, Monneron D, Remoli ME, Julkunen I, et al. Viral infection and toll-like receptor agonists induce a differential expression of type I and lambda interferons in human plasmacytoid and monocyte-derived dendritic cells. *Eur J Immunol* (2004) 34(3):796–805. doi: 10.1002/eji.200324610
- Prokunina-Olsson L, Muchmore B, Tang W, Pfeiffer RM, Park H, Dickensheets H, et al. A variant upstream of IFNL3 (IL28B) creating a new interferon gene IFNL4 is associated with impaired clearance of hepatitis C virus. *Nat Genet* (2013) 45(2):164–71. doi: 10.1038/ng.2521
- Lazear HM, Schoggins JW, Diamond MS. Shared and distinct functions of type I and type III interferons. *Immunity* (2019) 50(4):907–23. doi: 10.1016/j.immuni.2019.03.025

49. Lessard CJ, Li H, Adrianto I, Ice JA, Rasmussen A, Grundahl KM, et al. Variants at multiple loci implicated in both innate and adaptive immune responses are associated with sjogren's syndrome. *Nat Genet* (2013) 45(11):1284–92. doi: 10.1038/ng.2792
50. Park H, Li Z, Yang XO, Chang SH, Nurieva R, Wang YH, et al. A distinct lineage of CD4 T cells regulates tissue inflammation by producing interleukin 17. *Nat Immunol* (2005) 6(11):1133–41. doi: 10.1038/nl1261
51. Harrington LE, Hatton RD, Mangan PR, Turner H, Murphy TL, Murphy KM, et al. Interleukin 17-producing CD4+ effector T cells develop via a lineage distinct from the T helper type 1 and 2 lineages. *Nat Immunol* (2005) 6(11):1123–32. doi: 10.1038/nl1254
52. Iwakura Y, Ishigame H, Saijo S, Nakae S. Functional specialization of interleukin-17 family members. *Immunity* (2011) 34(2):149–62. doi: 10.1016/j.immuni.2011.02.012
53. Nguyen CQ, Hu MH, Li Y, Stewart C, Peck AB. Salivary gland tissue expression of interleukin-23 and interleukin-17 in sjogren's syndrome: findings in humans and mice. *Arthritis Rheum* (2008) 58(3):734–43. doi: 10.1002/art.23214
54. Luo D, Chen Y, Zhou N, Li T, Wang H. Blockade of Th17 response by IL-38 in primary sjogren's syndrome. *Mol Immunol* (2020) 127:107–11. doi: 10.1016/j.molimm.2020.09.006
55. Ciccia F, Guggino G, Rizzo A, Ferrante A, Raimondo S, Giardina A, et al. Potential involvement of IL-22 and IL-22-producing cells in the inflamed salivary glands of patients with sjogren's syndrome. *Ann Rheum Dis* (2012) 71(2):295–301. doi: 10.1136/ard.2011.154013
56. van Hamburg JP, Asmawidjaja PS, Davelaar N, Mus AM, Colin EM, Hazes JM, et al. Th17 cells, but not Th1 cells, from patients with early rheumatoid arthritis are potent inducers of matrix metalloproteinases and proinflammatory cytokines upon synovial fibroblast interaction, including autocrine interleukin-17A production. *Arthritis Rheum* (2011) 63(1):73–83. doi: 10.1002/art.30093
57. Asatsuma M, Ito S, Watanabe M, Takeishi H, Nomura S, Wada Y, et al. Increase in the ratio of matrix metalloproteinase-9 to tissue inhibitor of metalloproteinase-1 in saliva from patients with primary sjogren's syndrome. *Clin Chim Acta* (2004) 345(1-2):99–104. doi: 10.1016/j.cccn.2004.03.006
58. Iacomino G, Rotondi A, Iannaccone N, Melina R, Giardullo N, De Chiara G, et al. IBD: Role of intestinal compartments in the mucosal immune response. *Immunobiology* (2020) 225(1):151849. doi: 10.1016/j.imbio.2019.09.008
59. Silva FA, Rodrigues BL, Ayrisson ML, Leal RF. The immunological basis of inflammatory bowel disease. *Gastroenterol Res Pract* (2016) 2016:2097274. doi: 10.1155/2016/2097274
60. Shao S, Yu X, Shen L. Autoimmune thyroid diseases and Th17/Treg lymphocytes. *Life Sci* (2018) 192:160–5. doi: 10.1016/j.lfs.2017.11.026
61. Shi Y, Chen Z, Zhao Z, Yu Y, Fan H, Xu X, et al. IL-21 induces an imbalance of Th17/Treg cells in moderate-to-severe plaque psoriasis patients. *Front Immunol* (2019) 10:1865. doi: 10.3389/fimmu.2019.01865
62. Fletcher JM, Lalor SJ, Sweeney CM, Tubridy N, Mills KH. T Cells in multiple sclerosis and experimental autoimmune encephalomyelitis. *Clin Exp Immunol* (2010) 162(1):1–11. doi: 10.1111/j.1365-2249.2010.04143.x
63. Bystrom J, Clanchy FI, Taher TE, Mangat P, Jawad AS, Williams RO, et al. TNFalpha in the regulation of treg and Th17 cells in rheumatoid arthritis and other autoimmune inflammatory diseases. *Cytokine* (2018) 101:4–13. doi: 10.1016/j.cyto.2016.09.001
64. Paradowska-Gorycka A, Wajda A, Romanowska-Prochnicka K, Walczuk E, Kuca-Warnawin E, Kmiolek T, et al. Th17/Treg-related transcriptional factor expression and cytokine profile in patients with rheumatoid arthritis. *Front Immunol* (2020) 11:572858. doi: 10.3389/fimmu.2020.572858
65. Kopf H, de la Rosa GM, Howard OM, Chen X. Rapamycin inhibits differentiation of Th17 cells and promotes generation of FoxP3+ T regulatory cells. *Int Immunopharmacol* (2007) 7(13):1819–24. doi: 10.1016/j.intimp.2007.08.027
66. Cluxton D, Petrasca A, Moran B, Fletcher JM. Differential regulation of human treg and Th17 cells by fatty acid synthesis and glycolysis. *Front Immunol* (2019) 10:115. doi: 10.3389/fimmu.2019.00115
67. Wagner A, Wang C, Fessler J, DeTomaso D, Avila-Pacheco J, Kaminski J, et al. Metabolic modeling of single Th17 cells reveals regulators of autoimmunity. *Cell* (2021) 184(16):4168–85.e21. doi: 10.1016/j.cell.2021.05.045
68. Hwang SH, Park JS, Yang S, Jung KA, Choi J, Kwok SK, et al. Metabolic abnormalities exacerbate sjogren's syndrome by and is associated with increased the population of interleukin-17-producing cells in NOD/ShiLtJ mice. *J Transl Med* (2020) 18(1):186. doi: 10.1186/s12967-020-02343-7
69. Hwang SH, Woo JS, Moon J, Yang S, Park JS, Lee J, et al. IL-17 and CCR9(+) alpha4beta7(-) Th17 cells promote salivary gland inflammation, dysfunction, and cell death in sjogren's syndrome. *Front Immunol* (2021) 12:721453. doi: 10.3389/fimmu.2021.721453
70. Bradley JR. TNF-mediated inflammatory disease. *J Pathol* (2008) 214(2):149–60. doi: 10.1002/path.2287
71. Jang DI, Lee AH, Shin HY, Song HR, Park JH, Kang TB, et al. The role of tumor necrosis factor alpha (TNF-alpha) in autoimmune disease and current TNF-alpha inhibitors in therapeutics. *Int J Mol Sci* (2021) 22(5):2719. doi: 10.3390/ijms22052719
72. Mackay F, Schneider P. Cracking the BAFF code. *Nat Rev Immunol* (2009) 9(7):491–502. doi: 10.1038/nri2572
73. Mackay F, Schneider P, Rennert P, Browning J. BAFF AND APRIL: a tutorial on b cell survival. *Annu Rev Immunol* (2003) 21:231–64. doi: 10.1146/annurev.immunol.21.1.20601.141152
74. Scapini P, Bazzoni F, Cassatella MA. Regulation of b-cell-activating factor (BAFF)/B lymphocyte stimulator (BLyS) expression in human neutrophils. *Immunol Lett* (2008) 116(1):1–6. doi: 10.1016/j.imlet.2007.11.009
75. Kayagaki N, Yan M, Seshasayee D, Wang H, Lee W, French DM, et al. BAFF/BLyS receptor 3 binds the b cell survival factor BAFF ligand through a discrete surface loop and promotes processing of NF-kappaB2. *Immunity* (2002) 17(4):515–24. doi: 10.1016/s1074-7613(02)00425-9
76. Wei F, Chang Y, Wei W. The role of BAFF in the progression of rheumatoid arthritis. *Cytokine* (2015) 76(2):537–44. doi: 10.1016/j.cyto.2015.07.014
77. Vincent FB, Morand EF, Mackay F. BAFF and innate immunity: new therapeutic targets for systemic lupus erythematosus. *Immunol Cell Biol* (2012) 90(3):293–303. doi: 10.1038/icb.2011.111
78. Vannucchi G, Covelli D, Curro N, Dazzi D, Maffini A, Campi I, et al. Serum BAFF concentrations in patients with graves' disease and orbitopathy before and after immunosuppressive therapy. *J Clin Endocrinol Metab* (2012) 97(5):E755–9. doi: 10.1210/jc.2011-2614
79. Xin G, Cui Z, Su Y, Xu LX, Zhao MH, Li KS. Serum BAFF and APRIL might be associated with disease activity and kidney damage in patients with anti-glomerular basement membrane disease. *Nephrol (Carlton)* (2013) 18(3):209–14. doi: 10.1111/nep.12032
80. Ding J, Zhang W, Haskett S, Pellerin A, Xu S, Petersen B, et al. BAFF overexpression increases lymphocytic infiltration in sjogren's target tissue, but only inefficiently promotes ectopic b-cell differentiation. *Clin Immunol* (2016) 169:69–79. doi: 10.1016/j.clim.2016.06.007
81. Carrillo-Ballesteros FJ, Palafox-Sanchez CA, Franco-Topete RA, Munoz-Valle JF, Orozco-Barocio G, Martinez-Bonilla GE, et al. Expression of BAFF and BAFF receptors in primary sjogren's syndrome patients with ectopic germinal center-like structures. *Clin Exp Med* (2020) 20(4):615–26. doi: 10.1007/s10238-020-00637-0
82. Yoshimoto K, Suzuki K, Takei E, Ikeda Y, Takeuchi T. Elevated expression of BAFF receptor, BR3, on monocytes correlates with b cell activation and clinical features of patients with primary sjogren's syndrome. *Arthritis Res Ther* (2020) 22(1):157. doi: 10.1186/s13075-020-02249-1
83. Nusse R, Clevers H. Wnt/beta-catenin signaling, disease, and emerging therapeutic modalities. *Cell* (2017) 169(6):985–99. doi: 10.1016/j.cell.2017.05.016
84. Duchartre Y, Kim YM, Kahn M. The wnt signaling pathway in cancer. *Crit Rev Oncol Hematol* (2016) 99:141–9. doi: 10.1016/j.critrevonc.2015.12.005
85. Cici D, Corrado A, Rotondo C, Cantatore FP. Wnt signaling and biological therapy in rheumatoid arthritis and spondyloarthritis. *Int J Mol Sci* (2019) 20(22):5552. doi: 10.3390/ijms20225552
86. Gattinoni L, Zhong XS, Palmer DC, Ji Y, Hinrichs CS, Yu Z, et al. Wnt signaling arrests effector T cell differentiation and generates CD8+ memory stem cells. *Nat Med* (2009) 15(7):808–13. doi: 10.1038/nm.1982
87. Haseeb M, Pirzada RH, Ain QU, Choi S. Wnt signaling in the regulation of immune cell and cancer therapeutics. *Cells* (2019) 8(11):1380. doi: 10.3390/cells8111380
88. Chae WJ, Bothwell ALM. Canonical and non-canonical wnt signaling in immune cells. *Trends Immunol* (2018) 39(10):830–47. doi: 10.1016/j.it.2018.08.006
89. Awada A, Nicaise C, Ena S, Schandene L, Rasschaert J, Popescu I, et al. Potential involvement of the IL-33-ST2 axis in the pathogenesis of primary sjogren's syndrome. *Ann Rheum Dis* (2014) 73(6):1259–63. doi: 10.1136/annrheumdis-2012-203187
90. Schmitz J, Owyang A, Oldham E, Song Y, Murphy E, McClanahan TK, et al. IL-33, an interleukin-1-like cytokine that signals via the IL-1 receptor-related protein ST2 and induces T helper type 2-associated cytokines. *Immunity* (2005) 23(5):479–90. doi: 10.1016/j.immuni.2005.09.015
91. Soyfoo MS, Nicaise C. Pathophysiologic role of interleukin-33/ST2 in sjogren's syndrome. *Autoimmun Rev* (2021) 20(3):102756. doi: 10.1016/j.autrev.2021.102756
92. Tao SS, Cao F, Sam NB, Li HM, Feng YT, Ni J, et al. Dickkopf-1 as a promising therapeutic target for autoimmune diseases. *Clin Immunol* (2022) 245:109156. doi: 10.1016/j.clim.2022.109156
93. Karatas A, Omercikoglu Z, Oz B, Dagli AF, Catak O, Erman F, et al. Wnt signaling pathway activities may be altered in primary sjogren's syndrome. *Turk J Med Sci* (2021) 51(4):2015–22. doi: 10.3906/sag-2102-367
94. Dong Y, Ming B, Gao R, Mo Q, Wu X, Zheng F, et al. The IL-33/ST2 axis promotes primary sjogren's syndrome by enhancing salivary epithelial cell activation and type 1 immune response. *J Immunol* (2022) 208(12):2652–62. doi: 10.4049/jimmunol.2101070
95. Zhao L, Yao L, Yuan L, Xia L, Shen H, Lu J. Potential contribution of interleukin-33 to the development of interstitial lung disease in patients with primary sjogren's syndrome. *Cytokine* (2013) 64(1):22–4. doi: 10.1016/j.cyto.2013.07.006
96. Fasching P, Stradner M, Graninger W, DeJaco C, Fessler J. Therapeutic potential of targeting the Th17/Treg axis in autoimmune disorders. *Molecules* (2017) 22(1):134. doi: 10.3390/molecules22010134
97. Dinarello C, Arend W, Sims J, Smith D, Blumberg H, O'Neill L, et al. IL-1 family nomenclature. *Nat Immunol* (2010) 11(11):973. doi: 10.1038/nri1100-973
98. Rudloff I, Godsell J, Nold-Petry CA, Harris J, Hoi A, Morand EF, et al. Brief report: Interleukin-38 exerts antiinflammatory functions and is associated with disease activity in systemic lupus erythematosus. *Arthritis Rheumatol* (2015) 67(12):3219–25. doi: 10.1002/art.39328

99. Kolbinger F, Loesche C, Valentin MA, Jiang X, Cheng Y, Jarvis P, et al. Beta-defensin 2 is a responsive biomarker of IL-17A-driven skin pathology in patients with psoriasis. *J Allergy Clin Immunol* (2017) 139(3):923–32.e8. doi: 10.1016/j.jaci.2016.06.038
100. Laplante M, Sabatini DM. mTOR signaling in growth control and disease. *Cell* (2012) 149(2):274–93. doi: 10.1016/j.cell.2012.03.017
101. Powell JD, Lerner CG, Schwartz RH. Inhibition of cell cycle progression by rapamycin induces T cell clonal anergy even in the presence of costimulation. *J Immunol* (1999) 162(5):2775–84. doi: 10.4049/jimmunol.162.5.2775
102. Powell JD, Pollizzi KN, Heikamp EB, Horton MR. Regulation of immune responses by mTOR. *Annu Rev Immunol* (2012) 30:39–68. doi: 10.1146/annurev-immunol-020711-075024
103. Delgoffe GM, Pollizzi KN, Waickman AT, Heikamp E, Meyers DJ, Horton MR, et al. The kinase mTOR regulates the differentiation of helper T cells through the selective activation of signaling by mTORC1 and mTORC2. *Nat Immunol* (2011) 12(4):295–303. doi: 10.1038/ni.2005
104. Kim JW, Kim SM, Park JS, Hwang SH, Choi J, Jung KA, et al. Metformin improves salivary gland inflammation and hypofunction in murine sjogren's syndrome. *Arthritis Res Ther* (2019) 21(1):136. doi: 10.1186/s13075-019-1904-0
105. Shao Y, Fu J, Zhan T, Ye L, Yu C. Fangchinoline inhibited proliferation of neoplastic b-lymphoid cells and alleviated sjogren's syndrome-like responses in NOD/Ltj mice via the Akt/mTOR pathway. *Curr Mol Pharmacol* (2022) 15(7):969–79. doi: 10.2174/1874467215666220217103233
106. Xu J, Liu O, Wang D, Wang F, Zhang D, Jin W, et al. In vivo generating SSA/Ro-antigen specific regulatory T cells improves experimental sjogren's syndrome in mice. *Arthritis Rheumatol* (2022) 74(10):1699–1705. doi: 10.1002/art.42244
107. Chen W, Yu Y, Ma J, Olsen N, Lin J. Mesenchymal stem cells in primary sjogren's syndrome: Prospective and challenges. *Stem Cells Int* (2018) 2018:4357865. doi: 10.1155/2018/4357865
108. Chihaby N, Orliaguet M, Le Pottier L, Pers JO, Boisrame S. Treatment of sjogren's syndrome with mesenchymal stem cells: A systematic review. *Int J Mol Sci* (2021) 22(19):10474. doi: 10.3390/ijms221910474
109. Xu J, Wang D, Liu D, Fan Z, Zhang H, Liu O, et al. Allogeneic mesenchymal stem cell treatment alleviates experimental and clinical sjogren syndrome. *Blood* (2012) 120(15):3142–51. doi: 10.1182/blood-2011-11-391144
110. Aluri HS, Samizadeh M, Edman MC, Hawley DR, Armaos HL, Janga SR, et al. Delivery of bone marrow-derived mesenchymal stem cells improves tear production in a mouse model of sjogren's syndrome. *Stem Cells Int* (2017) 2017:3134543. doi: 10.1155/2017/3134543
111. Liu Y, Li C, Wang S, Guo J, Guo J, Fu J, et al. Human umbilical cord mesenchymal stem cells confer potent immunosuppressive effects in sjogren's syndrome by inducing regulatory T cells. *Mod Rheumatol* (2021) 31(1):186–96. doi: 10.1080/14397595.2019.1707996
112. Li B, Xing Y, Gan Y, He J, Hua H. Labial gland-derived mesenchymal stem cells and their exosomes ameliorate murine sjogren's syndrome by modulating the balance of treg and Th17 cells. *Stem Cell Res Ther* (2021) 12(1):478. doi: 10.1186/s13287-021-02541-0
113. Ogata K, Matsumura-Kawashima M, Moriyama M, Kawado T, Nakamura S. Dental pulp-derived stem cell-conditioned media attenuates secondary sjogren's syndrome via suppression of inflammatory cytokines in the submandibular glands. *Regener Ther* (2021) 16:73–80. doi: 10.1016/j.reth.2021.01.006
114. Gong B, Zheng L, Huang W, Pu J, Pan S, Liang Y, et al. Murine embryonic mesenchymal stem cells attenuated xerostomia in sjogren-like mice via improving salivary gland epithelial cell structure and secretory function. *Int J Clin Exp Pathol* (2020) 13(5):954–63.
115. Rui K, Hong Y, Zhu Q, Shi X, Xiao F, Fu H, et al. Olfactory ecto-mesenchymal stem cell-derived exosomes ameliorate murine sjogren's syndrome by modulating the function of myeloid-derived suppressor cells. *Cell Mol Immunol* (2021) 18(2):440–51. doi: 10.1038/s41423-020-00587-3
116. Shi B, Qi J, Yao G, Feng R, Zhang Z, Wang D, et al. Mesenchymal stem cell transplantation ameliorates sjogren's syndrome via suppressing IL-12 production by dendritic cells. *Stem Cell Res Ther* (2018) 9(1):308. doi: 10.1186/s13287-018-1023-x
117. Cai B, Cai JP, Luo YL, Chen C, Zhang S. The specific roles of JAK/STAT signaling pathway in sepsis. *Inflammation* (2015) 38(4):1599–608. doi: 10.1007/s10753-015-0135-z
118. Hofmann SR, Ettinger R, Zhou YJ, Gadina M, Lipsky P, Siegel R, et al. Cytokines and their role in lymphoid development, differentiation and homeostasis. *Curr Opin Allergy Clin Immunol* (2002) 2(6):495–506. doi: 10.1097/00130832-200212000-00004
119. Kolodziejska-Sawerska A, Rychlik A, Depta A, Wdowiak M, Nowicki M, Kander M. Cytokines in canine inflammatory bowel disease. *Pol J Vet Sci* (2013) 16(1):165–71. doi: 10.2478/pjvs-2013-0025
120. Nakayamada S, Kubo S, Iwata S, Tanaka Y. Chemical JAK inhibitors for the treatment of rheumatoid arthritis. *Expert Opin Pharmacother* (2016) 17(16):2215–25. doi: 10.1080/14656566.2016.1241237
121. Pardanani A, Laborde RR, Lasho TL, Finke C, Begna K, Al-Kali A, et al. Safety and efficacy of CYT387, a JAK1 and JAK2 inhibitor, in myelofibrosis. *Leukemia* (2013) 27(6):1322–7. doi: 10.1038/leu.2013.71
122. D'Amico F, Fiorino G, Furfaro F, Allocca M, Danese S. Janus kinase inhibitors for the treatment of inflammatory bowel diseases: developments from phase I and phase II clinical trials. *Expert Opin Investig Drugs* (2018) 27(7):595–9. doi: 10.1080/13543784.2018.1492547
123. Kremer JM, Emery P, Camp HS, Friedman A, Wang L, Othman AA, et al. A phase IIb study of ABT-494, a selective JAK-1 inhibitor, in patients with rheumatoid arthritis and an inadequate response to anti-tumor necrosis factor therapy. *Arthritis Rheumatol* (2016) 68(12):2867–77. doi: 10.1002/art.39801
124. Bowman SJ, Everett CC, O'Dwyer JL, Emery P, Pitzalis C, Ng WF, et al. Randomized controlled trial of rituximab and cost-effectiveness analysis in treating fatigue and oral dryness in primary sjogren's syndrome. *Arthritis Rheumatol* (2017) 69(7):1440–50. doi: 10.1002/art.40093
125. Mariette X, Seror R, Quartuccio L, Baron G, Salvin S, Fabris M, et al. Efficacy and safety of belimumab in primary sjogren's syndrome: results of the BELISS open-label phase II study. *Ann Rheum Dis* (2015) 74(3):526–31. doi: 10.1136/annrheumdis-2013-203991
126. Zhan T, Wang B, Fu J, Shao Y, Ye L, Shi H, et al. Artesunate inhibits sjogren's syndrome-like autoimmune responses and BAFF-induced b cell hyperactivation via TRAF6-mediated NF-kappaB signaling. *Phytomedicine* (2021) 80:153381. doi: 10.1016/j.phymed.2020.153381
127. Fisher BA, Szanto A, Ng W-F, Bombardieri M, Posch MG, Papas AS, et al. Assessment of the anti-CD40 antibody iscalimab in patients with primary sjogren's syndrome: a multicentre, randomised, double-blind, placebo-controlled, proof-of-concept study. *Lancet Rheumatol* (2020) 2(3):e142–e52. doi: 10.1016/S2665-9913(19)30135-3
128. Felten R MN, Duffaut P, Saadoun D, Hachulla E, Hatron P, Salliot C, et al. IL-6 receptor inhibition in primary sjogren syndrome: Results from a randomized multicenter academic double blind placebo-controlled trial of tocilizumab in 110 patients. *Arthritis Rheumatol* (2019) 71(suppl 10).
129. Dorner T, Posch MG, Li Y, Petricoul O, Cabanski M, Milojevic JM, et al. Treatment of primary sjogren's syndrome with ianalumab (VAY736) targeting b cells by BAFF receptor blockade coupled with enhanced, antibody-dependent cellular cytotoxicity. *Ann Rheum Dis* (2019) 78(5):641–7. doi: 10.1136/annrheumdis-2018-214720
130. Smolen J NP, Tahir H, Schulze-Koops H, Li L, Hohnik M, Gellett A, et al. Ianalumab (VAY736), a dual mode of action biologic combining BAFF receptor inhibition with b cell depletion, for treatment of primary sjogren's syndrome: Results of an international randomized, placebo controlled dose range finding study in 190 patients. *Arthritis Rheumatol* (2019) 71(suppl 10).
131. Meiners PM, Vissink A, Kroese FG, Spijkervet FK, Smitt-Kamminga NS, Abdulahad WH, et al. Abatacept treatment reduces disease activity in early primary sjogren's syndrome (open-label proof of concept ASAP study). *Ann Rheum Dis* (2014) 73(7):1393–6. doi: 10.1136/annrheumdis-2013-204653
132. Charras A, Arvaniti P, Le Dantec C, Arleevskaia MI, Zachou K, Dalekos GN, et al. JAK inhibitors suppress innate epigenetic reprogramming: a promise for patients with sjogren's syndrome. *Clin Rev Allergy Immunol* (2020) 58(2):182–93. doi: 10.1007/s12016-019-08743-y
133. Barrera MJ, Aguilera S, Castro I, Matus S, Carvajal P, Molina C, et al. Tofacitinib counteracts IL-6 overexpression induced by deficient autophagy: implications in sjogren's syndrome. *Rheumatol (Oxford)* (2021) 60(4):1951–62. doi: 10.1093/rheumatology/keaa670
134. Jabez-Ocampo J, Atisha-Fregoso Y, Llorente L. Refractory primary sjogren syndrome successfully treated with borteomib. *J Clin Rheumatol* (2015) 21(1):31–2. doi: 10.1097/RHU.0000000000000210
135. Navarra SV, Guzman RM, Gallacher AE, Hall S, Levy RA, Jimenez RE, et al. Efficacy and safety of belimumab in patients with active systemic lupus erythematosus: a randomised, placebo-controlled, phase 3 trial. *Lancet* (2011) 377(9767):721–31. doi: 10.1016/S0140-6736(10)61354-2
136. Edwards JC, Cambridge G. Sustained improvement in rheumatoid arthritis following a protocol designed to deplete b lymphocytes. *Rheumatol (Oxford)* (2001) 40(2):205–11. doi: 10.1093/rheumatology/40.2.205
137. Godeau B, Porcher R, Fain O, Lefrere F, Fenaux P, Cheze S, et al. Rituximab efficacy and safety in adult splenectomy candidates with chronic immune thrombocytopenic purpura: results of a prospective multicenter phase 2 study. *Blood* (2008) 112(4):999–1004. doi: 10.1182/blood-2008-01-131029
138. Sugai S. Report on "the 8th international symposium on sjogren syndrome". *Ryumachi* (2002) 42(5):765–8.
139. Gandolfo S, De Vita S. Double anti-b cell and anti-BAFF targeting for the treatment of primary sjogren's syndrome. *Clin Exp Rheumatol* (2019) 37 Suppl 118(3):199–208.
140. Jonsson R, Brokstad KA, Jonsson MV, Delaleu N, Skarstein K. Current concepts on sjogren's syndrome - classification criteria and biomarkers. *Eur J Oral Sci* (2018) 126 Suppl 1(Suppl Suppl 1):37–48. doi: 10.1111/eos.12536
141. Kroese FGM, Haacke EA, Bombardieri M. The role of salivary gland histopathology in primary sjogren's syndrome: promises and pitfalls. *Clin Exp Rheumatol* (2018) 36 Suppl 112(3):222–33.
142. Skarstein K, Aqrabi LA, Ojordsbakken G, Jonsson R, Jensen JL. Adipose tissue is prominent in salivary glands of sjogren's syndrome patients and appears to influence the microenvironment in these organs. *Autoimmunity* (2016) 49(5):338–46. doi: 10.1080/08916934.2016.1183656

Frontiers in Immunology

Explores novel approaches and diagnoses to treat immune disorders.

The official journal of the International Union of Immunological Societies (IUIS) and the most cited in its field, leading the way for research across basic, translational and clinical immunology.

Discover the latest Research Topics

[See more →](#)

Frontiers

Avenue du Tribunal-Fédéral 34
1005 Lausanne, Switzerland
frontiersin.org

Contact us

+41 (0)21 510 17 00
frontiersin.org/about/contact

