

# PLASTIC SURGERY FOR THE ONCOLOGICAL PATIENT

EDITED BY : Adrien Daigeler and Björn Behr

PUBLISHED IN : Frontiers in Oncology & Frontiers in Surgery



# frontiers

## Frontiers Copyright Statement

© Copyright 2007-2016 Frontiers Media SA. All rights reserved.

All content included on this site, such as text, graphics, logos, button icons, images, video/audio clips, downloads, data compilations and software, is the property of or is licensed to Frontiers Media SA ("Frontiers") or its licensees and/or subcontractors. The copyright in the text of individual articles is the property of their respective authors, subject to a license granted to Frontiers.

The compilation of articles constituting this e-book, wherever published, as well as the compilation of all other content on this site, is the exclusive property of Frontiers. For the conditions for downloading and copying of e-books from Frontiers' website, please see the Terms for Website Use. If purchasing Frontiers e-books from other websites or sources, the conditions of the website concerned apply.

Images and graphics not forming part of user-contributed materials may not be downloaded or copied without permission.

Individual articles may be downloaded and reproduced in accordance with the principles of the CC-BY licence subject to any copyright or other notices. They may not be re-sold as an e-book.

As author or other contributor you grant a CC-BY licence to others to reproduce your articles, including any graphics and third-party materials supplied by you, in accordance with the Conditions for Website Use and subject to any copyright notices which you include in connection with your articles and materials.

All copyright, and all rights therein, are protected by national and international copyright laws.

The above represents a summary only. For the full conditions see the Conditions for Authors and the Conditions for Website Use.

ISSN 1664-8714

ISBN 978-2-88919-987-7

DOI 10.3389/978-2-88919-987-7

## About Frontiers

Frontiers is more than just an open-access publisher of scholarly articles: it is a pioneering approach to the world of academia, radically improving the way scholarly research is managed. The grand vision of Frontiers is a world where all people have an equal opportunity to seek, share and generate knowledge. Frontiers provides immediate and permanent online open access to all its publications, but this alone is not enough to realize our grand goals.

## Frontiers Journal Series

The Frontiers Journal Series is a multi-tier and interdisciplinary set of open-access, online journals, promising a paradigm shift from the current review, selection and dissemination processes in academic publishing. All Frontiers journals are driven by researchers for researchers; therefore, they constitute a service to the scholarly community. At the same time, the Frontiers Journal Series operates on a revolutionary invention, the tiered publishing system, initially addressing specific communities of scholars, and gradually climbing up to broader public understanding, thus serving the interests of the lay society, too.

## Dedication to quality

Each Frontiers article is a landmark of the highest quality, thanks to genuinely collaborative interactions between authors and review editors, who include some of the world's best academicians. Research must be certified by peers before entering a stream of knowledge that may eventually reach the public - and shape society; therefore, Frontiers only applies the most rigorous and unbiased reviews.

Frontiers revolutionizes research publishing by freely delivering the most outstanding research, evaluated with no bias from both the academic and social point of view.

By applying the most advanced information technologies, Frontiers is catapulting scholarly publishing into a new generation.

## What are Frontiers Research Topics?

Frontiers Research Topics are very popular trademarks of the Frontiers Journals Series: they are collections of at least ten articles, all centered on a particular subject. With their unique mix of varied contributions from Original Research to Review Articles, Frontiers Research Topics unify the most influential researchers, the latest key findings and historical advances in a hot research area! Find out more on how to host your own Frontiers Research Topic or contribute to one as an author by contacting the Frontiers Editorial Office: [researchtopics@frontiersin.org](mailto:researchtopics@frontiersin.org)

# PLASTIC SURGERY FOR THE ONCOLOGICAL PATIENT

Topic Editors:

**Adrien Daigeler**, BG-University Hospital Bergmannsheil, Germany

**Björn Behr**, BG-University Hospital Bergmannsheil, Germany

The development of plastic surgery techniques allows for preserving and reconstruction of function after resection of malignant tumors. From split thickness skin grafts to pedicled and free tissue transfer multiple techniques are at hand to restore body integrity. Sufficient soft tissue coverage allows for adjuvant radiation therapy or can cure its sequelae. Nerve, tendon and muscle transfers are used to regain motor function of the extremities. Even large bony defects can be treated by microsurgically transferring fibula, pelvic and femoral bone. In case main vessels need to be resected reconstruction is possible with autologous and artificial grafts. By means of plastic surgery thoracic and abdominal defects can be covered so that foremost unresectable tumors become curable. Unfortunately the knowledge of these techniques is not very popular with oncologic surgeons. Therefore we suggest as a clinical topic the role of reconstructive surgery in the multimodal treatment of oncologic patients. The focus will be on different areas of the body, therefore articles for reconstructive procedures at the head, the extremities, the trunk, the thoracic wall, the breast, and the foot will be invited. Another focus will be the role of reconstructive procedures in the multimodal treatment concept consisting of radiation and chemotherapy as well. By knowing and applying the opportunities of plastic surgery the quality of life of the oncologic patient can be significantly improved.

**Citation:** Daigeler, A., Behr, B., eds. (2016). Plastic Surgery for the Oncological Patient. Lausanne: Frontiers Media. doi: 10.3389/978-2-88919-987-7

# Table of Contents

**05 Editorial: Plastic Surgery for the Oncological Patient**

Adrien Daigeler

**Head**

**07 Microsurgical reconstruction of extensive oncological scalp defects**

Ole Goertz, Leon von der Lohe, Ramón Martínez-Olivera, Adrien Daigeler, Kamran Harati, Tobias Hirsch, Marcus Lehnhardt and Jonas Kolbensschlag

**Breast and Thoracic Wall**

**14 Breast Reconstruction after Mastectomy**

Daniel Schmauss, Hans-Günther Machens and Yves Harder

**23 Thoracic wall reconstruction after tumor resection**

Kamran Harati, Jonas Kolbensschlag, Björn Behr, Ole Goertz, Tobias Hirsch, Nicolai Kapalschinski, Andrej Ring, Marcus Lehnhardt and Adrien Daigeler

**Trunk**

**33 Reconstructive Options for Oncologic Posterior Trunk Defects: A Review**

Björn Behr, Johannes M. Wagner, Christoph Wallner, Kamran Harati, Marcus Lehnhardt and Adrien Daigeler

**39 Plastic and reconstructive surgery in the treatment of oncological perineal and genital defects**

Rebekka Brodbeck, Raymund E. Horch, Andreas Arkudas and Justus P. Beier

**Extremities**

**47 Soft Tissue Coverage of the Lower Limb following Oncological Surgery**

Christine Radtke, Martin Panzica, Khaled Dastagir, Christian Krettek and Peter M. Vogt

**54 Soft Tissue Sarcomas of the Arm – Oncosurgical and Reconstructive Principles within a Multimodal, Interdisciplinary Setting**

Georgios Koulaxouzidis, Filip Simunovic and Holger Bannasch

**63 Reconstruction of Soft-Tissue Defects at the Foot and Ankle after Oncological Resection**

Andrej Ring, Pascal Kirchhoff, Ole Goertz, Björn Behr, Adrien Daigeler, Marcus Lehnhardt and Kamran Harati



**Neoadjuvant and Adjuvant Treatment Options and their Influence on Plastic Surgery Techniques**

**72    *Plastic Surgery in the Multimodal Treatment Concept of Soft Tissue Sarcoma: Influence of Radiation, Chemotherapy, and Isolated Limb Perfusion on Plastic Surgery Techniques***

Nicolai Kapalschinski, Ole Goertz, Kamran Harati, Maximilian Kueckelhaus, Jonas Kolbensschlag, Marcus Lehnhardt and Tobias Hirsch



# Editorial: Plastic Surgery for the Oncological Patient

**Adrien Daigeler\***

*Department of Plastic Surgery, BG-University Hospital Bergmannsheil, Bochum, North Rhine-Westphalia, Germany*

**Keywords:** plastic surgery, free flap, pedicled flap, breast reconstruction, soft-tissue sarcoma, soft-tissue defect, reconstruction in oncology, scalp defect

## The Editorial on the Research Topic

### Plastic Surgery for the Oncological Patient

Secondary to various surgical and non-surgical innovations for malignancy treatment, survival times associated with disease have improved for most cancer entities over the recent decades. Prolonged survival permits many oncologic patients to experience longer lives despite their advanced cancer stage. Working along the fellow cancer specialists, such as the oncologist, radiotherapist, and other surgical subspecialties, the plastic and reconstructive surgeon can add valuable tools to the armamentarium of oncological care in the palliative situation as well as importantly impact the cancer patient's quality of life. Plastic surgery can help to cover defects after resection of ulcerating, bleeding, and fetid tumors. Painful ulcers can be excised and closed by tissue transfer. Large tumor masses causing pain or restrictions in function can be resected and defects covered. Patient care will be facilitated, and quality of life of the palliative patient will be improved, by allowing them to take part in social life for the time remaining.

Furthermore, plastic surgery techniques can be used to cover defects following curative tumor resection and, thereby, make resections possible that otherwise would not be compatible with life, such as large skull, thoracic, and abdominal wall resections. Tissue transfer allows for tension-free defect coverage and reduces wound complication rates and time to healing. Adjuvant radiation and chemotherapy can be administered early, and hospitalization is shorter. By augmenting the soft-tissue envelope, flap coverage can not only enable a timely start of radiation therapy but can also be used to mitigate its adverse effects by the transfer of healthy tissue in case of radiation ulcers. By tendon, nerve, or muscle transfers, reconstruction of motor function follows resection of nerves or important muscles. Vessels can be replaced by autologous or synthetic grafts. By a combination of these techniques, limb salvage is possible in most cases with malignancies at the extremities. In cases where limb salvage is not possible because of excessive tumor growth, advanced resection techniques like intra-thoraco-scapular amputations or hemipelvectomies may become necessary. Resulting defects can then be covered with remaining soft-tissue flaps from the amputated extremity. In situations where a complete resection of the tumor cannot be achieved, despite these techniques, it is even feasible to cover remaining tumor tissue with bulky flaps to delay ulceration.

Unfortunately, the oncologic plastic surgeon often faces the situation that patients are referred too late so that sufficient reconstruction is no longer possible, and ablative procedures need to be performed. Medical oncologists, radiotherapists, and other partners treating oncologic patients must be informed about the treatment options of plastic surgery. To spread the awareness of the possible values of plastic surgery techniques for the sake of the oncologic patient, several articles focusing on different areas of the body are combined in this ebook to give an overview.

The first article and section focuses on craniofacial oncology of scalp reconstruction. These patients are usually treated in cooperation with neurosurgeons who take care of the intracranial

## OPEN ACCESS

### Edited by:

Raphael Pollock,  
Ohio State University, USA

### Reviewed by:

Ian Lee Valerio,  
Ohio State University, USA  
Donald Baumann,  
University of Texas MD Anderson  
Cancer Center, USA

### \*Correspondence:

Adrien Daigeler  
daigeler@hotmail.com

### Specialty section:

This article was submitted  
to Surgical Oncology,  
a section of the journal  
Frontiers in Oncology

**Received:** 08 March 2016

**Accepted:** 12 August 2016

**Published:** 31 August 2016

### Citation:

Daigeler A (2016) Editorial: Plastic  
Surgery for the Oncological Patient.  
Front. Oncol. 6:191.  
doi: 10.3389/fonc.2016.00191

tumor and bony reconstruction, while the plastic surgeon takes care of the soft-tissue coverage. The latissimus dorsi flap eventually combined with a parascapular flap is a save option; however, recipient vessels for the flap must be identified carefully. The muscle part of the flap covered with split thickness skin graft results in an esthetical acceptable aspect and allows for wig placement.

The second series of articles deals with diverse options available for oncologic breast reconstruction as well as complex chest wall reconstruction in cancer.

Another article deals with the individualized breast reconstruction after mastectomy for breast cancer, including implant- and expander-based, flap-based, a combination of both, and breast reconstruction using fat grafting, giving the pros and cons for each technique. The following article refers to advanced stages of malignancies, making thoracic wall resections and reconstructions necessary. Possible reconstructive procedures are mentioned and weighed against the literature as well as information of the influence of thoracic wall resections on pulmonary function and quality of life is given.

The third section outlines the challenging aspects of truncal reconstruction, including the posterior aspect of the trunk, which challenges the plastic surgeon because of limited recipient vessels for free flap surgery and limited availability of large pedicled flaps. Therefore, an article illustrates alternative options ranging from vessel loops over combined perforator-based pedicled propeller flaps to free flaps anastomosed microscurgically to recipient perforator vessels at the back.

Further down the human body, the perineal region often requires defect coverage after extensive tumor resections. The corresponding article points out the value of the pedicled VRAM flap for perineal defects but also shows alternatives, including vessel loops for free flap reconstruction. In special cases, a two-stage procedure consisting of resection and vacuum dressing followed by definite coverage after confirmation of negative margins by the pathology report can be performed.

This strategy is also mentioned in the following articles of the fourth section dealing with reconstruction at the extremities.

**Conflict of Interest Statement:** The author declares that the research was conducted in the absence of any commercial or financial relationships that could be construed as a potential conflict of interest.

The reviewer I.L.V. and handling Editor declared their shared affiliation, and the handling Editor states that the process nevertheless met the standards of a fair and objective review.

Although many studies have proven that the former dogma of wide excision can no longer be upheld in terms of recurrence and survival, complete resection should be achieved to reduce the local recurrence rate. In the extremities, functional structures, such as vessels and nerves, adjunct to the tumor should be preserved, but in some cases have to be resected with the tumor specimen. In these cases, functional reconstruction becomes necessary, which happens more often in the arm and especially the hand and foot than in the thigh or trunk because of the multitude of functionally relevant structures running in narrow spaces. In these cases, nerves, vessels, and muscles need to be replaced by microsurgical techniques or tendon transfers performed. Additionally, free-tissue transfer is required in up to 70% after tumor resections to cover exposed bone, tendon or vessels. In special cases, even microsurgical bone transfer or prosthetic joint replacement is necessary. In these cases, co-operation with trauma or orthopedic surgeons is helpful to guarantee the best possible functional outcome.

The last article and section discusses neoadjuvant and adjuvant treatment options, like radiation, chemotherapy, and isolated limb perfusion and their influence on plastic surgery techniques in terms of timing and complication rates.

While oncological safety remains of utmost importance, a multi-modal approach and advanced plastic surgery techniques can improve survival and quality of life as well as mitigate resulting functional deficits.

Due to the growing complexity of oncological care and the variety of disciplines involved, this can be best achieved in an inter-disciplinary setting of close collaborations (tumor boards, joint rounds, etc.) and is, therefore, well suited in specialized high-volume centers. The plastic and reconstruction surgeon should be an integral part to the combined multidisciplinary care of the oncologic patient.

## AUTHOR CONTRIBUTIONS

The author confirms being the sole contributor of this work and approved it for publication.

*Copyright © 2016 Daigeler. This is an open-access article distributed under the terms of the Creative Commons Attribution License (CC BY). The use, distribution or reproduction in other forums is permitted, provided the original author(s) or licensor are credited and that the original publication in this journal is cited, in accordance with accepted academic practice. No use, distribution or reproduction is permitted which does not comply with these terms.*



# Microsurgical reconstruction of extensive oncological scalp defects

Ole Goertz<sup>1\*</sup>, Leon von der Lohe<sup>1</sup>, Ramón Martínez-Olivera<sup>2</sup>, Adrien Daigeler<sup>1</sup>, Kamran Harati<sup>1</sup>, Tobias Hirsch<sup>1</sup>, Marcus Lehnhardt<sup>1</sup> and Jonas Kolbenschlager<sup>1</sup>

<sup>1</sup> Department of Plastic Surgery, BG University Hospital Bergmannsheil, Ruhr-University, Bochum, Germany, <sup>2</sup> Neurosurgical Unit, Department of Surgery, BG University Hospital Bergmannsheil, Ruhr-University, Bochum, Germany

## OPEN ACCESS

### Edited by:

Wim Ceelen,  
Ghent University Hospital, Belgium

### Reviewed by:

Andreas Arkudas,  
University Hospital of Erlangen,  
Germany  
Thomas Kremer,  
BG Trauma Center Ludwigshafen,  
Germany

### \*Correspondence:

Ole Goertz,  
Department of Plastic Surgery, BG  
University Hospital Bergmannsheil,  
Buerkle-de-la-Camp-Platz 1, Bochum  
44789, Germany  
ole.goertz@rub.de

### Specialty section:

This article was submitted to Surgical  
Oncology, a section of the  
journal *Frontiers in Surgery*

**Received:** 10 July 2015

**Accepted:** 21 August 2015

**Published:** 30 September 2015

### Citation:

Goertz O, von der Lohe L,  
Martínez-Olivera R, Daigeler A,  
Harati K, Hirsch T, Lehnhardt M and  
Kolbenschlager J (2015) Microsurgical  
reconstruction of extensive  
oncological scalp defects.  
*Front. Surg.* 2:44.  
doi: 10.3389/fsurg.2015.00044

Although most small to medium defects of the scalp can be covered by local flaps, large defects or complicating factors, such as a history of radiotherapy, often require a microsurgical reconstruction. Several factors need to be considered in such procedures. A sufficient preoperative planning is based on adequate imaging of the malignancy and a multi-disciplinary concept. Several flaps are available for such reconstructions, of which the latissimus dorsi and anterior-lateral thigh flaps are the most commonly used ones. In very large defects, combined flaps, such as a parascapular/latissimus dorsi flaps, can be highly useful or necessary. The most commonly used recipient vessels for microsurgical scalp reconstructions are the superficial temporal vessels, but various other feasible choices exist. If the concomitant veins are not sufficient, the jugular veins represent a safe back-up alternative but require a vessel interposition or long pedicle. Post-operative care and patient positioning can be difficult in these patients but can be facilitated by various devices. Overall, microsurgical reconstruction of large scalp defects is a feasible undertaking if the mentioned key factors are taken into account.

**Keywords:** plastic surgery, reconstruction, oncology, calvarial defect, head

## Introduction

The scalp covers the calvarium and consists of skin, subcutaneous tissue, the galea aponeurotica, loose areolar tissue, and the pericranium. If this cover is disrupted by trauma or the resection of malignancies, the exposed bone can succumb to infection and its potentially life-threatening complications. Therefore, timely reconstruction of such defects is paramount.

For small and medium sized defects, local flaps are often sufficient. Such coverage by means of adjacent tissue gives a good color and texture match and even allows the reconstruction of the hair bearing area. However, in large defects or in patients with a history of radiation therapy, such options are often not feasible. In these cases, free tissue transfer becomes the first choice (1).

Interestingly, the microsurgical reconstruction of the scalp was one of the earliest applications of free tissue transfer. Already in 1972, McLean and Buncke covered a large scalp defect with a free omentum majus flap (2). Microsurgery and its reconstructive possibilities have evolved since then, but some general principles still remain of unchanged importance.

Therefore, the aim of this review is to illustrate several general and specific considerations in patients undergoing microsurgical reconstruction of large oncological scalp defects.

## General Considerations

A sufficient preoperative planning is essential for an extensive surgical procedure, such as the oncological resection and microsurgical reconstruction of malignancies of the scalp.

First, the surgical resectability of the tumor needs to be evaluated. Although MRI provides good visualization of the soft tissues and the tumor, CT-scans can aid in assessing the amount of involvement of the calvarium bone. In patients with an extensive history of operative interventions, such as neck dissections or radiation therapy, an angiography of the possible recipient vessels can support preoperative decision-making and facilitate the intraoperative dissection. Based on the angiography findings (as well as in their absence), one should also devise a back-up plan in case the primary vessel can not be dissected due to scarring or does not show adequate flow after dissection.

Multiple soft-tissue and bone biopsies can aid in both an exact diagnosis of the malignancy and the planning of the surgical margins. Also, an adequate staging of the disease is paramount. Such complex cases should be preoperatively discussed in an interdisciplinary board of oncologists, neurosurgeons, and plastic surgeons. Here, not only the resection and reconstruction but also the use of (neo-)adjuvant radio- or chemotherapy should be discussed. Especially noteworthy in this regard is the trend toward less aggressive resections of sarcomas. Although the wide resection is still commonly recommended in sarcoma surgery, such an approach would render most of the sarcomas of the scalp to be considered not resectable. According to the findings in sarcomas of the extremities and recurrent sarcomas, less radical resections might be sufficient for most entities, as long as clear surgical margins are achieved (3, 4).

Only by incorporating all these findings, a reasonable treatment plan can be devised. However, even the most elaborate surgical treatment plan cannot stand on its own and needs to be adjusted to the individual patient and their respective wishes. Especially in a palliative situation, invasiveness of the procedure and its potential complications need to be weighted carefully against the expected gain in quality of life. Nonetheless, even large reconstructions should not be shunned in the face of palliation, if the patient is capable and willing to undertake such a journey. In this way, defects that are painful, bleeding, and demand extensive wound care can be covered, enabling the patient to regain their independence and quality of life (5, 6).

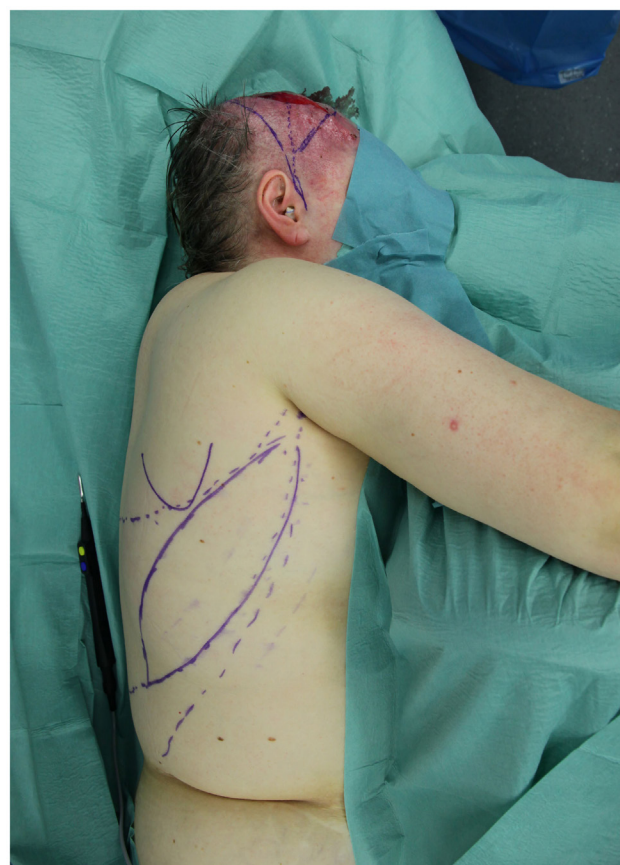The possibility to cover nearly any soft-tissue defect of the scalp via free tissue transfer enables a radical surgical resection. Often, this resection also has to include the calvarium bone and the dura. Such defects are commonly covered by custom-made methyl acrylate implants or titanium mesh implants and dura patch plasties. In some cases, a microvascular transplant can be used as a dermal reinforcement of such a dura plasty (7).

## Soft-Tissue Reconstruction

A variety of free flaps have been described for the microsurgical reconstruction of the scalp (2, 8–10). The choice of free flap is mainly dependent on the size of the defect and the required pedicle length. Due to its size, the latissimus dorsi has become one of the

work horse flaps for scalp reconstruction (11). It can be harvested as a sole muscle flap or musculocutaneous flap with an overlying skin paddle. Although this skin paddle facilitates clinical perfusion monitoring or/and could be use for extension of coverage, it is often very bulky due to the subcutaneous fat. In high risk cases requiring intense monitoring of the flap (coagulopathies, history of radiation, e.g.) such a skin paddle might be easier to monitor than the muscle itself. In such cases, one or more perforating vessel that supply the overlying skin paddle can be dissected in the initial operation. After isolating the paddle on these perforators, the muscle surface of the flap can be skin grafted, leaving only small gaps for the vessels (12). When the need for an intense clinical monitoring has subsided, the perforator-based skin paddle can be easily removed by ligating the vessels without the need for additional surgery. The initial bulk of the latissimus declines over the course of time and together with a split thickness graft results in a reasonable esthetic outcome. The case of a patient undergoing free latissimus dorsi coverage of the scalp following oncological resection is depicted in **Figures 1–5**.

In the beginning, we designed those skin islands on multiple perforators, but such large skin islands are often hard to fix to the underlying surface and can be compromised by shearing off due to their own weight. Therefore, a smaller island with one singled

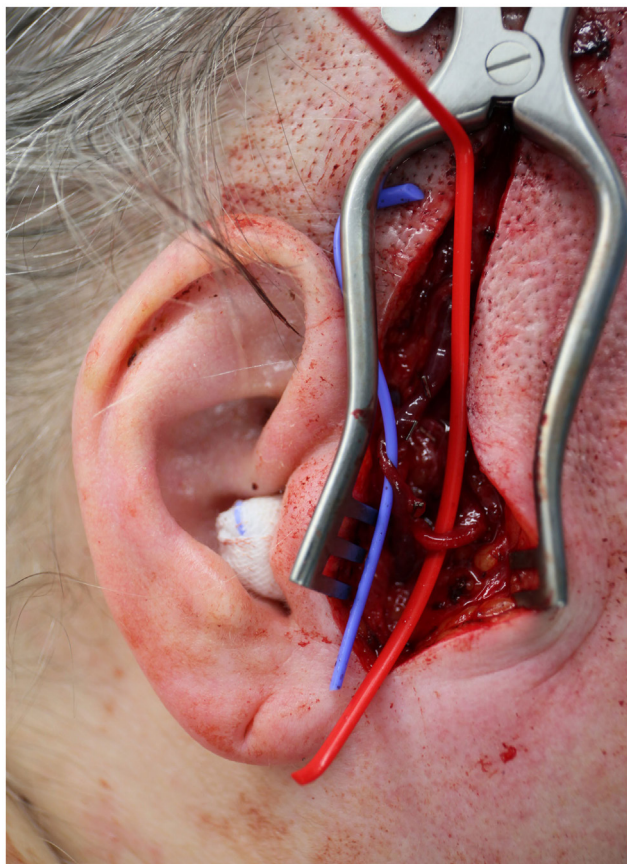

**FIGURE 1 | Intraoperative view of a patient with an oncological defect of the scalp.** The latissimus skin paddle as well as the anatomical landmarks are marked.

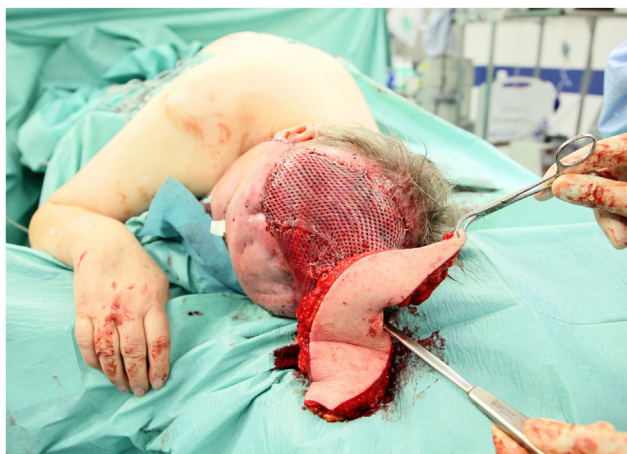Q1

Q2



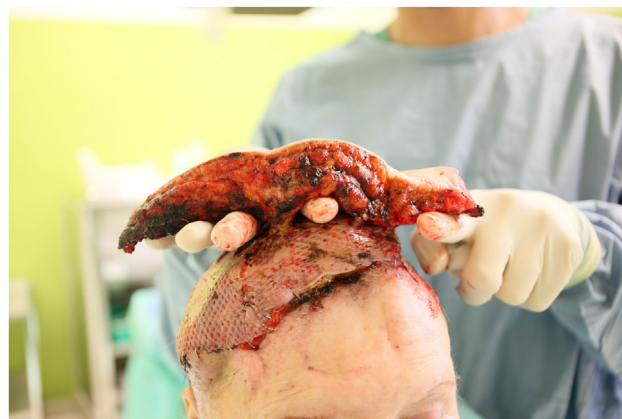

**FIGURE 2 |** The dissected superficial temporal vessels that will be utilized as recipient vessels.

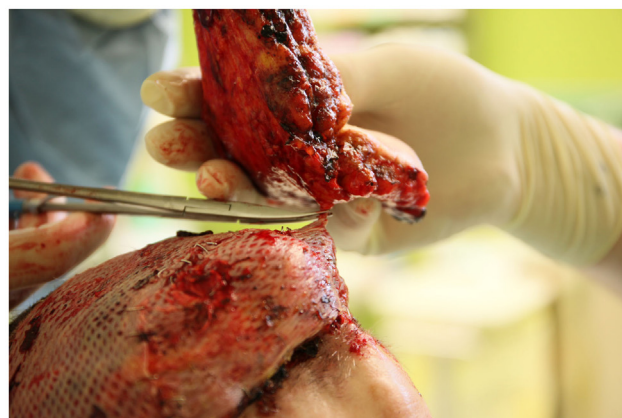

**FIGURE 3 |** After fitting of the flap. Note the skin grafted muscle surface with leaves only small gaps for the vessels.

out perforator is often more feasible, especially since the option to use such a perforator island as another flap to close secondary defects is undesirable in this constellation due to the bulk of the subcutaneous fat.



**FIGURE 4 |** Skin paddle of a latissimus dorsi free flap based on three perforator vessels 1 week after surgery.

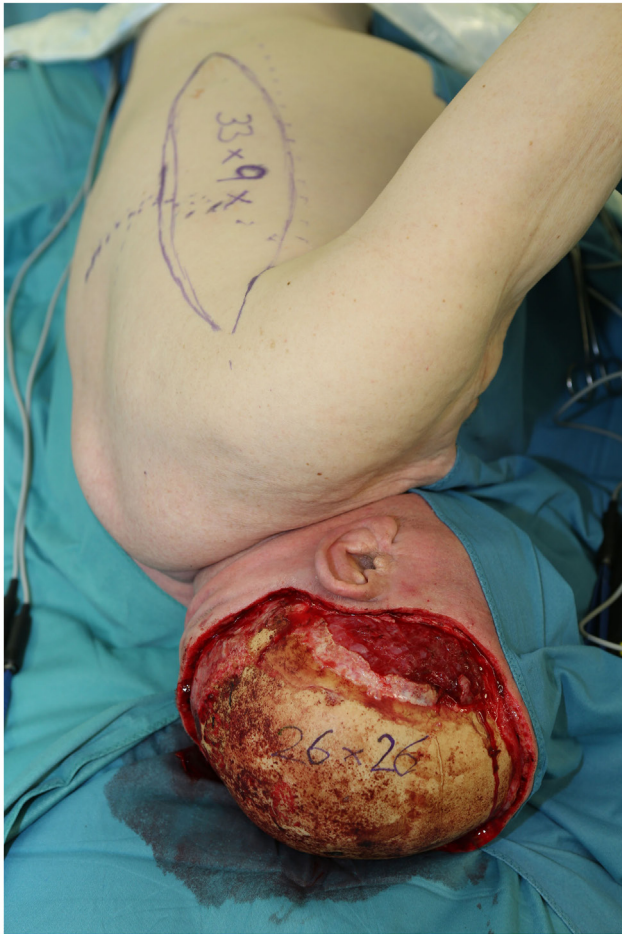

**FIGURE 5 |** Removal of the skin paddle after ligation and severing of the perforating vessels.

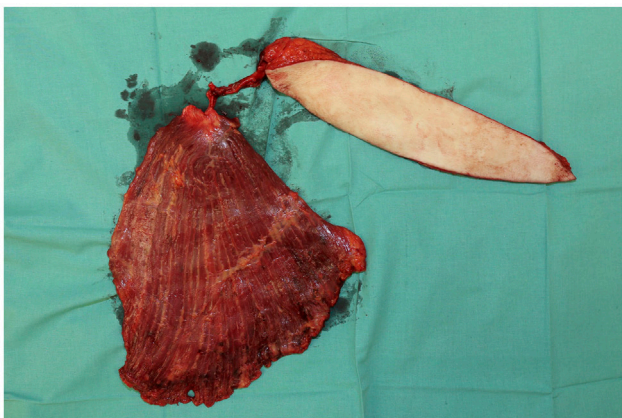
Based on the same vascular tree, the (para-) scapular flap can be raised as a fascio-cutaneous flap that carries little bulk and sufficient pedicle length (13). Due to their common vascular tree, both the (para-)scapular and the latissimus flap can be harvested together, thus allowing for even larger defects to be covered. A disadvantage of harvesting the common vascular tree is the extensive diameter of the venular confluence and its mismatch with the tiny vein of the superficial temporal vessels. To achieve a smooth passage at the anastomosis, we utilize a chamfering technique that is discussed later. We prefer to place the parascapular flap with its good skin quality over the occipital bone and the latissimus muscle over the mid part of the calvarium. This way, the more resilient skin of the parascapular flap allows for a better cover when resting the head. **Figures 6–9** depict the case of a patient undergoing total scalp resection for an angiosarcoma and the microsurgical reconstruction with a chimeric Latissimus/Parascapular flap.

Another commonly used free flap is the anterior-lateral thigh flap (ALT). The mean achievable flap size is smaller than in the

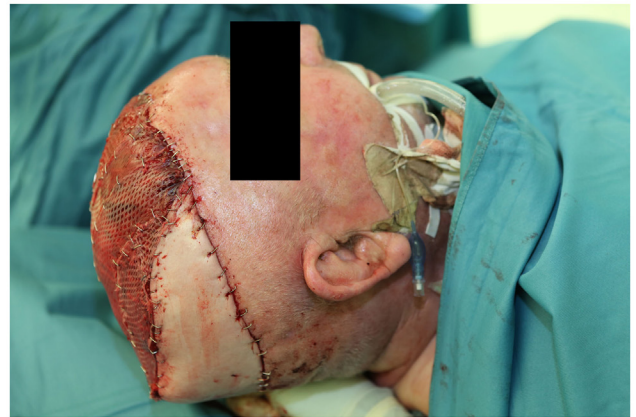



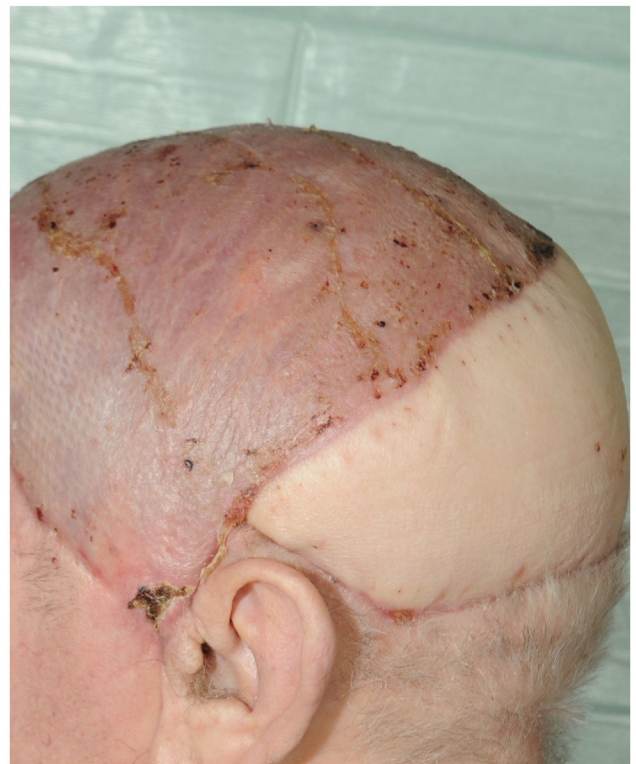**FIGURE 6 | Intraoperative view after total full thickness scalp resection due to an angiosarcoma.** Note the 26 cm x 26 cm sized defect and the planned parascapular flap with a size of 33 cm x 9 cm.



**FIGURE 7 | The combined latissimus/parascapular flap after its elevation on the common vascular pedicle.**



**FIGURE 8 | Intraoperative view after fitting of the flaps.** Note the more resilient skin cover of the parascapular flap over the occiput on which the head rests.



**FIGURE 9 | Follow up after 4 weeks.**

latissimus; however, it carries less initial bulk in slender patients. In cases where obliteration of dead space is required, the flap can be raised as a musculocutaneous flap that incorporates the vastus lateralis muscle. One of the main advantages of the ALT flap over the latissimus and the (para-)scapular flap is the possibility to harvest it in a supine position. However, in extensive scalp defects,

the patient is often positioned in either a prone or lateral position to allow access to the entire defect thus negating this advantage.

A good alternative for medium to large defects is the gracilis muscle free flap. It can be expanded and also flattened by intramuscular dissection, allowing for a stable coverage without too much bulk (14). Also, similar to the latissimus flap, the appearance of the grafted muscle surface is often superior to the patch-like appearance of fascio-cutaneous flaps.

Other potential flap choices include the ulnar and radial forearm flaps. Both deliver little bulk and often require a less complex dissection than perforator flaps. However, the donor site including the loss of a major artery can be problematic. Therefore, these flaps are not the first choice in our hands.

## Specific Considerations

One of the main things to be considered in microsurgical reconstructions is the recipient vessels. Although there are several potential vessels available in the head and neck, the choice of the optimal vessel depends on various factors. Depending on the localization of the defect, the recipient vessels should be easily reachable with the anticipated pedicle length, thus eliminating the need for vein grafts. In patients with extensive previous operations, such as neck dissections or history of radiotherapy, the integrity of the vessels might be compromised or its dissection can be hindered by scars. Therefore, preoperative evaluation of their patency is recommended in such cases. Often, hand-held Doppler assessment is sufficient. However, in selected cases, an angiography can aid in the preoperative planning. As mentioned above, sometimes the primary “go-to” vessel can not be dissected due to scarring or shows insufficient flow. Therefore, a back-up plan needs to be devised beforehand.

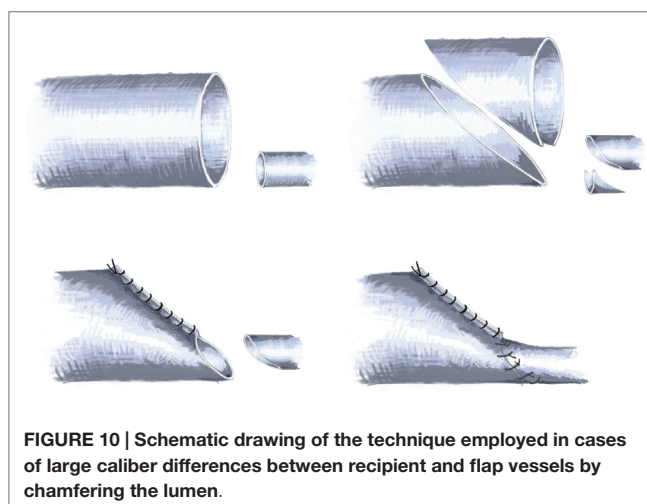
Due to its easy access in the preauricular space and reliable course, the superficial temporal artery is one of the most commonly used recipient vessels in microsurgical scalp reconstruction (10, 15). However, there can be a serious discrepancy of the caliber between the flap and the recipient vessels, especially in chimeric flaps. To reach an appropriate size of recipient vessels, one can either extend the dissection proximally, which in turn can bring the need for the interposition of vein grafts. Although such grafts carry an intrinsic risk, a proximal anastomosis often has less tendency for spasms and can deliver a higher blood flow to perfuse even very large flaps. Also, in our experience, the superficial temporal artery reacts quite sensitive to manipulation and its flow can easily become compromised due to vasoconstriction. However, by dissection of the artery to the level of the ear lobe the flow becomes sufficient in most cases.

Another option is to perform an end-to-end anastomosis after preparing both vessels in the way depicted in **Figure 10**. By chamfering the larger lumen of the flap vessel, a cone-like configuration can be achieved. This cone can then be adapted to the size of the recipient vessels by the numbers of sutures placed. In this way, the lumen can be tailored to the required size in a safe and reliable way. Such a procedure does also carry some intrinsic risk for thrombosis, therefore careful consideration of the recipient vessels need to be taken.

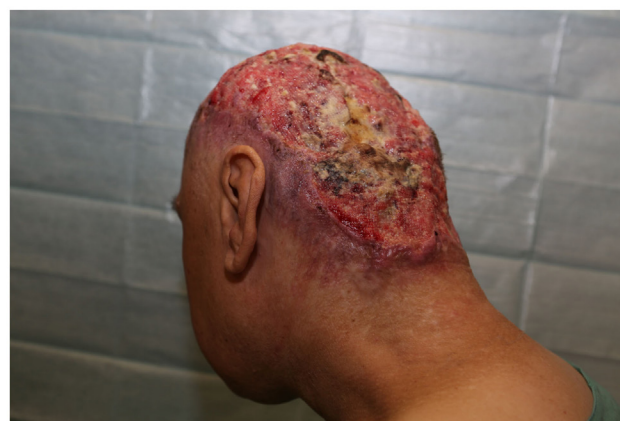Other options of recipient vessels include the superior thyroid and the facial artery. In cases where the concomitant veins are not sufficient, the internal and external jugular veins represent a reliable alternative (10, 16).

Due to the tendency to rest the head on the occipital bone, post-operative positioning of patients with total scalp reconstruction can be problematic. To avoid pressure on the flap, the patient can be positioned in a sitting position with some support of the cervical spine. If post-operative ventilation is required, the patient can be brought into a prone position to allow for an absolute pressure free environment for the flap. To facilitate this, special beds for the prone positioning of patients as seen in burn units can be used. However, both in sitting and prone positions, the risk for pressure sores is increased and therefore requires meticulous assessment of the soft tissues over high pressure areas.

**Figures 11–15** depict the case of a patient with a neglected carcinoma of the skull and a reduced compliance due to a mental handicap. Even despite complete resection of the malignancy, the

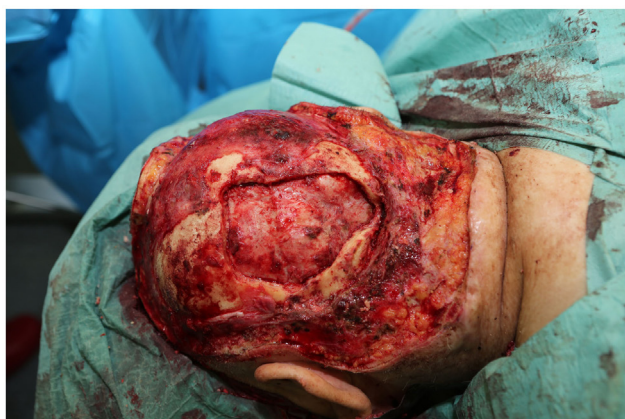

**FIGURE 10 |** Schematic drawing of the technique employed in cases of large caliber differences between recipient and flap vessels by chamfering the lumen.

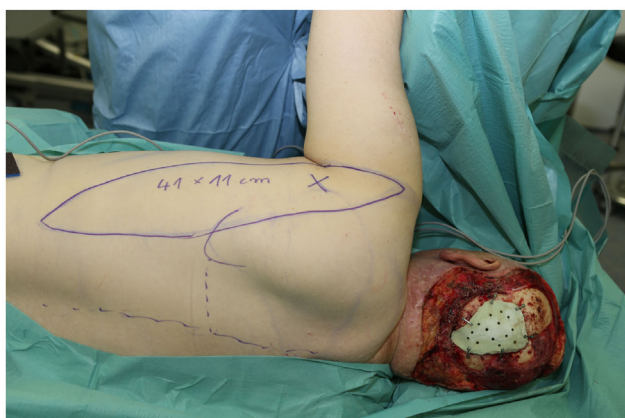


**FIGURE 11 |** A case of extensive squamous cell carcinoma of the scalp with infiltration of the calvarium.

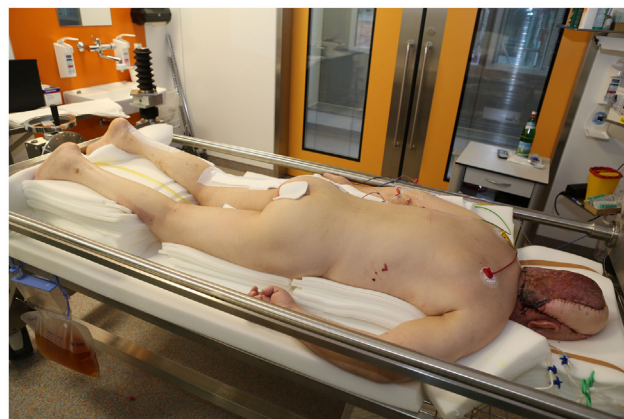



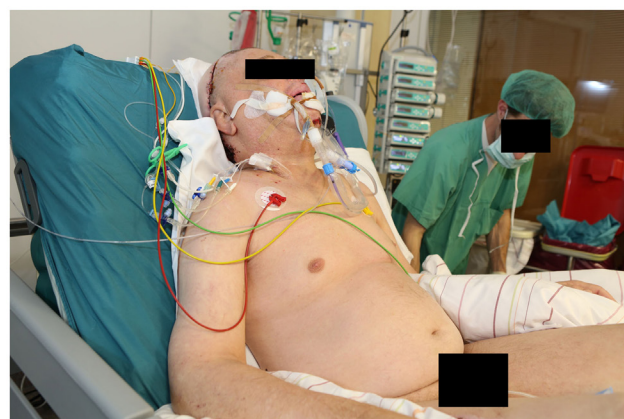**FIGURE 12 |** Intraoperative view after resection of the scalp and the infiltrated calvarium.



**FIGURE 13 |** The calvarial defect was closed with a custom-made methyl acrylate implant. Note the anatomical landmarks and the outline of the planned skin paddle of the parascapular flap.



**FIGURE 14 |** The patient was initially positioned in a prone position. Note the extensive padding to reduce the incidence of pressure sores and the apparatus on the end of the bed that facilitates rotating the bed.



**FIGURE 15 |** The same patient in a sitting position to prepare for extubation.

patient deceased 12 months after surgery due to metastatic disease. However, the painful daily dressing changes were discontinued, improving the quality of life of the patient. Therefore, such complex reconstructions can also be feasible in a palliative setting. In such cases, the invasiveness of the procedure needs to be weighted very carefully against the expected gains in quality of life.

Also, the site of the anastomosis itself needs to be protected from any pressure. If the anastomosis is in the area of the lateral face and neck, a modified cervical spine collar with sufficient space over the area of the anastomosis can aid in protecting it.

## References

- Desai SC, Sand JP, Sharon JD, Branham G, Nussenbaum B. Scalp reconstruction: an algorithmic approach and systematic review. *JAMA Facial Plast Surg* (2015) 17(1):56–66. doi:10.1001/jamafacial.2014.889
- McLean DH, Buncke HJ Jr. Autotransplant of omentum to a large scalp defect, with microsurgical revascularization. *Plast Reconstr Surg* (1972) 49(3):268–74. doi:10.1097/00006534-197203000-00005

## Conclusion

The ability to reconstruct even total scalp defects via free tissue transfer enables the radical surgical resection of malignancies.

A variety of free flaps are available for this task, most prominently the latissimus dorsi and the ALT flap. In very large defects, the latissimus dorsi and a parascapular flap can be elevated on their common vascular tree and used as a chimeric flap. Although the reconstruction itself as well as the perioperative management can be challenging, the overall outcomes with regards to the reconstruction is good.

- Daigeler A, Zmarsly I, Hirsch T, Goertz O, Steinau HU, Lehnhardt M, et al. Long-term outcome after local recurrence of soft tissue sarcoma: a retrospective analysis of factors predictive of survival in 135 patients with locally recurrent soft tissue sarcoma. *Br J Cancer* (2014) 110(6):1456–64. doi:10.1038/bjc.2014.21
- Steinau HU, Steinstrasser L, Langer S, Stricker I, Goertz O. [Surgical margins in soft tissue sarcoma of the extremities]. *Pathologe* (2011) 32(1):57–64. doi:10.1007/s00292-010-1394-y

5. Daigeler A, Harati K, Kapalschinski N, Goertz O, Hirsch T, Lehnhardt M, et al. Plastic surgery for the oncological patient. *Front Surg* (2014) 1:42. doi:10.3389/fsurg.2014.00042
6. Kippenhan T, Hirche C, Lehnhardt M, Daigeler A. [Palliative plastic surgery in multidisciplinary therapeutic concepts]. *Zentralbl Chir* (2015) 140(2):228–34. doi:10.1055/s-0032-1328184
7. Lessard L, Tahiri Y. Complex scalp, skull, and dural defect reconstruction using a turnover “tournedos” myocutaneous free flap. *J Craniofac Surg* (2013) 24(1):62–5. doi:10.1097/SCS.0b013e318272db28
8. Chao AH, Yu P, Skoracki RJ, Demonte F, Hanasono MM. Microsurgical reconstruction of composite scalp and calvarial defects in patients with cancer: a 10-year experience. *Head Neck* (2012) 34(12):1759–64. doi:10.1002/hed.21999
9. Lee B, Bickel K, Levin S. Microsurgical reconstruction of extensive scalp defects. *J Reconstr Microsurg* (1999) 15(4):255–62. doi:10.1055/s-2007-1000099
10. Takamatsu A, Harashina T, Inoue T. Selection of appropriate recipient vessels in difficult, microsurgical head and neck reconstruction. *J Reconstr Microsurg* (1996) 12(8):499–507. doi:10.1055/s-2007-1006622
11. Lin SJ, Hanasono MM, Skoracki RJ. Scalp and calvarial reconstruction. *Semin Plast Surg* (2008) 22(4):281–93. doi:10.1055/s-0028-1095887
12. Beier JP, Horch RE, Dragu A, Arkudas A, Kneser U. Perforator-based monitoring skin islands in free muscle flaps: teaching old dogs new tricks. *Plast Reconstr Surg* (2012) 129(3):586e–7e. doi:10.1097/PRS.0b013e3182419c54
13. Sachs C, Lehnhardt M, Daigeler A, Goertz O. [Free fasciocutaneous parascapular flap: Coverage of extensive skin and soft tissue defects]. [Article in German] *Unfallchirurg* (2015). doi:10.1007/s00113-014-2686-0.
14. Huemer GM, Dunst KM, Maurer H, Ninkovic M. Area enlargement of the gracilis muscle flap through microscopically aided intramuscular dissection: ideas and innovations. *Microsurgery* (2004) 24(5):369–73. doi:10.1002/micr.20050
15. Medved F, Manoli T, Medesan R, Janghorban Esfahani B, Stahl S, Schaller HE, et al. In vivo analysis of the vascular pattern of the superficial temporal artery based on digital subtraction angiography. *Microsurgery* (2014) 35(5):380–6. doi:10.1002/micr.22348
16. van Driel AA, Mureau MA, Goldstein DP, Gilbert RW, Irish JC, Gullane PJ, et al. Aesthetic and oncologic outcome after microsurgical reconstruction of complex scalp and forehead defects after malignant tumor resection: an algorithm for treatment. *Plast Reconstr Surg* (2010) 126(2):460–70. doi:10.1097/PRS.0b013e3181de2260

**Conflict of Interest Statement:** The authors declare that the research was conducted in the absence of any commercial or financial relationships that could be construed as a potential conflict of interest.

Copyright © 2015 Goertz, von der Lohe, Martinez-Olivera, Daigeler, Harati, Hirsch, Lehnhardt and Kolbenschlager. This is an open-access article distributed under the terms of the Creative Commons Attribution License (CC BY). The use, distribution or reproduction in other forums is permitted, provided the original author(s) or licensor are credited and that the original publication in this journal is cited, in accordance with accepted academic practice. No use, distribution or reproduction is permitted which does not comply with these terms.



# Breast Reconstruction after Mastectomy

Daniel Schmauss<sup>1</sup>, Hans-Günther Machens<sup>1</sup> and Yves Harder<sup>1,2\*</sup>

<sup>1</sup>Department of Plastic Surgery and Hand Surgery, Klinikum rechts der Isar, Technische Universität München, Munich, Germany, <sup>2</sup>Department of Plastic, Reconstructive and Aesthetic Surgery, Ospedale Regionale di Lugano, Ente Ospedaliero Cantonale, Lugano, Switzerland

Breast cancer is the leading cause of cancer death in women worldwide. Its surgical approach has become less and less mutilating in the last decades. However, the overall number of breast reconstructions has significantly increased lately. Nowadays, breast reconstruction should be individualized at its best, first of all taking into consideration not only the oncological aspects of the tumor, neo-/adjuvant treatment, and genetic predisposition, but also its timing (immediate versus delayed breast reconstruction), as well as the patient's condition and wish. This article gives an overview over the various possibilities of breast reconstruction, including implant- and expander-based reconstruction, flap-based reconstruction (vascularized autologous tissue), the combination of implant and flap, reconstruction using non-vascularized autologous fat, as well as refinement surgery after breast reconstruction.

**Keywords:** breast reconstruction, breast cancer, mastectomy, DIEP flap, breast implants, autologous fat grafting

## OPEN ACCESS

### Edited by:

Adrien Daigeler,  
BG-University Hospital  
Bergmannsheil, Germany

### Reviewed by:

Andreas Arkudas,  
University Hospital of Erlangen,  
Germany  
Marcus Lehnhardt,  
BG-University Hospital  
Bergmannsheil, Germany

### \*Correspondence:

Yves Harder  
yves.harder@eoc.ch

### Specialty section:

This article was submitted  
to Surgical Oncology,  
a section of the journal  
Frontiers in Surgery

**Received:** 31 July 2015

**Accepted:** 18 December 2015

**Published:** 19 January 2016

### Citation:

Schmauss D, Machens H-G and  
Harder Y (2016) Breast  
Reconstruction after Mastectomy.  
Front. Surg. 2:71.  
doi: 10.3389/fsurg.2015.00071

## INTRODUCTION

Breast cancer is the leading cause of cancer death among women worldwide with ~1.7 million new diagnoses and 521,900 deaths in 2012 (1). One important modality of breast cancer therapy is surgical treatment, which has become increasingly less mutilating over the last century.

William Halsted introduced radical mastectomy including resection of the breast and its underlying pectoralis major muscle in order to cure all stages of breast cancer at the end of the nineteenth century (2). Approximately 40 years later, Patey described a less radical modified type of mastectomy with preservation of the pectoralis major muscle yielding comparable local control and overall survival compared to Halsted (3). In 1985, Fisher et al. introduced the concept of breast conserving therapy (BCT), demonstrating that lumpectomy – by that time regarded as segmental mastectomy – followed by adjuvant radiotherapy of the remnant breast in patients with stage I and II breast cancer was indeed associated with an increased local recurrence rate, yet resulted in equal survival rates compared to mastectomy (4). Oncoplastic breast surgery, i.e., reshaping of the breast after local tumor resection, has shown to allow larger tumor excision, yet conserving large parts of the breast, maintaining shape (5) and resulting in improved quality of life and self-esteem (6). While surgical breast cancer treatment decreased in radicalness and invasiveness, breast cancer guidelines were defined, breast cancer screening programs were initiated, and breast centers offering an interdisciplinary and comprehensive therapeutical approach for breast cancer were established. This resulted in an increased detection and treatment of predominantly early breast cancers with improved survival rates and consequently superior esthetic outcome. Nowadays, BCT is a safe treatment for most women with early-stage breast cancers and can be safely applied in 70–80% of the cases requiring surgical tumor removal (7). Though, the primary goal of BCT is to preserve shape



and, to a lesser extent, size of the breast in order to best match the contralateral breast. Thereby, one should take into account that postoperative radiotherapy may result in some extent of tissue shrinkage (8). Although decreasing in number over the last two decades, the rate of mastectomy has again increased lately due to the detection of multifocal tumors, tumors with an extended *in situ* proportion that is difficult to delimit and due to an unfavorable breast-to-tumor size ratio in rather thin patients with small-to-intermediate sized breasts. Furthermore, the awareness of the disease itself in the female population and the relatively frequent detection of a genetic predisposition to breast cancer (i.e., BRCA-1, BRCA-2, p53) have confirmed this trend toward an increased rate of mastectomy, be it curative or prophylactic (9).

Although BCT remains the absolute gold standard for surgical breast cancer treatment, many women must or wish to undergo mastectomy. Consequently, reconstruction of the breast must be offered, particularly in young patients. This article provides an overview of various reconstruction techniques of the female breast after both, breast cancer-related and prophylactic mastectomy. This article does not cover partial breast reconstruction after extensive breast conservative therapy.

## MASTECTOMY

Mastectomy aims at resecting as much breast tissue as possible, knowing that glandular tissue will almost always remain in the region of the inframammary fold (10). Nowadays, basically two ways of mastectomy are performed, including skin-sparing mastectomy and total ablation of the breast. The latter consists of complete removal of both, breast skin and glandular breast tissue (**Figure 1**), whereas skin-sparing mastectomy preserves as much of the breast's skin envelope as possible, including the areola and the nipple (skin-sparing mastectomy, areola-sparing mastectomy, nipple-sparing mastectomy, skin-reducing mastectomy) and the inframammary fold. Furthermore, biopsy scars and skin overlying a tumor or even infiltrated by the tumor are excised in order to reduce the risk of local recurrence (11). Provided that the oncological indication is correct, skin-sparing mastectomy has been associated with equal oncological local

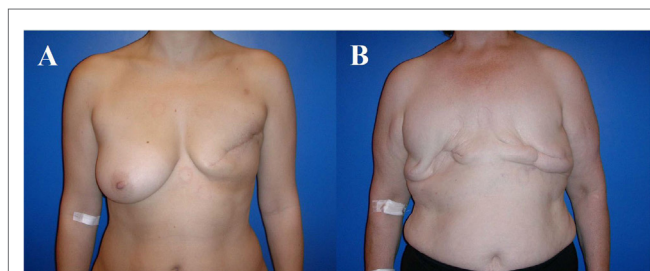
safety and improved esthetic outcome compared to modified radical mastectomy (10). Furthermore, the need for secondary surgery to adjust the contralateral breast in order to achieve symmetry is reduced after skin-sparing mastectomy, particularly if autologous reconstruction with flaps is used (12).

Lately, prophylactic bilateral mastectomy has to be offered more and more frequently due to the increased detection of patients carrying a genetic mutation or predisposition to develop breast cancer (e.g., BRCA-1, BRCA-2, p53). Understandably, these women have high demands to the esthetic outcome that can be overcome with nipple-sparing mastectomy being accepted as the gold standard in patients with prophylactic mastectomies (13).

Noteworthy, skin- and nipple-sparing mastectomies are associated with a high rate of ischemia-related wound breakdown and necrosis of up to 54%, which is a consequence of a critically impaired blood supply of the distant areas of the often very thin skin flap. Meanwhile, various approaches have been described to decrease ischemia-associated complications of the mastectomy skin flap, including surgical skin reduction of the mastectomy flap, temporary insertion of an expandable implant, and local application of vasodilators. Interestingly, first clinical data have shown that local heat preconditioning was able to safely and significantly reduce ischemia-related mastectomy skin flap complications in patients with skin-sparing mastectomy and immediate breast reconstruction (14).

## RECONSTRUCTION TECHNIQUES OF THE BREAST

Breast reconstruction depends primarily on the type of mastectomy and may be classified in various ways, such as reconstruction type and reconstruction time point. The latter includes delayed breast reconstruction (DBR; secondary breast reconstruction) and immediate breast reconstruction during the same surgery (IBR; primary breast reconstruction). IBR has the advantage of reducing the total number of surgical procedures. Since breast reconstruction *per se* represents an additional procedure to mastectomy, the potential surgery-related complications of both mastectomy and reconstruction accumulate due to prolonged surgery time, particularly if mastectomy is performed using a skin reducing or skin-sparing approach (hematoma due to bleeding of the mastectomy flap, ischemic complications of the mastectomy flap, infection, etc.), respectively, reconstruction is performed with implants. This has to be taken into consideration in order not to postpone adjuvant therapy, i.e., foremost chemotherapy, to the disadvantage of the patient (15). Despite very effective diagnostic work-up of breast cancer and highly standardized neo- and adjuvant treatment regimes, IBR bears the risk that unforeseen adjuvant radiotherapy may compromise the final result of the reconstructed breast, such as capsular contracture in implant-based reconstructions, respectively flap shrinkage in autologous reconstructions. Therefore, many surgeons may tend to a DBR when using free (microvascular) flaps in cases of an invasive tumor requiring adjuvant radiotherapy. In order not to lose the skin envelope after skin-sparing mastectomy, one can place a spacer until completion of adjuvant



**FIGURE 1 |** The 43- and 63-year-old patients after modified radical mastectomy of the left breast (A), respectively, of both breasts (B). Indication for autologous reconstruction with a microvascular flap, particularly if skin and fat excess is available and adjuvant radiotherapy has been performed.

therapy. Nonetheless, IBR is advantageously associated with a reduced recovery time, a better esthetic outcome, an improved quality of life, and, finally, lower surgery- and recovery-related costs (16–18).

Nowadays, the seek for bilateral prophylactic mastectomy particularly in women with a genetic predisposition for breast cancer (e.g. BRCA-1, BRCA-2, p53) increases and accordingly represents an ideal indication for IBR of any type, knowing that neither adjuvant chemotherapy nor adjuvant radiotherapy will be required (19).

Generally, three different approaches of breast reconstruction may be considered: (1) breast reconstruction using implants and skin expanders, (2) breast reconstruction using flaps (vascularized autologous tissue), and (3) breast reconstruction using non-vascularized lipoaspirate autologous fat. In the following, the different approaches will be briefly highlighted, including the advantages and disadvantages of each approach.

## Breast Reconstruction Using Implants and Skin Expanders

The use of implants and skin expanders is not only the oldest way to reconstruct a breast but also the quickest and presumably easiest method of breast reconstruction. Accordingly, implant-based breast reconstruction is by far the most often used technique worldwide (9, 20). The prerequisite for implant-based breast reconstruction is an adequate skin envelope that allows covering the implant that is usually introduced in a submuscular plane detaching the medial insertions of the pectoralis major muscle from the ribs.

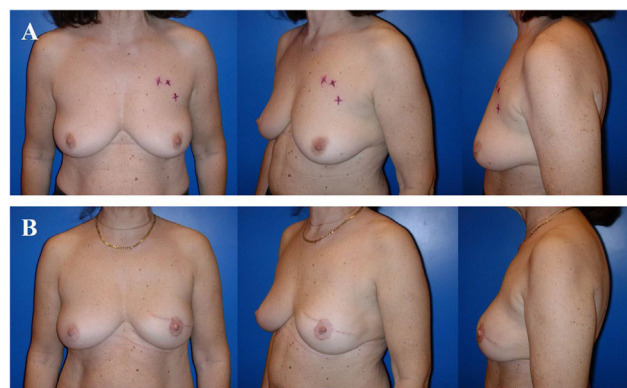
### Implant-Based Breast Reconstruction

Basically, the first “implant”-based breast reconstruction was performed 1895 by Vincenz Czerny, who used a patient’s lipoma from the lumbar region to reconstruct a post-surgical asymmetry after tumor removal (21).

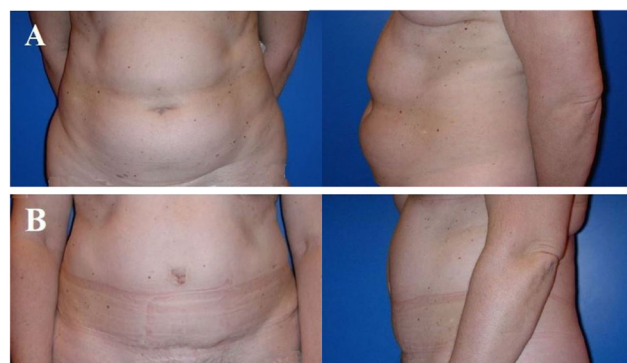Cronin and Gerow fathered the modern era of silicone gel-filled breast implants and so allowed DBR (22, 23). Nowadays, fifth generation silicone gel-filled breast implants that contain a highly viscous and more or less form-stable gel are usually used. The implants are available in both, round and anatomical shape and vary in width, height, and projection (profile). Implant-based breast reconstruction is used in women who do not want any additional scars (flap harvesting) (Figure 2) or do not have any adequate flap donor site (e.g., lean patient, pre-existing scars, and medical conditions).

Implant-based breast reconstructions prone to develop implant-related local complications during the subsequent 10 years with a risk for a reoperation of 70% (24). Approximately 25 and 35% of the patients are being diagnosed with severe capsular contracture and, respectively, implant rupture (25). This high complication rate results from the thin skin envelope remaining after mastectomy, which does not provide any robust coverage of the implant. This complication rate does neither consider breast shape deformity and asymmetry in the context of mild to moderate capsular contracture nor does it consider an even worse outcome in implant-based breast reconstruction with irradiated

skin. *De facto*, breast reconstruction using implants may yield very nice long-term results that suffice many patients, yet the implant will always remain more or less fixed to the thoracic wall and consequently the breast maintains a unique shape, independently from the patient’s posture. Finally, implant-based breast reconstruction will not allow recreating a naturally shaped ptotic breast in most patients, and therefore often requires adaptive surgery of the contralateral breast to achieve symmetry. Though, implant-based breast reconstruction prevents from “collateral damage,” such as scars, contour deformity, and muscular weakness, as it might be seen after flap harvesting for flap-based breast reconstruction (Figure 3).



**FIGURE 2 | A 58-year-old patient before skin-sparing mastectomy for multifocal cancer of the left breast (A).** Four years after primary reconstruction of the left breast using an implant in a subpectoral plane to cover the upper half of the implant and a resorbable mesh to prevent cranialization of the partially detached pectoralis major muscle, as well as reconstruction of the nipple-areolar complex (star flap for the nipple and tattoo of the nipple and neo-areola). Note the almost symmetric size and contour of both breasts (B).



**FIGURE 3 | Typical donor site for abdominal flap-based breast reconstruction.** A 57-year-old patient before (A) and 4 years after (B) harvesting a microvascular deep inferior epigastric perforator (DIEP) artery flap from the abdominal region. Note the adipocutaneous excess cranially and distally of the umbilicus, the almost invisible scar at the umbilicus and the suprapubic region, as well as the significantly improved abdominal contour [profile view (A,B)]. The reconstructed breast of this patient is shown in Figure 6.

## Expander-Based Breast Reconstruction

The technique of tissue expansion has first been described by Radovan in 1976, and since then, it has been used on a regular base in order to recreate the amount of lost skin after mastectomy through stepwise expansion of the remaining chest skin (26). Ideally, the contralateral breast volume should not exceed a volume of 300–400 g. Typically, patients with pre-expansion of the breast skin undergo secondary breast reconstruction with implants. In selected cases, especially in young and skinny patients with insufficient skin laxity, yet enough adipose tissue to reconstruct a breast mound of ~300–350 g, one might pre-expand the breast skin after mastectomy in order to substitute the expander with an autologous flap.

The main drawback of skin expansion are the frequent outpatient visits to gradually fill the expander, the need for an additional procedure (i.e., expander removal for permanent implant or flap) and the relatively high rate of complications, such as infection, capsular contracture, and skin perforation (27).

Alternatively, skin expanders can be used as “spacers” after skin-sparing mastectomy in order not to lose the skin pocket. This approach is particularly helpful in patients who are sure to get adjuvant radiotherapy of the skin and/or the thoracic wall. Indeed, postoperative radiotherapy will not significantly increase the rate of flap-related complications (28). Yet, IBR is more and more frequently performed using microvascular (free) flaps despite postoperative radiotherapy. However, we currently do not know at what extent the flap will indurate and shrink at long-term follow-up.

## Breast Reconstruction with Acellular Dermis

The use of acellular dermal matrices in implant- and expander-based breast reconstruction has lately become more and more popular. Matrices are usually of human, porcine, or bovine origin. They have shown to improve esthetic outcome and reduce implant-related morbidity (29), such as a decreased rate of capsular contracture (30–32), an improved tolerance to radiotherapy, and a more natural anatomical reconstruction of the inframammary fold and final breast contour (33).

Nahabedian demonstrated a high safety and excellent results using acellular dermis in a 12-year follow-up, even in the setting of reconstruction after infection or radiotherapy. However, other authors reported several matrix-related complications, such as hematoma, infection, and foremost late seromas (29). The use of matrices is again and again associated with a rather high rate of early complications. Lardi et al. have demonstrated that these complications were mostly related to patient characteristics and a learning curve, highlighting the importance of patient selection and technical principles (34).

## Breast Reconstruction Using Flaps (Vascularized Autologous Tissue)

The myocutaneous flaps that are being used for breast reconstruction have a long history, although the techniques of today are much more sophisticated than those of the past. Louis Ombredanne from France was the first to use a pedicled pectoralis muscle flap for IBR in 1906. Differently as his colleagues, Ombredanne was the first who wittingly tried to reconstruct not only the skin defect

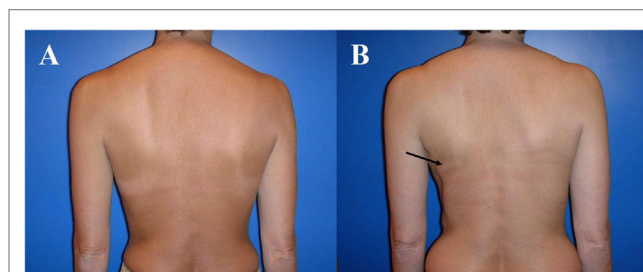
after mastectomy but also the breast mound that was considered at that time a “luxury” procedure with limited indications (35). Almost simultaneously, Tanzani from Italy used the pedicled myocutaneous latissimus dorsi flap to close mastectomy defects for the first time.

Flap surgery for breast reconstruction has been performed on a regular base, since the mid 70s, initially using both, tubed flaps from the abdomen (36) and thoraco-epigastric, necessitating several surgical stages (23). The initial attempts were still not able to really reconstruct the breast mound and therefore primarily aimed at resurfacing the thoracic wall's defects after radical mastectomy. Finally, it was the introduction of the myocutaneous latissimus dorsi flap with its overlying skin island, as described by Tanzani 70 years earlier, which allowed to restore mastectomy-induced skin loss and to a lesser extent also volume loss (37–39).

Almost at the same time, Bostwick described the combined use of the myocutaneous latissimus dorsi flap and a silicone implant to consistently provide adequate skin coverage, respectively, to restore the breast mound in postmastectomy reconstruction (40).

The advantage of the latissimus dorsi flap is its rather consistent anatomy and therefore easy flap harvest. However, flap transfer from the back can be associated with highly visible scars, contour deformity of the thorax ventrally and the back dorsally as well as animation of the skin/muscle-implant complex of the pectoralis major respectively latissimus dorsi muscle due to innervation of the latter one (Figure 4). Otherwise, the muscle undergoes atrophy of 50–75% of its volume unconditionally, almost always requiring an implant to restore volume, unless the patient is rather thin (Figure 5).

Since this reconstructive approach combines two basic techniques of reconstructive surgery, i.e., skin replacement with the flap and volume restoration with the implant, the patients are subject to an accumulation of the two technique's morbidities, which might be significant, particularly years after reconstruction. Tarantino et al. demonstrated that 57% of the patients treated with a latissimus dorsi flap and implants had revisional surgery for implant replacement or implant removal after a mean follow-up of 10 years, and concluded that the indication for this



**FIGURE 4 | Typical donor site for myocutaneous latissimus dorsi flap-based breast reconstruction.** A 36-year-old patient before (A) and 2 years after secondary reconstruction of the left breast using a pedicled myocutaneous latissimus dorsi flap (B). The skin island is harvested along the posterior axillary line. Note the well concealed scar (usually in the bra-line) that does not interfere with the back of the patient, yet skin and muscle harvesting result in a slight contour deformity of the periscapular region [arrow; (B)]. The reconstructed breast of this patient is shown in Figure 5.



procedure should be restricted to patients who do not qualify for either implant-based or flap-based breast reconstruction (41).

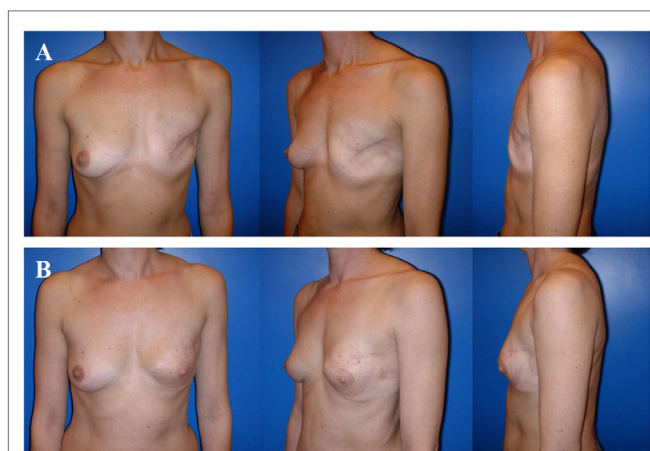
In 1987, Hokin and Silfverskiöld described the use of an extended latissimus dorsi flap to avoid the use of an implant. The flap's volume was significantly increased by dissecting the subcutaneous fat surrounding the skin island (42). Unfortunately, donor site morbidity increased dramatically, including prolonged seroma respectively wound dehiscence rate, and contour deformity (43).

The true progress in flap-based breast reconstruction occurred in 1982 when Hartrampf and colleagues used the cranially pedicled rectus abdominis muscle flap with a horizontally oriented adipocutaneous skin island (TRAM flap) supplied by the deep superior epigastric artery to anatomically reconstruct volume and shape of the breast in one single stage without using implants (44).

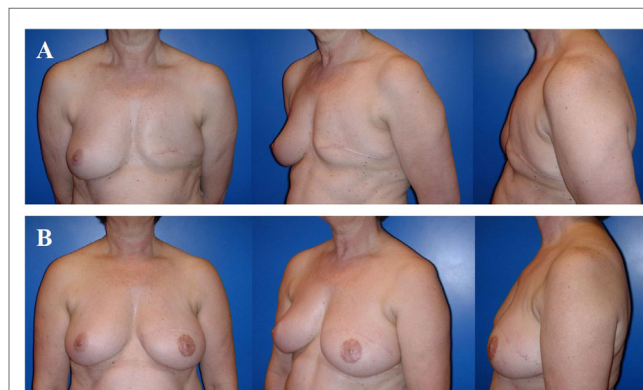
Although this procedure was able to both, restore the ablated breast and improve abdominal contour despite scars at the umbilicus and the waistline, following significant disadvantages have to be taken into consideration: a high tissue-to-blood supply ratio of the flap, protracted recovery of the patient and abdominal wall weakness, including bulging and herniation due to sacrifice of the rectus abdominis muscle and large part of its anterior fascia.

To overcome these drawbacks of the donor site of the pedicled TRAM flap, Arnez and colleagues and Grotting et al. popularized the free TRAM flap, i.e., the microvascular anastomosis of at least one artery and one vein of the flap to recipient vessels. In doing so, the authors were able to demonstrate a more limited harvest of the rectus abdominis muscle, a safer transfer due to improved perfusion originating from the larger caudal pedicle (deep inferior epigastric artery instead of deep superior epigastric artery), and an improved medial breast contour due to the lack of tunneling of the flap's cranial pedicle (45, 46). Further refinement of the surgical technique over time aimed at decreasing as much

as possible the weakening of the abdominal wall despite transferring most of the abdominal skin and its underlying subcutaneous tissue, including muscle sparing free TRAM flap (47), fascia sparing free TRAM flap (48), to finally achieve complete muscle preservation. The latter was obtained by dissecting the vascular pedicle of the adipocutaneous abdominal flap perforating the rectus abdominis muscle (deep inferior epigastric perforator (DIEP) artery flap) as described by Allen and Treece (49) and Blondeel and Boeckx (50) (**Figure 6**). The concept of this so-called "perforator flap" or DIEP flap has somehow revolutionized breast reconstruction by maximizing the amount of safe tissue transfer, yet minimizing donor site morbidity. Abdominal tissue is very suitable for breast reconstruction, since many patients have a certain abdominal excess of skin and fat. Consequently, autologous breast reconstruction using a DIEP flap nowadays represents the gold standard. In case of concomitant chronic lymphedema of the arm after sentinel lymph node biopsy, axillary lymph node dissection and or/radiotherapy of the lymph node basins, one can surgically address this problem using lymphaticovenous anastomosis or microvascular lymph node transfer. The latter can easily be combined with a DIEP flap, since the flap mostly consists of the lymph nodes in the groin area lateral to the femoral vessels and depends on the pedicle originating from the superficial inferior epigastric vessels (51). Given that not every woman is suitable for breast reconstruction using abdominal skin and fat, many more donor sites were described in the following years, aiming at harvesting the most suitable microvascular flap to best personalize breast reconstruction. This included, among others, the superior gluteal artery perforator (sGAP) flap (52), the inferior gluteal artery perforator (iGAP) flap (53) from the gluteal region, the fasciocutaneous infragluteal (FCI) flap (54), the profunda femoral artery perforator (PAP) flap (55) from the infragluteal region, and the transverse myocutaneous gracilis (TMG) flap from the inner thigh region (56).



**FIGURE 5 | A 36-year-old patient 3 years after modified radical mastectomy of the left breast and adjuvant radio-chemotherapy.** Note the oblique scar and rather large skin envelope in a thin patient (**A**). Two years after secondary reconstruction of the left breast using a pedicled myocutaneous latissimus dorsi flap without implant and reconstruction of the nipple-areolar complex (star flap for the nipple and tattoo of the nipple and neo-areola). Note the almost symmetric neckline and the slight volume loss of the lower pole of the breast resulting in contour deformity (**B**). The donor site of this patient is shown in **Figure 4**.



**FIGURE 6 | A 57-year-old patient 2 years after modified radical mastectomy of the left breast and adjuvant radio-chemotherapy.** Note the lack of skin and volume (**A**). Four years after secondary reconstruction of the left breast using a microvascular deep inferior epigastric perforator (DIEP) artery flap from the abdominal region and reconstruction of the nipple-areolar complex (star flap for the nipple and tattoo of the nipple and neo-areola). Note the almost symmetric size and contour of both breasts without corrective surgery of the non operated contralateral breast (**B**). The donor site of this patient is shown in **Figure 3**.

Nowadays, the internal mammary artery and its concomitant vein are predominantly used as the recipient vessels. Alternatively, the arterial branches originating from the subscapular artery (e.g., thoracodorsal artery, circumflex scapulae artery) or sternal perforators arising through the pectoral muscle are used.

Although breast reconstruction using autologous flap tissue allows a natural and durable result, flap harvest will cause a “collateral damage” at the flap’s donor site, including potential surgery-related complications, scars, contour deformity, and functional impairment. Furthermore, microvascular flap-based breast reconstruction is not only technically more demanding, but also requires more infrastructures within a breast reconstruction unit, as compared to implant-based breast reconstruction (Table 1).

## Fat Graft-Based Breast Reconstruction Using Non-Vascularized Lipoaspirate Fat

Autologous fat grafting (AFG; lipografting, lipofilling) describes the harvesting of the patient’s fat using liposuction followed by its reinjection into the tissue to be corrected or augmented. Fat grafting to the breast is more than 100 years old since Holländer corrected a retracted scar after mastectomy by injecting parceled fat into the scar (57). AFG to the breast has become a popular tool over the last 20 years, both in esthetic and reconstructive surgery. Regarding the breast, AFG has proven to be particularly effective to correct post-surgical irregularities, such as contour deformities and volume asymmetries after BCT, “rippling” after implant-based reconstruction and improvement of the transition zone between flap and skin in the neckline (58–60), as well as the preparation of the postmastectomy irradiated chest wall prior to implant placement (61). In selected cases, *de novo* reconstruction of the breast by means of AFG has shown very promising results. The patient must have several donor sites equipped with fat, because the reconstructive procedure usually takes four to six stages of fat grafting, each separated by 3 months at least (62). Irradiated skin does almost preclude this approach, since injected fat is not engrafted as desired (63).

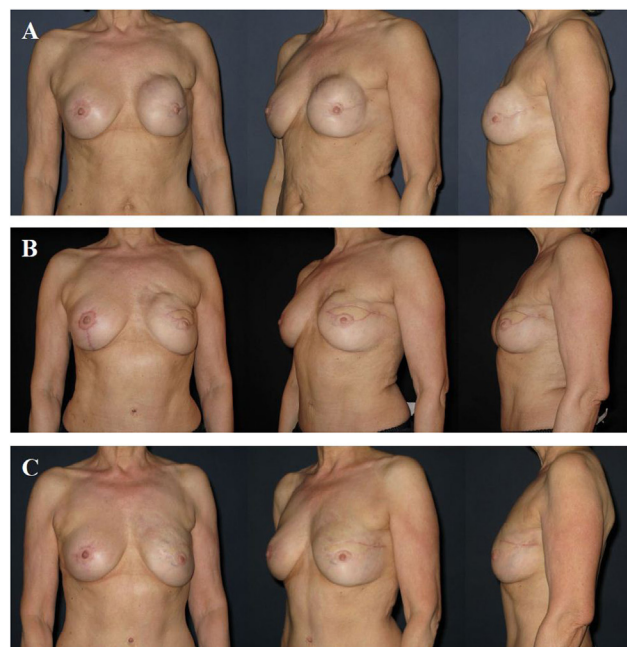
**TABLE 1 | Advantages and disadvantages of implant-based versus autologous tissue-based techniques of breast reconstruction.**

	Implant-based breast reconstruction	Autologous tissue-based breast reconstruction
Duration of surgery (h)	1–2	4–6
Infrastructural effort	Low	High <sup>a</sup>
Surgical complexity	Low	High
Donor site	None	Depending on flap <sup>b</sup> (abdominal, thigh, gluteal, dorsal region)
Complication rate (30 days) (implant-, respectively, flap-related) (%)	2–4	2–4
Complication rate (long-term)	Higher (due to capsular contracture)	Lower
Long-term reoperation rate	More likely	Less likely
Patient satisfaction	Short-term	Long-term

<sup>a</sup>Microscope, specific instruments, trained personnel (nurses in OR).

<sup>b</sup>Discomfort, pain, scars, abdominal bulging, hernia, asymmetry, and contour deformity.

Autologous fat grafting is a “natural” filler, and unlike synthetic fillers will neither induce any foreign body reaction nor be resorbed completely. Today, harvesting of the fat is discussed, among others, with regard to composition of the infiltration solution, to diameter and shape of the harvesting cannula and to suction forces. In order to be structural, injection of the fat should be performed in small aliquots using blunt cannulas in multiple directions and multiple layers. This multi-planar approach maximizes the fat-to-tissue contact, thereby the exposition of non-vascularized fat to vascularized host tissue (64). Consensus exists on the fact that fat may not be injected into the glandular tissue of the breast. Commonly, 60–70% of the injected fat is engrafted to the host tissue. Fat necrosis and oil cysts are common complications after AFG and occur in ~5% (65). Unfortunately, necrosis of the grafted fat might also be associated with microcalcifications, which sometimes may be difficult to distinguish from malignant breast cancer-associated microcalcifications (66). Presumably, the radiologist is an expert, fat grafting-induced microcalcifications do no impact on the radiological follow-up (67). Yet, this fact may unsettle the patient who has to appear for regular follow-up imaging and eventually undergo diagnostic biopsy to exclude malignancy.



**FIGURE 7 | A 58-year-old patient 2 years after modified radical mastectomy of the left breast, adjuvant radio-chemotherapy, and secondary expander-implant-based reconstruction.** The patient developed a capsular contracture Baker grade IV with a hard, deformed, and painful breast fixed to the thoracic wall (A). One year after implant removal, radical capsulectomy and secondary reconstruction of the left breast using a microvascular deep inferior epigastric perforator (DIEP) artery flap from the abdominal region. Note the contour deformity in the neckline and upper pole region of the breast resulting from partial fat necrosis of the flap (B). Approximately 1.5 years after refinement of the contour deformity using two sessions of autologous fat grafting. Note the almost symmetric size and contour of both breasts (C).



Currently, fat grafting to the breast is controversially discussed, particularly in the presence of remaining glandular breast tissue, as, for example, after BCT. Grafted fat that naturally contains progenitor and stem cells has lately been associated with breast cancer progression and metastatic spread in an experimental setting (68, 69). Despite the lack of prospective follow-up studies, fat grafting to reconstruct or to refine a breast after mastectomy and/or after breast reconstruction – BCT not included – is nowadays considered safe (70–72).

## REFINEMENT SURGERY AFTER BREAST RECONSTRUCTION

After breast reconstruction, particularly if breast reconstruction is performed unilaterally, refinement surgery may be necessary to reach symmetry of the breasts with regard to shape, contour, and size. The procedures usually consist of mastopexy, breast reduction, or breast augmentation using implants. Nowadays, AFG is often used to correct small volume asymmetries and contour deformities. The latter may occur after implant-based breast reconstruction (e.g., “rippling”), as well as after flap-based breast reconstruction (e.g., partial fat necrosis of the flap, transition zone between flap and neckline cranially). Refinement surgery is usually offered not earlier than 3 months after reconstruction or 6 months after completion of adjuvant radiotherapy. Fat grafting has often to be repeated. Its engraftment rate is ~60% (~40% fat resorption) (Figure 7). Last but not least, mastectomy is associated with the loss of the nipple–areolar complex (except for nipple-sparing mastectomy), requiring its reconstruction. Many techniques of reconstruction are available, including local flaps of the adjacent skin, skin grafts, tattoo, and a combination of all techniques.

## CONCLUSION

Breast cancer is the leading cause of cancer death in women. Its surgical approach has become less and less mutilating, allowing for 70–80% of the operated cases to undergo (BCT) that has proven to

be as safe as mastectomy with regard to overall survival. In other words, 20–30% of the operated women are subjected to mastectomy. Since ~25 years, the skin-sparing mastectomy approach is an alternative to ablation of the breast allowing for better esthetic results due to preservation of the breast's skin envelope, yet from an oncological point of view as safe as mastectomy. Other than mastectomy, skin-sparing mastectomy needs immediate reconstruction in order not to lose the skin envelope that unreconstructed will inevitably retract and shrink to the level of the thoracic wall. Nowadays, breast reconstruction should be personalized at its best, first of all taking into consideration not only the oncological aspects of the tumor, neo-/adjuvant treatment and genetic predisposition, but also its timing (IBR versus DBR), as well as the patient's condition and wish. Despite this complex decision-making including many aspects, the overall number of breast reconstruction has lately considerably increased. Breast reconstruction itself can basically be classified into three categories, including (1) implant- and expander-based breast reconstruction, (2) flap-based breast reconstruction (vascularized autologous tissue), a combination of both (flap and implant), and (3) breast reconstruction using fat grafting (non-vascularized autologous lipoaspirate fat). However, fat grafting is predominantly used to refine post-reconstructive asymmetries. Nowadays, it is of importance that every woman having a high risk constellation (family history), being diagnosed with a genetic mutation and/or being affected with breast cancer gets the possibility to be presented to a multidisciplinary board of a certified breast center prior to surgery in order to be informed about all treatment modalities, including the various modalities of breast reconstruction. The goal of this multidisciplinary board is to best personalize breast reconstruction, of course putting to the fore the adequate oncological treatment. The patients also need to know the advantages and disadvantages of any reconstructive option, including the presumably less complex implant-based techniques that may result in high temporary satisfaction without any donor site morbidity and likelihood of reoperation due to capsular contracture and the clearly more complex flap-based techniques that will yield in high long-term satisfaction with the risk of donor site-associated complications.

## REFERENCES

- Torre LA, Bray F, Siegel RL, Ferlay J, Lortet-Tieulent J, Jemal A. Global cancer statistics, 2012. *CA Cancer J Clin* (2015) **65**(2):87–108. doi:10.3322/caac.21262
- Sakorafas GH, Safioleas M. Breast cancer surgery: an historical narrative. Part II. 18th and 19th centuries. *Eur J Cancer Care (Engl)* (2010) **19**(1):6–29. doi:10.1111/j.1365-2354.2008.01060.x
- Patey DH. A review of 146 cases of carcinoma of the breast operated on between 1930 and 1943. *Br J Cancer* (1967) **21**(2):260–9. doi:10.1038/bjc.1967.28
- Fisher B, Bauer M, Margolese R, Poisson R, Pilch Y, Redmond C, et al. Five-year results of a randomized clinical trial comparing total mastectomy and segmental mastectomy with or without radiation in the treatment of breast cancer. *N Engl J Med* (1985) **312**(11):665–73. doi:10.1056/NEJM198503143121102
- Malhaire C, Hequet D, Falcou MC, Feron JG, Tardivon A, Leduey A, et al. Outcome of oncoplastic breast-conserving surgery following bracketing wire localization for large breast cancer. *Breast* (2015) **24**(4):370–5. doi:10.1016/j.breast.2015.02.037
- Veiga DF, Veiga-Filho J, Ribeiro LM, Archangelo I Jr, Balbino PF, Caetano LV, et al. Quality-of-life and self-esteem outcomes after oncoplastic breast-conserving surgery. *Plast Reconstr Surg* (2010) **125**(3):811–7. doi:10.1097/PRS.0b013e3181ccdac5
- Early Breast Cancer Trialists' Collaborative Group (EBCTCG), Darby S, McGale P, Correa C, Taylor C, Arriagada R, et al. Effect of radiotherapy after breast-conserving surgery on 10-year recurrence and 15-year breast cancer death: meta-analysis of individual patient data for 10,801 women in 17 randomised trials. *Lancet* (2011) **378**(9804):1707–16. doi:10.1016/S0140-6736(11)61629-2
- Haviland JS, Owen JR, Dewar JA, Agrawal RK, Barrett J, Barrett-Lee PJ, et al. The UK Standardisation of Breast Radiotherapy (START) trials of radiotherapy hypofractionation for treatment of early breast cancer: 10-year follow-up results of two randomised controlled trials. *Lancet Oncol* (2013) **14**(11):1086–94. doi:10.1016/S1470-2045(13)70386-3
- Albornoz CR, Bach PB, Mehrara BJ, Disa JJ, Pusic AL, McCarthy CM, et al. A paradigm shift in U.S. breast reconstruction: increasing implant rates. *Plast Reconstr Surg* (2013) **131**(1):15–23. doi:10.1097/PRS.0b013e3182729cde
- Barton FE Jr, English JM, Kingsley WB, Fietz M. Glandular excision in total glandular mastectomy and modified radical mastectomy: a comparison. *Plast Reconstr Surg* (1991) **88**(3):389–92; discussion 393–4. doi:10.1097/00006534-199109000-00001
- Singleton SE, Robb GL. Oncologic safety of skin-sparing mastectomy. *Ann Surg Oncol* (2003) **10**(2):95–7. doi:10.1245/ASO.2003.01.910
- Simmons RM, Adamovich TL. Skin-sparing mastectomy. *Surg Clin North Am* (2003) **83**(4):885–99. doi:10.1016/S0039-6109(03)00035-5

13. Hartmann LC, Schaid DJ, Woods JE, Crotty TP, Myers JL, Arnold PG, et al. Efficacy of bilateral prophylactic mastectomy in women with a family history of breast cancer. *N Engl J Med* (1999) **340**(2):77–84. doi:10.1056/NEJM199901143400201
14. Mehta S, Rolph R, Cornelius V, Harder Y, Farhadi J. Local heat preconditioning in skin sparing mastectomy: a pilot study. *J Plast Reconstr Aesthet Surg* (2013) **66**(12):1676–82. doi:10.1016/j.bjps.2013.07.034
15. Johnson A. The timing of treatment in breast cancer: gaps and delays in treatment can be harmful. *Breast Cancer Res Treat* (2000) **60**(3):201–9. doi:10.1023/A:1006441018271
16. Joslyn SA. Patterns of care for immediate and early delayed breast reconstruction following mastectomy. *Plast Reconstr Surg* (2005) **115**(5):1289–96. doi:10.1097/01.PRS.0000156974.69184.5E
17. Neyt MJ, Blondeel PN, Morrison CM, Albrecht JA. Comparing the cost of delayed and immediate autologous breast reconstruction in Belgium. *Br J Plast Surg* (2005) **58**(4):493–7. doi:10.1016/j.bjps.2004.12.002
18. Yang X, Zhu C, Gu Y. The prognosis of breast cancer patients after mastectomy and immediate breast reconstruction: a meta-analysis. *PLoS One* (2015) **10**(5):e0125655. doi:10.1371/journal.pone.0125655
19. Gurunluoglu R, Gurunluoglu A, Williams SA, Tebockhorst S. Current trends in breast reconstruction: survey of American Society of Plastic Surgeons 2010. *Ann Plast Surg* (2013) **70**(1):103–10. doi:10.1097/SAP.0b013e31822ed5ce
20. Kwok AC, Goodwin IA, Ying J, Agarwal JP. National trends and complication rates after bilateral mastectomy and immediate breast reconstruction from 2005 to 2012. *Am J Surg* (2015) **210**(3):512–6. doi:10.1016/j.amjsurg.2015.03.019
21. Champaneria MC, Wong WW, Hill ME, Gupta SC. The evolution of breast reconstruction: a historical perspective. *World J Surg* (2012) **36**(4):730–42. doi:10.1007/s00268-012-1450-2
22. Cronin TD, Greenberg RL. Our experiences with the silastic gel breast prosthesis. *Plast Reconstr Surg* (1970) **46**(1):1–7. doi:10.1097/00006534-197046010-00001
23. Cronin TD, Upton J, McDonough JM. Reconstruction of the breast after mastectomy. *Plast Reconstr Surg* (1977) **59**(1):1–14. doi:10.1097/00006534-197701000-00001
24. Gabriel SE, Woods JE, O'Fallon WM, Beard CM, Kurland LT, Melton LJ III. Complications leading to surgery after breast implantation. *N Engl J Med* (1997) **336**(10):677–82. doi:10.1056/NEJM199703063361001
25. Spear SL, Murphy DK; Allergan Silicone Breast Implant U.S. Core Clinical Study Group. Nattelle round silicone breast implants: core study results at 10 years. *Plast Reconstr Surg* (2014) **133**(6):1354–61. doi:10.1097/PRS.0000000000000021
26. Radovan C. Breast reconstruction after mastectomy using the temporary expander. *Plast Reconstr Surg* (1982) **69**(2):195–208. doi:10.1097/00006534-198202000-00001
27. Anker CJ, Hymas RV, Ahluwalia R, Kokeny KE, Avizonis V, Boucher KM, et al. The effect of radiation on complication rates and patient satisfaction in breast reconstruction using temporary tissue expanders and permanent implants. *Breast J* (2015) **21**(3):233–40. doi:10.1111/tbj.12395
28. Patel KM, Albino F, Fan KL, Liao E, Nahabedian MY. Microvascular autologous breast reconstruction in the context of radiation therapy: comparing two reconstructive algorithms. *Plast Reconstr Surg* (2013) **132**(2):251–7. doi:10.1097/PRS.0b013e31829586e2
29. Sbitany H, Serletti JM. Acellular dermis-assisted prosthetic breast reconstruction: a systematic and critical review of efficacy and associated morbidity. *Plast Reconstr Surg* (2011) **128**(6):1162–9. doi:10.1097/PRS.0b013e318230c29e
30. Spear SL, Howard MA, Boehmler JH, Ducic I, Low M, Abbruzzese MR. The infected or exposed breast implant: management and treatment strategies. *Plast Reconstr Surg* (2004) **113**:1634–44. doi:10.1097/01.PRS.0000117194.21748.02
31. Stump A, Holton LH III, Connor J, Harper JR, Slezak S, Silverman RP. The use of acellular dermal matrix to prevent capsule formation around implants in a primate model. *Plast Reconstr Surg* (2009) **124**:82–91. doi:10.1097/PRS.0b013e3181ab112d
32. Komorowska-Timek E, Oberg KC, Timek TA, Gridley DS, Miles DA. The effect of AlloDerm envelopes on periprosthetic capsule formation with and without radiation. *Plast Reconstr Surg* (2009) **123**:807–16. doi:10.1097/PRS.0b013e318199eef3
33. Spear SL, Pelletiere CV, Lockwood M. Immediate breast reconstruction with tissue expanders and AlloDerm. In: Spear SL, Wiley SC, Robb GL, Hammond DC, Nahabedian MY, editors. *Surgery of the Breast: Principles and Art*. Philadelphia, PA: Lippincott Williams & Wilkins (2006). p. 484–8.
34. Lardi AM, Ho-Asjoe M, Mohanna PN, Farhadi J. Immediate breast reconstruction with acellular dermal matrix: factors affecting outcome. *J Plast Reconstr Aesthet Surg* (2014) **67**(8):1098–105. doi:10.1016/j.bjps.2014.05.020
35. Teimourian B, Adham MN, Louis Ombredanne and the origin of muscle flap use for immediate breast mound reconstruction. *Plast Reconstr Surg* (1983) **72**(6):905–10. doi:10.1097/00006534-198312000-00037
36. Millard DR Jr. Breast reconstruction after a radical mastectomy. *Plast Reconstr Surg* (1976) **58**(3):283–91. doi:10.1097/00006534-197609000-00004
37. McCraw JB, Dibbell DG, Carraway JH. Clinical definition of independent myocutaneous vascular territories. *Plast Reconstr Surg* (1977) **60**(3):341–52. doi:10.1097/00006534-197706030-00003
38. Schneider WJ, Hill HL Jr, Brown RG. Latissimus dorsi myocutaneous flap for breast reconstruction. *Br J Plast Surg* (1977) **30**(4):277–81. doi:10.1016/0007-1226(77)90117-5
39. Olivari N. The latissimus flap. *Br J Plast Surg* (1976) **29**(2):126–8. doi:10.1016/0007-1226(76)90036-9
40. Bostwick J. Reconstruction of the breast. *Acta Chir Belg* (1980) **79**(2):125–9.
41. Tarantino I, Banic A, Fischer T. Evaluation of late results in breast reconstruction by latissimus dorsi flap and prosthesis implantation. *Plast Reconstr Surg* (2006) **117**(5):1387–94. doi:10.1097/01.prs.0000207396.22527.68
42. Hokin JA, Silfverskiold KL. Breast reconstruction without an implant: results and complications using an extended latissimus dorsi flap. *Plast Reconstr Surg* (1987) **79**(1):58–66. doi:10.1097/00006534-198701000-00010
43. Chang DW, Youssef A, Cha S, Reece GP. Autologous breast reconstruction with the extended latissimus dorsi flap. *Plast Reconstr Surg* (2002) **110**(3):751–9; discussion 760–1. doi:10.1097/00006534-200209010-00005
44. Hartrampf CR, Schefflan M, Black PW. Breast reconstruction with a transverse abdominal island flap. *Plast Reconstr Surg* (1982) **69**(2):216–25. doi:10.1097/00006534-198202000-00006
45. Arnez ZM, Smith RW, Eder E, Solinc M, Kersnic M. Breast reconstruction by the free lower transverse rectus abdominis musculocutaneous flap. *Br J Plast Surg* (1988) **41**(5):500–5. doi:10.1016/0007-1226(88)90007-0
46. Grotting JC, Urist MM, Maddox WA, Vasconez LO. Conventional TRAM flap versus free microsurgical TRAM flap for immediate breast reconstruction. *Plast Reconstr Surg* (1989) **83**(5):828–41; discussion 842–4. doi:10.1097/00006534-198905000-00009
47. Feller AM. Free TRAM. Results and abdominal wall function. *Clin Plast Surg* (1994) **21**(2):223–32.
48. Erni D, Harder YD. The dissection of the rectus abdominis myocutaneous flap with complete preservation of the anterior rectus sheath. *Br J Plast Surg* (2003) **56**(4):395–400. doi:10.1016/S0007-1226(03)00132-2
49. Allen RJ, Treece P. Deep inferior epigastric perforator flap for breast reconstruction. *Ann Plast Surg* (1994) **32**(1):32–8. doi:10.1097/00006537-199401000-00007
50. Blondeel PN, Boeckx WD. Refinements in free flap breast reconstruction: the free bilateral deep inferior epigastric perforator flap anastomosed to the internal mammary artery. *Br J Plast Surg* (1994) **47**(7):495–501. doi:10.1016/0007-1226(94)90033-7
51. Saaristo AM, Niemi TS, Viitanen TP, Tervala TV, Hartiala P, Suominen EA. Microvascular breast reconstruction and lymph node transfer for postmastectomy lymphedema patients. *Ann Surg* (2012) **255**(3):468–73. doi:10.1097/SLA.0b013e3182426757
52. Gurunluoglu R, Spanio S, Rainer C, Ninkovic M. Skin expansion before breast reconstruction with the superior gluteal artery perforator flap improves aesthetic outcome. *Ann Plast Surg* (2003) **50**(5):475–9. doi:10.1097/01.SAP.00000041489.11933.03
53. Granzow JW, Levine JL, Chiu ES, Allen RJ. Breast reconstruction with gluteal artery perforator flaps. *J Plast Reconstr Aesthet Surg* (2006) **59**(6):614–21. doi:10.1016/j.bjps.2006.01.005
54. Papp C, Windhofer C, Gruber S. Breast reconstruction with the fasciocutaneous infraglenular free flap (FCI). *Ann Plast Surg* (2007) **58**(2):131–6. doi:10.1097/01.sap.0000237635.05337.a1
55. Saad A, Sadeghi A, Allen RJ. The anatomic basis of the profunda femoris artery perforator flap: a new option for autologous breast reconstruction – a cadaveric and computer tomography angiogram study. *J Reconstr Microsurg* (2012) **28**(6):381–6. doi:10.1055/s-0032-1313773
56. Schoeller T, Huemer GM, Wechselberger G. The transverse musculocutaneous gracilis flap for breast reconstruction: guidelines for flap and patient selection. *Plast Reconstr Surg* (2008) **122**(1):29–38. doi:10.1097/PRS.0b013e318177436c

57. Holländer. Die kosmetische Chirurgie. In: Joseph M, editor. *Handbuch der Kosmetik*. Leipzig: Veit & Comp (1912). p. 669–712; 673.
58. Delay E, Gosset J, Toussoun G, Delaporte T, Delbaere M. [Efficacy of lipomodelling for the management of sequelae of breast cancer conservative treatment]. *Ann Chir Plast Esthet* (2008) **53**(2):153–68. doi:10.1016/j.anplas.2007.09.005
59. Kanchwala SK, Glatt BS, Conant EF, Bucky LP. Autologous fat grafting to the reconstructed breast: the management of acquired contour deformities. *Plast Reconstr Surg* (2009) **124**(2):409–18. doi:10.1097/PRS.0b013e3181aeadd
60. Weichman KE, Broer PN, Tanna N, Wilson SC, Allan A, Levine JP, et al. The role of autologous fat grafting in secondary microsurgical breast reconstruction. *Ann Plast Surg* (2013) **71**(1):24–30. doi:10.1097/SAP.0b013e3182920ad0
61. Sarfati I, Ihrari T, Duvernay A, Nos C, Clough K. [Autologous fat grafting to the postmastectomy irradiated chest wall prior to breast implant reconstruction: a series of 68 patients]. *Ann Chir Plast Esthet* (2013) **58**(1):35–40. doi:10.1016/j.anplas.2012.10.007
62. Hoppe DL, Ueberreiter K, Surlemont Y, Peltoniemi H, Stabile M, Kauhanen S. Breast reconstruction de novo by water-jet assisted autologous fat grafting – a retrospective study. *Ger Med Sci* (2013) **12**(11):Doc17. doi:10.3205/000185
63. Longo B, Laporta R, Sorotos M, Pagnoni M, Gentilucci M, Santanelli di Pompeo F. Total breast reconstruction using autologous fat grafting following nipple-sparing mastectomy in irradiated and non-irradiated patients. *Aesthetic Plast Surg* (2014) **38**(6):1101–8. doi:10.1007/s00266-014-0406-3
64. Coleman SR. Structural fat grafting: more than a permanent filler. *Plast Reconstr Surg* (2006) **118**(3 Suppl):108S–20S. doi:10.1097/01.prs.0000234610.81672.e7
65. Kaoutzanis C, Xin M, Ballard TN, Welch KB, Momoh AO, Kozlow JH, et al. Autologous fat grafting after breast reconstruction in postmastectomy patients: complications, biopsy rates, and locoregional cancer recurrence rates. *Ann Plast Surg* (2015). doi:10.1097/SAP.0000000000000561
66. Rubin JP, Coon D, Zuley M, Toy J, Asano Y, Kurita M, et al. Mammographic changes after fat transfer to the breast compared with changes after breast reduction: a blinded study. *Plast Reconstr Surg* (2012) **129**(5):1029–38. doi:10.1097/PRS.0b013e31824a2a8e
67. Gosset J, Guerin N, Toussoun G, Delaporte T, Delay E. [Radiological evaluation after lipomodelling for correction of breast conservative treatment sequelae]. *Ann Chir Plast Esthet* (2008) **53**(2):178–89. doi:10.1016/j.anplas.2007.09.003
68. Schweizer R, Tsuji W, Gorantla VS, Marra KG, Rubin JP, Plock JA. The role of adipose-derived stem cells in breast cancer progression and metastasis. *Stem Cells Int* (2015) **2015**:120949. doi:10.1155/2015/120949
69. Kamat P, Schweizer R, Kaenel P, Salemi S, Calcagni M, Giovanoli P, et al. Human adipose-derived mesenchymal stromal cells may promote breast cancer progression and metastatic spread. *Plast Reconstr Surg* (2015) **136**(1):76–84. doi:10.1097/PRS.0000000000001321
70. Lohsiriwat V, Curigliano G, Rietjens M, Goldhirsch A, Petit JY. Autologous fat transplantation in patients with breast cancer: “silencing” or “fueling” cancer recurrence? *Breast* (2011) **20**(4):351–7. doi:10.1016/j.breast.2011.01.003
71. Claro F Jr, Figueiredo JC, Zampar AG, Pinto-Neto AM. Applicability and safety of autologous fat for reconstruction of the breast. *Br J Surg* (2012) **99**(6):768–80. doi:10.1002/bjs.8722
72. Petit JY, Botteri E, Lohsiriwat V, Rietjens M, De Lorenzi F, Garusi C, et al. Locoregional recurrence risk after lipofilling in breast cancer patients. *Ann Oncol* (2012) **23**(3):582–8. doi:10.1093/annonc/mdr158

**Conflict of Interest Statement:** The authors declare that the research was conducted in the absence of any commercial or financial relationships that could be construed as a potential conflict of interest.

Copyright © 2016 Schmauss, Machens and Harder. This is an open-access article distributed under the terms of the Creative Commons Attribution License (CC BY). The use, distribution or reproduction in other forums is permitted, provided the original author(s) or licensor are credited and that the original publication in this journal is cited, in accordance with accepted academic practice. No use, distribution or reproduction is permitted which does not comply with these terms.



# Thoracic wall reconstruction after tumor resection

**Kamran Harati\*, Jonas Kolbenschlag, Björn Behr, Ole Goertz, Tobias Hirsch, Nicolai Kapalschinski, Andrej Ring, Marcus Lehnhardt and Adrien Daigeler**

*Department of Plastic Surgery, Burn Center, Hand Center, Sarcoma Reference Center, BG-University Hospital Bergmannsheil Bochum, Bochum, Germany*

**Introduction:** Surgical treatment of malignant thoracic wall tumors represents a formidable challenge. In particular, locally advanced tumors that have already infiltrated critical anatomic structures are associated with a high surgical morbidity and can result in full-thickness defects of the thoracic wall. Plastic surgery can reduce this surgical morbidity by reconstructing the thoracic wall through various tissue transfer techniques. Sufficient soft-tissue reconstruction of the thoracic wall improves quality of life and mitigates functional impairment after extensive resection. The aim of this article is to illustrate the various plastic surgery treatment options in the multimodal therapy of patients with malignant thoracic wall tumors.

**Materials and methods:** This article is based on a review of the current literature and the evaluation of a patient database.

**Results:** Several plastic surgical treatment options can be implemented in the curative and palliative therapy of patients with malignant solid tumors of the chest wall. Large soft-tissue defects after tumor resection can be covered by local, pedicled, or free flaps. In cases of large full-thickness defects, flaps can be combined with polypropylene mesh to improve chest wall stability and to maintain pulmonary function. The success of modern medicine has resulted in an increasing number of patients with prolonged survival suffering from locally advanced tumors that can be painful, malodorous, or prone to bleeding. Resection of these tumors followed by thoracic wall reconstruction with viable tissue can substantially enhance the quality of life of these patients.

**Discussion:** In curative treatment regimens, chest wall reconstruction enables complete resection of locally advanced tumors and subsequent adjuvant radiotherapy. In palliative disease treatment, plastic surgical techniques of thoracic wall reconstruction provide palliation of tumor-associated morbidity and can therefore improve patients' quality of life.

**Keywords:** thoracic wall, chest wall, tumor, sarcoma, breast cancer, reconstruction, flaps

## OPEN ACCESS

### Edited by:

Joe B. Putnam,  
Vanderbilt University Medical Center,  
USA

### Reviewed by:

Jan A. Plock,  
University of Zurich, Switzerland  
Osama Hussein,  
Mansoura University, Egypt

### \*Correspondence:

Kamran Harati  
kamran.harati@t-online.de

### Specialty section:

This article was submitted to *Surgical Oncology*, a section of the journal *Frontiers in Oncology*

**Received:** 28 June 2015

**Accepted:** 16 October 2015

**Published:** 29 October 2015

### Citation:

Harati K, Kolbenschlag J, Behr B, Goertz O, Hirsch T, Kapalschinski N, Ring A, Lehnhardt M and Daigeler A (2015) Thoracic wall reconstruction after tumor resection. *Front. Oncol.* 5:247. doi: 10.3389/fonc.2015.00247

## INTRODUCTION

The majority of thoracic wall defects result from the surgical resection of malignant tumors during curative or palliative attempts. These malignant tumors arise from all different anatomic structures of the thoracic wall and consequently vary in pathology and prognosis. Solid malignancies of the thoracic wall include primary thoracic wall tumors and metastatic lesions as well as locally invading



malignancies from adjacent tissues and organs, such as breast cancer, lung cancer, mediastinal neoplasms, and mesothelioma. The most common primary thoracic wall tumors are bone and soft-tissue sarcomas. Approximately 55% of the primary malignant chest wall tumors arise from the bone or cartilage, whereas 45% originate from the soft tissue (1, 2). Chondrosarcomas are the most common skeletal malignancies of the thoracic wall and commonly occur in the anterior thoracic wall (3). In the heterogeneous group of soft-tissue sarcomas, not otherwise specified sarcomas (NOS) and liposarcomas are known to be the most frequent primary soft-tissue sarcomas of the thoracic wall (4). Notably, the incidence of radiation-induced angiosarcomas of the chest wall is increasing due to the prolonged survival of women irradiated for primary breast cancer and will present a therapeutic challenge in the future (5). In patients with primary chest wall tumors and radiation-induced angiosarcomas, nearly all treatment regimens involve the surgical resection of the tumor with clear margins, usually followed by adjuvant radiation and/or chemotherapy depending on the histologic entity. However, surgical resection and reconstruction of the thoracic wall are also suitable for other patients besides those with primary tumors. Increasing knowledge in all fields of modern medicine and effective treatment modalities for different types of cancer continuously increase the survival of patients with metastatic or locally advanced disease stage. The incidence of metastatic lesions of the chest wall and locally invading tumors from the breast and lung will become more frequent in the future. Thus, palliative treatment options with as little perioperative morbidity as possible will become increasingly important. In this palliative setting, resection of painful, odor-intensive, and bleeding tumors with subsequent thoracic wall reconstruction seems to be a valid option to increase the quality of life at least for a period of time. Hence, careful planning and individualized treatment are particularly important in these patients to provide a safe and fast recovery.

Nevertheless, partial- and full-thickness thoracic wall resections combined with reconstruction still represent a formidable surgical challenge, but improvements in surgical technique, intensive care, and rehabilitation have led to reduced perioperative morbidity and mortality (6, 7). In the surgical field, plastic surgery procedures enable oncologic tumor resection, reconstruction of the thoracic wall, and adjuvant radiotherapy by improving the local tissue situation (8). Moreover, plastic surgical reconstruction of the thoracic wall provides sufficient stability to maintain pulmonary function. Pulmonary function parameters are reduced only moderately and are not significantly affected by the size of the resection or its location (9).

In the following article, we will discuss the different options for thoracic wall reconstruction after oncological resection by examining a series of cases from our institution and a review of the literature.

## PREOPERATIVE EVALUATION

Preoperative evaluation should be performed properly and in a multidisciplinary manner with pulmonary and cardiac function tests. In particular, patients with chronic obstructive pulmonary

disease should be treated preoperatively to optimize pulmonary function before surgery. Postoperatively, patients with cardiac or pulmonary disorders should be treated in the intensive care unit, and early extubation and active respiratory therapy should be the most important treatment goals. Chest X-ray, CT, and MRI can be used as diagnostic tools to assess the imaging appearance of thoracic wall tumors. CT can provide additional information about calcification, bone destruction, and vascularity of the tumor, whereas MRI provides more soft-tissue details. Precise radiological examination with detailed information about tumor location and extent is essential for proper surgical planning and management as well as preoperative histologic evaluation. CT-controlled biopsy and incisional biopsy can be used as suitable modalities of tissue obtainment. Preoperative histologic examination is mandatory and should be performed in any lesions suspected to be malignant.

## RESECTION

In a curative setting, the aim of surgical treatment is the resection of the tumor with microscopically negative margins. Appropriate oncologic resection should not be compromised because of concern for the resulting thoracic wall defect. However, the extent of surgical margin width is determined by the chest wall tumor histology. In soft-tissue sarcomas, there has been a shift of the paradigms regarding the width of surgical resection from radical wide resections to more marginal resections (10–12). In the surgical treatment of primary soft-tissue sarcomas of the chest wall, negative surgical margins were not significantly associated with prolonged overall survival when compared with positive margins (7, 13). However, the attainment of microscopically negative margins should be the goal of surgical resection to improve local control and to prevent local recurrence (14), but, to date, there is no reasonable evidence for radical surgical approach in most soft-tissue sarcomas, for which marginal resections seem to be sufficient for local disease control (12).

Complete surgical resection with negative margins also remains the mainstay of therapy in the curative treatment of other malignancies that are still localized and not disseminated, such as locally advanced breast carcinomas. Thoracic wall resection and reconstruction have been proven to be a safe and effective procedure in patients with advanced, locally recurrent breast carcinomas (15).

As mentioned earlier, increasing numbers of patients present with a disseminated disease stage and are not suitable for a curative approach. In these patients, surgical treatment should be considered carefully and every attempt should be made to minimize perioperative morbidity. Tumor debulking and reliable soft-tissue coverage can alleviate pain and suffering for at least a period of time.

## THORACIC WALL RECONSTRUCTION WITH MESH AND COMPOSITE IMPLANTS

Depending on the extent of the malignant tumor, adequate oncologic resection can result in partial- or full-thickness thoracic wall defects. Full-thickness defects, which involve all tissue layers

including soft tissue and bony structures, should be reconstructed immediately during the same surgery to protect the subjacent organs and to enable quick recovery. In this procedure, thoracic wall reconstruction should obliterate dead space and provide adequate soft-tissue coverage and stability, without compromising respiratory biomechanics. For this purpose, synthetic nets can be utilized to improve chest wall stability and to avoid herniation of intrathoracic organs. These nets should be both robust and pliable. In recent decades, synthetic nets have included essential features such as inertness, radiolucency, sufficient rigidity, and pliability. At our institution, we have had successful experiences with non-absorbable polypropylene meshes. However, different synthetic nets are now available, but none of them have proven to be significantly superior (16–18). The decision as to whether synthetic nets should be utilized depends on several factors, which include not only defect area and depth but also rigidity of the chosen flap coverage, location, wound contamination, and skin texture after previous radiation. It is widely accepted that defects exceeding more than four ribs at the lateral chest wall are associated with higher risks of herniation and paradox breathing and therefore should additionally be reconstructed with synthetic nets (8, 19–22). However, the closer the defect to the apex of the thoracic wall, the more suspension is provided by the sternum, scapula, and clavicle, and even larger defects might be reconstructed without additional synthetic material (23). Similarly, an irradiated chest wall may provide enough rigidity to avoid additional mesh implantation. Nevertheless, irradiated tissue should be replaced as far as possible by healthy tissue to allow proper healing and, if necessary, subsequent radiation (24). Notably, synthetic nets should be avoided in contaminated wound defects and should be implanted subsequently under clean wound conditions. Alternatively, if quick coverage and adequate stability can be achieved during the same surgical procedure, chest wall reconstruction can be performed with a stable, muscular flap, such as the latissimus dorsi flap, which is discussed below. In patients with simultaneous irradiated soft-tissue defects and infections in the chest wall area, such as pleural empyema, we usually debride and cover the defects with pedicled latissimus dorsi flaps without synthetic mesh implantation during one surgical procedure.

To maintain chest wall rigidity and to improve functional as well as cosmetic outcomes after large anterior and lateral resections, several authors have recommended the use of composite implant techniques (16, 21, 25–28). The most common composite is the combination of polypropylene meshes and methylmethacrylate substitutes in the form of a “sandwich” prosthesis. Here, a first layer of polypropylene mesh is positioned straight on the base of the defect and the methylmethacrylate substitute is then added and molded to the pattern of the defect. A second layer of polypropylene mesh is placed on top of the methylmethacrylate substitute, which hardens in an exothermic reaction. This composite implant technique allows for the reconstruction of the original contours of the chest wall and can be performed as a one-stage surgical procedure for major anterior and lateral chest wall defects to prevent paradoxical movement and overcome deformities. However, methylmethacrylate substitutes are not permeable to fluids and, hence, are considered to increase the risk of infections (29). Nevertheless, several case series and a

retrospective analysis of 112 patients with polypropylene mesh/methylmethacrylate composites have demonstrated quite good functional results without increased infection rates (16, 26, 28). Weyant and colleagues have reported no significant difference between large chest wall defects reconstructed with polypropylene mesh/methylmethacrylate composite and small chest wall defects reconstructed with polypropylene mesh with regard to respiratory complications (28). Other composite implant techniques, including silicone, rubber, carbon fiber, and polytetrafluoroethylene (PTFE), have been described in case reports (21, 29–31). There have also been reports on the safe use of titanium implants in the reconstruction of the chest wall after tumor resection (32–34). In 19 patients with large anterior and lateral full-thickness defects after tumor resection, Berthet et al. have reconstructed the chest wall via a combination of titanium rib osteosynthesis and PTFE mesh in a one-step procedure (32). There were two cases of infection and one patient with a major complication in the form of respiratory failure. More recently, the improvements in 3D prototyping technology by selective laser sintering have enabled the production of more complex and detailed custom-made titanium implants. In this regard, Turna et al. have presented a case in which an extended anterior chest wall defect after tumor resection was safely reconstructed with a customized titanium implant in combination with a pedicled latissimus dorsi flap and a split-thickness graft (34). However, each material has its own advantages and disadvantages. There is still a lack of evidence regarding each of these approaches, and further studies are warranted to provide long-term data. The same issue applies to the use of allografts and xenografts because the literature on these topics remains sparse (21). The decision about which material to use ultimately depends on the defect and the surgeon's experience.

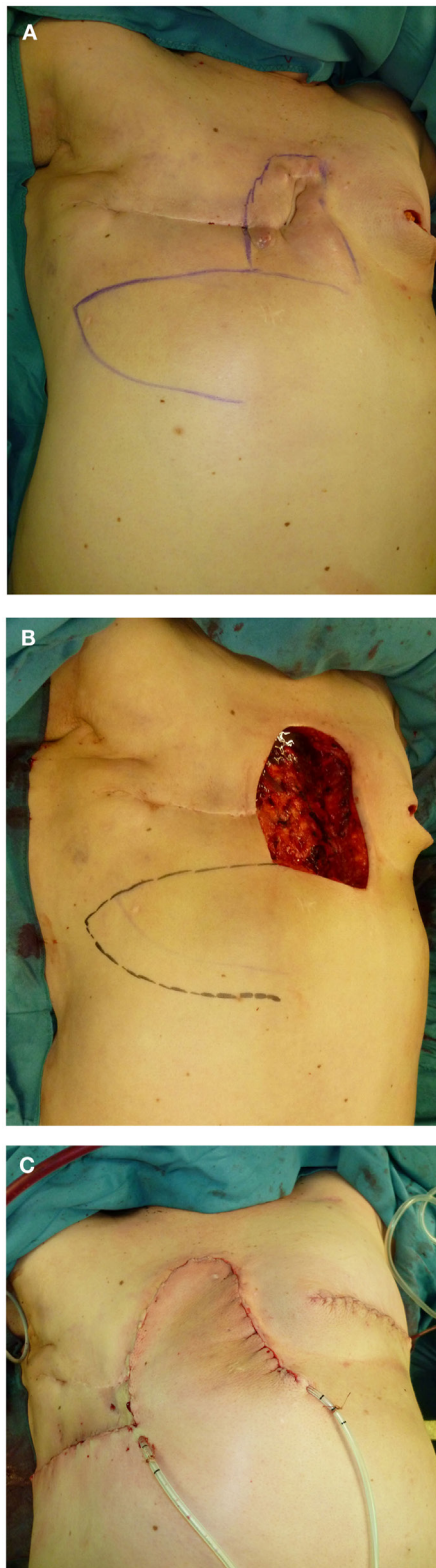
## OSTEOSYNTHESIS

When direct approximation of the sternal edges is possible, osteosynthetic procedures can maintain the chest wall stability and improve the functional outcome after partial anterior resections. Here, several studies have demonstrated that primary sternal plating reduces the risk of sternal non-unions and postoperative mediastinitis more effectively than does fixation via cerclage wires (35–37). If direct sternal fixation is not possible, we bridge over the sternal defect with local flaps such as the pectoralis major or vertical rectus abdominis muscle (VRAM) flap.

In the following section, we will address the different options of plastic surgical soft-tissue coverage that are commonly used at our institution.

## THORACOEPIGASTRIC FLAP

The thoracoepigastric flap is a fasciocutaneous flap pedicled to the perforators at the proximity of the midline of the fascia of the musculus rectus abdominis and can be utilized to cover smaller defects (Figures 1A–C). Medially based thoracoepigastric flaps receive perforator vessels from the epigastric arcade, whereas laterally based flaps are supplied by perforators from the intercostal arteries. The reliability of the blood supply can be assessed by preoperative Doppler imaging. Thoracoepigastric flaps can be raised superior



**FIGURE 1 | (A–C)** Thoracoepigastric soft-tissue coverage after resection of a locally recurrent breast carcinoma (right) with simultaneous, contralateral infestation at the left breast.

or inferior to the level of the rectus fascia and investing fascia of the external oblique musculature (38). Primary donor-site closure can be achieved for most of the laterally based flaps, whereas skin grafting is often required for medially based thoracoepigastric flaps (38, 39). Thoracoepigastric flaps are indicated for the coverage of smaller defects located in the lower thoracic region.

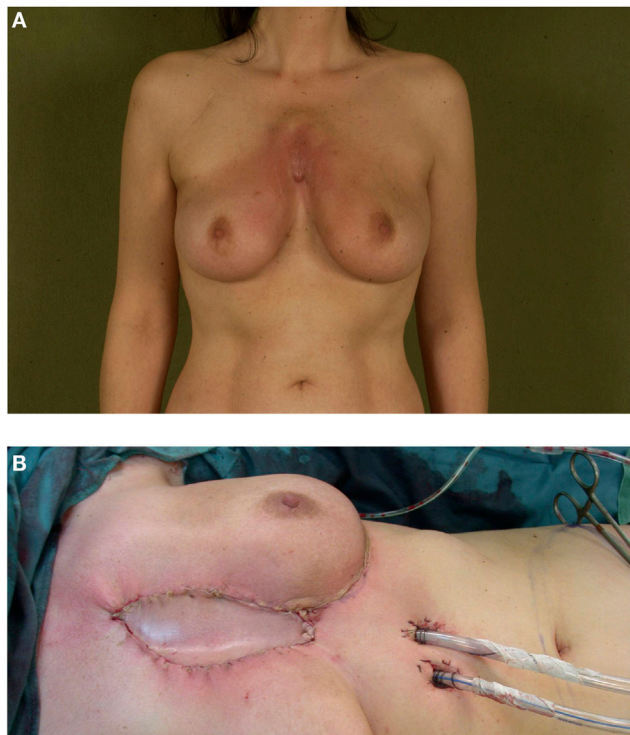
## PECTORALIS MAJOR FLAP

The pectoralis major flap can be used as a myocutaneous flap or simply as a muscular flap. When used as a myocutaneous flap, a skin graft is also taken from the region of the lower breast fold, and this graft remains pedicled to the muscle and can be transposed into the head and neck region (40). The pectoralis major muscle is supplied by a dominant vascular pedicle (arteria thoracoacromialis) and several minor pedicles. The thoracoacromial artery presents a consistent and reliable pedicle on which the pectoralis major muscle can be completely elevated (41). The pectoralis major muscle has also reliable secondary perforators from the internal mammary artery allowing medially based propeller flaps to cover smaller sternal defects. In chest wall reconstruction, the pectoralis major flap is primarily used as a muscle advancement or rotation flap to cover defects in the cranial portion of the sternum (42). Smaller contralateral defects may also be easily reached by this flap (**Figures 2A,B** and **3A,B**). It can also be lifted from the thoracic wall as a sliding pectoralis muscle flap. To gain more rotatory flexibility, it can be removed from the clavicle and the humerus. In this case, it remains pedicled to the pectoral branches of the thoracoacromial artery. Upon lifting the muscle, there is only a moderate loss of strength (42). However, the size of the skin graft is very limited when lifted as a myocutaneous flap, and the vascular structure of the flap is often impaired by prior operations and radiotherapy. Low sternal and xiphoid defects may also be out of reach for the pectoralis major flap.

## VRAM FLAP

The VRAM flap is particularly suited for longitudinal anterior chest wall defects (43) (**Figures 4A,B**). Preoperative planning should consider any possible removal of the arteria mammaria interna in previous coronary artery bypass operations because the VRAM flap is primarily supplied by the arteria epigastrica superior and arteria mammaria interna. In such cases, the VRAM flap can be lifted contralaterally to the place of removal. On rare occasions, insufficient venous outflow via the superior epigastric vessels can occur. Here, the inferior epigastric vessels at the caudal portion of the flap can be connected parasternally to the mammaria interna vessels in the sense of vessel supercharging. The VRAM flap is particularly indicated when sternal defects with large volumes should be covered and when sternal defects extend inferiorly to the epigastric areas (41, 44). It is also a reliable backup option when defect coverage with the latissimus dorsi flap is not possible. In a follow-up study at our institution, abdominal hernia and bulging occurred in 13% of all oncological patients treated with VRAM flap plasties. No flap loss was observed, and the loss of strength was moderate with a slight restriction of





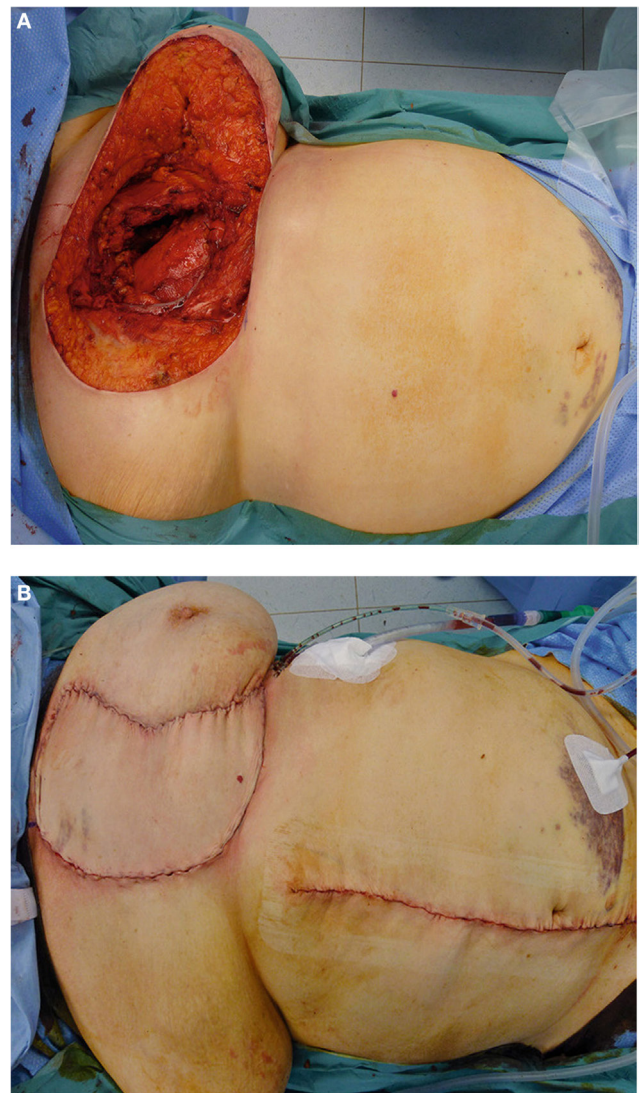
**FIGURE 2 | (A,B)** Pectoralis major flap coverage of a central chest wall defect after resection of a recurrent sarcoma.

endurance without decreased maximum strength (45). However, the relatively high rates of abdominal hernia have to be considered, and the indication for local reconstruction with VRAM should be weighed carefully, especially in patients in a palliative setting where some surgical procedures (e.g., stabilization of the abdominal wall) should be avoided.

## CRANIALLY PEDICLED TRAM FLAP

To cover larger defects, particularly at the anterolateral thorax, the VRAM flap can be extended to include a transversal graft from the lower abdomen [transverse rectus abdominis myocutaneous flap (TRAM)] (**Figures 4C and 5A,B**). The resulting anchor flap can correct defects up to 40 cm in diameter. In the majority of cases, the cutaneous donor site should primarily be closed by means of an abdominoplasty with umbilical repositioning when possible. Depending on the resulting fascia defect, the abdominal wall can be reinforced with a polypropylene mesh insert to avoid the formation of an abdominal hernia. The perfusion of cranially pedicled TRAM flap takes place via the superior epigastric vessels, which are slimmer than the inferior epigastric vessels. Hence, in the case of a cranially pedicled flap from the lower abdomen, perfusion disorders and partial necrosis can occur, particularly in the lateral portions of the flap.

Nevertheless, the cranially pedicled TRAM flap remains a reliable option in the armamentarium of soft-tissue coverage, especially in the case of extensive tumors of the anterolateral chest wall.

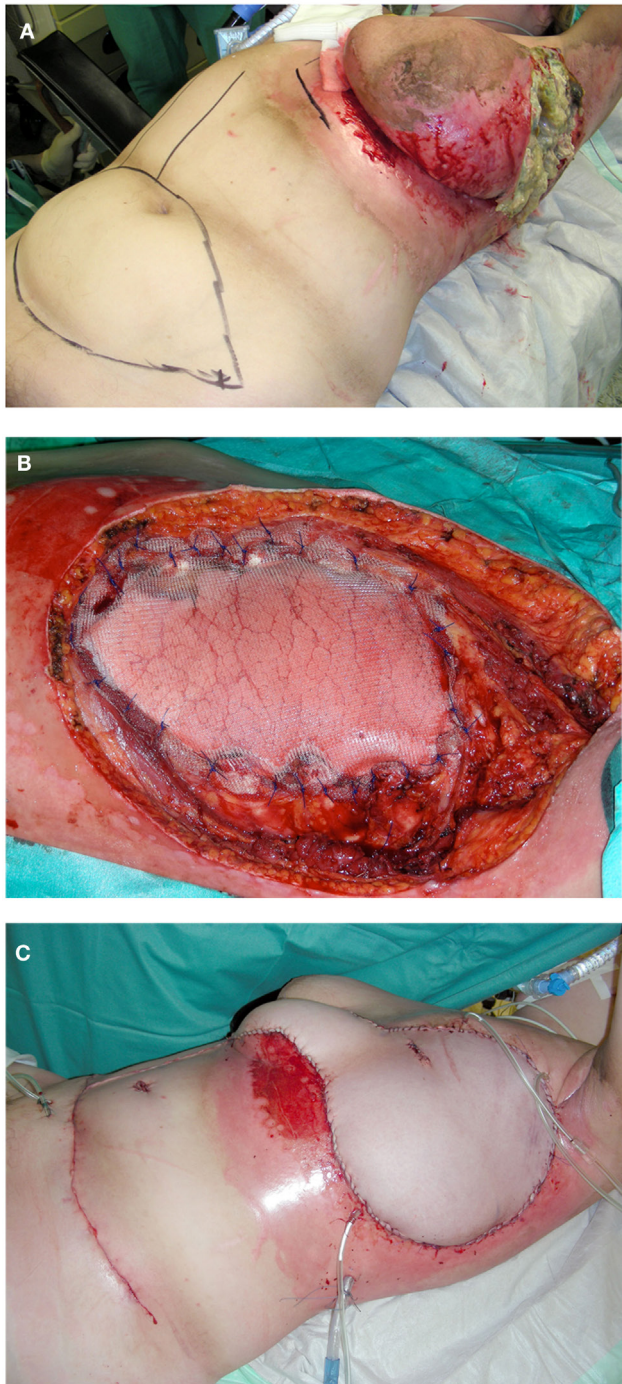


**FIGURE 3 | (A,B)** Chest wall coverage following tumor resection with VRAM flap.

## LATISSIMUS DORSI MUSCULAR FLAP

A pedicled latissimus dorsi flap can sufficiently cover most defects on the thoracic wall (**Figures 5C,D**). The latissimus dorsi flap can be harvested as a muscle flap, a myocutaneous flap, or a perforator flap. The thoracodorsal artery is the dominant pedicle of the latissimus dorsi flap and arises from the subscapular artery. Anatomic variations are well described and should be considered when raising the flap (41). After entering the base of the latissimus dorsi muscle, the thoracodorsal artery divides into two main branches. The upper horizontal branch runs medially along the superior border of the muscle and the descending branch runs parallel to the anterior border of the muscle (46, 47). The large radius of rotation enables large soft-tissue coverage at the anterior chest wall, the sternal region, and the upper arm. Due to its reliable vascular supply, its proportions, and the moderate donor-site





**FIGURE 4 | (A–C)** Resection of ulcerative breast carcinoma and subsequent chest wall reconstruction with implantation of polypropylene mesh and craniially pedicled TRAM flap plasty.

defect, the latissimus dorsi flap has proven itself in the coverage of thoracic wall defects (9, 20, 44, 48, 49). Because of its volume, it can also seal intrathoracic defects and dead space. The large caliber of the vascular pedicle with a diameter of 2–4 mm will also permit immediate microsurgical transfer if necessary (50).

## OMENTUM MAJUS FLAP

The omentum majus flap is an alternative option for closing defects in the anterior thoracic wall when the aforementioned pedicled flaps or free flaps flap are not suitable. It is also an option to cover large defects with small volumes. Pedicled to the unilateral or bilateral gastro-omental vessels, it can be lifted via a paramedian incision from the xiphoid process to beneath the umbilicus (51, 52). The size of the omentum majus flap can only be determined reliably under direct visual control after surgical exposition. Especially after previous abdominal surgery, adhesions must be removed and the omentum majus raised from the stomach to achieve the appropriate rotatory radius. Furthermore, a breach must remain in the cranial abdominal wall so that the pedicle can be guided through it toward the thoracic wall. Consequently, this flap should be raised only by experienced surgeons who can manage potential intra-abdominal complications such as intestinal perforations and bleeding. Due to its great plasticity, the omentum is well suited for sealing dead space. However, it must always be covered by split skin graft and partial secondary healing can occur due to persistent serous discharge from the fatty tissue. Because of the high risk for the development of epigastric hernia and the aforementioned disadvantages, the pedicled omentum majus remains principally a fallback option when other procedures are not suitable (53, 54).

## FREE FLAP PLASTIES

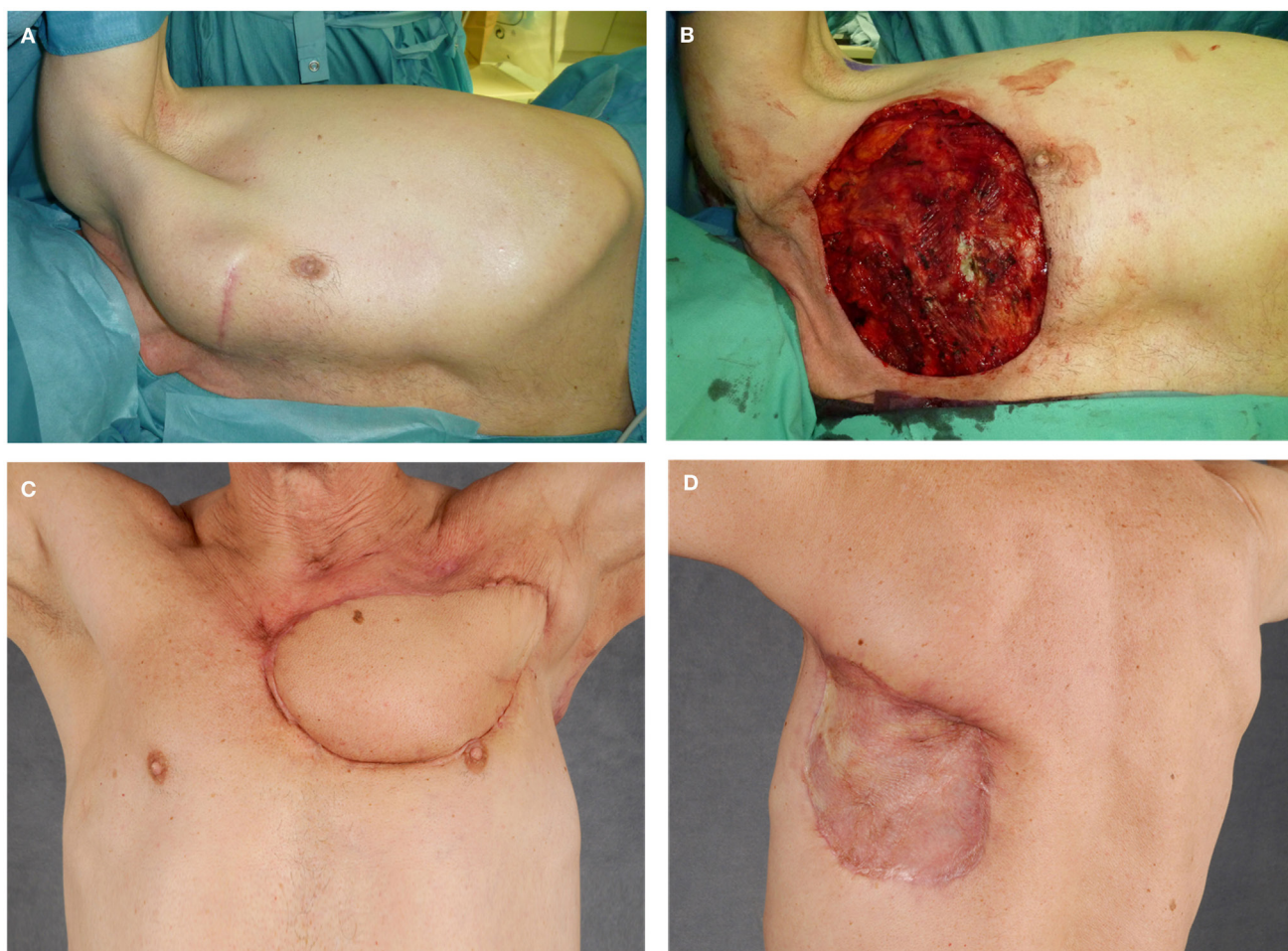Previous operations, axillary lymph dissection, or radiotherapy can prevent pedicled flaps from being utilized for soft-tissue coverage. In these situations, free flaps form an additional and pivotal tool in the armamentarium of plastic surgery. Fasciocutaneous or myocutaneous flaps from the back (latissimus dorsi flap, parascapular flap) or the thigh [anterior lateral thigh (ALT); tensor fasciae latae (TFL)] are some free flaps regularly used at our institution. Another frequently used donor area is the abdominal region with the TRAM flap or its muscle-preserving variation (ms-TRAM) as well as the perforator-based deep inferior epigastric artery perforator flap (DIEP).

The internal mammary artery is the primary connecting vessel at the anterior thoracic wall. At the lateral thoracic wall, the thoracodorsal vessels can act as sufficient connectors. In the event that these are not available, an arteriovenous loop between the cephalic vein and the thoracoacromial artery can constitute an effort-intensive but feasible solution (55).

The donor-site morbidity of free flaps is moderate and well tolerated by most patients, especially if the donor site can be closed primarily (50, 56, 57).

## PULMONARY FUNCTION, QUALITY OF LIFE, AND MORTALITY

In our patient population, thoracic wall reconstruction-impaired pulmonary function parameters vary only slightly (9). The most significant alteration was found in the forced expiratory volume in 1 s (FEV1), which was decreased by approximately 18%. This observed reduction of FEV1 might be the consequence of the loss



**FIGURE 5 | (A–D)** Resection of a recurrent high-grade chondrosarcoma and chest wall reconstruction utilizing latissimus dorsi flap with split skin graft coverage of the flap donor site.

of the intercostal muscles. However, the extent of chest wall resection was not found to be a significant predictor of pulmonary function alteration. In fact, breathing pain affected respiratory function in a significant manner, whereas the extent of resection surprisingly did not correlate with breathing pain. Partial lung resection also did not significantly impair pulmonary function. Similar findings were also observed in other studies in which pulmonary function was only slightly affected by thoracic wall resection (58–60). Reviewing our own data, hospitalization at our institution averaged 20.7 days (range, 6–89), and patients were in the intensive care unit for 6 days on average (range, 0–74). Patients were mechanically ventilated for 2.7 days postoperatively (range, 0–62) (9).

Thoracic wall resection and reconstruction are associated with significant morbidity reducing nearly all daily life activities (9). However, a certain degree of selection bias in such assessments must be acknowledged. The patients interviewed here represented the healthier and more active patients. These patients sensed postoperative restrictions more than those patients who were treated in palliative intention because of pain and ulcerated

lesions. However, with respect to the malignancy of the underlying disease, these restrictions might be justified. In our patient population, the majority of the treated and interviewed patients would undergo the procedure again (9).

Effective treatment modalities have improved the survival of patients with thoracic wall tumors in recent decades (61). At our institute, the 5-year overall survival rate for patients with malignant chest wall tumors including soft-tissue sarcomas and breast carcinoma was approximately 56% (9). For chest wall sarcomas, the 5-year overall survival rates were approximately 52%. Other studies have presented similar overall survival rates (7, 14, 62, 63). In an analysis of 127 full-thickness resections for chest wall sarcomas, Wouters et al. demonstrated that full-thickness chest wall resection represents a safe and effective procedure, with a limited number of complications and an adequate long-term survival. For primary chest wall sarcomas, these authors reported a 5-year survival rate of 63% and for recurrent sarcomas 50% (14). Furthermore, adjuvant radiotherapy was associated with increased local disease control. In the treatment of locally advanced or recurrent breast carcinomas, full-thickness chest



wall resection was also associated with an acceptable morbidity and a 5-year overall survival rate of 63% after surgery (64).

## CONCLUSION

In curative treatment regimens, chest wall reconstruction enables the complete resection of tumors and subsequent adjuvant radiotherapy. Even at advanced localized disease stages or in a palliative treatment setting, safe and reliable techniques allow the removal of large ulcerative tumors. As a reconstructive option after tumor resection, local flaps represent a reliable tool that can cover most thoracic wall defects. Nevertheless, concerns over distant iatrogenic implantation of tumor cells at the donor site of local flaps do exist when tumor resection and flap coverage are performed during the same surgery. In the literature, unfortunately, there has been no systematic analysis of this issue. However, iatrogenic tumor metastases, especially sarcoma metastases, at donor-tissue sites after local flap reconstruction are a rare occurrence and should not preclude the use of local flap reconstruction (65). They have been reported only in selected case reports (66). Further, the effect of donor-site radiation on the incidence of iatrogenic sarcoma metastases still remains unclear and should be examined (65).

Besides the aforementioned disadvantages and concerns, local flaps can offer some slight but noteworthy advantages. In contrast to free flaps, local flaps do not require intensive postoperative flap inspections. Postoperative positioning protocols and anticoagulation regimens are less stringent. However, there has been a paradigm shift in recent decades. Free tissue transfers can now be performed with a similar or even higher degree of safety than local flap transfer as a result of the improvements in microsurgical techniques. Safe dissection and positioning of a local flap at the chest wall can be technically more demanding, risky, and time-consuming when compared with a free flap transfer in a two-team approach. Due to the microsurgical and anesthesiological improvements, free flap transfers have become physically less demanding surgical procedures and have also become suitable for patients with chest wall tumors at an advanced disease stage.

For those defects that can be covered by local flaps, pectoralis major, thoracoepigastric, VRAM, cranially pedicled TRAM, and latissimus dorsi flaps are commonly used. Small defects can be covered by pectoralis or thoracoepigastric flaps, whereas larger vertical defects can be covered by VRAM flaps. However, the relatively high rates of abdominal hernia have to be considered here. To cover larger defects particularly at the anterolateral thorax, the cranially pedicled TRAM flap can be utilized. However, most of the chest wall defects can be safely covered by pedicled latissimus dorsi flaps, particularly at the anterior chest wall and the sternal region. Pedicled omentum flaps remain an option for large defects with small volumes or when other procedures are unsuitable. Although most chest wall defects can be covered with local flaps, free tissue reconstruction should be carefully considered in each case, especially in areas that are difficult to reach with local flaps or when a single local flap is inadequate to cover the defect. Full-thickness chest wall defects that involve more than four ribs at the lateral chest wall should additionally be stabilized with polypropylene mesh. Larger defects at the anterior and lateral chest wall can be reconstructed by polypropylene mesh/methylmethacrylate composite and covered by local or free flaps.

Conclusively, thoracic wall resection with defect coverage during the same procedure enables patients to recover more quickly and shortens hospitalization. The effects on pulmonary function are moderate and well tolerated. Thoracic wall resection and reconstruction have proven to be safe and effective, with a reasonable long-term survival in the treatment of chest wall sarcomas and locally advanced breast carcinomas. A multimodal approach with proper preoperative evaluation and advanced plastic surgery techniques can decrease postoperative morbidity and ameliorate the resulting functional deficits. Although oncological safety is of the upmost priority, patients' safety and their quality of life are essential to provide optimal care. Due to the increasing complexity of oncological care and the multiple disciplines involved, this can preferably be achieved in an interdisciplinary approach involving tumor boards at specialized treatment centers.

## REFERENCES

- Shah AA, D'Amico TA. Primary chest wall tumors. *J Am Coll Surg* (2010) **210**(3):360–6. doi:10.1016/j.jamcollsurg.2009.11.012
- David EA, Marshall MB. Review of chest wall tumors: a diagnostic, therapeutic, and reconstructive challenge. *Semin Plast Surg* (2011) **25**(1):16–24. doi:10.1055/s-0031-1275167
- Incarbone M, Alloisio M, Luzzati S, Testori A, Cariboni U, Infante M, et al. [Chest wall and vertebral en-bloc resection for sarcoma: ten-year experience]. *Minerva Chir* (2005) **60**(4):273–8.
- Tateishi U, Gladish GW, Kusumoto M, Hasegawa T, Yokoyama R, Tsuchiya R, et al. Chest wall tumors: radiologic findings and pathologic correlation: part 2. Malignant tumors. *Radiographics* (2003) **23**(6):1491–508. doi:10.1148/rg.236015527
- Depla AL, Scharloo-Karels CH, de Jong MA, Oldenburg S, Kolff MW, Oei SB, et al. Treatment and prognostic factors of radiation-associated angiosarcoma (RAAS) after primary breast cancer: a systematic review. *Eur J Cancer* (2014) **50**(10):1779–88. doi:10.1016/j.ejca.2014.03.002
- Tukiainen E, Popov P, Asko-Seljavaara S. Microvascular reconstructions of full-thickness oncological chest wall defects. *Ann Surg* (2003) **238**(6):794–801. doi:10.1097/01.sla.0000098626.79986.51
- van Geel AN, Wouters MW, Lans TE, Schmitz PI, Verhoef C. Chest wall resection for adult soft tissue sarcomas and chondrosarcomas: analysis of prognostic factors. *World J Surg* (2011) **35**(1):63–9. doi:10.1007/s00268-010-0804-x
- Stein HU, Hebebrand D, Vogt P, Peter F, Tosson R. [Reconstructive plastic surgery of thoracic wall defects]. *Chirurg* (1997) **68**(5):461–8. doi:10.1007/s001040050214
- Daigeler A, Druecke D, Hakimi M, Duchna HW, Goertz O, Homann HH, et al. Reconstruction of the thoracic wall-long-term follow-up including pulmonary function tests. *Langenbecks Arch Surg* (2009) **394**(4):705–15. doi:10.1007/s00423-008-0400-9
- Lehnhardt M, Hirche C, Daigeler A, Goertz O, Ring A, Hirsch T, et al. [Soft tissue sarcoma of the upper extremities. Analysis of factors relevant for prognosis in 160 patients]. *Chirurg* (2012) **83**(2):143–52. doi:10.1007/s00104-011-2124-6

11. Daigeler A, Zmarsly I, Hirsch T, Goertz O, Steinau HU, Lehnhardt M, et al. Long-term outcome after local recurrence of soft tissue sarcoma: a retrospective analysis of factors predictive of survival in 135 patients with locally recurrent soft tissue sarcoma. *Br J Cancer* (2014) **110**(6):1456–64. doi:10.1038/bjc.2014.21
12. Kandel R, Coakley N, Werier J, Engel J, Ghert M, Verma S, et al. Surgical margins and handling of soft-tissue sarcoma in extremities: a clinical practice guideline. *Curr Oncol* (2013) **20**(3):e247–54. doi:10.3747/co.20.1308
13. Gross JL, Younes RN, Haddad FJ, Deheinzlin D, Pinto CA, Costa ML. Soft-tissue sarcomas of the chest wall: prognostic factors. *Chest* (2005) **127**(3):902–8. doi:10.1378/chest.127.3.902
14. Wouters MW, van Geel AN, Nieuwenhuis L, van Tinteren H, Verhoef C, van Coevorden F, et al. Outcome after surgical resections of recurrent chest wall sarcomas. *J Clin Oncol* (2008) **26**(31):5113–8. doi:10.1200/JCO.2008.17.4631
15. Lindford AJ, Jähkola TA, Tukiainen E. Late results following flap reconstruction for chest wall recurrent breast cancer. *J Plast Reconstr Aesthet Surg* (2013) **66**(2):165–73. doi:10.1016/j.bjps.2012.09.027
16. Lardinois D, Muller M, Furrer M, Banic A, Gugger M, Krueger T, et al. Functional assessment of chest wall integrity after methylmethacrylate reconstruction. *Ann Thorac Surg* (2000) **69**(3):919–23. doi:10.1016/S0003-4975(99)01422-8
17. Deschamps C, Tirnaklis BM, Darbandi R, Trastek VF, Allen MS, Miller DL, et al. Early and long-term results of prosthetic chest wall reconstruction. *J Thorac Cardiovasc Surg* (1999) **117**(3):588–91. doi:10.1016/S0022-5223(99)70339-9
18. Daigeler A, Harati K, Goertz O, Hirsch T, Behr B, Lehnhardt M, et al. Thoracic wall reconstruction in advanced breast tumours. *Geburtshilfe Frauenheilkd* (2014) **74**(6):548–56. doi:10.1055/s-0033-1360321
19. Losken A, Thourani VH, Carlson GW, Jones GE, Culbertson JH, Miller JJ, et al. A reconstructive algorithm for plastic surgery following extensive chest wall resection. *Br J Plast Surg* (2004) **57**(4):295–302. doi:10.1016/j.bjps.2004.02.004
20. Arnold PG, Pairolero PC. Chest-wall reconstruction: an account of 500 consecutive patients. *Plast Reconstr Surg* (1996) **98**(5):804–10. doi:10.1097/00006534-199610000-00008
21. Mahabir RC, Butler CE. Stabilization of the chest wall: autologous and alloplastic reconstructions. *Semin Plast Surg* (2011) **25**(1):34–42. doi:10.1055/s-0031-1275169
22. Netscher DT, Izaddoost S, Sandvall B. Complications, pitfalls, and outcomes after chest wall reconstruction. *Semin Plast Surg* (2011) **25**(1):86–97. doi:10.1055/s-0031-1275175
23. Daigeler A, Drucke D, Tatar K, Homann HH, Goertz O, Tilkorn D, et al. The pedicled gastrocnemius muscle flap: a review of 218 cases. *Plast Reconstr Surg* (2009) **123**(1):250–7. doi:10.1097/PRS.0b013e3181904e2e
24. Vogt PM, Busch K, Peter FW, Mocklinghoff C, Torres A, Steinau HU. [Plastic reconstruction of the irradiated thoracic wall]. *Langenbecks Arch Chir Suppl Kongressbd* (1998) **115**:507–11.
25. Thomas PA, Brouchet L. Prosthetic reconstruction of the chest wall. *Thorac Surg Clin* (2010) **20**(4):551–8. doi:10.1016/j.thorsurg.2010.06.006
26. Fouad FA. Chest wall resection and reconstruction: analysis of 11 cases after methylmethacrylate reconstruction. *J Egypt Natl Canc Inst* (2006) **18**(3):175–82.
27. Vartanian SM, Colaco S, Orloff LE, Theodore PR. Oklahoma prosthesis: resection of tumor of clavicle and chest wall reconstructed with a custom composite graft. *Ann Thorac Surg* (2006) **82**(1):332–4. doi:10.1016/j.athoracsur.2005.09.029
28. Weyant MJ, Bains MS, Venkatraman E, Downey RJ, Park BJ, Flores RM, et al. Results of chest wall resection and reconstruction with and without rigid prosthesis. *Ann Thorac Surg* (2006) **81**(1):279–85. doi:10.1016/j.athoracsur.2005.07.001
29. Chapelier AR, Missana MC, Couturaud B, Fadel E, Fabre D, Mussot S, et al. Sternal resection and reconstruction for primary malignant tumors. *Ann Thorac Surg* (2004) **77**(3):1001–6. doi:10.1016/j.athoracsur.2003.08.053
30. Akiba T, Marushima H, Nogi H, Kamiya N, Kinoshita S, Takeyama H, et al. Chest wall reconstruction using Gore-Tex(R) dual mesh. *Ann Thorac Cardiovasc Surg* (2012) **18**(2):166–9. doi:10.5761/atcs.cr.11.01718
31. Watanabe A, Watanabe T, Obama T, Ohsawa H, Mawatari T, Ichimiya Y, et al. New material for reconstruction of the anterior chest wall, including the sternum. *J Thorac Cardiovasc Surg* (2003) **126**(4):1212–4. doi:10.1016/S0022-5223(03)00933-4
32. Berthet JP, Canaud L, D'Annoville T, Alric P, Marty-Ane CH. Titanium plates and Dualmesh: a modern combination for reconstructing very large chest wall defects. *Ann Thorac Surg* (2011) **91**(6):1709–16. doi:10.1016/j.athoracsur.2011.02.014
33. Girotti P, Leo F, Bravi F, Tavecchio L, Spano A, Cortinovis U, et al. The “rib-like” technique for surgical treatment of sternal tumors: lessons learned from 101 consecutive cases. *Ann Thorac Surg* (2011) **92**(4):1208–15. doi:10.1016/j.athoracsur.2011.05.016
34. Turna A, Kavakli K, Sapmaz E, Arslan H, Caylak H, Gokce HS, et al. Reconstruction with a patient-specific titanium implant after a wide anterior chest wall resection. *Interact Cardiovasc Thorac Surg* (2014) **18**(2):234–6. doi:10.1093/icvts/ivt408
35. Song DH, Lohman RF, Renucci JD, Jeevanandam V, Raman J. Primary sternal plating in high-risk patients prevents mediastinitis. *Eur J Cardiothorac Surg* (2004) **26**(2):367–72. doi:10.1016/j.ejcts.2004.04.038
36. Lee JC, Raman J, Song DH. Primary sternal closure with titanium plate fixation: plastic surgery effecting a paradigm shift. *Plast Reconstr Surg* (2010) **125**(6):1720–4. doi:10.1097/PRS.0b013e3181d51292
37. Raman J, Song DH, Bolotin G, Jeevanandam V. Sternal closure with titanium plate fixation – a paradigm shift in preventing mediastinitis. *Interact Cardiovasc Thorac Surg* (2006) **5**(4):336–9. doi:10.1510/icvts.2005.121863
38. Matros E, Disa JJ. Uncommon flaps for chest wall reconstruction. *Semin Plast Surg* (2011) **25**(1):55–9. doi:10.1055/s-0031-1275171
39. Skoracki RJ, Chang DW. Reconstruction of the chestwall and thorax. *J Surg Oncol* (2006) **94**(6):455–65. doi:10.1002/jso.20482
40. Ariyan S. The pectoralis major myocutaneous flap. A versatile flap for reconstruction in the head and neck. *Plast Reconstr Surg* (1979) **63**(1):73–81. doi:10.1097/00006534-197901000-00012
41. Bakri K, Mardini S, Evans KK, Carlsen BT, Arnold PG. Workhorse flaps in chest wall reconstruction: the pectoralis major, latissimus dorsi, and rectus abdominis flaps. *Semin Plast Surg* (2011) **25**(1):43–54. doi:10.1055/s-0031-1275170
42. Daigeler A, Falkenstein A, Pennekamp W, Duchna HW, Jettkant B, Goertz O, et al. Sternal osteomyelitis: long-term results after pectoralis muscle flap reconstruction. *Plast Reconstr Surg* (2009) **123**(3):910–7. doi:10.1097/PRS.0b013e318199f49f
43. Mathes SJ. Chest wall reconstruction. *Clin Plast Surg* (1995) **22**(1):187–98.
44. Beahm EK, Chang DW. Chest wall reconstruction and advanced disease. *Semin Plast Surg* (2004) **18**(2):117–29. doi:10.1055/s-2004-829046
45. Daigeler A, Simidjiiska-Belyaeva M, Drucke D, Goertz O, Hirsch T, Soimaru C, et al. The versatility of the pedicled vertical rectus abdominis myocutaneous flap in oncologic patients. *Langenbecks Arch Surg* (2011) **396**(8):1271–9. doi:10.1007/s00423-011-0823-6
46. Rowsell AR, Davies DM, Eisenberg N, Taylor GI. The anatomy of the subscapular-thoracodorsal arterial system: study of 100 cadaver dissections. *Br J Plast Surg* (1984) **37**(4):574–6. doi:10.1016/0007-1226(84)90152-8
47. Rowsell AR, Eisenberg N, Davies DM, Taylor GI. The anatomy of the thoracodorsal artery within the latissimus dorsi muscle. *Br J Plast Surg* (1986) **39**(2):206–9. doi:10.1016/0007-1226(86)90083-4
48. Arnold PG, Lovich SF, Pairolero PC. Muscle flaps in irradiated wounds: an account of 100 consecutive cases. *Plast Reconstr Surg* (1994) **93**(2):324–7. doi:10.1097/00006534-199402000-00016
49. Arnold PG, Pairolero PC. Surgical management of the radiated chest wall. *Plast Reconstr Surg* (1986) **77**(4):605–12. doi:10.1097/00006534-198604000-00016
50. Sauerbier M, Dittler S, Kreutzer C. Microsurgical chest wall reconstruction after oncologic resections. *Semin Plast Surg* (2011) **25**(1):60–9. doi:10.1055/s-0031-1275172
51. Lee AB Jr, Schimert G, Shaktin S, Seigel JH. Total excision of the sternum and thoracic pedicle transposition of the greater omentum; useful strategies in managing severe mediastinal infection following open heart surgery. *Surgery* (1976) **80**(4):433–6.
52. Arnold PG, Witzke DJ, Irons GB, Woods JE. Use of omental transposition flaps for soft-tissue reconstruction. *Ann Plast Surg* (1983) **11**(6):508–12. doi:10.1097/00006537-198312000-00010
53. Hultman CS, Culbertson JH, Jones GE, Losken A, Kumar AV, Carlson GW, et al. Thoracic reconstruction with the omentum:

- indications, complications, and results. *Ann Plast Surg* (2001) **46**(3):242–9. doi:10.1097/0000637-200103000-00007
54. Jurkiewicz MJ, Arnold PG. The omentum: an account of its use in the reconstruction of the chest wall. *Ann Surg* (1977) **185**(5):548–54. doi:10.1097/0000637-197705000-00007
  55. Reichenberger MA, Harenberg PS, Pelzer M, Gazyakan E, Ryssel H, Germann G, et al. Arteriovenous loops in microsurgical free tissue transfer in reconstruction of central sternal defects. *J Thorac Cardiovasc Surg* (2010) **140**(6):1283–7. doi:10.1016/j.jtcvs.2010.05.019
  56. Fischer S, Klinkenberg M, Behr B, Hirsch T, Kremer T, Hernekamp F, et al. Comparison of donor-site morbidity and satisfaction between anterolateral thigh and parascapular free flaps in the same patient. *J Reconstr Microsurg* (2013) **29**(8):537–44. doi:10.1055/s-0033-1351394
  57. Klinkenberg M, Fischer S, Kremer T, Hernekamp F, Lehnhardt M, Daigeler A. Comparison of anterolateral thigh, lateral arm, and parascapular free flaps with regard to donor-site morbidity and aesthetic and functional outcomes. *Plast Reconstr Surg* (2013) **131**(2):293–302. doi:10.1097/PRS.0b013e31827786bc
  58. Meadows JA III, Staats BA, Pairolero PC, Rodarte JR, Arnold PG. Effect of resection of the sternum and manubrium in conjunction with muscle transposition on pulmonary function. *Mayo Clin Proc* (1985) **60**(9):604–9. doi:10.1016/S0025-6196(12)60984-7
  59. Kohman LJ, Auchincloss JH, Gilbert R, Beshara M. Functional results of muscle flap closure for sternal infection. *Ann Thorac Surg* (1991) **52**(1):102–6. doi:10.1016/0003-4975(91)91428-X
  60. Klesius AA, Dzembali O, Simon A, Kleine P, Abdel-Rahman U, Herzog C, et al. Successful treatment of deep sternal infections following open heart surgery by bilateral pectoralis major flaps. *Eur J Cardiothorac Surg* (2004) **25**(2):218–23. doi:10.1016/j.ejcts.2003.11.019
  61. Tukiainen E. Chest wall reconstruction after oncological resections. *Scand J Surg* (2013) **102**(1):9–13. doi:10.1177/145749691310200103
  62. Chapelier A, Macchiarini P, Rietjens M, Lenot B, Margulis A, Petit JY, et al. Chest wall reconstruction following resection of large primary malignant tumors. *Eur J Cardiothorac Surg* (1994) **8**(7):351–6. doi:10.1016/1010-7940(94)90028-0
  63. Walsh GL, Davis BM, Swisher SG, Vaporciyan AA, Smythe WR, Willis-Merriman K, et al. A single-institutional, multidisciplinary approach to primary sarcomas involving the chest wall requiring full-thickness resections. *J Thorac Cardiovasc Surg* (2001) **121**(1):48–60. doi:10.1067/mtc.2001.111381
  64. Levy Faber D, Fadel E, Kolb F, Delaloue S, Mercier O, Mussot S, et al. Outcome of full-thickness chest wall resection for isolated breast cancer recurrence. *Eur J Cardiothorac Surg* (2013) **44**(4):637–42. doi:10.1093/ejcts/ezt105
  65. Saba SC, Shaterian A, Tokin C, Dobke MK, Wallace AM. The pedicled myocutaneous flap as a choice reconstructive technique for immediate adjuvant brachytherapy in sarcoma treatment. *Curr Oncol* (2012) **19**(6):e491–5. doi:10.3747/co.19.1141
  66. Hughes TM, Thomas JM. Sarcoma metastases due to iatrogenic implantation. *Eur J Surg Oncol* (2000) **26**(1):50–2. doi:10.1053/ejso.1999.0740

**Conflict of Interest Statement:** The authors declare that the research was conducted in the absence of any commercial or financial relationships that could be construed as a potential conflict of interest.

Copyright © 2015 Harati, Kolbenschlag, Behr, Goertz, Hirsch, Kapalschinski, Ring, Lehnhardt and Daigeler. This is an open-access article distributed under the terms of the Creative Commons Attribution License (CC BY). The use, distribution or reproduction in other forums is permitted, provided the original author(s) or licensor are credited and that the original publication in this journal is cited, in accordance with accepted academic practice. No use, distribution or reproduction is permitted which does not comply with these terms.



# Reconstructive Options for Oncologic Posterior Trunk Defects: A Review

Björn Behr\*, Johannes M. Wagner, Christoph Wallner, Kamran Harati, Marcus Lehnhardt and Adrien Daigeler

Department of Plastic Surgery, BG University Hospital Bergmannsheil Bochum, Bochum, Germany

## OPEN ACCESS

### Edited by:

Russell Scott Berman,  
NYU School of Medicine, USA

### Reviewed by:

Ernest S. Chiu,  
NYU Langone Medical Center, USA  
Alexes Hazen,  
NYU Langone Medical Center, USA

### \*Correspondence:

Björn Behr  
bjorn.behr@rub.de

### Specialty section:

This article was submitted to  
Surgical Oncology,  
a section of the journal  
Frontiers in Oncology

Received: 06 July 2015

Accepted: 22 February 2016

Published: 07 March 2016

### Citation:

Behr B, Wagner JM, Wallner C,  
Harati K, Lehnhardt M and Daigeler A  
(2016) Reconstructive Options for  
Oncologic Posterior Trunk Defects:  
A Review.  
Front. Oncol. 6:51.  
doi: 10.3389/fonc.2016.00051

After oncological tumor resections at the back, large defects can remain that depending on the size and location may represent reconstructive challenges to plastic surgeons. Flap selection includes the entire armamentarium of coverage, including transposition flaps, perforator flaps, pedicled muscle flaps, and free flaps. Most defects can be closed and reconstructed with local or pedicled muscle flaps. In our hands, sufficient closure could be obtained with all techniques, except the latissimus dorsi turn-over flap. Thereupon, an algorithm for closure of posterior trunk defects related to the anatomical region is proposed.

**Keywords:** plastic surgery, posterior trunk, back, reconstruction, flap

## INTRODUCTION

Soft-tissue defects of the posterior trunk may represent challenges for reconstructive surgeons. Reasons include shortages of both, reliable axial pattern flaps for local tissue transfer and recipient vessels for microsurgical reconstruction (1). Upon the various causes such as trauma, congenital malformations, spine surgery, or radiation ulcers, malignant skin or soft-tissue tumors may also put the back at risk for soft-tissue defects. At first, general surgical principles such as proper debridement and adequate preparation of the wound have to be performed. Depending on the characteristics of the tumor, single-stage or sequential operations may be indicated. Eventually, vacuum-assisted wound conditioning may be performed. In case, spinous processes are exposed, they may be readily removed in order to avoid any perforations or subsequent pressure sores after soft-tissue coverage. Besides therapeutic concepts such as secondary healing or skin grafts may only be of partial benefit to these patients (2). Given the relative lack of elasticity as well as a shortage of potential microsurgical recipient vessels, the back offers special challenges to the reconstructive surgeon (3). Nevertheless, the dorsal trunk hosts several muscles that may be transferred as pedicled flaps such as M. latissimus dorsi or M. trapezius flaps. A popular fasciocutaneous option is the parascapular flap; though given their cephalic pedicle, they are not useful for reconstruction of the lower back. Moreover in selected cases, free flaps with vein grafts or loops may be utilized. More recent trends involve the application of fasciocutaneous perforator flaps since the posterior trunk involves abundant perforators. Of note, the concept of perforator-based soft-tissue reconstruction was first described for defect coverage at the back (4). This article describes and illustrates the different soft-tissue reconstruction techniques for the posterior trunk.



## TRANSPOSITION PATTERN AND PERFORATOR FLAPS

Given the large area and abundance of perforating vessels in the posterior trunk, this anatomic region offers multiple options for plastic-surgical reconstruction by means of random pattern and especially perforator flaps (5). If established principles such as a proper width-length ratio in random-pattern flaps, as well as the right angiosome size in perforator flaps are considered, these flaps are safe and can cover many defects that occur (**Figure 1**). It has to be stressed though that utilization of these flaps is highly dependent on the quality of the surrounding tissue, which might be compromised due to radiation or scarring. However, with these techniques, the underlying muscles are conserved and may be utilized in later reconstructions, if necessary. For the operative planning, a handheld Doppler or power Doppler to track the route of the perforator vessel is advisable. Moreover, combination of both techniques is possible. For instance, a perforator can be integrated into a transposition flap in order to design it larger and safer.

Options for pedicled fasciocutaneous flaps at the back include parascapular and scapular flaps. These flaps are supplied by the circumflex scapular artery and can cover defects of upper- and mid-thoracic area of the back. Similar as in a free flap procedure, the pedicle can be dissected up to the level of the subscapular artery and vein; however, this is rarely necessary. Dimensions of parascapular flaps can reach up to 15 cm × 40 cm; therefore, they can be considered larger than scapular flaps.

Moreover, gluteal perforator flaps can be useful in coverage of sacral defects (6). For instance, the *superior gluteal artery flap* (S-GAP) can be dissected without major damages to the gluteus maximus muscle (**Figure 2**). Finally, lumbar- or

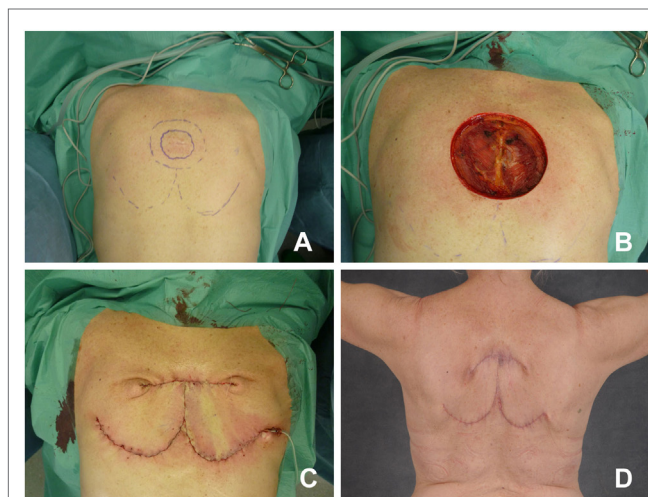
intercostal artery-based perforator flaps may be utilized in this anatomical region (7).

## SUPRACLAVICULAR FLAPS

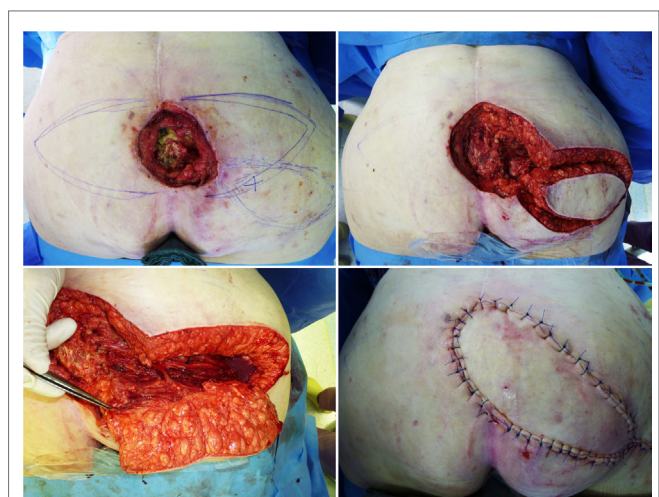
Supraclavicular flaps that can also be raised as island flaps represent an interesting fasciocutaneous option for soft-tissue coverage of the dorsal neck region. As indicated by its name, it is raised from the supraclavicular region based on the transverse cervical artery and has dimensions up to 22 cm in length and 10 cm in width (8). Even in complicated surgical conditions, these flaps can provide reliable defect coverage in the anterior and posterior neck region (9).

## TRAPEZIUS FLAP

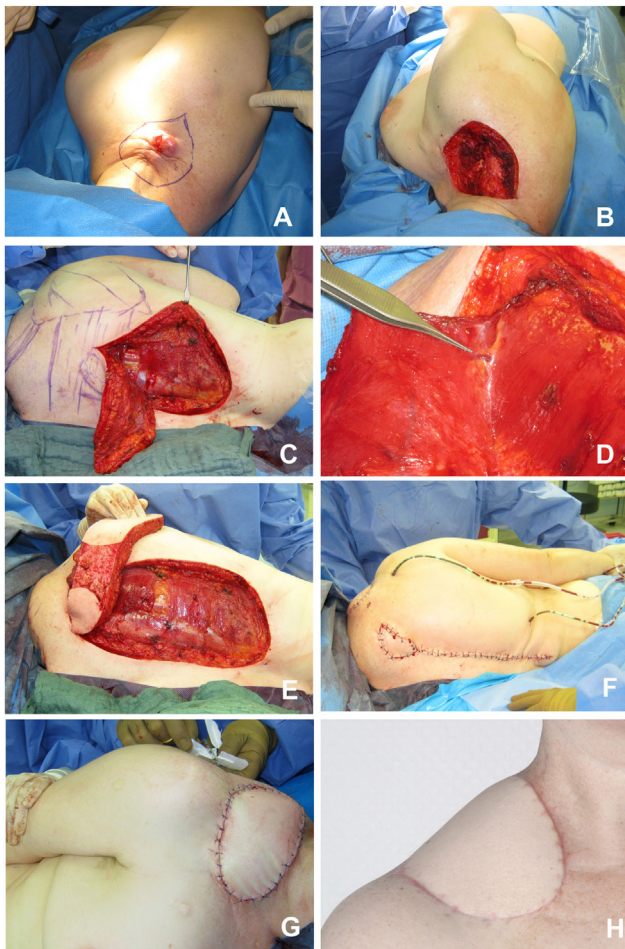
The trapezius muscle, the superficial muscle of the neck and upper-thoracic region is an excellent option to cover defects in the upper thorax and neck region (10). It is traditionally considered a class 2 muscle according to (11) (one dominant and several minor vascular pedicles), although others have noted two dominant vessels for separate portions of the muscle. The inferior part of the trapezius muscle is supplied by the dorsal scapular artery (a deep branch of the cervical artery), whereas the transverse part is supplied by the superficial cervical artery. It extends from the external occipital protuberans to the 12th thoracic spine. It is up to 34 cm × 18 cm in size and can be dissected as a muscle-only or myocutaneous flap. The muscle can be dissected from caudal to cephalic and can be rotated into defects of the upper posterior trunk and dorsal neck. Moreover, they can be utilized as advancement flaps or turn-over flaps (**Figure 3**) (12, 13). In that respect, it has to be emphasized that good results can be obtained when the skin island does not exceed the muscle for more than 1 cm (14).



**FIGURE 1 | Bilateral rotation flap.** (A) Patient with dermatofibrosarcoma protuberans at the upper thorax. Preoperative markings, two bilateral rotational flaps are planned from caudal. (B) Intraoperative status after resection. (C) Status after rotation of the flaps and wound closure. (D) Postoperative result.



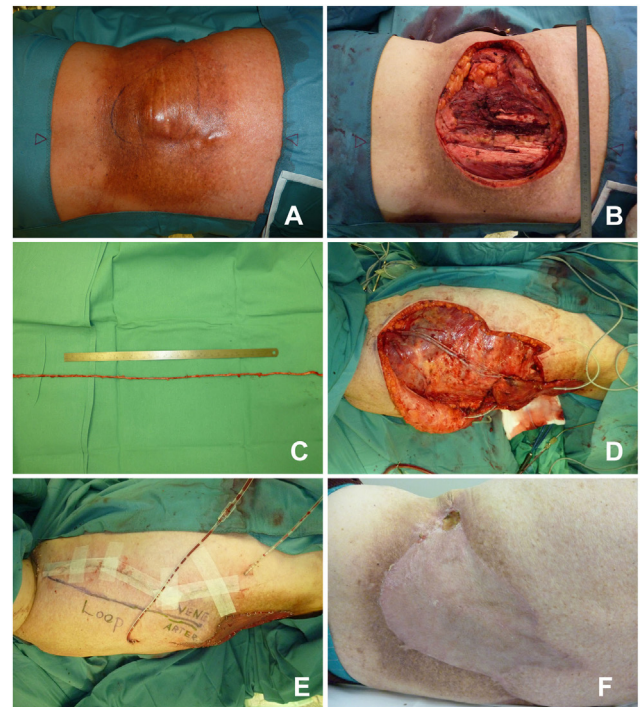
**FIGURE 2 | S-GAP perforator flap for coverage of the sacrum.** (A) Status after debridement and planning of the flap. (B) Flap before rotation. (C) Identification and preparation of the perforator. (D) Postoperative result.



**FIGURE 3 | Trapezius flap for coverage of the right shoulder.** (A) Cutaneous metastasis of breast cancer at the right shoulder. (B) Status after resection. (C) Preparation of the myocutaneous trapezius muscle from caudal to cephalic. (D) Identification of the deep branch of the cervical artery and vein. (E) Transposition of the myocutaneous flap. (F,G) Intraoperative insert of the flap. (H) Postoperative result.

## LATISSIMUS DORSI FLAP

The latissimus dorsi muscle flaps offers great variety and options to cover large defects in the mid-thoracic and upper-thoracic posterior trunk. It can be raised up to 30 cm × 40 cm in size and may be transferred as a muscular (eventually with additional skin grafts) or myocutaneous flap. The latter option makes postoperative monitoring considerably easier. It originates at the thoracal spinous processes, inferior ribs, and iliac crest. The latissimus dorsi muscle inserts at the intertubercular groove of the humerus. Its dominant vascular pedicle is the thoracodorsal artery, which is part of the scapular vascular system, whereas the non-dominant pedicles originate from intercostal and lumbar arteries. It is therefore a class 5 muscle according to the popular classification of Mathes and Nahai; thus, survival of the flap may also be based on the non-dominant pedicles (15), which would allow utilization of this flap as a “reverse” flap in order to cover contralateral or more



**FIGURE 4 | Latissimus dorsi flap with vein transposition.** (A) NOS sarcoma in the left lumbar region. (B) Resected tumor. (C) Great saphenous vein graft with 30 cm ruler for comparison purposes. (D) Latissimus dorsi muscle transferred with two interposed veins. (E) Operative situs after skin closure. (F) Postoperative result.

caudal defects. However, in certain instances such as previous spinal surgery, these lumbar perforators may not exist anymore; hence, preoperative Doppler control is highly suggested in these instances. In our experience, the reverse latissimus dorsi muscle produced inconsistent results; therefore, it is no longer part of our armamentarium. An alternative for more caudal defects is the transposition of vein grafts to increase the reach of latissimus dorsi muscle flaps (Figure 4) (16).

## PARASPINOUS MUSCLE FLAP

An additional option for small defects in the paravertebral region is the paraspinous muscle flap (17). Paraspinous muscles are located in the lumbar region up to the 10th thoracic vertebrae and are typically utilized as bipediced turn-over flaps. Muscles are dissected off the transverse processes of the vertebrae and advanced medially; thus, wound in the perivertebral region can be closed with two pedicled paraspinous flaps.

## PULL-THROUGH VRAM-FLAPS

In certain conditions, such as sacral wound coverage after abdominoperineal resection, pull-through vertical rectus abdominis muscle (VRAM) flaps may be utilized (18). Here, the



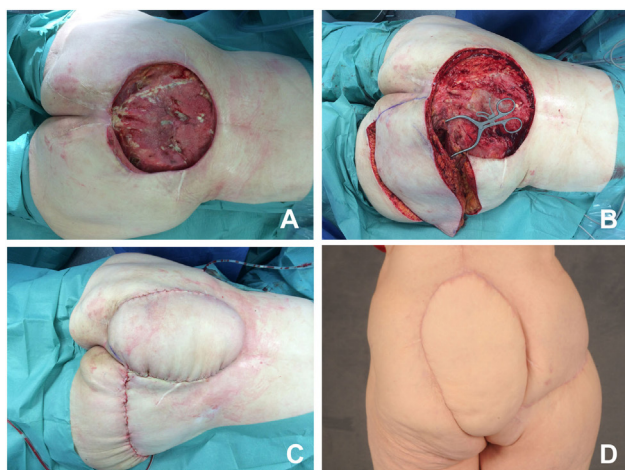
rectus abdominis muscle is pedicled on the inferior epigastric artery and the flap (muscle including skin island) is transpelvically pulled through to the sacrum.

## GLUTEUS MAXIMUS FLAP

Besides utilization of gluteal perforator flaps, defects in the sacral region can likewise be reconstructed with the gluteus maximus muscle flap (Figure 5). This is a type 3 muscle with two dominant pedicles (superior and inferior gluteal arteries). Especially, the superior gluteal artery is a useful pedicle for the advancement or turn-over gluteus maximus muscle flaps for sacral defects (19).

## MICROSURGERY AND OPTIONS FOR RECIPIENT VESSELS

In rare instances where defects of the posterior trunk can not be managed by local or pedicled flaps, microvascular free flaps have to be utilized. Although there are virtually no limits in terms of potential donor sites in the selection of free flaps, the actual choice for recipient vessels might prove to be challenging. One potential recipient vessel is the superior gluteal artery at the buttock (20). Moreover, microvascular free flaps may also be anastomosed to the fourth lumbar artery, lateral of the sacrospinal muscle (Figure 6). In case these options are not feasible, transpositions of vein grafts are necessary. Few et al. have reported about their experience in the “hostile” back, defined as a defect larger than 200 cm<sup>2</sup> in size, previous radiation therapy, fulminant infections, or exposed hardware (21). In four of their patients, defects were closed with free latissimus dorsi flaps or VRAM flap with interposition of vein grafts. For this purpose, the great saphenous vein may be readily utilized. Of note, there is no need to reposition the patient intraoperatively when operating latissimus dorsi flaps with vein grafts.



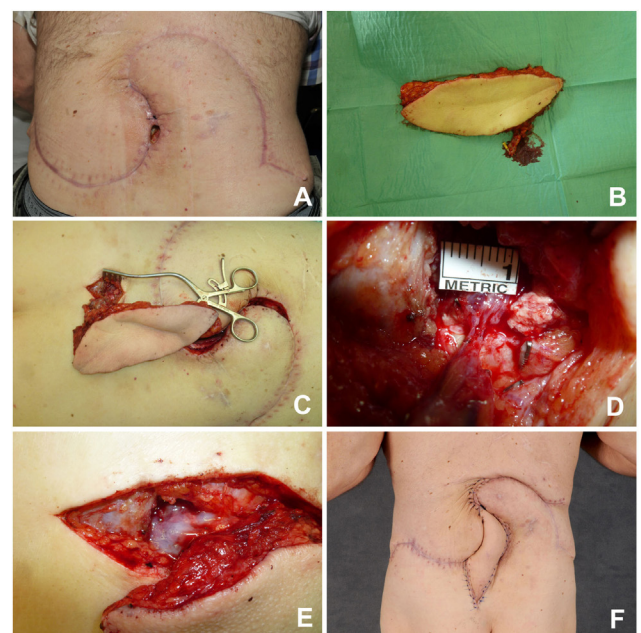
**FIGURE 5 | Gluteus maximus flap.** (A) Large defect in the sacral region. (B) Myocutaneous gluteus maximus flap before transposition. (C) Operative situs after skin closure. (D) Postoperative result.

## SPECIAL CONSIDERATIONS

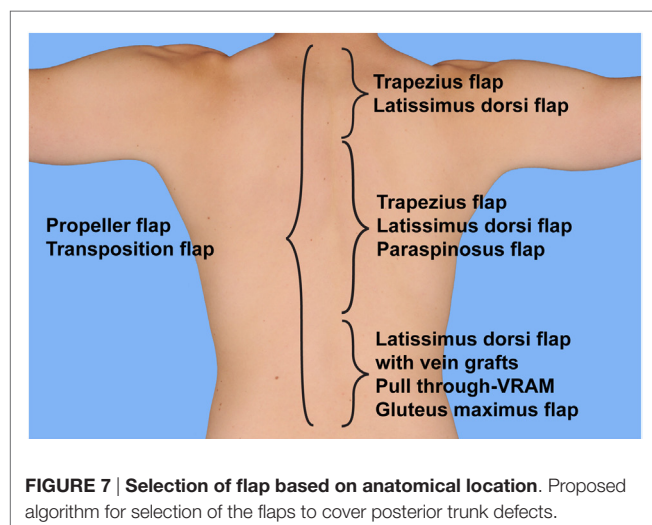
When operating at the posterior trunk, there are a couple of obstacles to consider, which should be taken into consideration preoperatively. For instance, leakage of cerebrospinal fluid should prompt an interdisciplinary approach with neurosurgery to adequately reconstruct the dura. Another problem that may be encountered is exposed spinal hardware. In case fusion is noted on CT-scans, the hardware may be removed; however, in all other patients, instruments may remain *in situ* (22, 23). Finally as previously noted, radiation of the defect area in the medical history may further bedevil the situation and preclude local tissue transfer. Importantly, ulcers in these radiated areas may contain neoplastic processes, such as squamous cell carcinoma, which should be histologically excluded.

## APPROACH FOR SELECTION OF THE FLAP RELATED TO THE ANATOMIC REGION

Related to the anatomic region, several flaps have proven to be of value in reconstructing the defect. It goes without saying that the flap selection has to be adjusted to the encountered situation, surrounding tissue, and abilities and experience of the surgeon. The proposed algorithm therefore provides a rough guideline that needs to be adapted. Supposing high quality tissue in the vicinity, closure of small defects is possible with transposition or propellerflaps in all regions of the posterior trunk. In addition,



**FIGURE 6 | Fasciocutaneous infragluteal free flap (FCI).** (A) Remaining lumbar defect after two rotational flaps. (B) FCI flap with pedicle. (C) Anastomosis of the flap to a lumbosacral perforator. (D) Close-up view, revealing the small caliber of the recipient vessel. (E) Fibrin glue protection of the pedicle. (F) Early postoperative result.



**TABLE 1 | Options for posterior trunk defects related to the anatomic region.**

Upper defects	Propeller-/transposition flaps Trapezius flap Latissimus dorsi flap
Middle defects	Propeller-/transposition flaps Trapezius flap Latissimus dorsi flap Paraspinosus flap
Lower defects	Propeller-/transposition flaps Latissimus dorsi flap with vein grafts Pull-through VRAM Gluteus maximus flap Free flap

the following flaps may be utilized (likewise in combination) according to the anatomic region (Figure 7; Table 1).

## Upper Defects

Given the high traction forces in the neck and shoulder region, soft-tissue reconstruction may be challenging. The majority of

defects may be closed with trapezius flaps. In case the trapezius muscle is damaged or absent due to previous surgery, defects in that region may also be treated with a latissimus dorsi flap.

## Middle Defects

In the upper-thoracic region, defect coverage is possible with both, the latissimus dorsi and trapezius flap. Given the great reliability and our substantial experience, we prefer working with the latissimus dorsi flap, if possible. Both flaps can be dissected as a muscle-only flap or myocutaneous flap. If the defect requires coverage of larger areas, they might also be combined.

## Lower Defects

In the thoracolumbar and lumbar region, therapeutic options are often more complex. The extend of the latissimus dorsi flap is insufficient to reach the defect and may only be of value if combined with interposition of vein grafts, although the patient has to be in the prone position or air-fluidized bed in the early postoperative phase. According to our experience, we advise against latissimus dorsi turn-over flaps. An alternative option is provided with the pull-through VRAM in the sacral region. Additional therapeutic options are represented by paraspinosus muscle flaps, gluteus maximus flaps, and microvascular free flaps, anastomosed to perforators, the superior gluteal arteries, or elongated with vein grafts.

## SUMMARY

Given the special anatomy with few options for microvascular recipient vessel, soft-tissue defects at the posterior trunk may represent a challenge to reconstructive surgery. However, the majority of defects can be closed with pedicled flaps. If basic surgical principles such as radical debridement and removal of infected hardware are followed, good reconstructive results may be obtained with the presented methods.

## AUTHOR CONTRIBUTIONS

All authors listed, have made substantial, direct, and intellectual contribution to the work, and approved it for publication.

## REFERENCES

- Behr B, Hirsch T, Goertz O, Ring A, Lehnhardt M, Daigeler A. [Therapeutic options for reconstruction of the dorsal trunk wall]. *Handchir Mikrochir Plast Chir* (2014) **46**(2):90–6. doi:10.1055/s-0034-1370994
- Hallock GG. Reconstruction of posterior trunk defects. *Semin Plast Surg* (2011) **25**(1):78–85. doi:10.1055/s-0031-1275174
- Mathes DW, Thornton JF, Rohrich RJ. Management of posterior trunk defects. *Plast Reconstr Surg* (2006) **118**(3):73e–83e. doi:10.1097/01.prs.0000233130.93861.15
- Kroll SS, Rosenfield L. Perforator-based flaps for low posterior midline defects. *Plast Reconstr Surg* (1988) **81**(4):561–6. doi:10.1097/00006534-198804000-00012
- Hamdi M, Stillaert FB. Pedicled perforator flaps in the trunk. *Clin Plast Surg* (2010) **37**(4):655–65. doi:10.1016/j.cps.2010.06.004
- Koshima I, Moriguchi T, Soeda S, Kawata S, Ohta S, Ikeda A. The gluteal perforator-based flap for repair of sacral pressure sores. *Plast Reconstr Surg* (1993) **91**(4):678–83. doi:10.1097/00006534-199304000-00017
- Roche NA, Van Landuyt K, Blondeel PN, Matton G, Monstrey SJ. The use of pedicled perforator flaps for reconstruction of lumbosacral defects. *Ann Plast Surg* (2000) **45**(1):7–14. doi:10.1097/00006534-2000045010-00002
- Pallua N, Magnus Noah E. The tunneled supraclavicular island flap: an optimized technique for head and neck reconstruction. *Plast Reconstr Surg* (2000) **105**(3):842–51. doi:10.1097/00006534-200003000-00003
- Su T, Pargousis P, Fernandes R. Versatility of supraclavicular artery island flap in head and neck reconstruction of vessel-depleted and difficult necks. *J Oral Maxillofac Surg* (2013) **71**(3):622–7. doi:10.1016/j.joms.2012.07.005

10. Ramasastry SS, Schlechter B, Cohen M. Reconstruction of posterior trunk defects. *Clin Plast Surg* (1995) **22**(1):167–85.
11. Mathes SJ, Nahai F. *Reconstructive Surgery: Principles, Anatomy and Technique*. Edinburgh: Churchill Livingstone (1997).
12. Mathes SJ, Stevenson TR. Reconstruction of posterior neck and skull with vertical trapezius musculocutaneous flap. *Am J Surg* (1988) **156**(4):248–51. doi:10.1016/S0002-9610(88)80284-8
13. Disa JJ, Smith AW, Bilsky MH. Management of radiated reoperative wounds of the cervicothoracic spine: the role of the trapezius turnover flap. *Ann Plast Surg* (2001) **47**(4):394–7. doi:10.1097/0000637-200110000-00006
14. Chun JK, Lynch MJ, Poultides GA. Distal trapezius musculocutaneous flap for upper thoracic back wounds associated with spinal instrumentation and radiation. *Ann Plast Surg* (2003) **51**(1):17–22. doi:10.1097/01.SAP.0000054242.00928.06
15. Stevenson TR, Rohrich RJ, Pollock RA, Dingman RO, Bostwick J III. More experience with the “reverse” latissimus dorsi musculocutaneous flap: precise location of blood supply. *Plast Reconstr Surg* (1984) **74**(2):237–43. doi:10.1097/00006534-198408000-00011
16. Hallock GG. An extended latissimus dorsi “non-free” flap. *Br J Plast Surg* (1987) **40**(5):516–7. doi:10.1016/S0007-1226(87)90085-3
17. Wilhelmi BJ, Snyder N, Colquhoun T, Hadjipavlou A, Phillips LG. Bipedicle paraspinous muscle flaps for spinal wound closure: an anatomic and clinical study. *Plast Reconstr Surg* (2000) **106**(6):1305–11. doi:10.1097/00006534-200011000-00011
18. Daigeler A, Simidjiiska-Belyaeva M, Drucke D, Goertz O, Hirsch T, Soimarur C, et al. The versatility of the pedicled vertical rectus abdominis myocutaneous flap in oncologic patients. *Langenbecks Arch Surg* (2011) **396**(8):1271–9. doi:10.1007/s00423-011-0823-6
19. Koh PK, Tan BK, Hong SW, Tan MH, Tay AG, Song C, et al. The gluteus maximus muscle flap for reconstruction of sacral chordoma defects. *Ann Plast Surg* (2004) **53**(1):44–9. doi:10.1097/01.sap.0000106423.87203.a3
20. Park S, Koh KS. Superior gluteal vessel as recipient for free flap reconstruction of lumbosacral defect. *Plast Reconstr Surg* (1998) **101**(7):1842–9. doi:10.1097/00006534-199806000-00010
21. Few JW, Marcus JR, Lee MJ, Ondra S, Dumanian GA. Treatment of hostile midline back wounds: an extreme approach. *Plast Reconstr Surg* (2000) **105**(7):2448–51. doi:10.1097/00006534-200006000-00022
22. Garvey PB, Rhines LD, Dong W, Chang DW. Immediate soft-tissue reconstruction for complex defects of the spine following surgery for spinal neoplasms. *Plast Reconstr Surg* (2010) **125**(5):1460–6. doi:10.1097/PRS.0b013e3181d5125e
23. Weinstein MA, McCabe JP, Cammisa FP Jr. Postoperative spinal wound infection: a review of 2,391 consecutive index procedures. *J Spinal Disord* (2000) **13**(5):422–6. doi:10.1097/00002517-200010000-00009

**Conflict of Interest Statement:** The authors declare that the research was conducted in the absence of any commercial or financial relationships that could be construed as a potential conflict of interest.

The reviewers (EC and AH) and handling Editor (RB) declared their shared affiliation, and the handling Editor states that the process nevertheless met the standards of a fair and objective review.

Copyright © 2016 Behr, Wagner, Wallner, Harati, Lehnhardt and Daigeler. This is an open-access article distributed under the terms of the Creative Commons Attribution License (CC BY). The use, distribution or reproduction in other forums is permitted, provided the original author(s) or licensor are credited and that the original publication in this journal is cited, in accordance with accepted academic practice. No use, distribution or reproduction is permitted which does not comply with these terms.





# Plastic and reconstructive surgery in the treatment of oncological perineal and genital defects

Rebekka Brodbeck, Raymund E. Horch, Andreas Arkudas and Justus P. Beier\*

Department of Plastic and Hand Surgery, University Hospital of Erlangen, Friedrich-Alexander-University Erlangen-Nuernberg, Erlangen, Germany

## OPEN ACCESS

### Edited by:

Björn Behr,  
Ruhr University Bochum, Germany

### Reviewed by:

Ziv Radisavljevic,  
Brigham and Women's Hospital, USA  
Paul Willemsen,  
ZNA, Belgium

### \*Correspondence:

Justus P. Beier,  
Department of Plastic and Hand  
Surgery, University Hospital of  
Erlangen, Friedrich-Alexander-  
University Erlangen-Nuernberg,  
Erlangen, Germany  
justus.beier@uk-erlangen.de

### Specialty section:

This article was submitted to Surgical  
Oncology, a section of the  
journal *Frontiers in Oncology*

**Received:** 18 June 2015

**Accepted:** 17 September 2015

**Published:** 08 October 2015

### Citation:

Brodbeck R, Horch RE, Arkudas A  
and Beier JP (2015) Plastic and  
reconstructive surgery in the  
treatment of oncological perineal and  
genital defects.  
*Front. Oncol.* 5:212.  
doi: 10.3389/fonc.2015.00212

Defects of the perineum may result from ablative procedures of different malignancies. The evolution of more radical excisional surgery techniques resulted in an increase in large defects of the perineum. The perineogenital region *per se* has many different functions for urination, bowel evacuation, sexuality, and reproduction. Up-to-date individual and interdisciplinary surgical treatment concepts are necessary to provide optimum oncological as well as quality of life outcome. Not only the reconstructive method but also the timing of the reconstruction is crucial. In cases of postresectional exposition of e.g., pelvic or femoral vessels or intrapelvic and intra-abdominal organs, simultaneous flap procedure is mandatory. In particular, the reconstructive armamentarium of the plastic surgeon should include not only pedicled flaps but also free microsurgical flaps so that no compromise in terms of the extent of the oncological resection has to be accepted. For intra-abdominally and/or pelvic tumors of the rectum, the anus, or the female reproductive system, which were resected through an abdominally and a sacrally surgical access, simultaneous vertical rectus abdominis myocutaneous (VRAM) flap reconstruction is recommendable. In terms of soft tissue sarcoma of the pelvic/caudal abdomen/proximal thigh region, two-stage reconstructions are possible. This review focuses on the treatment of perineum, genitals, and pelvic floor defects after resection of malignant tumors, giving a distinct overview of the different types of defects faced in this region and describing a number of reconstructive techniques, especially VRAM flap and pedicled flaps like antero-lateral thigh flap or free flaps. Finally, this review outlines some considerations concerning timing of the different operative steps.

**Keywords:** interdisciplinary surgery, exenteration, VRAM flap, perineal reconstruction, microsurgical free flap

## Introduction

Defects of the perineum usually result from ablative procedures of different malignancies, such as gynecological (cervix, vagina, endometrial), urological (urinary bladder, prostate), and colorectal (anal and rectal carcinoma) tumors. The evolution of more radical excisional surgery techniques resulted in an increase in large defects of the perineum (1). The perineogenital region *per se* has many different functions for urination, bowel evacuation, sexuality, and reproduction (2), so extensive resection in this region results often in functional deficits.

Pelvic surgery is characterized by a complex anatomy, involvement of different organs and microbial environment of this region. Plastic-reconstructive measures like simultaneously used

skin grafts, pedicled, or free flaps avoid different complications or reduce their incidence, such as chronic wound healing disorders and chronic secretion of intrapelvic or peritoneal wound cavities (3, 4). For locally advanced primary or recurrent rectal cancer invading the urine bladder or prostate, pelvic exenteration is often the only treatment, with is potentially curative (5–7). Radical surgery completely resects all malignant disease, often including the complete or at least large parts of pelvic viscera, vessels, muscles, ligaments, or pelvic bone. In modern concepts of advanced oncological surgery, survival is not the only consideration; quality of life has to be taken into account (8). Up-to-date individual and interdisciplinary surgical treatment concepts are necessary to provide optimum oncological as well as quality of life outcome (3, 9).

This review focuses on the treatment of perineum, genitals, and pelvic floor defects after resection of malignant tumors, giving a distinct overview of the different types of defects faced in this region and describing a number of reconstructive techniques. Finally, this review outlines some considerations concerning timing of the different operative steps.

Literature about pelvic reconstruction in particular is very rare and review articles or larger case series are absent, hence only case reports have been published. There is only scarce literature with sufficient evidence on this topic, apart from some single case reports and a few case series, this will be critically discussed in the following review.

## Pelvic Region: Extra- and Intrapelvic Tumors

In the pelvic and the inguinal/proximal femoral region, there are essentially two various tumor entities to discuss. Their anatomical localization and extension require very different treatment concepts. In course of this, both initial multidisciplinary team approach and form of reconstructive measures have been adapted to it (3, 8). On the one hand, there are mainly intra-abdominal and pelvic tumors, which are mostly low rectal carcinomas and deep infiltrating anal carcinomas (10), as well as far advanced gynecological tumors [e.g., vulval cancer (11) or cervix cancer (3)]. On the other hand, there are soft tissue sarcomas of the pelvis, the caudal abdomen, and the proximal femoral region (12).

Despite this, there are many other indications, like congenital defects, infections, trauma, lymphedema, and other uncommon problems, e.g., transsexuality (2) requiring reconstructive surgery in the pelvic region, which are not subject of this review.

Different reconstruction methods are available for the above-mentioned malignancies. An overview of the most common pedicled (Table 1) and free flaps (Table 2) for reconstruction of the perigenital region is shown in Tables 1 and 2.

In most of the cases, primary closure of perineal defects is not possible. Skin grafts are suboptimal in the perigenital area due high bacterial load in this region, frequently leading to graft loss, prolonged healing resulting in unsatisfactory scar quality and contractures that may affect urination or coitus (14). Over the past decades, flap reconstruction has replaced these techniques in the vast majority of cases. An ideal flap should provide soft-tissue volume to close dead space in pelvis and the skin island should

**TABLE 1 | The most useful pedicled flaps for defect reconstruction of the pelvic region [modification of Beier et al. (3) and Das Gupta et al. (13)].**

Pedicled flaps	Vascular supply	Region of defect reconstruction
Gluteus muscle flap	Superior gluteal artery/inferior gluteal artery	Sacral
SGAP/IGAP flap	Superior/inferior gluteal artery perforator	Sacral
TRAM flap	Inferior epigastric artery	Pelvic floor
VRAM flap	Inferior epigastric artery	Pelvic floor
Groin flap	Medial circumflex femoral artery/superficial circumflex iliac artery	Perineal
SCIP flap	Superficial circumflex iliac artery perforator	Inguinal
Gracilis muscle flap	Medial circumflex femoral artery	Perineal
Pudendal flap	External pudendal artery	Perineal
Tensor fasciae latae flap	Lateral circumflex femoral artery	Perineal
Rectus femoris muscle flap	Lateral circumflex femoral artery	Ischial
Vastus lateralis muscle flap	Lateral circumflex femoral artery	Ischial/Perineal

SGAP, superior gluteal artery perforator; IGAP, inferior gluteal artery perforator; TRAM, transversal rectus abdominis myocutaneous flap; VRAM, vertical rectus abdominis myocutaneous flap; SCIP, superficial circumflex iliac artery perforator.

**TABLE 2 | The most useful microsurgical free flaps for defect reconstruction of the pelvic region [modification of Beier et al. (3) and Das Gupta et al. (13)].**

Vascular system	Microsurgical free flaps
Subscapularis artery	Latissimus dorsi muscle flap (thoracodorsal artery) Scapular/Parascapular flap (circumflex scapula artery) Serratus anterior muscle flap (serratus branch of thoracodorsal artery) Combinations
Inferior epigastric artery	Vertical rectus abdominis myocutaneous (VRAM) flap expanded VRAM Transversal rectus abdominis myocutaneous (TRAM) flap or deep inferior epigastric perforator (DIEP) flap
Lateral circumflex femoral artery	Antero-lateral thigh (ALT) flap (descending branch) Tensor fasciae latae (TFL) flap (ascending branch) Combinations with rectus femoral muscle, lateral vastus muscle, etc.

replace resected perineal skin (15). These flaps will be described and discussed in detail for the two different groups of malignancies in the pelvic regions in the following paragraph.

## Plastic-Reconstructive Measures of Rectal and Anal Carcinomas

Modern treatment of rectal and anal carcinomas includes a multimodal therapy concept. Preoperative neoadjuvant radio-chemotherapy has become standard treatment for rectal cancer and has been shown to downstage tumors (15, 16), before radical aggressive surgery is applied to achieve a lasting cure (8, 17). Despite the concept that multidisciplinary team approach is

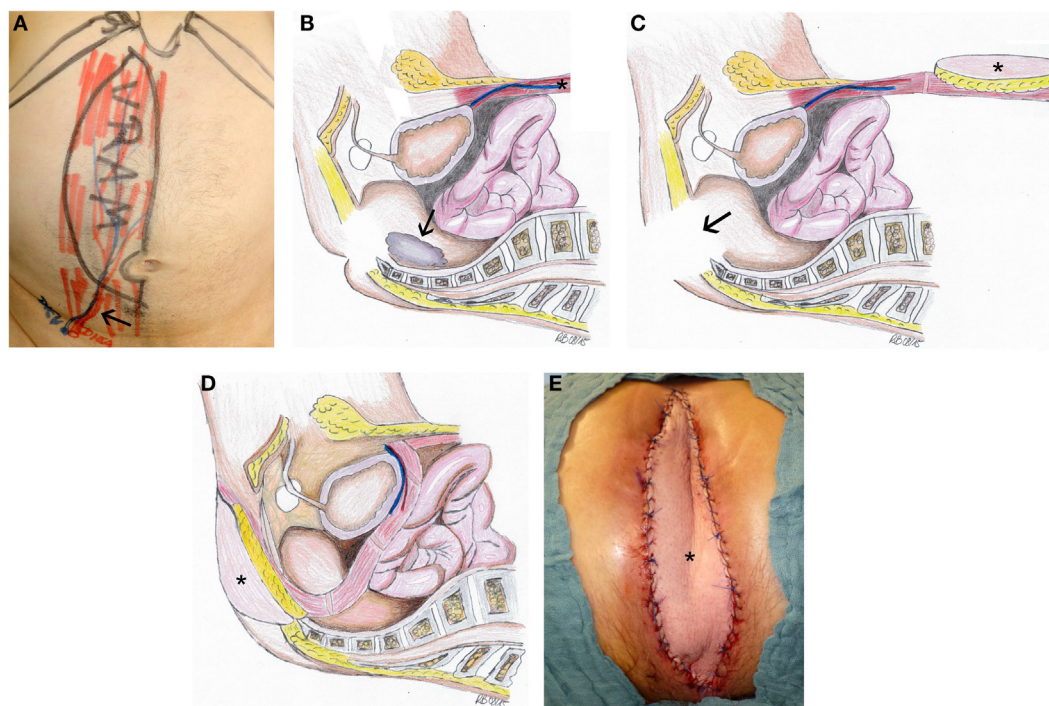
identically for both entities, the surgical therapy concept itself is very different, associated with the plastic-reconstructive possibilities (3).

For intra-abdominal and/or pelvic tumors of the rectum, the anus or the female reproductive system, which were resected through an abdominal and a perineal surgical access (18), simultaneous flap reconstruction is recommendable. The goal is not only a perineal and/or sacral defect reconstruction but also an intrapelvic sealing, as well as a vaginal partial reconstruction if necessary; both is facilitated by the vertical rectus abdominis myocutaneous (VRAM) flap (**Figure 1**) (8, 13, 19). To achieve an oncological safe situation, aggressive surgery must be implemented and performing pelvic exenteration with “en bloc” resection of multiple pelvic structures is necessary (8, 9, 18). After abdominoperineal extirpation, often a large intrapelvic cavity remains, perineal wound complications including wound dehiscence and longtime of secretion occur, even according to radiotherapy. Studies have shown that the VRAM flap is a reliable and safe method for pelvic reconstruction in patients with advanced disease requiring pelvic exenteration and radiation, with relatively low rate of donor and recipient site complications (20–22).

During the last years, important advances in generation of vascularized tissue engineering have been achieved (23).

However, until today flap surgery still remains the gold standard for plastic-reconstructive treatment of oncological defects (24). The immediately/simultaneously used transpelvic VRAM flap has several advantages: first of all, the VRAM flap is a very safe and robust flap and relatively easy to technical perform, when necessary plastic-reconstructive expertise exists. Furthermore, the vascular supply of the deep inferior epigastric vessel is constant. Using the VRAM flap as a transpelvic flap not only allows reconstruction of perineal and perigenital skin defects, but also enables obliteration of the sacral cavity (22, 25, 26). Principally, alloplastic and biological matrices have also been used to avoid a herniation of the small bowel, but these techniques are correlated with a significant risk for foreign body reaction, and are prone to infections and formation of chronic fistula, especially if non-absorbable matrices have been used in a radiated field (27, 28). Furthermore, a vascularized muscle flap can reliably fill dead space in the pelvis and can even help to cure local infection (29).

Vertical rectus abdominis myocutaneous flap can also be used for reconstruction of the vagina, when part of the vagina are infiltrated by the tumor and need to be excised. Therefore, the unilateral caudally pedicled VRAM flap can reconstruct half of circumference of the vagina (8). Moreover, vaginal fistula



**FIGURE 1 | Defect reconstruction after resection of a rectal carcinoma using VRAM flap illustrated by intraoperative photographs and schematic drawings of the surgical technique. (A)** Preoperative marking for VRAM-flap procedure with the planned skin paddle and location of the ostomy performed on the day before surgery. Black arrow marks the flap pedicle. **(B)** The operation involves a two-part procedure with an anterior abdominal dissection first, which is followed by a second step with perineal tumor excision (black arrow) in prone position. We first ensure the viability of the deep inferior epigastric vessels before we proceed with the flap raising. The design of the flap and the size of the skin paddle are then planned according to the prospective perineal and pelvic defect. The skin island is placed vertically over the rectus muscle. The rectus muscle is dissected cranially from the costal arch. In the prone phase, tumor excision (black arrow) had been completed **(C)**. The flap (black asterisk) is then flipped and rotated at 180° into the pelvic cavity so that the skin paddle closes the defect **(D)**. Intraoperative view with VRAM flap (black asterisk) inserted to reconstruct perineal defect **(E)**.



development can be avoided, because of the sealing effect and the well-vascularized tissue over the sutured vaginal stump (30).

A situation after multiple abdominal surgeries represents a major challenge for VRAM flap implementation. On the one hand, the deep inferior epigastric vascular supply may not be available anymore; on the other hand, significant scarring complicates the preparation. Careful preparation and experience of the surgeon permit the implementation of a VRAM flap even in these cases; furthermore, assessment of the deep inferior epigastric vessels through computer angiography is recommended.

Vertical rectus abdominis myocutaneous flaps can also be desepithelialized, which allows to obliterate larger dead space volumes and adjustment of the skin paddle to smaller skin defects, no bulky perineal skin surface and a shorter suture line is achieved. Vascularized dermis at the wound base seems to be associated with a rapidly healing, even in an irradiated field (31, 32).

The most common defects of tumors in this region are caused by rectal and anal carcinomas. In addition, excision of other tumors necessitates a resection of the neighboring skin-/soft tissue, which requires a reconstruction during the same operation. This includes, e.g., extensive gynecological and bladder carcinomas. In case of resection of pelvic bone, VRAM flap can be transferred anteriorly to the symphysis instead of the transpelvic course (33). Two-stage reconstruction has some disadvantages in such cases. Secondary reopening of the abdomen carries a lot of risks, like discrete intestinal loops that are easily being injured during dissection, e.g., interim negative wound pressure therapy is a possible option, but carries the risk for chronic fistulas through the continuous negative pressure (34), hence single-stage reconstruction is strongly recommended under these circumstances.

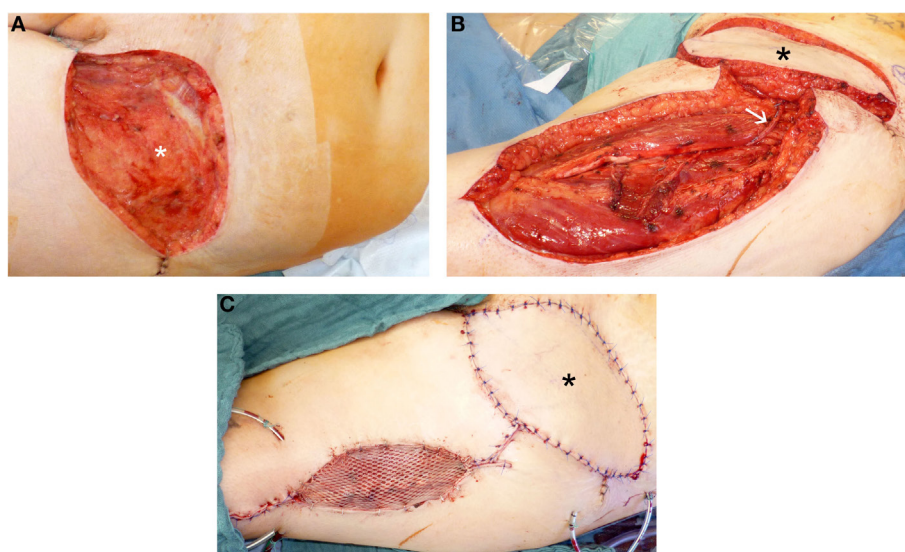
Summarizing, we suggest that VRAM flap is a particularly suitable method for pelvic reconstruction in patients with advanced colorectal cancer disease requiring pelvic exenteration (20–22).

## Plastic-Surgical Measures of Sarcomas of the Pelvic Region

In terms of soft tissue sarcoma of the pelvic/caudal abdomen/proximal thigh region, two-stage reconstruction is possible. Until the final histopathological results, negative wound pressure therapy can be used after tumor resection. Additional resections can be performed until histopathological R0-margins are achieved. Nevertheless simultaneous tumor resection and defect reconstruction can be useful (35).

In general, perineal soft tissue tumors are rare, so optimizing their management and outcome of treatment are still subject to investigation (12). General guidelines have been published, although the histological types are very variable and the locations mostly very complex and various (36, 37). Soft tissue sarcoma requires individual treatments, because optimal local control prevents deaths, related to local progression (38). The soft tissue sarcoma tumor size is often very large, because these tumors grow often without symptoms in the ischioanal fossa (12). In case of chemo- or radiosensitive subtypes, neoadjuvant radiochemotherapy should be discussed (36).

Treatment of arrosion hemorrhage and exposed osteosynthesis implants are urgent indications of simultaneous reconstructions (39). Another indication for simultaneous defect reconstruction is exposition of vulnerable structure like nerves or vessels, e.g., negative wound pressure therapy (possibly using an additional silicon membrane beneath the sponge



**FIGURE 2 | Defect reconstruction at groin after resection of a dermatofibrosarcoma protuberans using caudal pedicled ALT flap. (A)** Extent of groin defect after resection (black asterisk) of a dermatofibrosarcoma protuberans. **(B)** Intraoperative view after dissection of ALT flap and rotation into the groin defect. For typical manner of harvesting ALT flap, ALT perforator is localized between the central to lower third of the ALT flap area after skin incision and initial preparation. White arrow shows the ALT perforator. **(C)** Intraoperative view at the end of the operation with ALT flap (black asterisk) and skin graft at donor site to reconstruct groin defect.

for protection of underlying structures) may be applied in between, since harm of nerves by negative pressure therapy has not been reported so far. Nevertheless, the risk especially for infection of expanded defects even after radio-chemotherapy is very high; therefore, simultaneous defect reconstruction is recommended.

However, timing of reconstruction is very challenging. To achieve a long-lasting cure, thorough examination of the patient and his local findings, as well as the radiologic findings, has to be evaluated in a multidisciplinary approach. No compromise in terms of the extent of the oncological resection has to be accepted, and the extent of the defect decides the treatment regime as a simultaneous vs. a two-stage defect reconstruction (3).

As an example for two-stage defect reconstruction and using a pedicled antero-lateral thigh (ALT) flap, **Figure 2** shows the case of a patient with dermatofibrosarcoma protuberans at the left groin. Negative wound pressure therapy was applied until the histopathological R0-result was confirmed. For defect reconstruction (**Figure 2A**), a caudally pedicled ALT flap was used (**Figures 2B,C**).

All in all, in cases of reconstructions after sarcoma resection in the pelvic region, we recommend a two-stage reconstruction where possible, i.e., when no vulnerable structures are exposed after tumor resection. Many factors like size and character of the defect have to receive attention, but often a pedicled flap like ALT flap or VRAM flap could be used (3, 40).

## Combined Intra- and Extrapelvic Defects

Combined intrapelvic organ defects (e.g., chronic bladder fistulas) and concurrent abdominal skin defects (e.g., with abdominal skin fistulas and/or unstable scars or skin grafts) are very

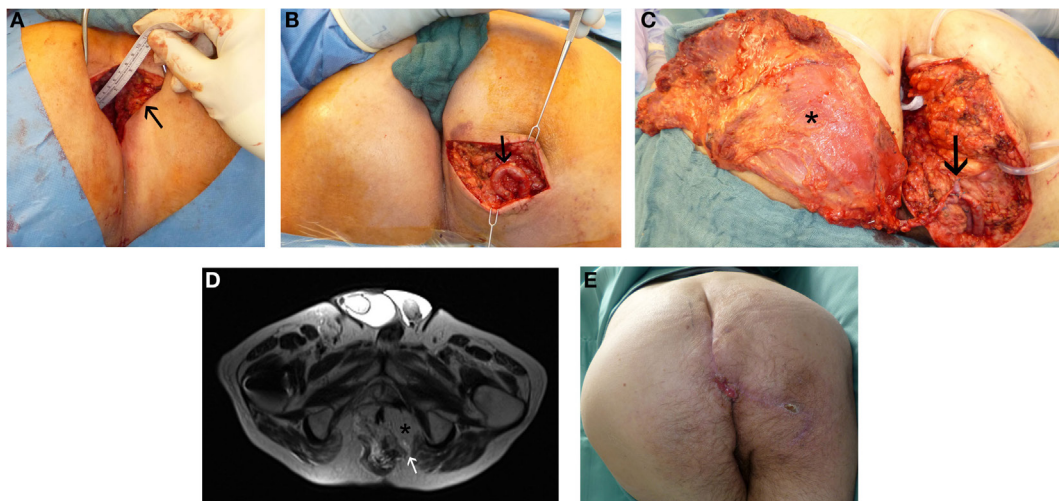
challenging. In particular, due to side effects of radiotherapy, skin grafts are prone to complications. Most times the defect may initially underestimated and skin grafts are applied, which need to be replaced during the further course by vascularized tissue/flaps.

As an example for such postoperative complication, a vesico-cutaneous fistula of the caudal rectus abdominis muscle after sarcoma resection and radiotherapy may result, which is very difficult to treat (41). For treatment of this rare entity, microsurgical free flap transplantation can become necessary, especially to avoid an additional weakening of the abdominal wall using the contralateral rectus abdominal muscle. A combined bipedicular latissimus dorsi/anterior serrate flap is capable of covering the intrapelvic defect (bladder vault using the part of serratus flap) as well as the abdominal wall defect cranial to the symphysis (using the part of latissimus dorsi flap) (42).

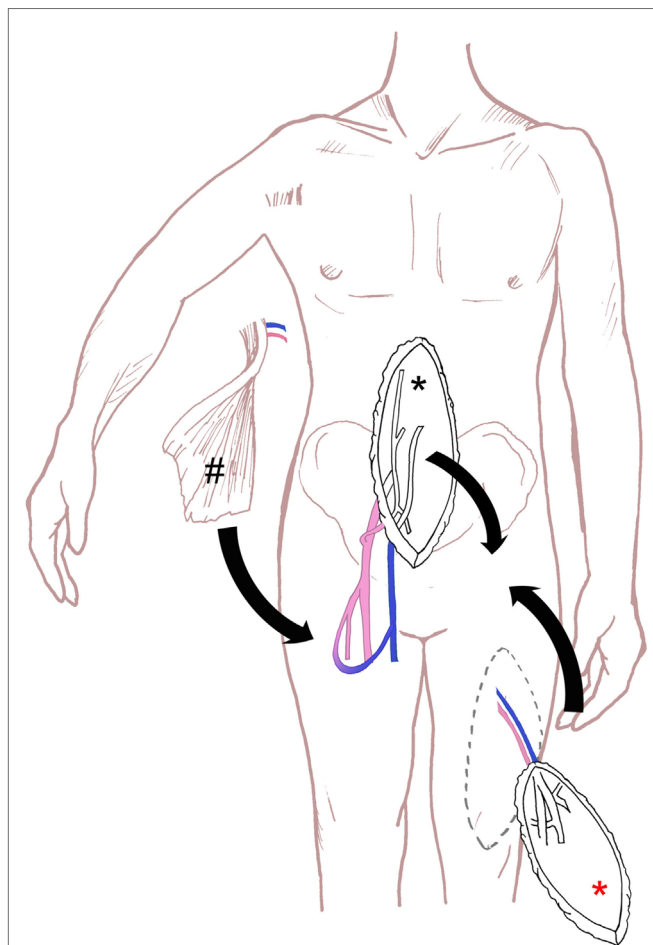
Reconstruction of combined intra- and extrapelvic defects is always very challenging. The literature describes no patent remedy, so we suggest for treatment of this rare entity microsurgical free flap transplantation (42, 43).

## Secondary Treatment of Perigenital Defects

Sometimes patients present themselves, secondary or after complications have occurred, like recurrent absceding or phlegmonous infections of the pelvis, persistent severe secretion out of chronic sacral cavities or fistulas in prostate/vaginal/urine bladder region. Treatment of such sequelae is technically very challenging and connected to a severe risk profile. A reopening of the abdominal access for VRAM flap is difficult, because of a high risk for injury of adherent small intestine or fibrosis as well



**FIGURE 3 | Perineal defect reconstruction after resection of a chronic sacral cavity with fistulas using a microsurgical free “buried” latissimus dorsi flap and an arterio-venous loop.** In history, after radio-chemotherapy a rectal carcinoma had been resected. **(A)** Preoperative presentation of chronic sacral fistula (black arrow). **(B)** Situs after dissection of the arterio-venous loop (black arrow). **(C)** Intraoperative view at anastomosed latissimus dorsi flap (black asterisk) at the loop (black arrow). **(D)** MR-Angiography with microsurgical free “buried” latissimus dorsi flap (black asterisk) inserted to reconstruct perineal defect and imaging of the consistent arterio-venous loop (white arrow). **(E)** Result 1 month postoperatively.



**FIGURE 4 |** Schematic drawing of the surgical technique for perineal defect reconstruction, with schematic drawing of VRAM flap (black asterisk), ALT flap (red asterisk) and microsurgical free latissimus dorsi flap and an arterio-venous loop (hash).

as stenosis of the pelvic entry. Another problem is loss of both inferior epigastric vessels. In these cases, other pedicled regional flaps should be used for defect reconstruction (15).

To cover posterior defects, gluteal flaps are useful (1); for ventral defects, pudendal flaps (44) and groin flaps (45) should be mentioned. Similarly, the use of lateral vastus muscle flap (46) and ALT flap (15) for defect reconstruction after pelvic exenteration has been described. Myocutaneous gluteal flaps are mainly

used as rotation – or as VY advancement – flaps (47), while the gracilis muscle flap is mainly used as proximally pedicled muscle flap (48). Complications result most from chronic lymphfistulas or lymphedema at femoral or groin region. Gluteal perforator flaps (SGAP and IGAP) do not affect the motor function and minimize the donor-side morbidity (49), thus, offering a technically more advanced solution with relatively low donor site morbidity.

A successful defect reconstruction including in particular a sufficient filling of presacral cavity requires an acceptable intrapelvic access using pedicled gluteal muscle flaps. Sometimes sacral or coccygeal bone has been resected (50).

Secondary sealing itself is very challenging, if chronic sacral cavities or recurrent pelvic infections are being observed. An access to and sufficient filling of presacral dead space is difficult to achieve in a secondary perineal approach. In such cases, sufficient three-dimensional defect reconstruction often is not possible without microsurgical free flaps. These could be anastomosed to local blood vessels, like gluteal vessels (51), femoral vessels, or iliac vessels after an arterio-venous loop (Figure 3).

After radiation, wound healing disorders are more frequent, therefore skin grafts are often not useful for defect reconstruction in such cases. Primary treatment with pedicled or microsurgical free flaps can be appropriate (52).

## Conclusion

The evolution of more radical excisional surgery techniques resulted in an increase in large defects of the perineum. In most of the cases, primary closure of perineal defects is not possible. Skin grafts are suboptimal in the perigenital area. For intra-abdominally and/or pelvic tumors of the rectum, the anus or the female reproductive system, which were resected through an abdominally and a sacrally surgical access, simultaneous VRAM flap reconstruction is recommendable. We suggest the VRAM flap as a particularly suitable method for pelvic reconstruction in patients with advanced colorectal cancer disease requiring pelvic exenteration. In terms of soft tissue sarcoma of the pelvic/caudal abdomen/proximal thigh region, two-stage reconstructions are possible. Many factors, like size and character of the defect have to be considered, but often a pedicled flap, like ALT flap could be used in cases of sarcoma resection. Secondary sealing itself is very challenging, if chronic sacral cavities or recurrent pelvic infections are being observed. In such cases, sufficient three-dimensional defect reconstruction often is not possible without microsurgical free flaps (Figure 4).

## References

- Winterton RIS, Lambe GF, Ekwobi C, Oudit D, Mowatt D, Murphy JV, et al. Gluteal fold flaps for perineal reconstruction. *J Plast Reconstr Aesthet Surg* (2013) **66**:397–405. doi:10.1016/j.bjps.2012.09.026
- Kolehmainen M, Suominen S, Tukiainen E. Pelvic, perineal and genital reconstructions. *Scand J Surg* (2013) **102**:25–31. doi:10.1177/145749691310200106
- Beier JP, Croner RS, Lang W, Arkudas A, Schmitz M, Göhl J. Komplikationsvermeidung in der onkologischen Chirurgie der Becken-/Leistenregion. *Der Chirurg* (2015) **86**:242–50. doi:10.1007/s00104-014-2835-6
- Chessin B, Hartley J, Cohen AM, Mazumdar M, Cordeiro P, Disa J, et al. Rectus flap reconstruction decreases perineal wound complications after pelvic chemoradiation and surgery: a cohort study. *Ann Surg Oncol* (2005) **12**:104–10. doi:10.1245/ASO.2005.03.100
- Nielsen MB, Rasmussen PC, Lindegaard JC, Laurberg S. A 10-year experience of total pelvic exenteration for primary advanced and locally recurrent rectal cancer based on a prospective database. *Colorectal Dis* (2012) **14**:1076–83. doi:10.1111/j.1463-1318.2011.02893.x
- Emmertsen KJ, Laurberg S. Low anterior resection syndrome score. *Ann Surg* (2012) **255**:922–8. doi:10.1097/SLA.0b013e31824f1c21



7. Christensen HK, Nerstrøm P, Tei T, Laurberg S. Perineal repair after extralevator abdominoperineal excision for low rectal cancer. *Dis Colon Rectum* (2011) **54**:711–7. doi:10.1007/DCR.0b013e3182163c89
8. Horch RE, Hohenberger W, Eweida A, Kneser U, Weber K, Arkudas A, et al. A hundred patients with vertical rectus abdominis myocutaneous (VRAM) flap for pelvic reconstruction after total pelvic exenteration. *Int J Colorectal Dis* (2014) **29**:813–23. doi:10.1007/s00384-014-1868-0
9. Sauer R, Becker H, Hohenberger W, Rödel C, Wittekind C, Fietkau R, et al. Preoperative versus postoperative chemoradiotherapy for rectal cancer. *N Engl J Med* (2004) **351**:1731–40. doi:10.1056/NEJMoa040694
10. Ferrand F, Malka D, Bourredjem A, Allonier C, Bouché O, Louafi S. Impact of primary tumour resection on survival of patients with colorectal cancer and synchronous metastases treated by chemotherapy: results from the multicenter, randomised trial Fédération Francophone de Cancérologie Digestive 9601. *Eur J Cancer* (2013) **49**:90–7. doi:10.1016/j.ejca.2012.07.006
11. Ghurani GB, Penalver MA. An update on vulvar cancer. *Am J Obstet Gynecol* (2001) **185**:294–9. doi:10.1067/mob.2001.117401
12. Sourrouille I, Vilcot L, Honoré C, Coppola S, Terrier P, Le Cesne A. Algorithm for the surgical management of mesenchymal tumors of the perineum in adults. *Dis Colon Rectum* (2015) **58**:304–13. doi:10.1097/DCR.0000000000000272
13. Das Gupta K, Busch K, Kall S, Vogt PM. Plastisch-rekonstruktive Therapie bei postonkologischen Defekten im Bereich der Beckenregion. *Der Chirurg* (2004) **75**:1135–44. doi:10.1007/s00104-004-0964-z
14. Körlof B, Nylén B, Tillinger KG, Tjernberg B. Different methods of reconstruction after vulvectomy for cancer of the vulva. *Acta Obstet Gynecol Scand* (1975) **54**:411–5. doi:10.3109/00016347509157103
15. Wong S, Garvey P, Skibber J, Yu P. Reconstruction of pelvic exenteration defects with anterolateral thigh-vastus lateralis muscle flaps. *Plast Reconstr Surg* (2009) **124**:1177–85. doi:10.1097/PRS.0b013e3181b5a40f
16. Onaitis MW, Noone RB, Hartwig M, Hurwitz H, Morse M, Jowell P, et al. Neoadjuvant chemoradiation for rectal cancer: analysis of clinical outcomes from a 13-year institutional experience. *Ann Surg* (2001) **233**:778–85. doi:10.1097/00000658-200106000-00007
17. Gerard JP, Romestaing P, Chapet O. Radiotherapy alone in the curative treatment of rectal carcinoma. *Lancet Oncol* (2003) **4**:158–66. doi:10.1016/S1470-2045(03)01020-9
18. Croner RS, Merkel S, Papadopoulos T, Schellerer V, Hohenberger W, Goehl J. Multivisceral resection for colon carcinoma. *Dis Colon Rectum* (2009) **52**:1381–6. doi:10.1007/DCR.0b013e3181ab580b
19. Jain AK, DeFranzo AJ, Marks MW, Loggie BW, Lentz S. Reconstruction of pelvic exenterative wounds with transpelvic rectus abdominis flaps: a case series. *Ann Plast Surg* (1997) **38**:115–22. doi:10.1097/00006637-199702000-00004
20. Horch RE, Gitsch G, Schultze-Seemann W. Bilateral pedicled myocutaneous vertical rectus abdominis muscle flaps to close vesicovaginal and pouch-vaginal fistulas with simultaneous vaginal and perineal reconstruction in irradiated pelvic wounds. *Urology* (2002) **60**:502–7. doi:10.1016/S0090-4295(02)01823-X
21. Horch RE, Ulrich K, Weber K, Hohenberger W, Dragu A. The transpelvic vertical rectus abdominis flap: one interdisciplinary approach to reduce postoperative complications after surgery for rectal cancer. *Ann Surg* (2013) **257**:e16. doi:10.1097/SLA.0b013e31828cbe3a
22. Nelson RA, Butler CE. Surgical outcomes of VRAM versus thigh flaps for immediate reconstruction of pelvic and perineal cancer resection defects. *Plast Reconstr Surg* (2009) **123**:175–83. doi:10.1097/PRS.0b013e3181904df7
23. Horch RE, Beier JP, Kneser U, Arkudas A. Successful human long-term application of in situ bone tissue engineering. *J Cell Mol Med* (2014) **18**:1478–85. doi:10.1111/jcmm.12296
24. Sun D, Yang Y, Wei Z, Xu Y, Zhang X, Hong B. Engineering of pre-vascularized urethral patch with muscle flaps and hypoxia-activated hUCMSCs improves its therapeutic outcome. *J Cell Mol Med* (2014) **18**:434–43. doi:10.1111/jcmm.12157
25. Howell AM, Jarral OA, Faiz O, Ziprin P, Darzi A, Zacharakis E. How should perineal wounds be closed following abdominoperineal resection in patients post radiotherapy – primary closure or flap repair? Best evidence topic (BET). *Int J Surg* (2013) **11**:514–7. doi:10.1016/j.ijsu.2013.05.004
26. Tei TM, Stolzenburg T, Buntzen S, Laurberg S, Kjeldsen H. Use of transpelvic rectus abdominis musculocutaneous flap for anal cancer salvage surgery. *Br J Surg* (2003) **90**:575–80. doi:10.1002/bjs.4073
27. Foster JD, Pathak S, Smart NJ, Branagan G, Longman RJ, Thomas MG, et al. Reconstruction of the perineum following extralevator abdominoperineal excision for carcinoma of the lower rectum: a systematic review. *Colorectal Dis* (2012) **14**:1052–9. doi:10.1111/j.1463-1318.2012.03169.x
28. Jensen KK, Rashid L, Pilsgaard B, Møller P, Wille-Jørgensen P. Pelvic floor reconstruction with a biological mesh after extralevator abdominoperineal excision leads to few perineal hernias and acceptable wound complication rates with minor movement limitations: single-centre experience including clinical examination and interview. *Colorectal Dis* (2014) **16**:192–7. doi:10.1111/codi.12492
29. Anthony JP, Mathes SJ. The recalcitrant perineal wound after rectal extirpation. Applications of muscle flap closure. *Arch Surg* (1990) **125**:1371–6. doi:10.1001/archsurg.1990.0141022015022
30. Huang JJ, Chang NJ, Chou HH, Wu CW, Abdelrahman M, Chen HY. Pedicle perforator flaps for vulvar reconstruction—new generation of less invasive vulvar reconstruction with favorable results. *Gynecol Oncol* (2015) **137**:66–72. doi:10.1016/j.ygyno.2015.01.526
31. de Haas WG, Miller MJ, Temple WJ, Kroll SS, Schusterman MA, Reece GP, et al. Perineal wound closure with the rectus abdominis musculocutaneous flap after tumor ablation. *Ann Surg Oncol* (1995) **2**:400–6. doi:10.1007/BF02306372
32. Campbell CA, Butler CE. Use of adjuvant techniques improves surgical outcomes of complex vertical rectus abdominis myocutaneous flap reconstructions of pelvic cancer defects. *Plast Reconstr Surg* (2011) **128**:447–58. doi:10.1097/PRS.0b013e31821e6fd2
33. Ho K, Warrier S, Solomon MJ, Lee K. A prepelvic tunnel for the rectus abdominis myocutaneous flap in perineal reconstruction. *J Plast Reconstr Aesthet Surg* (2006) **59**:1415–9. doi:10.1016/j.bjps.2006.01.050
34. Zhao JC, Xian CJ, Yu JA, Shi K. Reconstruction of infected and denuded scrotum and penis by combined application of negative pressure wound therapy and split-thickness skin grafting. *Int Wound J* (2013) **10**:407–10. doi:10.1111/j.1742-481X.2012.00997.x
35. Steinau HU, Steinsträsser L, Hauser J, Tilkorn D, Stricker I, Daigeler A. Bösartige Weichgewebeschwülste: Resektion und plastische Wiederherstellung. *Der Chirurg: Zeitschrift für alle Gebiete der operativen Medizin* (2012) **83**:673–84. doi:10.1007/s00104-011-2241-2
36. The ESMO/European Sarcoma Network Working Group. Soft tissue and visceral sarcomas: ESMO clinical practice guidelines for diagnosis, treatment and follow-up. *Ann Oncol* (2014) **25**(Suppl 3): 102–12. doi:10.1093/annonc/mdl254
37. von Mehren M, Benjamin RS, Bui MM, Casper ES, Conrad EU, DeLaney TF, et al. Soft tissue sarcoma, version 2.2012: featured updates to the NCCN guidelines. *J Natl Compr Canc Netw* (2012) **10**:951–60.
38. Bonvalot S, Rivoire M, Castaing M, Stoeckle E, Le Cesne A, Blay JY. Primary retroperitoneal sarcomas: a multivariate analysis of surgical factors associated with local control. *J Clin Oncol* (2009) **27**:31–7. doi:10.1200/JCO.2008.18.0802
39. Darouiche O. Treatment of infections associated with surgical implants. *N Engl J Med* (2004) **350**:1422–9. doi:10.1056/NEJMra035415
40. Gravanis AI, Tsoutsos DA, Karakitsos D, Panayotou P, Ionomou T, Zografos G, et al. Application of the pedicled anterolateral thigh flap to defects from the pelvis to the knee. *Microsurgery* (2006) **26**:432–8. doi:10.1002/micr.20267
41. Hennessey DB, Bolton E, Thomas AZ, Lynch TH. Vesicocutaneous fistula following adjuvant radiotherapy for prostate cancer. *BMJ Case Rep* (2013) **2013** doi:10.1136/bcr-2013-008986
42. Ludolph I, Apel H, Horch RE, Beier JP. Treatment of a chronic vesicocutaneous fistula and abdominal wall defect after resection of a soft tissue sarcoma using a bipedicle latissimus dorsi and serratus anterior free flap. *Int J Urol* (2014) **21**:1178–80. doi:10.1111/iju.12545
43. Fujioka M, Hayashida K, Morooka S, Saijo H, Nonaka T. Combined serratus anterior and latissimus dorsi myocutaneous flap for obliteration of an irradiated pelvic exenteration defect and simultaneous site for colostomy revision. *World J Surg Oncol* (2014) **12**:319. doi:10.1186/1477-7819-12-319
44. Wee JT, Joseph VT. A new technique of vaginal reconstruction using neurovascular pedicled-thigh flaps: a preliminary report. *Plast Reconstr Surg* (1989) **83**:701–9. doi:10.1097/00006534-198904000-00018
45. McGregor IA, Jackson IT. The groin flap. *Br J Plast Surg* (1972) **25**:3–16. doi:10.1016/S0007-1226(72)80097-3
46. Waterhouse N, Healy C. Vastus lateralis myocutaneous flap for reconstruction of defects around the groin and pelvis. *Br J Surg* (1990) **77**:1275–7. doi:10.1002/bjs.1800771125

47. Ay A, Aytakin O, Aytakin A. Interdigitating fasciocutaneous gluteal V-Y advancement flaps for reconstruction of sacral defects. *Ann Plast Surg* (2003) **50**:636–8. doi:10.1097/01.SAP.0000054241.94281.D2
48. Becker DW, Massey FM, McCraw JB. Musculocutaneous flaps in reconstructive pelvic surgery. *Obstet Gynecol* (1979) **54**:178–83.
49. Schmidt VJ, Horsch RE, Dragu A, Weber K, Göhl J, Mehlhorn G, et al. Perineal and vaginal wall reconstruction using a combined inferior gluteal and pudendal artery perforator flap: a case report. *J Plast Reconstr Aesthet Surg* (2012) **65**:1734–7. doi:10.1016/j.bjps.2012.04.055
50. Galandiuk S, Jorden J, Mahid S, McCafferty MH, Tobin G. The use of tissue flaps as an adjunct to pelvic surgery. *Am J Surg* (2005) **190**:186–90. doi:10.1016/j.amjsurg.2005.05.009
51. Hung SJ, Chen HC, Wei FC. Free flaps for reconstruction of the lower back and sacral area. *Microsurgery* (2000) **20**:72–6. doi:10.1002/(SICI)1098-2752(2000)20:2<72
52. Taeger CD, Arkudas A, Beier JP, Horsch RE. Emergency arterio-venous loop for free-flap defect reconstruction of the lower thigh with a post-irradiated and heavily infected wound. *Int Wound J* (2015) **12**:598–600. doi:10.1111/iwj.12278

**Conflict of Interest Statement:** The authors declare that the research was conducted in the absence of any commercial or financial relationships that could be construed as a potential conflict of interest.

Copyright © 2015 Brodbeck, Horsch, Arkudas and Beier. This is an open-access article distributed under the terms of the Creative Commons Attribution License (CC BY). The use, distribution or reproduction in other forums is permitted, provided the original author(s) or licensor are credited and that the original publication in this journal is cited, in accordance with accepted academic practice. No use, distribution or reproduction is permitted which does not comply with these terms.



# Soft Tissue Coverage of the Lower Limb following Oncological Surgery

Christine Radtke<sup>1\*</sup>, Martin Panzica<sup>2</sup>, Khaled Dastagir<sup>1</sup>, Christian Krettek<sup>2</sup> and Peter M. Vogt<sup>1</sup>

<sup>1</sup> Department of Plastic, Aesthetic, Hand and Reconstructive Surgery, Hannover Medical School, Hannover, Germany,

<sup>2</sup> Department of Trauma Surgery, Hannover Medical School, Hannover, Germany

## OPEN ACCESS

### Edited by:

Adrien Daigeler,  
BG-University Hospital  
Bergmannsheil, Germany

### Reviewed by:

Rutie Yin,  
West China Second University  
Hospital, China  
Zarah Hirche,  
Klinikum Ludwigshafen, Germany

### \*Correspondence:

Christine Radtke  
radtke.christine@mh-hannover.de

### Specialty section:

This article was submitted to  
Surgical Oncology,  
a section of the journal  
Frontiers in Oncology

**Received:** 28 August 2015

**Accepted:** 17 December 2015

**Published:** 13 January 2016

### Citation:

Radtke C, Panzica M, Dastagir K,  
Krettek C and Vogt PM (2016) Soft  
Tissue Coverage of the Lower Limb  
following Oncological Surgery.  
Front. Oncol. 5:303.  
doi: 10.3389/fonc.2015.00303

The treatment of lower limb tumors has been shifted by advancements in adjuvant treatment protocols and microsurgical reconstruction from limb amputation to limb salvage. Standard approaches include oncological surgery by a multidisciplinary team in terms of limb sparing followed by soft tissue reconstruction and adjuvant therapy when indicated. For the development of a comprehensive surgical plan, the identity of the tumor should first be determined by histology after biopsy. Then the surgical goal and comprehensive treatment concept should be developed by a multidisciplinary tumor board and combined with soft tissue reconstruction. In this article, plastic surgical reconstruction options for soft coverage of the lower extremity following oncological surgery will be described along with the five clinical cases.

**Keywords:** soft tissue sarcoma, bone sarcoma, limb-sparing surgery, modular endoprosthetic implantation, soft tissue reconstruction, microvascular flap

## INTRODUCTION

Soft tissue tumors and bone sarcomas are a heterogeneous class of mesenchymal tumors comprising <1% of all malignancies in adults and represent 15% of pediatric malignancies<sup>1</sup> (1). The overall mortality rate for soft and bone sarcomas was estimated as 30 and 45%, respectively<sup>1</sup> (1). Two-thirds of the tumors are located in limbs, most frequently in the lower extremity (46%) (1). Osteosarcoma has been the primary model to base treatment of all sarcomas. Multi-agent chemotherapy regimens have demonstrated an increase in overall survival rates (15–20%) as compared to surgery alone in the 1970s, but more recently, survival has increased to 55–80%<sup>1</sup> (2).

There has been considerable progress in the management of limb sarcomas over the past few decades. Several decades ago, there was a high rate of limb amputations (38–47%) associated with sarcoma, likely the result of reduced radiotherapy and reconstructive methods (3). The introduction of radiotherapy has considerably improved outcome and in combination with oncological and advanced reconstructive surgery important advances have been made in tumor control and functional limb preservation<sup>1</sup> (4).

In high-grade malignancies or tumors of borderline resectability, preoperative chemotherapeutic downsizing could be indicated. In the case of non-resectable tumors, especially sarcomas in close proximity of functional structures, isolated limb perfusion can be considered (5). Postoperatively, necessary chemotherapy can be combined with deep wave hyperthermia (6). Although limb amputation may be unavoidable in some circumstances, the combination of limb-sparing and reconstructive surgery can optimize function of the affected limb and

<sup>1</sup> www.sarcoma.org



avoid the significant psychological impact associated with amputation<sup>1</sup>. Endoprosthetic procedures for skeletal reconstruction have improved functional outcome (7). Currently, 90–95% of limb sarcoma patients may undergo successful limb-sparing procedures with soft tissue coverage when treated at a major center specializing in musculoskeletal oncology (4). Thus, for the majority of soft tissue malignancies and bone sarcomas of the limb, limb-sparing surgery performed in an interdisciplinary team (8) is an important treatment option.

## SURGICAL PLANNING AND DECISION-MAKING CONSIDERATIONS

A meticulous surgical technique is crucial to ensure an optimal oncological and functional outcome for the patient. Successful limb-sparing surgery consists of three interdependent stages performed in sequence as follows:

1. Tumor resection with appropriate oncological margins,
2. Reconstruction and stabilization of the involved bone and joints, and
3. Restoration of the soft tissue envelope and restoration of function.

The overall aim of oncological surgery followed by soft tissue reconstruction is to carry out a wide compartmental excision for maximal tumor removal, yet to preserve limb function. The excision is defined as wide when the distance between the histologically defined tumor and the excision margins are at least 2 cm (3). However, if there is an anatomical barrier such as deep or muscle fascia that is intact, which separates the tumor from the excision border, the tumor may be considered wide with an excision distance <2 cm (3). The European Society for Medical Oncology (ESMO) guideline does not state a specific margin size. However, it does recommend that radiation therapy can be used for tumors larger than 5 cm<sup>2,3</sup>. Because tumor excision often leads to potentially large tissue defects, including bone, joint, and tendon exposure, reconstructive surgery is an important and critical element (9, 10). For skeletal and joint reconstruction, advances in commercial modular endoprosthetic devices have importantly advanced the field<sup>1</sup> (7, 11). With the development of modular endoprosthetic devices with their large range in size and adaptability, the surgeon can focus on optimizing the oncological resection procedure, having the knowledge that appropriate prosthetic components will likely be available even if the surgical procedure needs to deviate from the preoperative plan. Thus, modern modular endoprosthetic reconstruction plays an important role in limb-sparing surgery for bone sarcoma resection. Ongoing work to develop better approaches for attachment of tendon to endoprosthetic devices such as novel clamps and in growth-promoting surfaces to

promote may lead to improved junctional strength<sup>1</sup> (11). The most common site for primary bone sarcomas is the distal femur. Endoprosthetic reconstruction of this region is of particular challenge because the cruciate and collateral ligaments must be removed thus reducing stability<sup>1</sup> (12). Appropriate soft tissue coverage is imperative to decrease the risk of secondary periprosthetic infection.

After tumor resection of the lower extremity complex, defects are anticipated and multiple variables must be considered for soft tissue reconstruction. A large number of details must be taken into consideration when planning a reconstruction, especially after oncological surgery. One must consider the timing of reconstruction, size and location of the defect, involvement of neurovascular structures, and exposure or resection of bone, tendons, and nerves. Donor site morbidity, disease prognosis, and the patient's previous level of function and expectations of restored function must be evaluated as well.

The reconstructive ladder as a concept for wound closure has gone through several adjustments over time (13–15). While the concept of using the simplest approach and moving up the ladder to more complex approaches is certainly important, there may be times with oncological defect surgery where this approach may not be valid (13).

This led to the idea of the “reconstructive elevator,” which was introduced by Gottlieb and Krieger (16). While still admitting to the idea of increasing levels of complex difficulty, the “reconstructive elevator” offers the flexibility to elevate directly to an appropriate level of complexity as necessary (17). This concept draws attention to the importance of selecting the most appropriate level of reconstruction instead of selecting the least complex that is often the case in soft tissue coverage after oncological surgery.

## DETERMINING THE OPTIMAL TIMING FOR SOFT TISSUE RECONSTRUCTION

It was demonstrated with regard to traumatic wound coverage of the lower limb that microvascular tissue transfer after 5–21 days post-trauma resulted in higher flap failure rates and wound infections (18). In soft tissue coverage following oncological surgery, an early time point for wound closure is preferred, but multiple stage/sequential procedure might be necessary for the achievement of a R0 resection and temporary closure is applicable. However, when there is R1 or R2 status and chemo- and radiation therapy is required, stable wound closure is essential before the onset of these therapeutic regimens.

There are several advantages for immediate reconstruction to be carried out at the time of tumor resection. One is that the anatomical perspective of the oncological defect can be assessed prior to scar formation. This will minimize surgical dissection of, for example, exposure of vessels for microvascular repair that would be necessitated if there was a delay with scar formation (19, 20). Another advantage is the psychological benefit to the patient. However, reconstruction is delayed in cases where the margins of the resection site are not clear or when the patient has issues with wound healing (20).

<sup>2</sup>www.esmo.org

<sup>3</sup>www.current-oncology.com

## SOFT TISSUE RECONSTRUCTION

Plastic surgical reconstruction options for soft coverage of the lower extremity following oncological surgery will be described by means of five clinical cases.

### Case 1

The first case describes the soft tissue coverage in the proximal thigh/inguinal region. A 55-year-old male patient presented with an ulcerating metachronous metastasis in the right inguinal region (**Figure 1A**) after resection of a squamous cell carcinoma (SCC) to the anus limited to the anal margin only infiltrating the perianal skin and without invasion of the sphincter muscle, which was resected 11 months before (pT1, pN0, pM0, R0). The surgical excision of the metachronous metastasis resulted in a soft tissue defect with an extension of 11 cm × 11 cm as illustrated in **Figures 1B,C**. Here, the complete resection with preservation of vessels and femoral nerve followed by soft tissue coverage with an extended vertical rectus abdominis myocutaneous (VRAM) flap (**Figures 1C–E**). After wound healing, adjuvant chemotherapy with Cisplatin/5-Fluorouracil followed by radiotherapy was performed according to the anal cancer treatment protocols for metastatic diseases following current guidelines (21). Long-term follow-up demonstrated stable coverage (**Figure 1F**). This case represents an individualized tumor treatment concept and a challenging situation for soft tissue coverage because of its large soft tissue defect in the groin with the need of a soon adjuvant therapy.

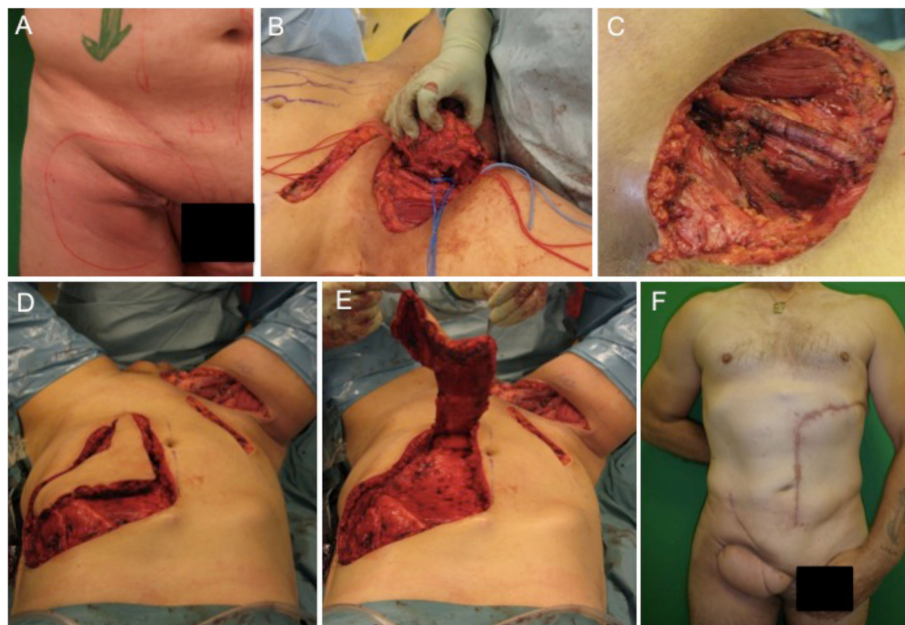
Treatment options for the groin and thigh reconstruction include as local flaps include sartorius, the tensor fascia latae, or

the rectus femoris flaps. With regard to tumor size in the presented case, an extended VRAM flap was performed.

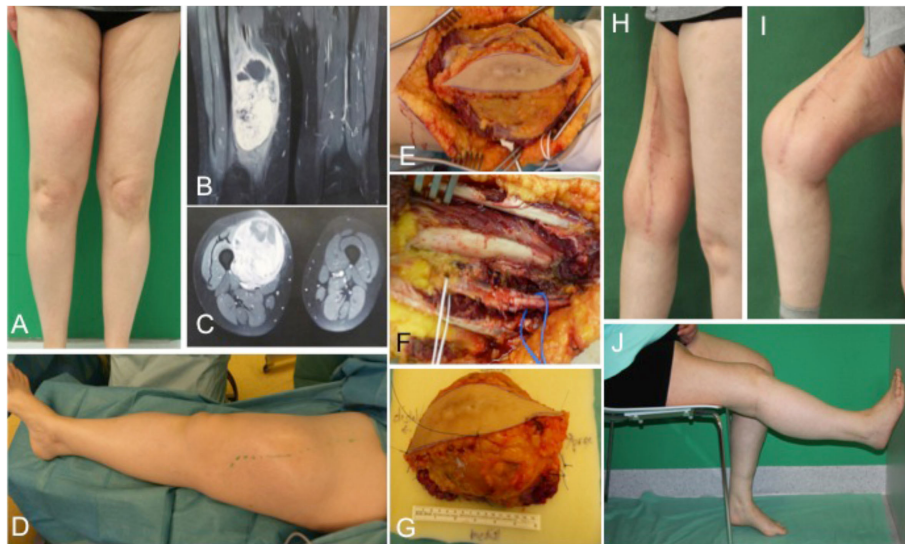
### Case 2

A 54-year-old female patient presented with a gradually growing non-inflammatory and indolent tumor of the right thigh (**Figures 2A,D**). Magnetic resonance imaging (MRI) revealed a heterogeneous tumor involving the vastus lateralis, medialis, and intermedius muscles (**Figures 2B,C**). A biopsy confirmed an undifferentiated myxofibrosarcoma. CT scans showed no evidence of metastasis. The tumor was removed with a complete size of the resected tissue of 15 cm × 8 cm × 7.5 cm under preservation of vessels and the femoral nerve (**Figures 2E–G**). Primary closure could be performed after radical resection and histology revealed an undifferentiated myxofibrosarcoma pT2b, pN0, pM0, R0; G3 (FNCLCC). Clinical follow-up examination 1 year after surgical treatment showed stable long-term results with a range of motion of right knee for extension/flexion 0/0/120° and 60/0/40° of the right hip joint (**Figures 2H–J**).

Treatment options for the groin and thigh reconstruction include sartorius, tensor fascia latae, or rectus femoris local flaps (22). With regard to tumor size in the presented case 1, an extended VRAM flap was performed. In the illustrated case 2, the defect could be closed primarily. If primary closure cannot be performed, the use of local muscle is in most cases the best treatment option and the need for free flaps is only in extensive cases necessary. For anastomosis of a microvascular flap, the deep inferior epigastric, the superficial epigastric, the superficial circumflex iliac, or the femoral vessels could serve as recipient



**FIGURE 1 | Demonstration of tumor at the right inguinal region expanding on the proximal thigh (A), complete metastatic resection was performed with preservation of inguinal vessels and femoral nerve (B,C). As a next step, an extended VRAM flap from the contralateral side was prepared and transferred for defect closure (D,E). Long-term results revealed complete removal and stable coverage with minimal donor morbidity (F).**



**FIGURE 2 |** Preoperative clinical presentation of a 54-year-old female with an undifferentiated myxofibrosarcoma G3 in the anterior compartment of ventral thigh and correlation with MRI (A–C). Intraoperative situs (C–F) with complete tumor removal (G). Long-term results (H–J) of primary closure showing the esthetic outcome and maintained function of the right limb.

vessels where end to side anastomoses should be preferred to preserve distal blood flow (23).

### Case 3

This case describes a 15-year-old female with confirmed osteosarcoma of the proximal tibia and treatment with an induction chemotherapy according to the Cooperative German–Austrian–Swiss Osteosarcoma Study Group (COSS) protocol (24, 25). After completing neoadjuvant therapy, the patient was scheduled for extraarticular knee joint resection. Modular endoprosthesis knee reconstruction was performed with a proximal tibia replacement and a knee reconstruction implant (MUTARS®) using a trevira tube for soft tissue fixation. Initial soft tissue coverage with a medial gastrocnemius flap failed due to early post-operative infection. After multiple debridement and revision surgery with antibiotic spacer application, infection was treated successfully. A new modular endoprosthesis replacement (Figures 3A–C) was then covered with a microvascular latissimus dorsi flap as limb salvage procedure (Figures 3B,D–F). Histology confirmed complete R0 resection of the osteosarcoma pT2, pN0, pM0; G3. The patient regained good post-operative function without signs of extension gap and long-term stable soft tissue reconstruction (Figures 3D–F).

Local flap for soft tissue coverage at the knee, the gastrocnemius flap is the first choice (26). From the gastrocnemius muscle, either the medial or the lateral or both heads can be transferred for soft tissue coverage. Usually, the medial head is larger in comparison to the lateral gastrocnemius head. Other possibilities besides free flaps include a reversed anterior lateral thigh (ALT) flap or a reverse vastus lateralis flap. In flap decision-making for knee reconstruction, the range of motion of the knee as highly mobile joint has to be taken into consideration and the amount of necessary surface area has to be calculated carefully within the flap design (23).

### Case 4

The next case describes a 51-year-old female patient with a gradually growing non-inflammatory and indolent swelling of her right lower leg. MRI showed a non-homogeneous tumor in the antero-lateral compartment of right leg, within the tibialis anterior and the extensor digitorum longus muscles. CT scans of her abdomen and chest and other studies showed no evidence of metastasis. Biopsy confirmed the diagnosis of a sarcoma. Subsequently, complete tumor removal was performed (Figure 4A) leading to a soft tissue defect of 10 cm × 7 cm (Figure 4B). Wound closure was performed with a fasciocutaneous transposition combined with a small split thickness skin graft at the donor side (Figures 4C–F). Histologically, the tumor was graded as pleomorphic undifferentiated sarcoma pT1, pN0, pM0, R0; G3. After wound healing, adjuvant radiotherapy with total dose of 56 Gy was conducted. Clinical follow-up 1 year after surgical treatment showed a stable complete soft tissue coverage with a range of motion for ankle dorsiflexion/plantar flexion of 5/0/30° and for eversion/inversion of 5/0/20° on the operated right side in comparison to the unaffected left side for ankle dorsiflexion/plantar flexion with 15/0/30° and eversion/inversion 10/0/20°.

Reconstruction options for the lower leg with regard to local flaps are limited particularly for the lower third can be challenging, thus free flaps are often required. Here, we performed as a prerequisite an angiography. Underlying stenosis of the arteries can often be diagnosed and the lower limb revascularization preceding surgical wound coverage is necessary to reduce complication rates. An algorithm was described to improve the success of microvascular tissue transfer on the lower extremity (27).

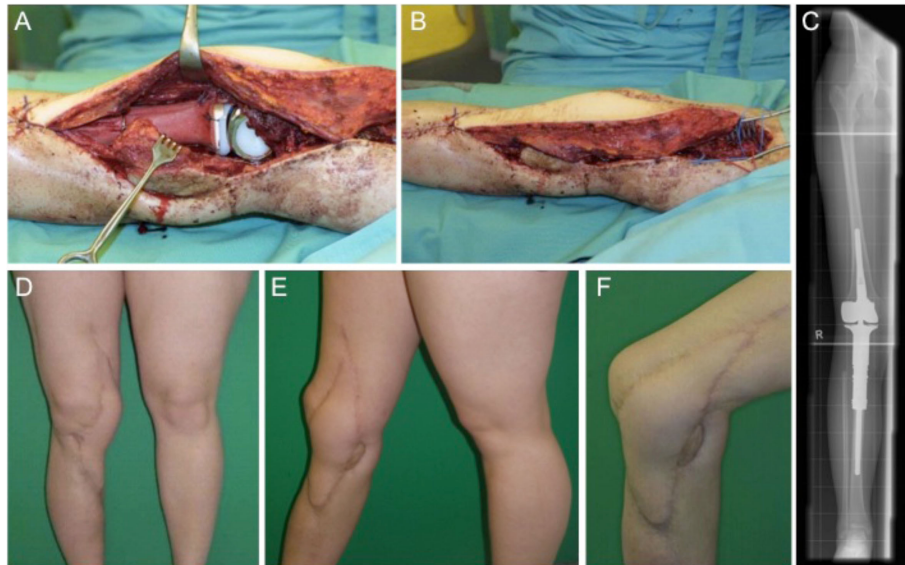
### Case 5

An 81-year-old male patient presented with a previously incomplete (R1) resected primary SCC on the lateral aspect of

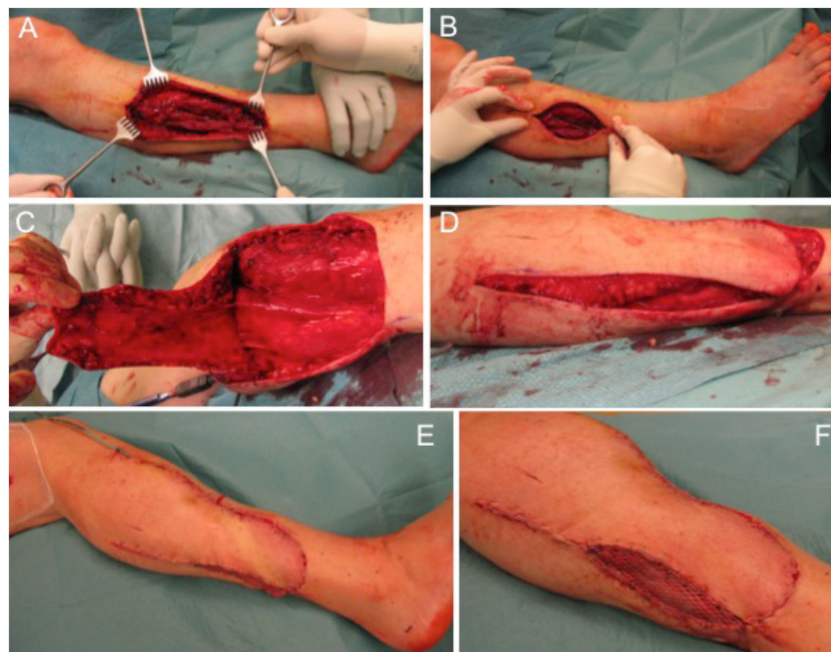


his left ankle. X-ray examination revealed no involvement of the underlying bone and CT scans ruled out any further metastatic involvement. Tumor resection of the SCC resulted in an extended soft tissue defect (**Figures 5A,B**) that required microvascular flap coverage and preparation of an ipsilateral ALT flap

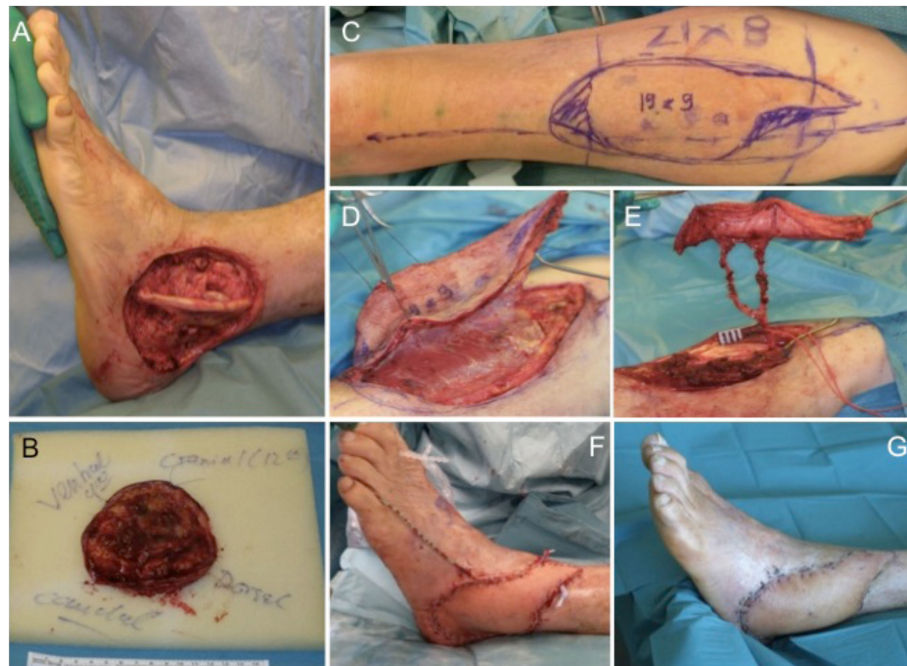
with a size of 19 cm × 9 cm was performed (**Figures 5C–E**). Histology confirmed complete tumor removal of the SCC (pTx, pN0, pM0, R0; G2). Complete wound closure could be achieved (**Figure 5F**) with long-term functional and esthetic outcome (**Figure 5G**).



**FIGURE 3 |** Intraoperative situs with implanted tumor prosthesis (MUTARS®) after extraarticular tumor resection of the knee joint (**A,B**) and coverage with a microvascular latissimus dorsi flap (**B**). (**C**) shows the corresponding x-ray image with a proximal tibial replacement. Post-operative esthetic and functional outcome (**D–F**).



**FIGURE 4 |** Defect of the lower leg after tumor removal (**A**) with remaining defect at the lateral side (**B**). A fasciocutaneous transposition flap is raised (**C**) and transferred ventrally into the defect (**D**). Full coverage can be achieved (**E**) and remaining areas at the donor side can be transplanted with split thickness skin graft (**F**).



**FIGURE 5 | Extensive soft tissue defect at the lateral malleolus (A) after tumor excision (B).** For wound coverage, an ALT flap is prepared (C,D) with a long pedicle (E) for microvascular anastomosis. The ALT flap engrafted into the defect shows intraoperatively (F) and after wound healing a very satisfying result (G).

Possibilities for local flaps at the foot include the reversed sural, dorsalis pedis, and abductor digiti minimi flaps. For free-flap anastomosis, recipient vessels are the anterior, posterior, peroneal, and dorsalis pedis artery with concomitant veins. The plantar surface requires a separate approach of exposure to high pressure during walking and mechanical stress. Here, an instep flap could be used as an option (22).

## POST-OPERATIVE CARE AND IMMOBILIZATION

In the post-operative phase, the limb should be maximally elevated for swelling reduction that could potentially compromise the flap used for soft tissue coverage<sup>1</sup> (22). It is critical that the limb is immobilized and sterile dressing applied to maximize tissue survival (22, 28). The 24-h post-operative period is critical because a high incidence of complication related to micro-revascularization of the flap occurs (22, 28). Hematoma formation must be reduced and large-bore closed suction drains are helpful in this regard<sup>1</sup> (22). In case of hematoma development immediate and aggressive treatment in the operating room should be carried out to prevent occlusion/compression of microvascular anastomoses, which could lead to perfusion complications of the flap as an immediate effect and the secondary effect of infection, especially in case of implanted endoprosthesis<sup>1</sup> (22). Subsequent wound care, physical therapy, and potential tumor adjuvant therapy are essential to complete

the therapeutic process (28). Completion of the therapy should include standard wound care and physical therapy with the potential for adjuvant therapy for tumor treatment (22, 28).

## CONCLUSION

Limb salvage in patients with sarcoma is possible with an acceptable outcome by selective combination of required treatment modalities. Currently, primary amputation is usually only performed in cases where the tumor infiltrates major neurovascular structures, bone or joint and when not even marginal resection is feasible. In these cases, the great risk of local recurrence or of poor limb function favored amputation. Clearly, it is important that patients should be provided with solutions that address improvement in function, but cosmetic and psychological issues should be addressed as well. For patients initially thought to have unsalvageable limbs because of tumor size and location, reassessment after preoperative chemotherapy may allow reconsideration of limb-sparing procedures. Therefore, a careful re-evaluation of the patient following adjuvant treatment is necessary for defining a meticulous multidisciplinary surgical plan. Limb-sparing procedures combined with soft tissue coverage after oncological surgery should not be limited to patients with a curative goal, patients in a palliative stage of disease can benefit from surgery in terms of pain reduction and improvement of quality of life. Finally, given the complexity of a multidisciplinary approach, individualized treatment should be performed in major centers specializing in musculoskeletal oncology.

## REFERENCES

- Pukkala E, Rautalahti M. *Cancer in Finland*. Helsinki: Cancer Society of Finland (2000). Available from: [http://cancer-fi-bin.directo.fi/Bin/cd02344ab808f8670cef1c3fd0f5a397/1452006536/application/pdf/91148164/Cancer\\_in\\_Finland\\_19.6.13\\_sivuittain.pdf](http://cancer-fi-bin.directo.fi/Bin/cd02344ab808f8670cef1c3fd0f5a397/1452006536/application/pdf/91148164/Cancer_in_Finland_19.6.13_sivuittain.pdf)
- Malawer M. Section 1: principles of management. Chapter 1. Bone and soft-tissue sarcomas: epidemiology, radiology, pathology and fundamentals of surgical treatment. In: Shmookler B, Bickels J, Jelinek J, Sugarbaker P, Malawer M, editors. *Musculoskeletal Cancer Surgery: Treatment of Sarcomas and Allied Diseases*. Dordrecht: Kluwer Academic Publishers (2000). p. 3–37.
- Popov P, Tukiainen E, Asko-Seljaavaara S, Huuhtanen R, Virolainen M, Virkkunen P, et al. Soft tissue sarcomas of the lower extremity: surgical treatment and outcome. *Eur J Surg Oncol* (2000) **26**:679–85. doi:10.1053/ejso.2000.0980
- Wiklund T, Huuhtanen R, Blomqvist C, Tukiainen E, Virolainen M, Virkkunen P, et al. The importance of a multidisciplinary group in the treatment of soft tissue sarcomas. *Eur J Cancer* (1996) **32A**:269–73. doi:10.1016/0959-8049(95)00520-X
- Bhangu A, Broom L, Nepogodiev D, Gourevitch D, Desai A. Outcomes of isolated limb perfusion in the treatment of extremity soft tissue sarcoma: a systematic review. *Eur J Surg Oncol* (2013) **39**:311–9. doi:10.1016/j.ejso.2012.12.018
- Lindner LH, Angele M, Dürr HR, Rauch J, Bruns C. Systemic therapy and hyperthermia for locally advanced soft tissue sarcoma. *Chirurg* (2014) **85**:398–403. doi:10.1007/s00104-013-2687-5
- Bickels J, Wittig JC, Kollender Y, Henshaw RM, Kellar-Graney KL, Meller I, et al. Distal femur resection with endoprosthesis reconstruction: a long term followup study. *Clin Orthop* (2002) **400**:225–35. doi:10.1097/00003086-200207000-00028
- Jakob J, Henzler T, Kasper B, Marx A, Hohenberger P. Interdisciplinary treatment of soft tissue sarcoma of the extremities. *Chirurg* (2014) **85**:383–90. doi:10.1007/s00104-013-2689-3
- Casali PG, Blay JY; ESMO/CONTICANET/EUOBONET Consensus Panel of experts. Soft tissue sarcomas: ESMO clinical practice guidelines for diagnosis, treatment and follow-up. *Ann Oncol* (2010) **21**:v198–203. doi:10.1093/annonc/mdq208
- Popov P, Tukiainen E, Asko-Seljavaara S, Huuhtanen R, Virolainen M, Virkkunen P, et al. Soft-tissue sarcomas of the upper extremity: surgical treatment and outcome. *Plast Reconstr Surg* (2004) **113**:222–32. doi:10.1097/01.PRS.0000095946.90511.1D
- Henshaw RM, Bickels J, Malawer MM. Modular endoprosthesis reconstruction for lower extremity skeletal defects: oncologic and reconstructive indications. *Semin Arthroplasty* (1999) **10**:180–7.
- Capanna R, Morris HG, Campanacci D, Del Ben M, Campanacci M. Modular uncemented prosthetic reconstruction after resection of tumours of the distal femur. *J Bone Joint Surg Br* (1994) **76**:178–86.
- Janis JE, Kwon RK, Attinger CE. The new reconstructive ladder: modifications to the traditional model. *Plast Reconstr Surg* (2011) **127**(Suppl 1):205S–12S. doi:10.1097/PRS.0b013e318201271c
- Fleming ME, O'Daniel A, Bharmal H, Valerio I. Application of the orthoplastic reconstructive ladder to preserve lower extremity amputation length. *Ann Plast Surg* (2014) **73**:183–9. doi:10.1097/SAP.0b013e3182a638d8
- Tintle SM, Levin LS. The reconstructive microsurgery ladder in orthopaedics. *Injury* (2013) **44**:376–85. doi:10.1016/j.injury.2013.01.006
- Gottlieb LJ, Krieger LM. From the reconstructive ladder to the reconstructive elevator. *Plast Reconstr Surg* (1994) **93**:1503–4. doi:10.1097/00006534-199406000-00027
- Harrison B. General management of complex wounds. 2nd ed. *Essentials of Plastic Surgery*. CRC Press (2014).
- Godina M. Early microsurgical reconstruction of complex trauma of the extremities. *Plast Reconstr Surg* (1986) **78**:285–92. doi:10.1097/00006534-198609000-00001
- Reece GP, Schusterman MA, Pollock RE, Kroll SS, Miller MJ, Baldwin BJ, et al. Immediate versus delayed free-tissue transfer salvage of the lower extremity in soft tissue sarcoma patients. *Ann Surg Oncol* (1994) **1**:11–7. doi:10.1007/BF02303536
- Heller L, Kronowitz SJ. Lower extremity reconstruction. *J Surg Oncol* (2006) **94**:479–89. doi:10.1002/jso.20485
- Glynne-Jones R, Nilsson PJ, Aschele C, Goh V, Peiffert D, Cervantes A, et al. Anal cancer: ESMO-ESSO-ESTRO clinical practice guidelines for diagnosis, treatment and follow-up. *Radiother Oncol* (2014) **111**:330–9. doi:10.1016/j.radonc.2014.04.013
- Vogt PM. Maligne Weichgewebstumoren des Stammes und der Extremitäten. In: Vogt PM, editor. *Praxis der Plastischen Chirurgie*. Berlin, Heidelberg: Springer Verlag (2011). p. 303–16.
- Zenn M, Jones G. *Reconstructive Surgery: Anatomy, Technique, and Clinical Applications*. St. Louis, MI: Quality Medical Publishing, Inc. (2012).
- Kager L, Zoubek A, Pötschger U, Kastner U, Flege S, Kempf-Bielack B, et al. Primary metastatic osteosarcoma: presentation and outcome of patients treated on neoadjuvant Cooperative Osteosarcoma Study Group protocols. *J Clin Oncol* (2003) **21**:2011–8. doi:10.1200/JCO.2003.08.132
- Bielack S, Jürgens H, Jundt G, Kevric M, Kühne T, Reichardt P, et al. Osteosarcoma: the COSS experience. *Cancer Treat Res* (2009) **152**:289–308. doi:10.1007/978-1-4419-0284-9\_15
- Malawer MM, Price WM. Gastrocnemius transposition flap in conjunction with limb-sparing surgery for primary bone sarcomas around the knee. *Plast Reconstr Surg* (1984) **73**:741–50. doi:10.1097/00006534-198405000-00004
- Aust MC, Spies M, Guggenheim M, Gohritz A, Kall S, Rosenthal H, et al. Lower limb revascularisation preceding surgical wound coverage – an interdisciplinary algorithm for chronic wound closure. *J Plast Reconstr Aesthet Surg* (2008) **61**:925–33. doi:10.1016/j.bjps.2007.09.060
- Willcox TM, Smith AA. Upper limb free flap reconstruction after tumor resection. *Semin Surg Oncol* (2000) **19**:246–54. doi:10.1002/1098-2388(200010/11)19:3<246::AID-SSU6>3.0.CO;2-F

**Conflict of Interest Statement:** The authors declare that the research was conducted in the absence of any commercial or financial relationships that could be construed as a potential conflict of interest.

Copyright © 2016 Radtko, Panzica, Dastagir, Krettek and Vogt. This is an open-access article distributed under the terms of the Creative Commons Attribution License (CC BY). The use, distribution or reproduction in other forums is permitted, provided the original author(s) or licensor are credited and that the original publication in this journal is cited, in accordance with accepted academic practice. No use, distribution or reproduction is permitted which does not comply with these terms.





# Soft Tissue Sarcomas of the Arm – Oncosurgical and Reconstructive Principles within a Multimodal, Interdisciplinary Setting

Georgios Koulaxouzidis<sup>1</sup>, Filip Simunovic<sup>1</sup> and Holger Bannasch<sup>1,2\*</sup>

<sup>1</sup> Department of Plastic and Hand Surgery, University of Freiburg Medical Center, Freiburg, Germany, <sup>2</sup> Section for Plastic-Reconstructive Tumor Surgery, University of Freiburg Medical Center, Freiburg, Germany

## OPEN ACCESS

### Edited by:

Adrien Daigeler,  
BG-University Hospital  
Bergmannsheil, Germany

### Reviewed by:

Wanda Petz,  
European Institute of  
Oncology, Italy  
Rutie Yin,  
West China Second University  
Hospital, China

### \*Correspondence:

Holger Bannasch  
holger.bannasch@uniklinik-freiburg.de

### Specialty section:

This article was submitted to  
Surgical Oncology,  
a section of the journal  
Frontiers in Surgery

**Received:** 17 August 2015

**Accepted:** 11 February 2016

**Published:** 23 February 2016

### Citation:

Koulaxouzidis G, Simunovic F and  
Bannasch H (2016) Soft Tissue  
Sarcomas of the Arm – Oncosurgical  
and Reconstructive Principles  
within a Multimodal,  
Interdisciplinary Setting.  
Front. Surg. 3:12.  
doi: 10.3389/fsurg.2016.00012

Soft tissue sarcomas of the upper extremity represent a severe threat for the patient and a difficult task for the treatment team. Due to the complex anatomy of the arm, most sarcomas involve valuable functional structures. Nonetheless, a large portion of the patients can be treated in a limb-sparing manner, and surgery is the mainstay of local tumor control. This review gives an overview of the disease entities and their epidemiology, on necessary patient work-up, staging, and imaging modalities, as well as the importance of interdisciplinary decision-making. The surgical therapies and principles of tumor excision are outlined, as well as reconstructive options. Furthermore, adjuvant treatments are discussed with a special focus on the various application techniques for radiation therapy. In spite of established treatment algorithms, each case is an individual challenge and individually tailored therapy is required. This aspect is illustrated by presenting three comprehensive cases demonstrating useful strategies. A summary of the relevant literature is given.

**Keywords:** soft tissue sarcoma, plastic-reconstructive surgery, upper extremity reconstruction

## INTRODUCTION

Soft tissue sarcomas (STS) are a heterogeneous group of rare malignant mesenchymal tumors representing <1% of newly diagnosed solid tumors a year (1). They have an annual incidence of two to three cases per 100,000 (2). Although sarcomas can occur throughout the body, 60% of STS in adults occur in the limbs (15% in the upper extremity and 45% in the lower extremity) (3). One-fifth of all STS occur in the upper extremity (4). Therefore, this condition is very rare, and consequently, the literature is limited to small case series (5–9). Compared to the lower extremity, where liposarcoma and myxoid sarcoma are commonly encountered; synovial sarcoma, epithelioid sarcoma, and fibrosarcoma are relatively more common in the upper extremity (10).

Treatment of upper extremity STS presents a major challenge as the complex anatomy and high functional demands compete with oncological safety demands. Until the 1970s, extremity STS often required limb amputation due to high rates of local recurrence (11, 12). Nowadays, limb-sparing surgery can be performed in more than 90% of the patients without compromise in local recurrence rates or survival rates (8, 13). This development reflects the success of a modern treatment concept with a multidisciplinary team approach (7, 14–18). However, surgical resection remains the cornerstone of treatment, and surgical resection margins are the main prognostic factor for local and

systemic tumor control (6, 8, 19). In this review, we highlight key principles of oncological and reconstructive surgery of the upper extremity with focus on the upper arm and the forearm.

## DIAGNOSTIC AND STAGING WORK-UP

Patients usually present with a subcutaneous tumor discovered by palpation. STS of the upper extremity are more readily noticed by the patient compared to the lower extremity. The estimation of duration and progression of the tumor is often uncertain, and there is no association to traumatic injury. The clinical behavior of STS is mostly misleading as they are characterized by slow growth, few physical complaints, and harmless appearance in cross-sectional imaging (20). However, due to the anatomic proximity of functional and neurovascular structures at the upper extremity complaints of nerve involvement or functional impairment at first presentation are more common than in the lower extremity. Due to these circumstances, tumors of the upper extremity tend to be smaller at the time of presentation. In any case, every refractory swelling that is not recurrent after 4 weeks should initiate diagnostic work-up, as described and discussed in this article and elsewhere (21).

It is generally recommended that STS should be treated in tumor centers (16, 22–28). However, given the rarity and diversity of these tumors, it is not surprising that excisions are often performed without preoperative suspicion of malignancy and adequate preoperative diagnostic and staging work-up (22, 26, 29). Tumors of the upper extremity are twice as likely to undergo unplanned excision, probably because of their smaller size and more superficial location (30). In our own patient collectively, more than 50% of the patients are referred after such a procedure for further treatment. As shown, resection margins and histopathological assessments from referring institutions are often unreliable and unsuitable for further treatment planning. Moreover, especially in the upper extremity, the risk for residual tumor after unplanned primary excision is high. Although tumors are usually smaller than in the lower extremity, complex regional anatomy may be the reason for close margins or positive margins, necessitating more frequently postoperative radiotherapy. There is significantly more frequent residual disease and local recurrence in the upper extremity, especially around the elbow (10). Completion of diagnostic and staging work-up followed by re-excision is required in this patient group.

Contrast-enhanced MRI represents the standard procedure of diagnostic imaging, as it provides a detailed three-dimensional anatomic presentation of the tumor. With this information, tumor biopsy and excision can be planned (20, 31). A diagnosis can only be achieved by histopathological examination of a representative tumor sample. Therefore, excisional (only for small, superficial tumors) or incisional/punch biopsy has to be performed, as described elsewhere (21, 32). Second opinion reference-center pathology should be indicated generously.

Additionally, before a definitive treatment plan is established, completion of the clinical staging is mandatory. The assessment of tumor size, nodal status, and presence of metastasis has to be performed (TNM status) (33). A spiral CT of the thorax is indicated, as STS are primarily characterized by pulmonary metastasis.

However, at the time of diagnosis, only 10% of the patients present with pulmonary metastasis (34). Only rarely, adult type STS metastasize to regional lymph nodes. Nevertheless, there are some sarcoma subtypes (synovial sarcoma, vascular sarcomas, rhabdomyosarcomas, and epithelioid and clear cell sarcomas) with a higher probability of lymphatic spread. However, the role of sentinel lymph node biopsy in these sarcoma subtypes is still unclear (35, 36). Although positron emission tomography (FDG–PET) has not been yet established as standard imaging modality, it has some relevant advantages. As a functional imaging procedure, FDG–PET provides, besides the metastatic situation of the whole body, data on tumor activity and treatment response after neoadjuvant treatment. However, limited experience, availability, and examination costs are actually restricting factors for standardized use (37).

## TUMOR BOARD REVIEW

Categorization of the patients takes place according to the American Joint Committee on Cancer/International Union against Cancer classification (33, 38). A thorough treatment plan is determined in an interdisciplinary tumor board setting, including oncosurgical, reconstructive, neoadjuvant, and adjuvant treatment options.

## PROGNOSTIC FACTORS

Complete tumor resection is the most important prognostic factor for local and distant disease control (8, 9). If local tumor control is not achieved, there can be no successful treatment. Similarly, the general patient outcome is strongly correlated to distant metastasis. In case of insufficient primary excision and evidence of residual tumor, maximum effort should be made to achieve complete resection by re-excision. Re-excision has to include all previous incisions and drainage exit sites as well as every anatomic compartment suspicious for contamination. Furthermore, the presentation status, whether it is a primary or recurrent tumor, as well as the tumor size (<5 or >5 cm), tumor grading, and extracompartmental location are relevant prognostic factors (8, 9). The specific anatomic tumor location is also a relevant factor: for example, tumor location at the shoulder girdle hampers limb-sparing surgery (39–41). As previously stated, residual disease and recurrence are more common in the upper extremity. Besides anatomical factors, this is also due to the fact that histological entities, which are more common in the upper extremity (angiosarcoma, malignant peripheral nerve sheath tumor), are associated with a higher risk of recurrence (42) that more frequent tumors of the lower extremity, such as low grade liposarcoma.

## ONCOSURGICAL RESECTION

The extent of surgical margins is subject of discussion, as there is no solid evidence. The trend during the past decades has been directed toward reduction of the margins (43, 44). The most frequent type of excision is termed “wide excision,” signifying that the tumor is to be removed within healthy tissue, in the manner

that the tumor is not seen by the surgeon. Contrastingly, the so-called “marginal excision” (excision at the level of the tumor capsule) is not adequate since it does not include a macroscopic layer of uninvolved tissue, which is required by the pathologist in order to certify an R0 status. Resection of the entire compartment, involving all muscles from their origin to the insertion is largely historical and is rarely required. Recently, the type of connective tissue involved was a topic of interest, as sarcomas grow along, rather than transverse, major fascial planes. This enables preservation of major nerves, bones, and muscles with <1 cm resection margin, when fascial planes can be included in the resection (45). Microsurgical techniques enable us to maintain the balance between radical resection and preservation of function. Tumor invasion of nerves is a rare occurrence. In case of close proximity to the tumor, epineural dissection is a safe option (46). Furthermore, neoadjuvant, intraoperative (IORT), or adjuvant radiotherapy treatment modalities additionally contributed to the reduction of resection margins. However, when neurovascular or functional structures cannot be preserved, the oncosurgical defects have to be incorporated into the reconstructive plan.

In cases of advanced disease and extensive infiltration, amputation of the limb is required. Also in these cases, there are useful reconstructive options, such as composite-tissue elbow transfer for reconstruction of the shoulder silhouette (41). In order to offer consultation to these patients, the surgeon also needs to be aware of the current advances in bionic prosthetics, which is a rapidly evolving field offering good solutions. The resected specimen should be clearly marked with sutures and the corresponding sites in the tumor bed with clips. An intraoperative biopsy examination is generally not recommended.

## RECONSTRUCTION

Whenever possible, reconstruction should be achieved as a one-step procedure during tumor excision. Otherwise, wound closure by vacuum-assisted closure can be an alternative, especially when resection margins are uncertain.

The goal of reconstruction is to provide reconstruction of every resected tissue and the related function and to achieve primary wound healing in the interest of timely rehabilitation and adjuvant therapy. In modern reconstructive surgery, it is not sufficient to merely achieve wound closure. It is just as important to strive for optimal functional and esthetic results. For example, split-thickness skin grafts can be transplanted on vital muscle tissue with success. However, this will not lead to an esthetically pleasing result, and it can possibly cause extensive wound healing problems, especially if tendons are exposed. In our patients, almost 70% of the patients with upper extremity sarcoma require reconstructive surgery, compared to 50% at the lower extremity. Reconstructive techniques are more often required in the distal parts of an extremity. In most of these patients, the whole reconstructive armamentarium has to be utilized (16, 18). Due to small case numbers, there is no evidence supporting the use of individual reconstructive techniques, so that the plastic surgeons use the traditional “reconstructive-ladder” when devising the treatment plan. It is, however, common for experienced surgeons, especially in the light of increasing expertise and confidence in

free-flap surgery, to skip one or more ladders in the decision-making process.

Several authors have reported that local or regional flaps are associated with higher complication rates and have inferior functional results compared to free flaps (7, 47), which is also our own experience. Some authors found that free-flap reconstruction after soft tissue sarcoma excision at the upper extremity is associated with increased morbidity but better local control (48). Others found that functional outcome achieved satisfactory levels with both pedicled and free flaps (49).

Proximal upper extremity can be successfully treated with traditional random-pattern flaps or axial-pattern flaps originating from the extremity (lateral upper arm flap) or the shoulder (subscapular vascular territory). Axial flaps, such as dorsal interosseous flap, can be used on the forearm. Local flaps that compromise one of the major vessels, such as the pedicled radial artery flap, are not recommended any more due to extensive donor-site morbidity.

There are several free-flap options with minimal donor-site issues, which are used routinely. Since there is no advantage in using a muscle flap and since there are several good perforator flaps available, the perforator flaps have become the mainstay of modern reconstructive surgery. The workhorse flap for extremity reconstruction is the anterolateral thigh (ALT) flap (17), which enables a two-team parallel approach in the supine position. The parascapular flap is another good alternative, requiring surgery in the lateral position. The thoracodorsal artery perforator (TDAP) flap or the musculocutaneous latissimus-dorsi (LD) flap is available for larger defects.

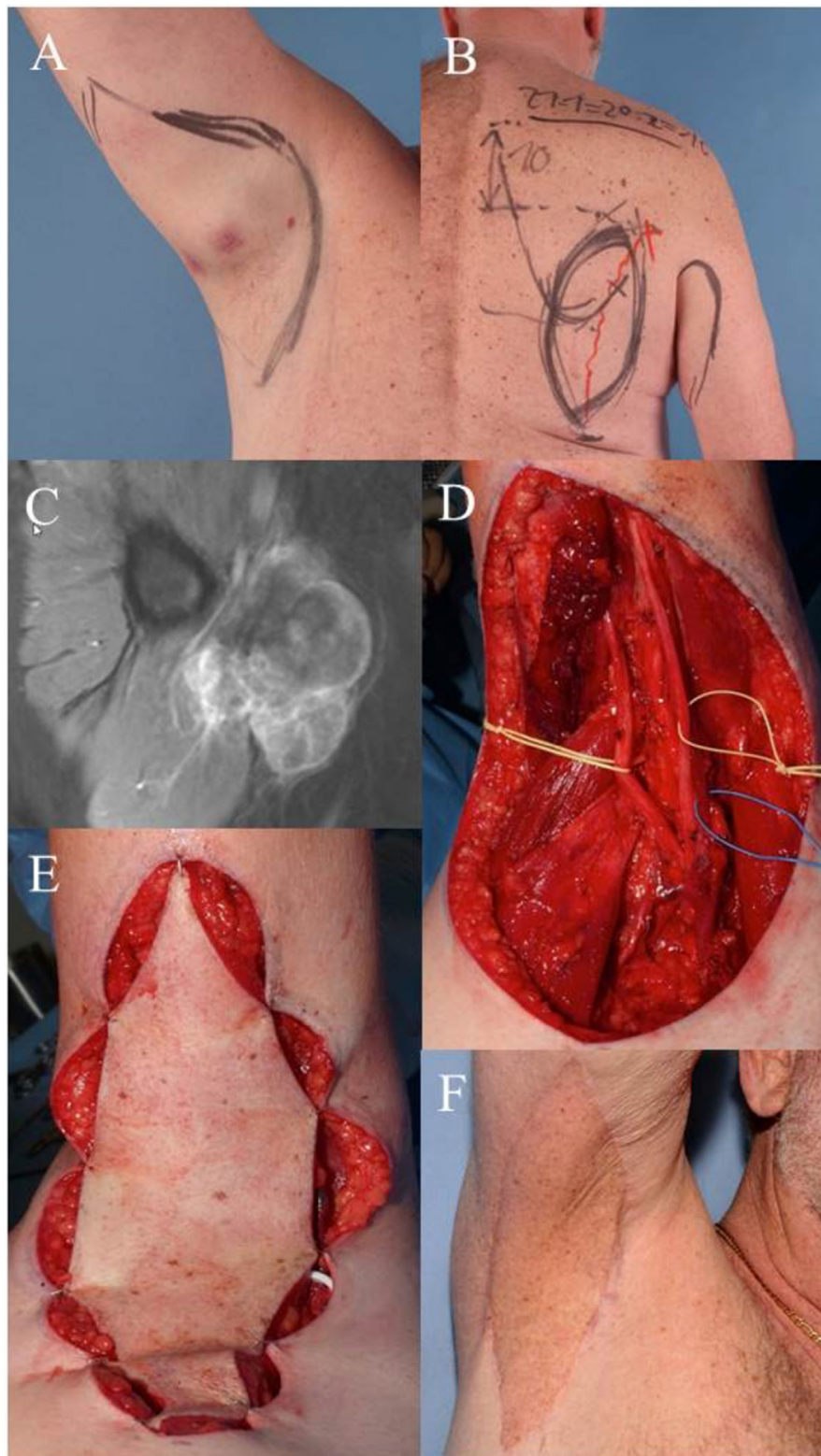
Functional reconstruction of nerve defects (commonly using sural nerve grafting) or blood vessel interposition is also performed at this stage. If there is a tendon defect and the muscle can be preserved, free tendon transplants are performed, usually using the palmaris longus or plantaris tendon. If the muscle has to be sacrificed, the first-line solutions available are the classical tendon transfers, e.g., radial nerve palsy tendon transfer (50). Functional free flaps are rarely required. In this case, free functional gracilis transfer is the primary option, e.g., for reconstruction of finger flexion, as shown in case 3.

## ADJUVANT THERAPY

### Radiation Therapy

Radiation therapy is almost always used as neoadjuvant therapy. The only indication for radiation monotherapy is rare cases that are deemed inoperable because of significant comorbidities. Using the combination of surgical and radiation therapy, 90–95% rates of limb salvage can be achieved. Radiation is usually administered as adjuvant therapy, in a combined dosage of 60–66 Gy with conventional fractionation. The field of radiation includes the tumor bed, margin of safety, as well as scars from previous operations and drainage exit sites. In this way, an improvement of local control for G2 and G3 STS can be achieved. Radiation for G1 tumors is not indicated after R0 resection. Adjuvant radiation can negatively influence complex reconstruction, so that high-grade sarcoma requiring extensive surgery should preferably be treated



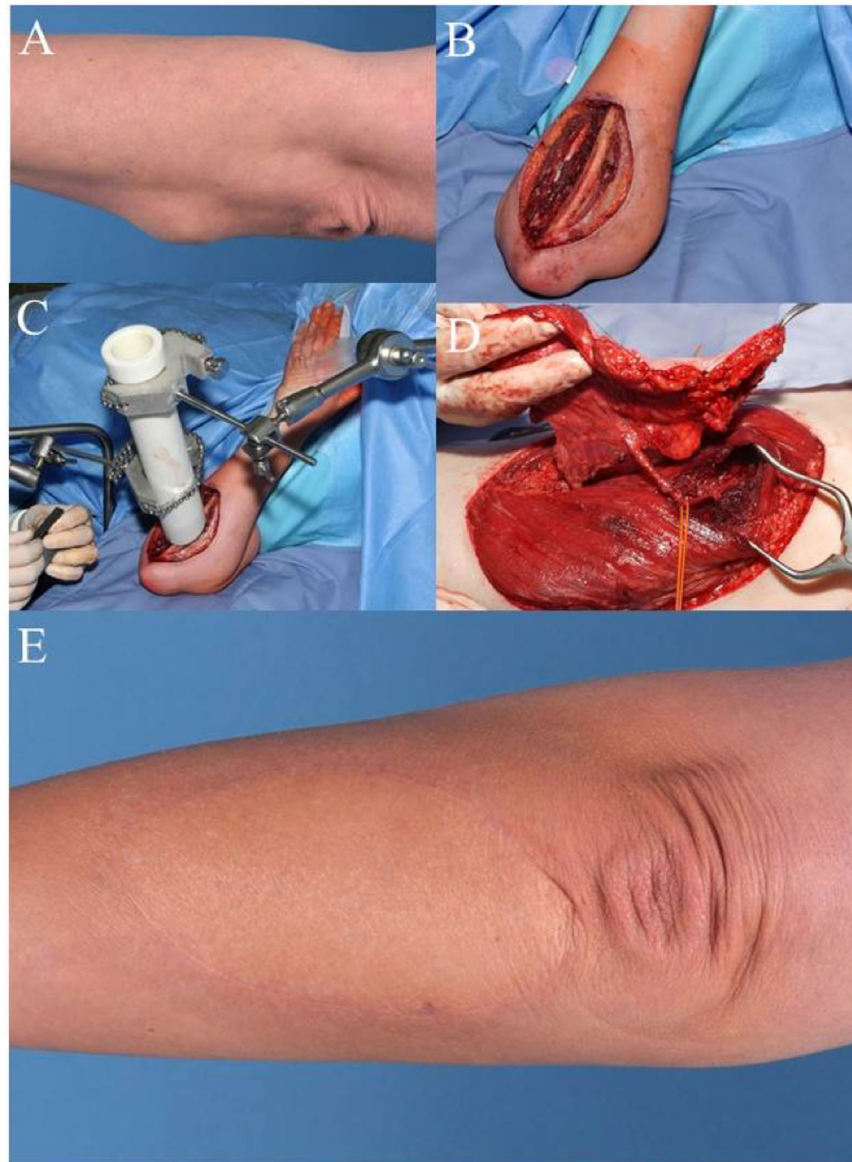


**FIGURE 1 | Case 1: (A) clinical visible mass in the right axilla, pre-OP drawing of the wide resection margins. (B) Pre-OP drawing demonstrates planned pedicled parascapular fasciocutaneous flap. (C) Pre-OP MRI of the right axilla. (D) Intraoperative situation after wide en-bloc excision of tumor. Deep margins were achieved by epineurectomy and adventitiectomy. (E) Pedicled parascapular flap inset reconstructs the defect. (F) Clinical appearance 5 years after surgery and external post-OP radiation therapy.**

with neoadjuvant radiation (51). Neoadjuvant radiation has comparable effects on local disease control as adjuvant therapy. The advantages are that the field of radiation can be kept smaller, and the dosage required (50 Gy) is lower. The often discussed severe postoperative wound healing complications after neoadjuvant radiotherapy are much more frequent in the lower extremity (52). Thus in the upper extremity, this strategy can be applied more liberally by taking advantage of the smaller irradiation field and dose. Intraoperative radiation therapy is always used in addition to neoadjuvant radiation therapy, the dosage of which can be reduced accordingly. Usually, 12–15 Gy are administered to the tumor bed (case 2).

## Chemotherapy

Most types of STS are not very sensitive to chemotherapy, with exception of small-round-blue-cell tumors, extraosseous Ewing sarcoma, rhabdomyosarcoma, primitive neuroectodermal tumor, and desmoplastic small-round-cell tumor. Despite an increase in experimental data, there is still limited application of molecular-targeted therapy for treatment of STS. Two examples of successful targeted therapy are the use of imatinib in treatment of dermatofibrosarcoma protuberans and the use of sorafenib in treatment of angiosarcoma. The use of standard chemotherapeutics, such as anthracyclines or ifosfamide after R0 resection, is not generally recommended.



**FIGURE 2 | Case 2: (A) pre-OP picture shows mass in the proximal forearm. (B) Intra-OP situation after wide en-bloc excision. (C) Intra-OP application of radiation therapy in the wound bed close to the ulna (15 Gy). (D) Raised anterolateral thigh flap from the left leg for microvascular reconstruction. (E) Clinical appearance of the reconstructed forearm 1 year after additional external radiation therapy (50.4 Gy).**



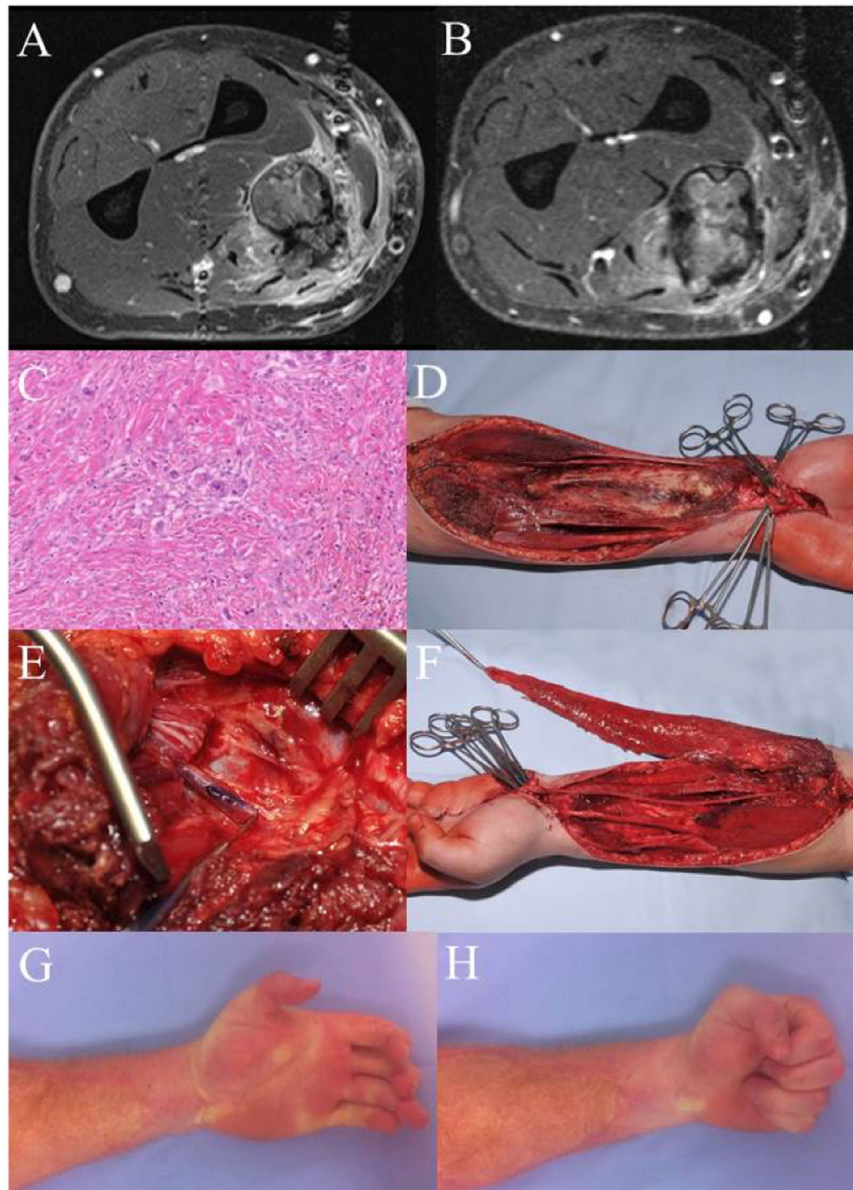
## Hyperthermia and Isolated Limb Perfusion

The combination of neoadjuvant or adjuvant chemotherapy and regional hyperthermia, possibly with additional radiation therapy, can improve local disease control in locally advanced tumors. Isolated limb perfusion with tumor necrosis factor alpha or melphalan can be considered in tumors, which cannot be

resected with R0 margins, or when surgical excision would lead to mutilating loss of function.

## CONCLUSION

To achieve optimal outcomes, treatment of STS of the upper extremity should be carried out at experienced institutions where



**FIGURE 3 | Case 3: (A)** MRI left forearm before radiation. **(B)** MRI left forearm post radiation. **(C)** H&E specimen showing only few scattered remaining tumor cells as a result of the preoperative radiotherapy. **(D)** Intraoperative situation after en-bloc excision of the flexor compartment. **(E)** Intraoperative detail photography of the transected median nerve. The blue marking shows the motor branch to the deep flexors, later used for nerve coaptation to the obturator branch of the transferred gracilis muscle. **(F)** Gracilis muscle after microvascular transfer and motor nerve coaptation. After defining the proper tension, the muscle will be fixed to the deep flexor tendons (II–V). Flexor pollicis longus function was reconstructed using a brachioradial tendon transfer. **(G,H)** Clinical result 5 years after therapy. There is a remaining extension deficit, but a full finger flexion with a strong grip could be achieved. Patient is in complete remission and rehabilitated in his original job as a truck driver.



all relevant disciplines are represented. Each sarcoma has its specific histopathological phenotype, grading, size, and, importantly, specific anatomical localization within the complex anatomy of the arm.

Nevertheless, widely accepted treatment principles exist that can be adapted to the individual situation. Prior to treatment, it is mandatory to discuss the case in a multidisciplinary conference defining the use and the sequence of treatment modalities. The mainstay of local tumor control – the prerequisite for curing the patient – is surgery. A radical oncosurgical approach in the upper extremity requires plastic-reconstructive procedures in more than 70% of the cases. The continuously expanding plastic-surgical options for reconstruction of surface, volume, and function enable surgeons to customize the oncosurgical procedure and to preserve the upper extremity with a good oncological and functional result in most of the cases.

## CASE DEMONSTRATIONS

Case 1 (**Figure 1**) demonstrates the case of a 64-year-old male patient suffering from a high-grade pleomorphic sarcoma in the right axilla (T2b, N0, M0, G3). A wide excision was planned and carried out with sufficient removal of skin and subcutaneous tissue due to the extracompartmental localization of the sarcoma. Margins to the deep structures of the axilla could be achieved by thorough dissection of the nerve and vessel sheaths. The transfer of a pedicled parascapular flap was performed in the same operation. Noteworthy, we dissect the pedicle completely back through the medial axillary gap, ligating the osseous branches of the circumflex scapular artery. The flap can be advanced through this tunnel, allowing a completely tension-free placement in the axilla. The patient is shown 5 years after surgery and post-OP radiation therapy with an excellent functional result. The parascapular flap delivers sufficient pliable soft tissue coverage avoiding functional impairment of shoulder movement (53–55).

Case 2 (**Figure 2**) shows a 47-year-old female patient with fast recurrence of an incompletely resected high-grade sarcoma of the left forearm (pleomorphic sarcoma, initially T1b, N0, M0, G3). She had undergone the so-called “whoops procedure” – a term referring to an unplanned sarcoma resection where no malignancy had been suspected. A wide resection was performed with partial removal of the ulnar periosteum. The deep tumor bed was treated with an internal radiation therapy with the application of 15 Gy, thus reducing the post-OP dose from 65 to 50 Gy. Distal to the elbow, large defects are difficult to cover with local tissue transfer. The transfer of a free-flap offers an

elegant option to avoid additional morbidity in proximity to the tumor region. The demonstrated ALT flap is one of the “work-horse” microvascular flaps in reconstructive tumor surgery of the extremities (17).

Case 3 (**Figure 3**) shows a 29-year-old patient with an epithelioid cell sarcoma (T2b, N0, M0, G3) of the left forearm within the flexor compartment. Crucial structures (flexor muscles, median nerve, and radial artery) are involved. When complex functional reconstruction of those structures is necessary, postoperative radiation therapy should be avoided, which is why preoperative radiation therapy (50 Gy) was conducted in this case. The MRI pre- and postradiation do not differ much in tumor size, but a significant reduced contrast enhancement can be demonstrated. Histology reflects good response to radiation therapy with only few vital, scattered tumor cells. Radical resection was carried out with en-bloc removal of all flexors (except FCU), the median nerve, and the radial artery. Sensory reconstruction was performed *via* multiple sural nerve cable grafts, which resulted in recovery of protection sensation. Functional reconstruction for the flexors was achieved with a free microvascular, functional gracilis muscle transfer, covered with a split-thickness skin graft (56). The patient has recovered quite well from this radical approach and is rehabilitated in his former job as truck driver. In the upper extremity, much less wound healing complications arise from this sequence of treatment modalities, especially when free tissue transfer is performed. In the lower extremity, there is a higher occurrence of severe wound healing complications after preoperative radiation.

## ETHICS STATEMENT

Written informed consent was obtained from the patients prior to presenting the cases.

## AUTHOR CONTRIBUTIONS

GK: data acquisition, literature search, manuscript preparation, and final approval. FS: data acquisition, critical manuscript review, literature search, and final approval. HB: data acquisition, case reports, critical manuscript review, and final approval.

## ACKNOWLEDGMENTS

The authors thank Dr. Philipp Kurz (Department of Pathology, University Medical Center Freiburg) for the histological slide in case 3.

## REFERENCES

- Jemal A, Tiwari RC, Murray T, Ghafoor A, Samuels A, Ward E, et al. Cancer statistics, 2004. *CA Cancer J Clin* (2004) 54:8–29. doi:10.3322/canjclin.54.1.8
- Jane MJ, Hughes PJ. Disease incidence and results of extremity lesion treatment: Mersey region soft tissue sarcomas (1975–1985). *Sarcoma* (1998) 2:89–96. doi:10.1080/13577149878046
- Lahat G, Lazar A, Lev D. Sarcoma epidemiology and etiology: potential environmental and genetic factors. *Surg Clin North Am* (2008) 88:451–81. doi:10.1016/j.suc.2008.03.006
- Gustafson P, Arner M. Soft tissue sarcoma of the upper extremity: descriptive data and outcome in a population-based series of 108 adult patients. *J Hand Surg Am* (1999) 24:668–74. doi:10.1053/jhsu.1999.0406
- Muller M, Bickert B, Germann G, Sauerbier M. [Soft-tissue sarcoma of the forearm and hand. Plastic surgical management]. *Chirurg* (2008) 79:682–8. doi:10.1007/s00104-008-1529-3
- Muramatsu K, Ihara K, Doi K, Hashimoto T, Taguchi T. Sarcoma in the forearm and hand: clinical outcomes and microsurgical reconstruction for limb salvage. *Ann Plast Surg* (2009) 62:28–33. doi:10.1097/SAP.0b013e3181743a11
- Barner-Rasmussen I, Popov P, Bohling T, Blomqvist C, Tukiainen E. Microvascular reconstructions after extensive soft tissue sarcoma

- resections in the upper limb. *Eur J Surg Oncol* (2010) **36**:78–83. doi:10.1016/j.ejso.2009.08.003
8. Lehnhardt M, Hirche C, Daigeler A, Goertz O, Ring A, Hirsch T, et al. [Soft tissue sarcoma of the upper extremities. Analysis of factors relevant for prognosis in 160 patients]. *Chirurg* (2012) **83**:143–52. doi:10.1007/s00104-011-2124-6
  9. Baroudi MR, Ferguson PC, Wunder JS, Isler MH, Mottard S, Werier JA, et al. Forearm soft tissue sarcoma: tumors characteristics and oncologic outcomes following limb salvage surgery. *J Surg Oncol* (2014) **110**:676–81. doi:10.1002/jso.23686
  10. Gerrand CH, Bell RS, Wunder JS, Kandel RA, O'Sullivan B, Catton CN, et al. The influence of anatomic location on outcome in patients with soft tissue sarcoma of the extremity. *Cancer* (2003) **97**:485–92. doi:10.1002/cncr.11076
  11. Cantin J, Mcneer GP, Chu FC, Booher RJ. The problem of local recurrence after treatment of soft tissue sarcoma. *Ann Surg* (1968) **168**:47–53. doi:10.1097/00000658-196807000-00005
  12. Hoekstra HJ, Thijssens G, Van Ginkel RJ. Role of surgery as primary treatment and as intervention in the multidisciplinary treatment of soft tissue sarcoma. *Ann Oncol* (2004) **15**(Suppl 4):iv181–6. doi:10.1093/annonc/mdh924
  13. Canter RJ, Beal S, Borys D, Martinez SR, Bold RJ, Robbins AS. Interaction of histologic subtype and histologic grade in predicting survival for soft-tissue sarcomas. *J Am Coll Surg* (2010) **210**(191–198):e192. doi:10.1016/j.jamcollsurg.2009.10.007
  14. Clark MA, Fisher C, Judson I, Thomas JM. Soft-tissue sarcomas in adults. *N Engl J Med* (2005) **353**:701–11. doi:10.1056/NEJMra041866
  15. Gronchi A, Olmi P, Casali PG. Combined modalities approach for localized adult extremity soft-tissue sarcoma. *Expert Rev Anticancer Ther* (2007) **7**:1135–44. doi:10.1586/14737140.7.8.1135
  16. Bannasch H, Haivas I, Momeni A, Stark GB. Oncosurgical and reconstructive concepts in the treatment of soft tissue sarcomas: a retrospective analysis. *Arch Orthop Trauma Surg* (2009) **129**:43–9. doi:10.1007/s00402-008-0576-z
  17. Momeni A, Kalash Z, Stark GB, Bannasch H. The use of the anterolateral thigh flap for microsurgical reconstruction of distal extremities after oncosurgical resection of soft-tissue sarcomas. *J Plast Reconstr Aesthet Surg* (2011) **64**:643–8. doi:10.1016/j.bjps.2010.08.005
  18. Penna V, Iblher N, Momeni A, Stark GB, Bannasch H. Free tissue transfer in reconstruction following soft tissue sarcoma resection. *Microsurgery* (2011) **31**:434–40. doi:10.1002/micr.20895
  19. Gronchi A, Lo Vullo S, Colombo C, Collini P, Stacchiotti S, Mariani L, et al. Extremity soft tissue sarcoma in a series of patients treated at a single institution: local control directly impacts survival. *Ann Surg* (2010) **251**:506–11. doi:10.1097/SLA.0b013e3181cf87fa
  20. Berger F, Winkler EC, Ruderer C, Reiser MF. [Imaging of soft tissue sarcomas: standard approaches and new strategies]. *Chirurg* (2009) **80**:175–85. doi:10.1007/s00104-008-1594-7
  21. Bannasch H, Eisenhardt SU, Grosu AL, Heinz J, Momeni A, Stark GB. The diagnosis and treatment of soft tissue sarcomas of the limbs. *Dtsch Arztebl Int* (2011) **108**:32–8. doi:10.3238/arztebl.2011.0032
  22. Noria S, Davis A, Kandel R, Levesque J, O'Sullivan B, Wunder J, et al. Residual disease following unplanned excision of soft-tissue sarcoma of an extremity. *J Bone Joint Surg Am* (1996) **78**:650–5.
  23. Davis AM, Kandel RA, Wunder JS, Unger R, Meer J, O'Sullivan B, et al. The impact of residual disease on local recurrence in patients treated by initial unplanned resection for soft tissue sarcoma of the extremity. *J Surg Oncol* (1997) **66**:81–7. doi:10.1002/(SICI)1096-9098(199710)66:2<81::AID-JSO2>3.0.CO;2-H
  24. Rydholm A. Improving the management of soft tissue sarcoma. Diagnosis and treatment should be given in specialist centres. *BMJ* (1998) **317**:93–4. doi:10.1136/bmj.317.7151.93
  25. Siebenrock KA, Hertel R, Ganz R. Unexpected resection of soft-tissue sarcoma. More mutilating surgery, higher local recurrence rates, and obscure prognosis as consequences of improper surgery. *Arch Orthop Trauma Surg* (2000) **120**:65–9.
  26. Bhangu AA, Beard JA, Grimer RJ. Should soft tissue sarcomas be treated at a specialist centre? *Sarcoma* (2004) **8**:1–6. doi:10.1080/13577140410001679185
  27. Gutierrez JC, Perez EA, Moffat FL, Livingstone AS, Franceschi D, Koniaris LG. Should soft tissue sarcomas be treated at high-volume centers? An analysis of 4205 patients. *Ann Surg* (2007) **245**:952–8. doi:10.1097/01.sla.0000250438.04393.a8
  28. Lehnhardt M, Daigeler A, Homann HH, Hauser J, Langer S, Steinstrasser L, et al. [Importance of specialized centers in diagnosis and treatment of extremity-soft tissue sarcomas. Review of 603 cases]. *Chirurg* (2009) **80**:341–7. doi:10.1007/s00104-008-1562-2
  29. Giuliano AE, Eilber FR. The rationale for planned reoperation after unplanned total excision of soft-tissue sarcomas. *J Clin Oncol* (1985) **3**:1344–8.
  30. Korah MP, Deyrup AT, Monson DK, Oskoue SV, Weiss SW, Landry J, et al. Anatomic tumor location influences the success of contemporary limb-sparing surgery and radiation among adults with soft tissue sarcomas of the extremities. *Int J Radiat Oncol Biol Phys* (2012) **82**:933–9. doi:10.1016/j.ijrobp.2010.11.020
  31. Misra A, Mistry N, Grimer R, Peart F. The management of soft tissue sarcoma. *J Plast Reconstr Aesthet Surg* (2009) **62**:161–74. doi:10.1016/j.bjps.2008.08.018
  32. Megerle K, Sauerbier M. Reconstructive treatment of soft tissue sarcoma of the upper extremity. *J Hand Surg Am* (2011) **36**:1241–7. doi:10.1016/j.jhsa.2011.04.017
  33. Greene FL; American Joint Committee on Cancer. *AJCC Cancer Staging Atlas*. New York, NY: Springer (2006).
  34. Dadia S, Grimer R. Characteristics, diagnosis and treatment of bone and soft tissue sarcomas. *Br J Hosp Med (Lond)* (2007) **68**:589–93. doi:10.12968/hmed.2007.68.11.27680
  35. Tunn PU, Andreou D, Illing H, Fleige B, Dresel S, Schlag PM. Sentinel node biopsy in synovial sarcoma. *Eur J Surg Oncol* (2008) **34**:704–7. doi:10.1016/j.ejso.2007.07.014
  36. Maduekwe UN, Hornicek FJ, Springfield DS, Raskin KA, Harmon DC, Choy E, et al. Role of sentinel lymph node biopsy in the staging of synovial, epithelioid, and clear cell sarcomas. *Ann Surg Oncol* (2009) **16**:1356–63. doi:10.1245/s10434-009-0393-9
  37. Schuetz SM. Utility of positron emission tomography in sarcomas. *Curr Opin Oncol* (2006) **18**:369–73. doi:10.1097/01.cco.0000228744.49294.12
  38. Lahat G, Tuvin D, Wei C, Anaya DA, Bekele BN, Lazar AJ, et al. New perspectives for staging and prognosis in soft tissue sarcoma. *Ann Surg Oncol* (2008) **15**:2739–48. doi:10.1245/s10434-008-9970-6
  39. Litasova EE. [Three operations of intrascapulo-thoracic amputation for sarcoma of the shoulder girdle]. *Vestn Khir Im I I Grek* (1957) **79**:127–8.
  40. Marinescu S, Giuglea C, Mihai R, Oporanu A, Manea S, Florescu IP. Forequarter amputation (upper limb and shoulder girdle) in a synovial sarcoma case – case report. *J Med Life* (2010) **3**:444–8.
  41. Koulaxouzidis G, Simunovic F, Stark GB. Shoulder silhouette and axilla reconstruction with free composite elbow tissue transfer following interscapulothoracic amputation. *J Plast Reconstr Aesthet Surg* (2014) **67**:81–6. doi:10.1016/j.bjps.2013.10.040
  42. Collin C, Hajdu SI, Godbold J, Friedrich C, Brennan MF. Localized operable soft tissue sarcoma of the upper extremity. Presentation, management, and factors affecting local recurrence in 108 patients. *Ann Surg* (1987) **205**:331–9. doi:10.1097/00000658-198704000-00001
  43. Dickinson IC, Whitwell DJ, Battistuta D, Thompson B, Strobel N, Duggal A, et al. Surgical margin and its influence on survival in soft tissue sarcoma. *ANZ J Surg* (2006) **76**:104–9. doi:10.1111/j.1445-2197.2006.03615.x
  44. Tunn PU, Kettelhack C, Durr HR. Standardized approach to the treatment of adult soft tissue sarcoma of the extremities. *Recent Results Cancer Res* (2009) **179**:211–28. doi:10.1007/978-3-540-77960-5\_13
  45. Daigeler A, Harati K, Goertz O, Hirsch T, Steinau HU, Lehnhardt M. [Prognostic factors and surgical tactics in patients with locally recurrent soft tissue sarcomas]. *Handchir Mikrochir Plast Chir* (2015) **47**:118–27. doi:10.1055/s-0034-1394425
  46. Clarkson PW, Griffin AM, Catton CN, O'Sullivan B, Ferguson PC, Wunder JS, et al. Epineural dissection is a safe technique that facilitates limb salvage surgery. *Clin Orthop Relat Res* (2005) **438**:92–6. doi:10.1097/01.blo.0000180057.22712.53
  47. Vinals JM, Rodrigues TA, Sildenikova DP, Payro JM, Porte JA, Sune CH, et al. Indications of microsurgery in soft tissue sarcomas. *J Reconstr Microsurg* (2012) **28**:619–25. doi:10.1055/s-0032-1326740
  48. Kang S, Han I, Kim S, Lee YH, Kim MB, Kim HS. Outcomes after flap reconstruction for extremity soft tissue sarcoma: a case-control study using propensity score analysis. *Eur J Surg Oncol* (2014) **40**:1101–8. doi:10.1016/j.ejso.2014.05.004

49. Payne CE, Hofer SO, Zhong T, Griffin AC, Ferguson PC, Wunder JS. Functional outcome following upper limb soft tissue sarcoma resection with flap reconstruction. *J Plast Reconstr Aesthet Surg* (2013) **66**:601–7. doi:10.1016/j.bjps.2013.01.034
50. Koulaxouzidis G, Stark GB, Lampert FM. [Motor replacement surgery via tendon transfer in radial nerve palsy]. *Oper Orthop Traumatol* (2015) **27**:47–62. doi:10.1007/s00064-014-0322-3
51. Townley WA, Mah E, O'Neill AC, Wunder JS, Ferguson PC, Zhong T, et al. Reconstruction of sarcoma defects following pre-operative radiation: free tissue transfer is safe and reliable. *J Plast Reconstr Aesthet Surg* (2013) **66**:1575–9. doi:10.1016/j.bjps.2013.06.029
52. O'Sullivan B, Davis AM, Turcotte R, Bell R, Catton C, Chabot P, et al. Preoperative versus postoperative radiotherapy in soft-tissue sarcoma of the limbs: a randomised trial. *Lancet* (2002) **359**:2235–41. doi:10.1016/S0140-6736(02)09292-9
53. Kim PS, Lewis VL Jr. Use of a pedicled parascapular flap for anterior shoulder and arm reconstruction. *Plast Reconstr Surg* (1985) **76**:942–4. doi:10.1097/00006534-198512000-00029
54. Klinkenberg M, Fischer S, Kremer T, Hernekamp F, Lehnhardt M, Daigeler A. Comparison of anterolateral thigh, lateral arm, and parascapular free flaps with regard to donor-site morbidity and aesthetic and functional outcomes. *Plast Reconstr Surg* (2013) **131**:293–302. doi:10.1097/PRS.0b013e31827786bc
55. Sachs C, Lehnhardt M, Daigeler A, Goertz O. [Free fasciocutaneous parascapular flap. Coverage of extensive skin and soft tissue defects]. *Unfallchirurg* (2015) **118**:881–4. doi:10.1007/s00113-014-2686-0
56. Ihara K, Shigetomi M, Kawai S, Doi K, Yamamoto M. Functioning muscle transplantation after wide excision of sarcomas in the extremity. *Clin Orthop Relat Res* (1999) (358):140–8.

**Conflict of Interest Statement:** There is no conflict of interest. There was no payment or services from a third party for any aspect of the submitted work.

Copyright © 2016 Koulaxouzidis, Simunovic and Bannasch. This is an open-access article distributed under the terms of the Creative Commons Attribution License (CC BY). The use, distribution or reproduction in other forums is permitted, provided the original author(s) or licensor are credited and that the original publication in this journal is cited, in accordance with accepted academic practice. No use, distribution or reproduction is permitted which does not comply with these terms.





# Reconstruction of Soft-Tissue Defects at the Foot and Ankle after Oncological Resection

Andrej Ring<sup>\*†</sup>, Pascal Kirchhoff, Ole Goertz, Bjorn Behr, Adrien Daigeler, Marcus Lehnhardt and Kamran Harati

Department for Plastic and Hand Surgery, Burn Center/Sarcoma Reference Center, Ruhr-University Bochum, Bochum, Germany

## OPEN ACCESS

### Edited by:

Gyu Seog Choi,  
Kyungpook National University  
Medical Center, South Korea

### Reviewed by:

Andreas Arkudas,  
University Hospital of Erlangen,  
Germany  
Osama Hussein,  
Mansoura University, Egypt

### \*Correspondence:

Andrej Ring  
a.ring@lukas-gesellschaft.de

### †Present address:

Andrej Ring,  
Department of Plastic Surgery,  
St. Rochus Hospital,  
Castrop-Rauxel, Germany

### Specialty section:

This article was submitted to  
Surgical Oncology,  
a section of the journal  
Frontiers in Surgery

**Received:** 10 August 2015

**Accepted:** 24 February 2016

**Published:** 08 March 2016

### Citation:

Ring A, Kirchhoff P, Goertz O, Behr B, Daigeler A, Lehnhardt M and Harati K (2016) Reconstruction of Soft-Tissue Defects at the Foot and Ankle after Oncological Resection. *Front. Surg.* 3:15. doi: 10.3389/fsurg.2016.00015

**Introduction:** Solid malignancies at the foot and ankle region are rare and include mainly soft-tissue sarcomas, bone sarcomas, and skin malignancies. Complete surgical resection with clear margins still remains the mainstay of therapy in these malignancies. However, attainment of negative surgical margins in patients with locally advanced tumors of the foot and ankle region may require extensive surgery and could result in loss of extremity function. In these circumstances, plastic surgical techniques can frequently reduce functional impairment and cover soft-tissue defects, particularly in cases of large tumor size or localization adjacent to critical anatomic structures, thereby improving the quality of life for these patients. The aim of this article is to illustrate the various treatment options of plastic surgery in the multimodal therapy of patients with malignant tumors of the foot and ankle region.

**Materials and methods:** This article is based on the review of the current literature and the evaluation of the author's own patient database.

**Results:** The local treatment of malignant extremity tumors has undergone major changes over the last few decades. Primary amputations have been increasingly replaced by limb-sparing techniques, preserving extremity function as much as possible. Although defect coverage at the foot and ankle region is demanding due to complex anatomical features and functional requirements, several plastic surgical treatment options can be implemented in the curative treatment of patients with malignant solid tumors in this area. Soft-tissue defects after tumor resection can be covered by a variety of local flaps. If local flaps are not applicable, free flap transfers, such as the anterolateral thigh flap, parascapular flap, or latissimus dorsi flap, can be utilized to cover nearly all kinds of defects in the foot and ankle region.

**Conclusion:** Soft-tissue reconstruction in the foot and ankle region is a vital component of limb-sparing surgery. It enables complete resection of locally advanced tumors and subsequent adjuvant radiotherapy. Modern plastic surgical techniques should, therefore, be integrated in the multimodal treatment concept of malignancies in the foot and ankle region.

**Keywords:** sarcoma, reconstructive surgical procedures, lower extremity, microsurgery, flap

## TUMORS OF THE FOOT AND ANKLE REGION

Malignant neoplasms on the foot and ankle make up about 4% of all bone and soft-tissue tumors of the body (1–3). Soft-tissue sarcomas, as rare tumors of mesenchymal origin, account for about 1% of all adult malignancies but are located in the extremities in about 60% of all cases (4). Regarding the content of soft tissues, the lower extremities are affected more frequently than the upper extremities, with a ratio of 3:1. Other rare malignancies with localization at the foot are, for example, tumors of the skin, such as melanoma, and giant cell tumors of the tendon-sheath, vascular sarcomas, and carcinoma metastases. The local treatment of soft-tissue sarcomas has undergone major changes over the last few decades. Primary amputations have been increasingly replaced by limb-sparing techniques, preserving extremity function as much as possible (3, 5). Interestingly, a recently published meta-analysis revealed that the width of negative surgical margins has no significant impact on overall survival (6). The data within the latter suggested that patients with clear margins had a better prognosis, but surgery to preserve functionality may result in very close margins without impairing survival. However, in patients with locally advanced soft-tissue sarcomas of the extremities, attainment of negative surgical margins may require extensive surgery and could result in a loss of extremity function. In these circumstances, plastic surgical techniques can frequently reduce functional impairment and cover soft-tissue defects, particularly in cases of large tumor size or localization adjacent to critical anatomic structures, thereby improving the quality of life for these patients. Whether limb preservation or ablative procedures are applied is also determined by the location of the tumor and the expectations and the functional demands of the patient.

## ONCOLOGICAL TREATMENT STRATEGIES AND CONCEPTS

Contemporary treatment strategies should include concepts of complete resection with negative surgical margins in combination with plastic reconstructive surgery, especially considering the postoperative functional aspects. The factors that determine the resectability of sarcomas are mainly the tumor size and localization. Regarding surgical resectability, the localization of the tumor is of great relevance. Deep or subfascial localization is associated with a higher risk of local recurrence or distant metastasis when compared with superficial or epifascial localization (7–9). Regarding tumor size, large soft-tissue sarcomas are shown to have a diminished survival when compared with small tumors. However, large tumor size is found more frequently in high-grade tumors. Most survival studies have revealed that the tumor grade is the most significant prognostic factor (9, 10). Dedifferentiated and high tumor grade is also associated with higher invasiveness, resulting in extensive infiltration of the surrounding tissues.

In cases with extensive infiltration of functional structures, amputation still has to be considered as a treatment option in order to obtain clear margins (7, 11, 12). However, the fact that amputation as a curative treatment strategy for sarcomas in the

extremities has no survival benefit when compared to limb-preserving surgical procedures should be taken into account. It has been shown that amputation, especially in combination with radiotherapy, has no advantage compared to resection (6). The use of reconstructive surgery and adjuvant radiation since the 1980s has been able to reduce the amputation rate to less than 20% (13–16). The incidence of local recurrences under limb preservation therapy has decreased to 10–15% in recent years; however, no change in terms of overall survival has been shown (17, 18). Local control rates for high-grade tumors amounted to about 90% and to 90–100% for low-grade sarcomas. Notably, high-grade tumors are associated with a higher risk of local recurrence (19, 20). Subsequently, local recurrence has been found to be associated with a diminished survival when compared with the primary disease (7, 21, 22). Nowadays, primary indications for amputations are fortunately rare. Primary amputations are indicated when negative margins are not otherwise attainable. However, whenever an amputation is deemed necessary to obtain local control of an extremity soft-tissue sarcoma, isolated limb perfusion should be considered. Tumor necrosis factor alpha-based isolated limb perfusion has been demonstrated to result in a limb salvage rate of 81% in patients with locally advanced extremity soft-tissue sarcoma who would have otherwise undergone amputation (23, 24). The second indication for primary amputation is the palliation of extensive ulcerative, bleeding, or odor-intensive tumors with complete loss of extremity function. A primary amputation must also be drawn early into consideration when satisfactory functional results cannot be expected from reconstructive techniques after extensive or disabling limb-sparing resections. In such cases, timely recovery and mobilization might be achieved earlier after primary amputation.

## PRINCIPLES OF TUMOR RESECTION AT THE FOOT AND ANKLE

The implementation of a radical surgical procedure in the distal region of the limb is often difficult due to a limited soft-tissue situation. Attainment of clear margins becomes much more difficult in distal tumors and can result in soft-tissue defects. Plastic surgical techniques remain particularly indispensable in the treatment of such distal tumors. The extent of resection after histological confirmation depends on the size, grading, and local relationship to functional structures. Decisions regarding further leading reconstructive procedures also depend on it. Negative margins should be the goal of surgical therapy. Performance of the appropriate margins in soft-tissue sarcomas is often complicated by the extended growth of the tumor. Margins to adjacent functional structures should be taken into account in the oncosurgical considerations. These functional structures are fascia, synovia, periosteum, and perivascular and perineural tissue. When there is tumor infiltration of such structures, en-block resection should be performed. The course of vascular structures should be taken into account during the resection to allow planning of reconstructive procedures by using pedicled or free tissue transplantation.

## ANATOMICAL AND SURGICAL FEATURES

Whereas limb salvage has become the standard of care in the treatment of tumor in an extremity, the unique anatomy of the foot presents challenges in reconstructing a viable and functional limb. The defect coverage in the area of the foot and ankle region is demanding due to complex anatomical features and functional requirements. The skeletal stability of the foot and ankle region, the resilience of the soft tissues, and the preservation of sensation are at the forefront of reconstructive considerations. Here, profound knowledge of the anatomy of the foot and ankle area is essential for the development of a rational treatment algorithm for covering soft-tissue defects. Hidalgo and Shaw studied the arterial anatomy and the cutaneous nerve supply of the plantar skin extensively in the 1980s, providing guidelines of safe plantar incisions and flap design (25, 26). Prior to their work, flap designs on the plantar aspect of the foot were based on the concept that blood supply proceeds from the deep to the superficial tissue. Therefore, plantar flaps were usually raised subfascially requiring extensive dissection of the plantar soft tissue and, thus, resulting in severe foot and donor site morbidities (27). However, Hidalgo and Shaw demonstrated that local flaps at the plantar aspect could be designed with preserved sensitivity and abundant blood supply as reliable and safe alternatives without the need of subfascial dissection. Based on their findings, they further divided the foot into four major areas based on different requirements for reconstruction and the types of flaps available (28, 29). These are the proximal and distal weight-bearing plantar areas, the dorsum and the ankle region including the malleoli, the Achilles tendon, and the non-weight-bearing heel area. Furthermore, they provided a classification of foot defects and an algorithm of their coverage whose principles are still relevant. They preferred to cover soft-tissue losses less than 3 cm<sup>2</sup> with local flaps in weight-bearing areas and with skin grafts in non-weight-bearing areas (Type I). Local flaps are more durable than skin grafts and allow normal weight-bearing on the reconstructed surface. Plain local flaps, such as V-Y flaps and transposition flaps, should be preferred to avoid a soft-tissue surplus, which could enhance strains on the scar at walking and, thus, increasing the risk of ulceration. Skin grafting represents a simple and safe procedure to cover small defects with a well-vascularized wound bed. However, skin grafts are usually suitable for smaller defects at the dorsum and non-weight-bearing areas at the instep but are fragile and can generate painful scars and ulcerations when transplanted on tenuous soft tissue. Therefore, Hidalgo and Shaw do not recommend skin grafting alone for larger defects. Such Type II defects, which are defined to be larger than 3 cm<sup>2</sup> without bone involvement were preferred to be covered by free fasciocutaneous, free musculocutaneous flaps, or local flaps to ensure a durable soft-tissue coverage preventing recurrent ulcerations, improving the scar qualities, and reducing strains on the scars. Large tissue losses with bone involvement (Type III) were recommended to be reconstructed with free flaps or free osteocutaneous transfers if necessary. Here, adequate soft-tissue coverage also provides an essential base for following necessary surgical bone procedures. Bulky soft-tissue surpluses can be thinned out easily in future procedures after healing.

The reconstruction of the highly specific, thick, load-capable, and stress-resistant skin of the weight-bearing proximal and distal plantar area is more difficult, because the patient's own tissue from other donor regions of the body does not often meet the requirements with regard to tissue quality and functional needs. By contrast, soft-tissue coverage of the dorsum of the foot and the ankle region is of thin and pliable skin with a delicate subcutaneous adipose tissue layer. This feature is often severe in surgical interventions, for example, in osteosynthetic care of ankle fractures. In this case, due to the peculiarity of the soft-tissue cover, wound complications with exposure of structures, such as tendons, joint capsule, bone, and hardware, can occur. Furthermore, the mobility of the soft tissue covering the foot and ankle is due to quite limited multiple zones of adherence. Consequently, defects in serving areas can rarely be treated by local tissue displacement. In such cases, tissue from other parts of the body must be free transplanted. However, the tissue units used for microvascularized transfer are often bulky and have to be thinned out and adapted in the course of correction operations for subsequent shoe care and esthetic perception. Furthermore, the fact that the free transplanted tissue is not innervated must be considered. This fact may stimulate the formation of pressure ulcers. The reconstruction of complex defects of the foot has experienced a steady improvement in recent decades. Achievements in the therapy have been kept particularly for innovative surgical techniques and a better understanding of the specific tissue situation and functional requirements of the foot and ankle area.

## PLASTIC SURGICAL RECONSTRUCTION OPTIONS

Tumor removal is often accompanied by major tissue defects. Furthermore, there might be an exposure of functional structures, such as bones, tendons, nerves, and blood vessels. Therefore, plastic surgical reconstruction methods must be an integral part of oncosurgical treatment concepts. Moreover, transfer of healthy tissue with adequate blood supply enables adjuvant radiation and chemotherapy, and might improve the effectiveness by improving oxygen nourishment in the tumor bed. A simple reconstructive procedure, such as skin grafting, is, therefore, not usual, since the resulting soft-tissue coverage is often insufficient for adjuvant radiotherapy. However, the reconstructive ladder should still be addressed when considering soft-tissue coverage at the foot and ankle area. Some local flaps have proven to be very efficacious in the treatment of foot and ankle defects. Small defects at the non-weight-bearing sole can be covered by simple cutaneous or myocutaneous V-Y flaps. Due to its reliable vascular supply, its proportions and the moderate donor site defect, the distally based sural flap has proven itself in the coverage of smaller defects at the hind foot and malleolar region (30–33). The dominant pedicle of the distally based sural artery flap is a branch arising from the popliteal artery descending from the popliteal fossa between the heads of the gastrocnemius muscle. It is accompanied by the medial sural cutaneous nerve from the tibial nerve and small venae comitantes. The sural artery flap is a fasciocutaneous flap located at the proximal dorsal area of the lower leg. Elevation of

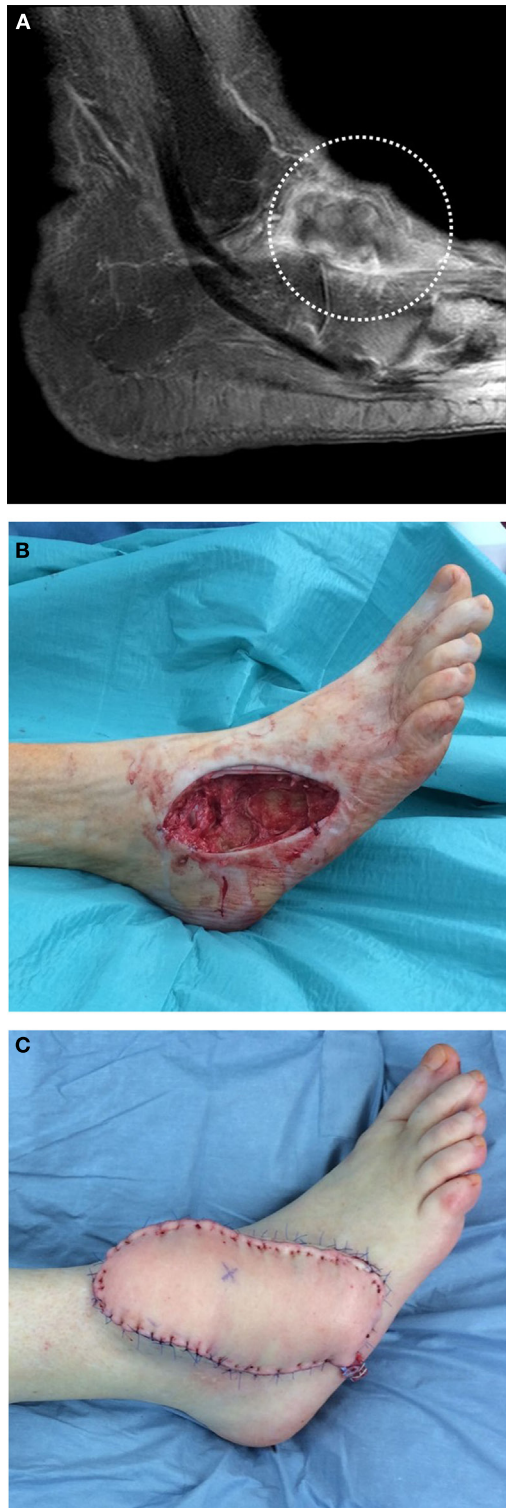

the flap proceeds proximally after visualization of the entrance of the dominant pedicle into the deep fascia in a subfascial plane until an adequate arc of rotation is achieved. Notably, the pivot point of the pedicle should be at least 5 cm proximal of the lateral malleolus in order to preserve the anastomoses with the peroneal artery. The maximum size of the distally based sural flap is limited because of its slight perfusion provided by the arterial network surrounding the sensory medial sural cutaneous nerve. Delayed distally based sural flaps can be raised larger and present an improved reliability but require a two-step surgical approach (34). Such delayed reverse sural flaps are particularly suited for small hind foot defects (35, 36). However, defects at the weight-bearing hind foot should ideally be reconstructed with sensible local flaps to avoid ulcerations. Mendieta et al. reported a case of a heel defect in which they connected the severed nerve end of a distally based sural flap with the intermediate dorsal cutaneous branch of the superficial peroneal nerve to give sensibility to the flap (37). Tan et al. recently reported a case series of such neurotized distally based sural flaps in 14 patients where all flaps survived and two-point discrimination achieved at least 14 mm after 6 months (38). The neurotized sural flap represents an interesting modification for the sensory reconstruction of weight-bearing hind foot defects and upcoming studies deserve attention. In the armamentarium of local flaps, the instep-island flap based on the medial plantar neurovascular pedicle provides another option for the sensory soft-tissue reconstruction of small hind foot defects (39, 40). The instep-island flap occupies the skin of the non-weight-bearing instep between the first metatarsal head and the distal portion of the heel. The flap is elevated distally deep to the plantar fascia and dissection continues proximally toward the medial plantar artery and nerve. Here, the medial plantar nerve can be split from distal to proximal in order to preserve the sensitivity of the flap and the medial foot (41, 42). The instep-island flap is suited for smaller defects, and the donor site must usually be transplanted with a skin graft.

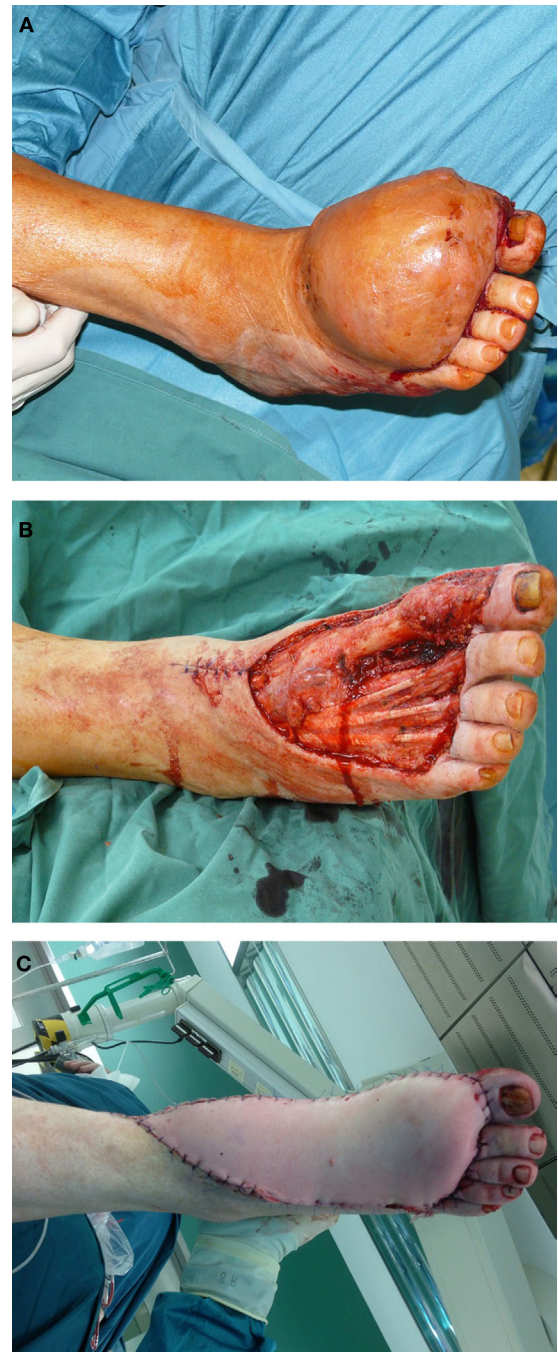If local flaps are not applicable for soft-tissue coverage, free tissue transfers can be utilized. Following the resection of a malignant tumor in the foot, the use of microvascularized tissue has been proven to be a successful surgical technique, offering an alternative to ablative surgery with functional restoration of the salvaged limb. Large defects of the foot can be treated by free microvascular myocutaneous or fasciocutaneous tissue transfer. If small defects, exposing bones or tendons, are not eligible for local flaps, small free microvascular flaps can be applied. These flaps cause a very low donor site morbidity. Myocutaneous and fasciocutaneous flaps have the advantage of replacing the missing tissue volume. Osseous surfaces can also be adequately covered and padded. If local flaps are not available, the implementation of a free tissue transfer should be taken into consideration. Such flaps provide adequate soft-tissue coverage for adjuvant radiation. A new group of propeller perforator flaps based on perforators from the anterior and posterior tibial artery and from the peroneal artery has been established in recent years, which also allows good defect management. In the Tokyo consensus, a propeller flap is defined as an island flap that reaches the recipient site through an axial rotation. The classification is based on the nourishing pedicle (subcutaneous pedicled propeller flap, perforator

pedicled propeller flap, and supercharged propeller flap), the degrees of skin island rotation (from 90 to 180°), and, when possible, the artery of origin of the perforator (43, 44). Dong et al. recently reported a series of 20 patients with soft-tissue defects of the lower leg and foot that were covered by perforator pedicled propeller flaps (45). All flaps survived and the areas of soft-tissue defect ranged from 2 cm × 8 cm to 10 cm × 20 cm. The donor sites could be closed primarily in 12 patients and skin grafted in 8 patients. Georgescu et al. reported another retrospectively analyzed series using perforator pedicled propeller flaps in 24 diabetic patients with acute and chronic wounds at the foot (46). A primary healing rate (96%) was obtained in 72% of all cases, whereas flap necrosis occurred in 24% and complete flap loss in 4%. Specific data after oncological resection and adjuvant therapy are still missing to date, but in experienced hands and in well selected cases, propeller perforator flaps can cover defects at the foot and ankle region reliably and provide an alternative to free flaps. In our experience, plastic reconstructive procedures after tumor resection in the foot and ankle area are required in about 50% of cases and are associated with a high success rate. Free transplants, such as fasciocutaneous flaps from the anterolateral thigh (ALT) and parascapular region, and also myocutaneous flaps, such as latissimus flap with or without a skin island, dominate. The ALT flap represents a versatile fasciocutaneous flap and is located at the anterolateral surface of the thigh (**Figures 1 and 2**). Its dominant pedicle proceeds from the septocutaneous or myocutaneous perforators of the descending branch of the lateral circumflex femoral artery. Primary closure of the donor site is usually possible when the flap width is 10 cm or less. Larger flaps need skin grafting of the donor site. Depending on the distribution of the subcutaneous fat in corpulent patients, the ALT flap might be less bulky than the parascapular flap in some cases and, thus, should be preferred in the soft-tissue reconstruction of the foot. The parascapular flap is a fasciocutaneous flap of the posterior trunk and is nourished by the descending branch of the circumflex scapular artery, which emerges from the triangular space between teres major, teres minor, and the long head of the triceps brachii muscle (**Figures 3 and 4**). The parascapular flap can be harvested up to 12 cm in width and 25 cm in length with primary closure. Similar to the parascapular flap, the latissimus dorsi muscle flap is also one of the most versatile flaps available to soft-tissue reconstruction (**Figure 5**). The expendable muscle with its reliable pedicle (thoracodorsal artery) can be harvested with or without a skin island from the posterior trunk and is excellently suited for widespread defects. The donor site morbidity of most free flaps is moderate and well tolerated by most of the patients, especially if the donor site can be closed primarily (47–49). Despite the adjuvant radiotherapy applied, the postoperative complications are tolerable and do not limit the use of microvascular tissue transfer.

As a reconstructive option after tumor resection, local flaps represent a reliable tool and can cover a wide range of smaller defects. Nevertheless, concerns over distant iatrogenic implantation of tumor cells at the donor site of local flaps exist when tumor resection and flap coverage were performed in the same surgical procedure. Reviewing the literature, there has, unfortunately, been no systematic analysis on this issue. However, iatrogenic



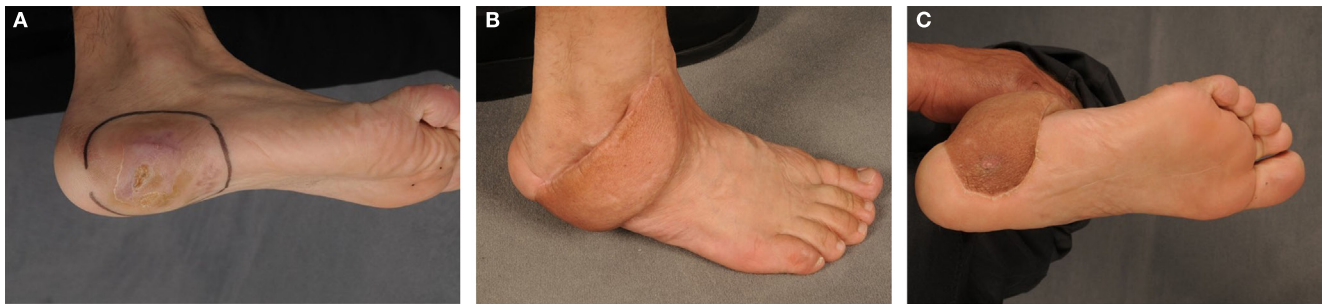**FIGURE 1 | A 77-year-old female was presented after incomplete resection of a liposarcoma G2 on the lateral ankle of her right foot.** The initial tumor localization is shown by MRI image (A). A two-stage reconstruction of the defect after extensive resection (B) was done by free transplantation of an adipocutaneous flap (C) from the anterolateral region of the thigh (ALT flap).



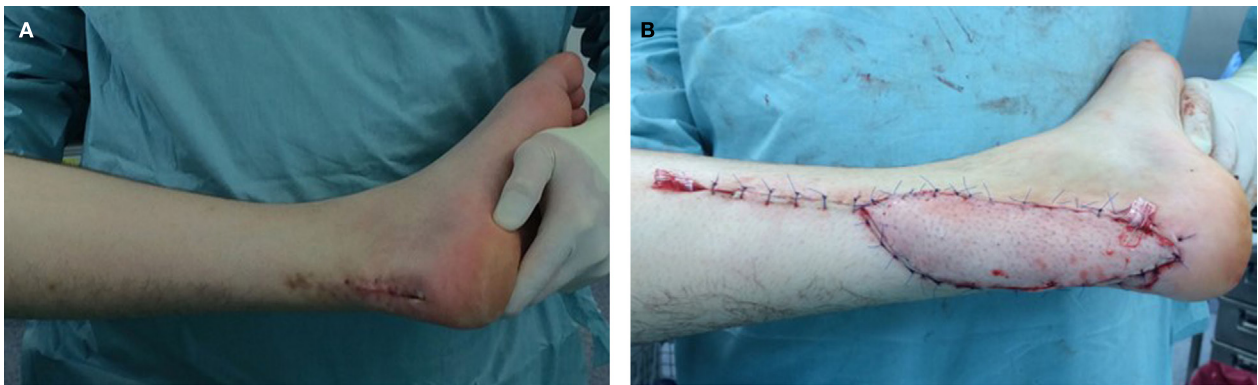
**FIGURE 2 | A 62-year-old male presented with first diagnosis of a myxoid fibrosarcoma G2 at the dorsum of his right foot (A).** After oncological tumor resection, the defect was reconstructed with a free fasciocutaneous ALT flap from the thigh (B,C).

tumor metastases at donor tissue sites after local flap reconstruction are a rare occurrence and should not preclude the use of local flap reconstruction (50). They have been described only in selected case reports (51). Furthermore, the effect of donor site radiation on the incidence of iatrogenic tumor metastases

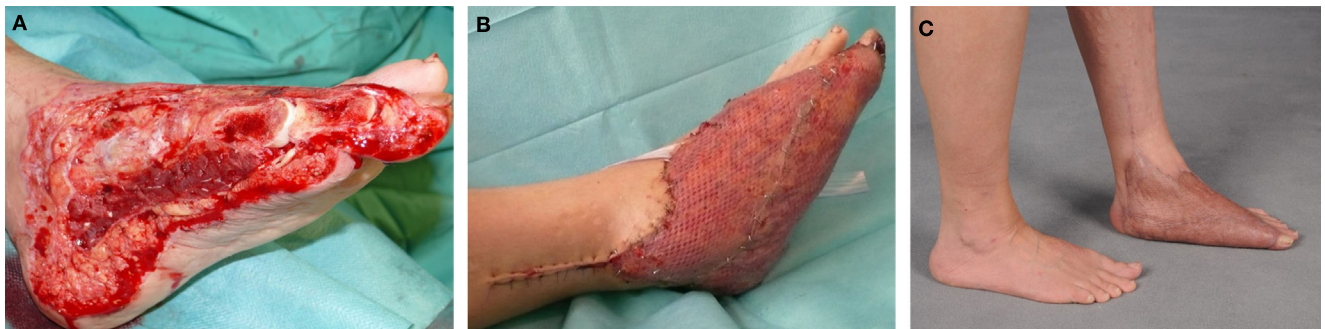



**FIGURE 3 | A 49-year-old male with a clear cell sarcoma G2 localized on his right foot (A).** The patient was transferred to our department for oncological resection and plastic reconstruction after an incomplete tumor resection. The coverage of the soft-tissue defect about the load-exposed part of the sole was performed by a free fasciocutaneous flap (B,C) from the parascapular area.



**FIGURE 4 | A 54-year-old male with infiltrative myxoid fibrosarcoma G2 of the Achilles' tendon of his left leg and R2 status after foreign surgery (A).** Reconstructive procedure after oncological resection was performed by use of a free parascapular flap (B).



**FIGURE 5 | A 46-year-old female with soft-tissue defect on her left foot after tumor resection (A).** The reconstruction was carried out by free transplantation of a latissimus dorsi muscle with split skin (A,B). Image of the foot after healing (C).

still remains unclear and should be examined (50). Beside the aforementioned concerns, local flaps can offer some slight but noteworthy advantages. In contrast to free flaps, local flaps do not require intensive postoperative flap inspections. Postoperative positioning protocols and anticoagulation regimens are less stringent. However, there has been a paradigm shift in the last few decades. Free tissue transfers can be performed with the same

or even higher degree of safety than local flap transfer as a result of the improvements in microsurgical techniques nowadays. Safe dissection and positioning of a local flap at the hind foot can be technically more demanding, risky, and time-consuming when compared to a free flap transfer in a two-team approach. Due to the microsurgical and anesthesiological improvements, free flap transfers have become physically less demanding



surgical procedures and have also become suitable for patients with vascular comorbidities.

Unfortunately, not all postoperative wound complications can be anticipated. For defects that extend to the tendons or joints, flap reconstruction is always required for adequate closure. A forced wound closure and “unexpected” wound complications can be slow to heal, devastating for the patient, and delay adjuvant radiotherapy. In this instance, early referral to a plastic surgeon is necessary in these cases to prevent devitalized superficial tissue from becoming infected and generating a deep infection that involves tendon, bone, or hardware. The use of free tissue transfer remains at the highest level on the reconstructive ladder. Although it is more complex, free tissue transfer may be necessary as a first choice. Our experience indicates that microvascularized tissue transfer is often the most suitable first option in accordance with established reconstructive principles. Furthermore, wound complications can occur more often after adjuvant radiation. Although defects, at first appearance, may be closed primarily or by using simple methods, such as split-thickness skin grafts, one must take the possibility of postoperative and postradiogenic wound complication into consideration. In those cases where there is an increased risk of exposure of tendons, bones or osteosynthetic material, a prophylactic use of an effective free flap for reconstruction should be considered. In the presence of avascular scar tissue, it should be removed before reconstruction. The use of prophylactic flaps in foot and ankle reconstruction is of great interest in patients with a high risk of wound healing disorders.

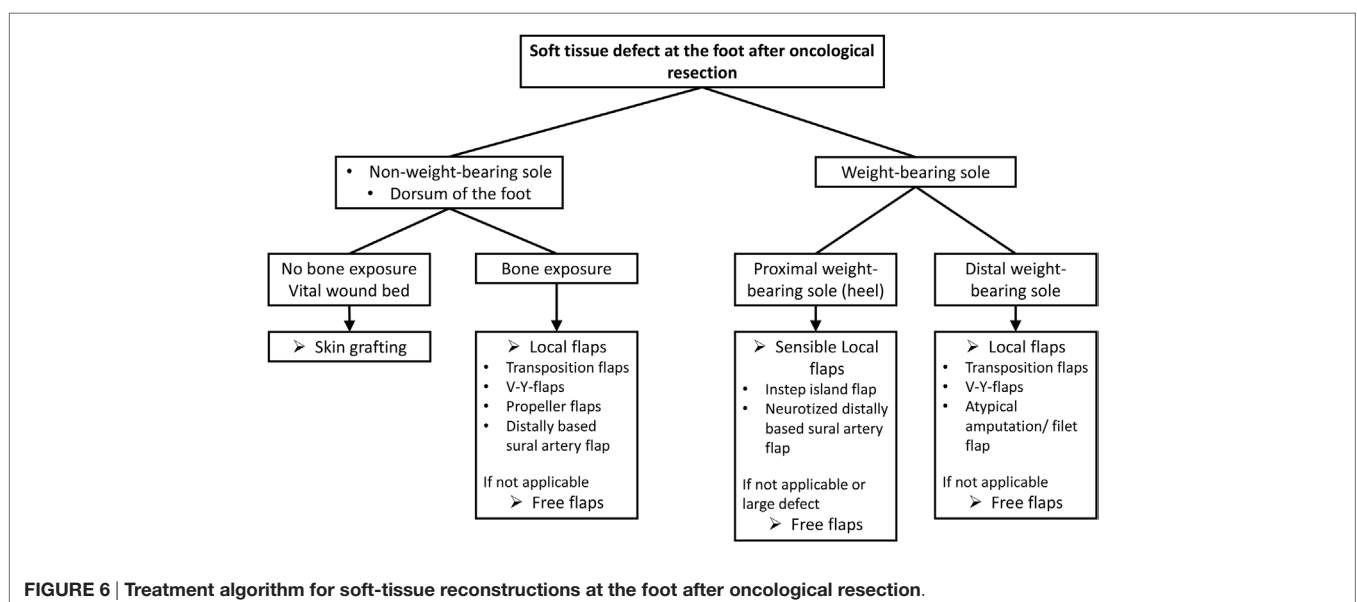
In addition to transplantation of tissue to cover the defects, the replacement of functional structures, such as tendons, vessels, and nerves, are at the forefront. Common peroneal nerve lesions or extensive loss of the anterior tibialis muscle might be an inevitable part of oncological resection and lead to a drop foot deformity. Primary transfer of the posterior tibialis tendon to the anterior tibialis tendon can restore the active extension of the foot (52, 53). There have been several technical modifications of

this procedure to date and most of them improve the extremity function notably (54, 55). Indications for the oncological resection of the tibial or peroneal nerve are fortunately rare, but, if necessary, nerve grafting using the sural nerve can restore some protective touch sensibility at the plantar foot even after nerve defects of several centimeters (56, 57). However, there are still controversies about the timing of nerve grafting, especially when adjuvant radiation treatment is planned. There are missing specific data for peroneal and tibial nerve reconstructions to date, but a very recent study that analyzed the functional outcome of multiple sural nerve grafts for facial nerve defects after oncological resection could not detect any adverse effects of adjuvant radiation treatment on the outcome of the nerve grafts and endorsed an immediate nerve grafting after primary tumor resection (58).

## CONCLUSION

Surgical therapy provides the basis for local tumor control in soft-tissue sarcoma. The goal defined is the resection of the tumor with clear surgical margins, followed by adjuvant radiotherapy in highly malignant tumors. In many cases, more complex plastic surgical reconstructions, such as the replacement of nerves, blood vessels, and bone, or transfer of muscles or tendons, are required due to the close proximity to functionally relevant anatomical structures. Defects can be covered by means of plastic surgery techniques so that the foremost unresectable tumors become curable. In our institution, we use the treatment algorithm depicted in **Figure 6** in order to cover most of the defects resulting after tumor resection.

At the present time, due to efforts in reconstructive plastic surgery, complex tumor resection with clear margins can be performed while still preserving the function that once may have been considered unsalvageable, particularly in the case of advanced tumors.



Patients are frequently presented with incompletely resected tumors. In such situations, the resection required is usually far more complex and extensive than the primary intervention. Due to this fact and the rarity and wide heterogeneity of soft-tissue sarcomas, they should be treated in specialized centers with plastic surgery as part of an interdisciplinary and multimodal treatment concept.

Our experience shows that reconstructive plastic surgery can play an integral role in the multimodal treatment concept including radiation and chemotherapy. The current plastic surgery

techniques allow for the preservation and reconstruction of function after the resection of malignant tumors. The quality of life of the oncologic patient can be significantly improved by knowing and applying the opportunities of plastic reconstructive surgery.

## AUTHOR CONTRIBUTIONS

AR and KH have written and prepared the manuscript. AD and ML reviewed and edited the manuscript. OG, PK, and BB helped to prepare the manuscript and the figures.

## REFERENCES

- Weiss SW, Goldblum JR, Folpe AL. *Enzinger and Weiss's Soft Tissue Tumors*. Philadelphia, USA: Elsevier Health Sciences (2007).
- Karakousis CP, De Young C, Driscoll DL. Soft tissue sarcomas of the hand and foot: management and survival. *Ann Surg Oncol* (1998) 5(3):238–40. doi:10.1007/BF02303779
- Lin PP, Guzel VB, Pisters PW, Zagars GK, Weber KL, Feig BW, et al. Surgical management of soft tissue sarcomas of the hand and foot. *Cancer* (2002) 95(4):852–61. doi:10.1002/cncr.10750
- Billingsley KG, Lewis JJ, Leung DH, Casper ES, Woodruff JM, Brennan MF. Multifactorial analysis of the survival of patients with distant metastasis arising from primary extremity sarcoma. *Cancer* (1999) 85(2):389–95. doi:10.1002/(SICI)1097-0142(19990115)85:2<389::AID-CNCR17>3.3.CO;2-A
- Stein HU, Daigeler A, Langer S, Steinstrasser L, Hauser J, Goertz O, et al. Limb salvage in malignant tumors. *Semin Plast Surg* (2010) 24(1):18–33. doi:10.1055/s-0030-1253240
- Kandel R, Coakley N, Werier J, Engel J, Ghert M, Verma S, et al. Surgical margins and handling of soft-tissue sarcoma in extremities: a clinical practice guideline. *Curr Oncol* (2013) 20(3):e247–54. doi:10.3747/co.20.1308
- Stojadinovic A, Jaques DP, Leung DH, Healey JH, Brennan MF. Amputation for recurrent soft tissue sarcoma of the extremity: indications and outcome. *Ann Surg Oncol* (2001) 8(6):509–18. doi:10.1007/s10434-001-0509-3
- Stojadinovic A, Leung DH, Allen P, Lewis JJ, Jaques DP, Brennan MF. Primary adult soft tissue sarcoma: time-dependent influence of prognostic variables. *J Clin Oncol* (2002) 20(21):4344–52. doi:10.1200/JCO.2002.07.154
- Stojadinovic A, Leung DH, Hoos A, Jaques DP, Lewis JJ, Brennan MF. Analysis of the prognostic significance of microscopic margins in 2,084 localized primary adult soft tissue sarcomas. *Ann Surg* (2002) 235(3):424–34. doi:10.1097/0000658-200203000-00015
- Gronchi A, Casali PG, Mariani L, Miceli R, Fiore M, Lo Vullo S, et al. Status of surgical margins and prognosis in adult soft tissue sarcomas of the extremities: a series of patients treated at a single institution. *J Clin Oncol* (2005) 23(1):96–104. doi:10.1200/JCO.2005.04.160
- Stein HU, Steinstrasser L, Hauser J, Tilkorn D, Stricker I, Daigeler A. [Soft tissue sarcoma. Resection and plastic reconstruction]. *Orthopäde* (2012) 41(2):165–75. doi:10.1007/s00132-011-1876-5
- Lehnhardt M, Daigeler A, Homann HH, Schwaiberger V, Goertz O, Kuhnen C, et al. MFH revisited: outcome after surgical treatment of undifferentiated pleomorphic or not otherwise specified (NOS) sarcomas of the extremities – an analysis of 140 patients. *Langenbecks Arch Surg* (2009) 394(2):313–20. doi:10.1007/s00423-008-0368-5
- Karakousis CP. Refinements of surgical technique in soft tissue sarcomas. *J Surg Oncol* (2010) 101(8):730–8. doi:10.1002/jso.21563
- Kaushal A, Citrin D. The role of radiation therapy in the management of sarcomas. *Surg Clin North Am* (2008) 88(3):629–46. doi:10.1016/j.suc.2008.03.005
- Pisters PW, Pollock RE, Lewis VO, Yasko AW, Cormier JN, Respondek PM, et al. Long-term results of prospective trial of surgery alone with selective use of radiation for patients with T1 extremity and trunk soft tissue sarcomas. *Ann Surg* (2007) 246(4):675–81. doi:10.1097/SLA.0b013e318155a9ae
- Karakousis CP, Zografos GC. Radiation therapy for high grade soft tissue sarcomas of the extremities treated with limb-preserving surgery. *Eur J Surg Oncol* (2002) 28(4):431–6. doi:10.1053/ejs.2002.1264
- Potter BK, Hwang PF, Forsberg JA, Hampton CB, Graybill JC, Peoples GE, et al. Impact of margin status and local recurrence on soft-tissue sarcoma outcomes. *J Bone Joint Surg Am* (2013) 95(20):e1511–8. doi:10.2106/JBJS.L.01149
- Kasper B, Ouali M, van Glabbeke M, Blay JY, Bramwell VH, Woll PJ, et al. Prognostic factors in adolescents and young adults (AYA) with high risk soft tissue sarcoma (STS) treated by adjuvant chemotherapy: a study based on pooled European Organisation for Research and Treatment of Cancer (EORTC) clinical trials 62771 and 62931. *Eur J Cancer* (2013) 49(2):449–56. doi:10.1016/j.ejca.2012.08.007
- Daigeler A, Harati K, Goertz O, Hirsch T, Steinau HU, Lehnhardt M. [Prognostic factors and surgical tactics in patients with locally recurrent soft tissue sarcomas]. *Handchir Mikrochir Plast Chir* (2015) 47(2):118–27. doi:10.1055/s-0034-1394425
- Daigeler A, Zmarsly I, Hirsch T, Goertz O, Steinau HU, Lehnhardt M, et al. Long-term outcome after local recurrence of soft tissue sarcoma: a retrospective analysis of factors predictive of survival in 135 patients with locally recurrent soft tissue sarcoma. *Brit J Cancer* (2014) 110(6):1456–64. doi:10.1038/bjc.2014.21
- Lewis JJ, Leung D, Casper ES, Woodruff J, Hajdu SI, Brennan MF. Multifactorial analysis of long-term follow-up (more than 5 years) of primary extremity sarcoma. *Arch Surg* (1999) 134(2):190–4. doi:10.1001/archsurg.134.2.190
- Trovik CS. Scandinavian Sarcoma Group P. Local recurrence of soft tissue sarcoma. A Scandinavian Sarcoma Group Project. *Acta Orthop Scand Suppl* (2001) 72(300):1–31. doi:10.1080/000164701317323417
- Deroose JP, Eggermont AM, van Geel AN, Burger JW, den Bakker MA, de Wilt JH, et al. Long-term results of tumor necrosis factor alpha- and melphalan-based isolated limb perfusion in locally advanced extremity soft tissue sarcomas. *J Clin Oncol* (2011) 29(30):4036–44. doi:10.1200/JCO.2011.35.6618
- Deroose JP, Grunhagen DJ, de Wilt JH, Eggermont AM, Verhoef C. Treatment modifications in tumour necrosis factor-alpha (TNF)-based isolated limb perfusion in patients with advanced extremity soft tissue sarcomas. *Eur J Cancer* (2015) 51(3):367–73. doi:10.1016/j.ejca.2014.11.020
- Hidalgo DA, Shaw WW. Anatomic basis of plantar flap design. *Plast Reconstr Surg* (1986) 78(5):627–36.
- Shaw WW, Hidalgo DA. Anatomic basis of plantar flap design: clinical applications. *Plast Reconstr Surg* (1986) 78(5):637–49. doi:10.1097/00006534-198611000-00012
- Gahalaut P, Pinto J, Pai GS, Kamath J, Joshua TV. A novel treatment for plantar ulcers in leprosy: local superficial flaps. *Lepr Rev* (2005) 76(3):220–31.
- Hidalgo DA, Shaw WW. Reconstruction of foot injuries. *Clin Plast Surg* (1986) 13(4):663–80.
- Spyropoulou A, Jeng SF. Microsurgical coverage reconstruction in upper and lower extremities. *Semin Plast Surg* (2010) 24(1):34–42. doi:10.1055/s-0030-1253244
- Chang SM, Li XH, Gu YD. Distally based perforator sural flaps for foot and ankle reconstruction. *World J Orthop* (2015) 6(3):322–30. doi:10.5312/wjo.v6.i3.322
- Jordan DJ, Malahias M, Hindocha S, Juma A. Flap decisions and options in soft tissue coverage of the lower limb. *Open Orthop J* (2014) 8:423–32. doi:10.2174/1874325001408010423
- Mileto D, Cotrufo S, Cuccia G, Delia G, Risitano G, Colonna MR, et al. The distally based sural flap for lower leg reconstruction: versatility in patients with associated morbidity. *Ann Ital Chir* (2007) 78(4):323–7.

33. Akhtar S, Hameed A. Versatility of the sural fasciocutaneous flap in the coverage of lower third leg and hind foot defects. *J Plast Reconstr Aesthet Surg* (2006) **59**(8):839–45. doi:10.1016/j.bjps.2005.12.009
34. Kneser U, Bach AD, Polykandriotis E, Kopp J, Horch RE. Delayed reverse sural flap for staged reconstruction of the foot and lower leg. *Plast Reconstr Surg* (2005) **116**(7):1910–7. doi:10.1097/01.prs.0000189204.71906.c2
35. Ali F, Harunarashid H, Yugasmavan K. Delayed reverse sural flap for cover of heel defect in a patient with associated vascular injury. A case report. *Indian J Surg* (2013) **75**(Suppl 1):148–9.
36. Ali MA, Chowdhury P, Ali M, Iftaker Ibne Z, Dev J. Distally-based sural island flap for soft tissue coverage of ankle and heel defects. *J Coll Physicians Surg Pak* (2010) **20**(7):475–7.
37. Mendieta MJ, Roblero C, Vega JC. Neurotized distally based sural flap for heel reconstruction. *J Reconstr Microsurg* (2013) **29**(8):501–4. doi:10.1055/s-0033-1348034
38. Tan O, Aydin OE, Demir R, Barin EZ, Cinal H, Algan S. Neurotized sural flap: an alternative in sensory reconstruction of the foot and ankle defects. *Microsurgery* (2015) **35**(3):183–9. doi:10.1002/micr.22325
39. Bibbo C. Plantar heel reconstruction with a sensate plantar medial artery musculocutaneous pedicled island flap after wide excision of melanoma. *J Foot Ankle Surg* (2012) **51**(4):504–8. doi:10.1053/j.jfas.2012.04.017
40. Kwan MK, Merican AM, Ahmad TS. Reconstruction of the heel defect with in-step island flap. A report of four cases. *Med J Malaysia* (2005) **60**(Suppl C):104–7.
41. Mourougayan V. Medial plantar artery (instep flap) flap. *Ann Plast Surg* (2006) **56**(2):160–3. doi:10.1097/01.sap.0000190830.71132.b8
42. Yang D, Yang JF, Morris SF, Tang M, Nie C. Medial plantar artery perforator flap for soft-tissue reconstruction of the heel. *Ann Plast Surg* (2011) **67**(3):294–8. doi:10.1097/SAP.0b013e3181f9b278
43. Georgescu AV. Propeller perforator flaps in distal lower leg: evolution and clinical applications. *Arch Plast Surg* (2012) **39**(2):94–105. doi:10.5999/aps.2012.39.2.94
44. Pignatti M, Ogawa R, Hallock GG, Mateev M, Georgescu AV, Balakrishnan G, et al. The “Tokyo” consensus on propeller flaps. *Plast Reconstr Surg* (2011) **127**(2):716–22. doi:10.1097/PRS.0b013e3181fed6b2
45. Dong KX, Xu YQ, Fan XY, Xu LJ, Su XX, Long H, et al. Perforator pedicled propeller flaps for soft tissue coverage of lower leg and foot defects. *Orthop Surg* (2014) **6**(1):42–6. doi:10.1111/os.12081
46. Georgescu AV, Matei IR, Capota IM. The use of propeller perforator flaps for diabetic limb salvage: a retrospective review of 25 cases. *Diabet Foot Ankle* (2012) **3**. doi:10.3402/dfa.v3i0.18978
47. Fischer S, Klinkenberg M, Behr B, Hirsch T, Kremer T, Hernekamp F, et al. Comparison of donor-site morbidity and satisfaction between anterolateral thigh and parascapular free flaps in the same patient. *J Reconstr Microsurg* (2013) **29**(8):537–44. doi:10.1055/s-0033-1351394
48. Klinkenberg M, Fischer S, Kremer T, Hernekamp F, Lehnhardt M, Daigeler A. Comparison of anterolateral thigh, lateral arm, and parascapular free flaps with regard to donor-site morbidity and aesthetic and functional outcomes. *Plast Reconstr Surg* (2013) **131**(2):293–302. doi:10.1097/PRS.0b013e31827786bc
49. Sauerbier M, Dittler S, Kreutzer C. Microsurgical chest wall reconstruction after oncologic resections. *Semin Plast Surg* (2011) **25**(1):60–9. doi:10.1055/s-0031-1275172
50. Saba SC, Shaterian A, Tokin C, Dobke MK, Wallace AM. The pedicled myocutaneous flap as a choice reconstructive technique for immediate adjuvant brachytherapy in sarcoma treatment. *Curr Oncol* (2012) **19**(6):e491–5. doi:10.3747/co.19.1141
51. Hughes TM, Thomas JM. Sarcoma metastases due to iatrogenic implantation. *Eur J Surg Oncol* (2000) **26**(1):50–2. doi:10.1053/ejso.1999.0740
52. Mehling I, Lanz U, Prommersberger KJ, Fuhrmann RA, van Schoonhoven J. [Transfer of the posterior tibialis tendon to restore an active dorsiflexion of the foot]. *Handchir Mikrochir Plast Chir* (2012) **44**(1):29–34. doi:10.1055/s-0031-1291316
53. Kremer T, Riedel K, Germann G, Heitmann C, Sauerbier M. [Tendon transfers for peroneal palsy – functional outcome]. *Handchir Mikrochir Plast Chir* (2011) **43**(2):95–101. doi:10.1055/s-0030-1269930
54. Steinau HU, Tofaute A, Huellmann K, Goertz O, Lehnhardt M, Kammeler J, et al. Tendon transfers for drop foot correction: long-term results including quality of life assessment, and dynamometric and pedobarographic measurements. *Arch Orthop Trauma Surg* (2011) **131**(7):903–10. doi:10.1007/s00402-010-1231-z
55. Vigasio A, Marcoccio I, Patelli A, Mattiuzzo V, Prestini G. New tendon transfer for correction of drop-foot in common peroneal nerve palsy. *Clin Orthop Relat Res* (2008) **466**(6):1454–66. doi:10.1007/s11999-008-0249-9
56. Dellon AL, Mackinnon SE. Results of posterior tibial nerve grafting at the ankle. *J Reconstr Microsurg* (1991) **7**(2):81–3. doi:10.1055/s-2007-1006764
57. Nunley JA, Gabel GT. Tibial nerve grafting for restoration of plantar sensation. *Foot Ankle* (1993) **14**(9):489–92. doi:10.1177/107110079301400901
58. Lee MC, Kim DH, Jeon YR, Rah DK, Lew DH, Choi EC, et al. Functional outcomes of multiple sural nerve grafts for facial nerve defects after tumor-ablative surgery. *Arch Plast Surg* (2015) **42**(4):461–8. doi:10.5999/aps.2015.42.4.461

**Conflict of Interest Statement:** The authors declare that the research was conducted in the absence of any commercial or financial relationships that could be construed as a potential conflict of interest.

Copyright © 2016 Ring, Kirchhoff, Goertz, Behr, Daigeler, Lehnhardt and Harati. This is an open-access article distributed under the terms of the Creative Commons Attribution License (CC BY). The use, distribution or reproduction in other forums is permitted, provided the original author(s) or licensor are credited and that the original publication in this journal is cited, in accordance with accepted academic practice. No use, distribution or reproduction is permitted which does not comply with these terms.





# Plastic Surgery in the Multimodal Treatment Concept of Soft Tissue Sarcoma: Influence of Radiation, Chemotherapy, and Isolated Limb Perfusion on Plastic Surgery Techniques

*Nicolai Kapalschinski, Ole Goertz, Kamran Harati, Maximilian Kueckelhaus, Jonas Kolbenschlag, Marcus Lehnhardt and Tobias Hirsch\**

*Department of Plastic and Reconstructive Surgery, Burn Centre, BG University Hospital Bergmannsheil, Ruhr University Bochum, Bochum, Germany*

## OPEN ACCESS

### Edited by:

Raphael Pollock,  
Ohio State University, USA

### Reviewed by:

Andreas Arkudas,  
University Hospital of Erlangen,  
Germany  
Holger Bannasch,  
University Freiburg Medical Center,  
Germany

### \*Correspondence:

Tobias Hirsch  
tobias.hirsch@rub.de

### Specialty section:

This article was submitted to Surgical Oncology, a section of the journal *Frontiers in Oncology*

**Received:** 05 August 2015

**Accepted:** 16 November 2015

**Published:** 01 December 2015

### Citation:

Kapalschinski N, Goertz O, Harati K, Kueckelhaus M, Kolbenschlag J, Lehnhardt M and Hirsch T (2015) Plastic Surgery in the Multimodal Treatment Concept of Soft Tissue Sarcoma: Influence of Radiation, Chemotherapy, and Isolated Limb Perfusion on Plastic Surgery Techniques. *Front. Oncol.* 5:268. doi: 10.3389/fonc.2015.00268

Surgical intervention is the mainstay treatment for soft tissue sarcomas (STSs). The significance of adjuvant and neoadjuvant therapies, such as chemotherapy, radiation, and isolated limb perfusion, remains under controversial discussion. The goal of this review is to discuss the effects of the aforementioned treatment modalities and their timing of application in plastic surgery techniques. Furthermore, options of reconstruction in cases of complications caused by adjuvant and neoadjuvant therapies are discussed. When compared with adjuvant radiation, neoadjuvant treatment can reduce negative side effects such as fibrosis and edema because radioderma can be removed during the subsequent surgical procedure. Furthermore, there have not been any reports of negative effects of neoadjuvant radiation on microsurgical procedures. However, the dose of neoadjuvant radiation correlates with increased risks of impaired wound healing postoperatively. Thus, a patient-specific approach to decide whether radiation should be performed adjuvant or neoadjuvant is necessary. Preoperative irradiation should be considered in cases where functional structures are exposed after tumor resection, in order to ensure the best possible functionality. Adjuvant radiation should be considered in all other cases because of its known superior wound healing. As for chemotherapy, no negative influence of its use adjuvant or neoadjuvant to reconstructive procedures, such as local or free flaps, has been reported. Lastly, small sample size studies have not shown increased risks of microsurgical failure or wound complications after isolated limb perfusion. The findings of this review suggest that the chronological order of the discussed therapeutic approaches is not a decisive factor in the surgical outcome of reconstructive procedures for STS.

**Keywords:** plastic surgery, sarcoma, radiation, chemotherapy, isolated limb perfusion

## BACKGROUND

Arising from the mesenchymal connective tissues, the heterogeneous group of soft tissue sarcomas (STS) occurs subcutaneous or deep in the extremities in 60% of cases (1). Surgical resection is the mainstay treatment of STS, and margin status is the most important prognostic factor. Margin status is usually documented according to the classification defined by Enneking et al. as intraleisional (biopsy), marginal (resection through the pseudocapsule and pretumoral reactive tissue), wide (resection including surrounding “normal” tissue outside the reactive zone, but within the involved anatomical compartment), or radical (compartment resection) (2). Historically, amputation or compartment resection is most often chosen in order to ensure complete tumor removal. Modern limb salvage techniques combined with neoadjuvant or adjuvant radiotherapy are now the standard treatment options for extremity STS. Sparing adjacent critical structures is safe and contributes to improved functional outcomes (3). Nevertheless, due to the heterogeneity of histological STS subtypes and of responses to chemotherapy, radiation, and isolated limb perfusion, the significance of adjuvant and neoadjuvant options in multimodal therapeutic approaches were a controversial topic of discussion in the past (1). In 1982, Rosenberg et al. showed that there was no difference in local tumor control and disease-free survival between amputation and limb-saving surgery followed by radiation (4). In addition, further studies showed similar results for marginal, wide or radical resection incorporated into pre- and postoperative radiation (5, 6).

Sarcoma resection should be performed in specialized cancer centers. Preoperative diagnostic measures, such as magnetic resonance imaging (MRI), are indispensable to define the expected surgical margins. Tumor resection frequently affects exposed functional structures, such as bones, joints, tendons, blood vessels, or nerves in addition to soft tissue defects, introducing the need for reconstructive procedures that include local or free flaps and motor replacement surgery. Therefore, plastic surgery methods have to be included in the multimodal approach, and the preference is shifted from conventional simple techniques of wound closure toward microsurgical procedures that enable the transfer of uninvolved tissues to the affected region. Furthermore, reconstructive surgery can help treat complications caused by adjuvant and neoadjuvant therapies. The timepoint at which additional treatments are introduced directly affects the planning for and the outcomes of tumor resection and reconstructive plastic surgery techniques.

The goal of this review is to show the influence of the timing of introduction of additional treatments for STS, such as radiation, chemotherapy, and isolated limb perfusion, on the surgical techniques used for reconstruction following tumor resection.

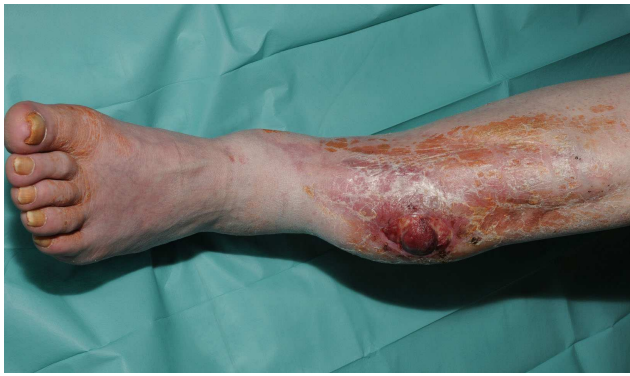## RADIOTHERAPY

Despite years of experience, the role of radiotherapy in the treatment of extremities STS was not fully established in the past (1). It has been demonstrated that neoadjuvant irradiation provides no significant benefit in local control of the tumors and/or development of distant metastasis when compared with

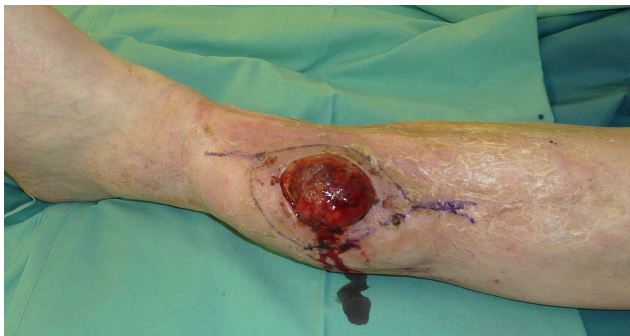adjuvant treatment (6, 7). Moreover, the influence of neoadjuvant irradiation on subsequent plastic surgery techniques remains controversially discussed. As radiation theoretically sterilizes the reactive zone surrounding the tumor, neoadjuvant radiation may allow marginal excision to be safely performed around vital structures without compromising local control rates (6). Neoadjuvant irradiation enables a smaller radiation field size when compared with adjuvant irradiation (8).

After neoadjuvant radiotherapy, complete removal of surrounding radioderma prior to soft tissue coverage via plastic surgery can be performed. As a result, late radiation effects, such as fibrosis, caused by increased collagen synthesis as a side effect of external radiotherapy and edema can be reduced. This procedure is of major interest in cases of exposed functional structures, such as tendons or joints where fibrosis and edema can compromise functional restrictions. Furthermore, preoperative treatment prevents the delay between irradiation and surgical resection that is caused by a possible compromised wound healing when radiotherapy is performed adjuvant. Several studies showed that neoadjuvant radiation has no negative effect on microsurgical procedures, including free flaps (9–11). For afferent vessels located in postradiogenic altered tissue, there was no significant increase of complications. Even though preoperative radiotherapy typically involves a lower dose of radiation when compared with postoperative radiotherapy, the risk of impaired postoperative wound healing rises in direct correlation with the neoadjuvant radiation dose (12). O’Sullivan reported that 35% of patients receiving preoperative radiotherapy (50 Gy in 25 fractions) and 17% of patients receiving postoperative radiotherapy (66 Gy in 33 fractions) developed wound complications irrespective of the surgical procedure (primary closure or plastic surgery) (7, 12). Other authors reported that 21–37% of the patients who received neoadjuvant radiation developed serious local wound complications including infection, tissue necrosis, seroma, and dehiscence, particularly at the proximal lower extremity (36 vs. 15–27% for other locations) (6, 13). Interestingly, for the upper extremity, much less wound healing problems were described compared to the lower extremity after neoadjuvant radiation therapy (7). Thus, a different regimen of therapy chronology can be considered for the upper extremity. Nevertheless, additional surgical procedures aimed to control wound morbidity were necessary in 16–23% of the cases (13, 14). On the other hand, rates of fibrosis were increased in patients who received adjuvant treatment. Radiation doses of 50–60 Gy within 6 weeks after surgery can reduce local recurrence, but fibrosis and postradiogenic altered skin can provoke chronic ulceration in an otherwise adequately healed transplant (15). Resulting unstable scars and fibrotic tissue may cause inferior functional outcomes (16).

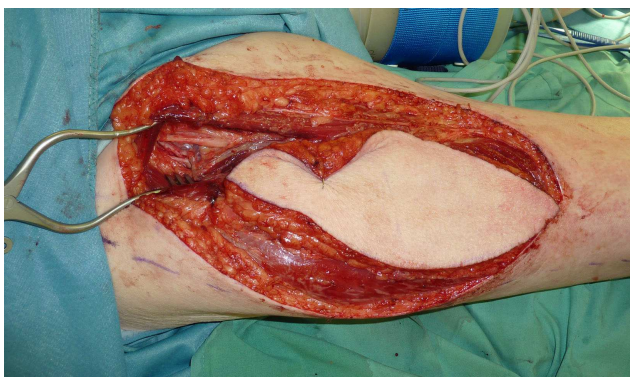
High-dose-rate brachytherapy provides a constant dose to the target and very low doses to nearby radiosensitive tissues. Sharma et al. reported that perioperative high-dose-rate interstitial brachytherapy in combination with external beam radiation therapy provides excellent local control and survival rates (follow-up 46 months) with acceptable acute and late toxicities (17). Delayed wound healing was observed in 5.7% of cases, whereas chronic skin lesions and fibrosis were observed in 9.6%



**FIGURE 1 |** Recurrence of a myofibroblastic sarcoma (TNM classification: pT2b pNX M0, G1) of the left lower leg 13 years after tumor resection and free latissimus dorsi transfer. Status post neoadjuvant isolated limb perfusion.

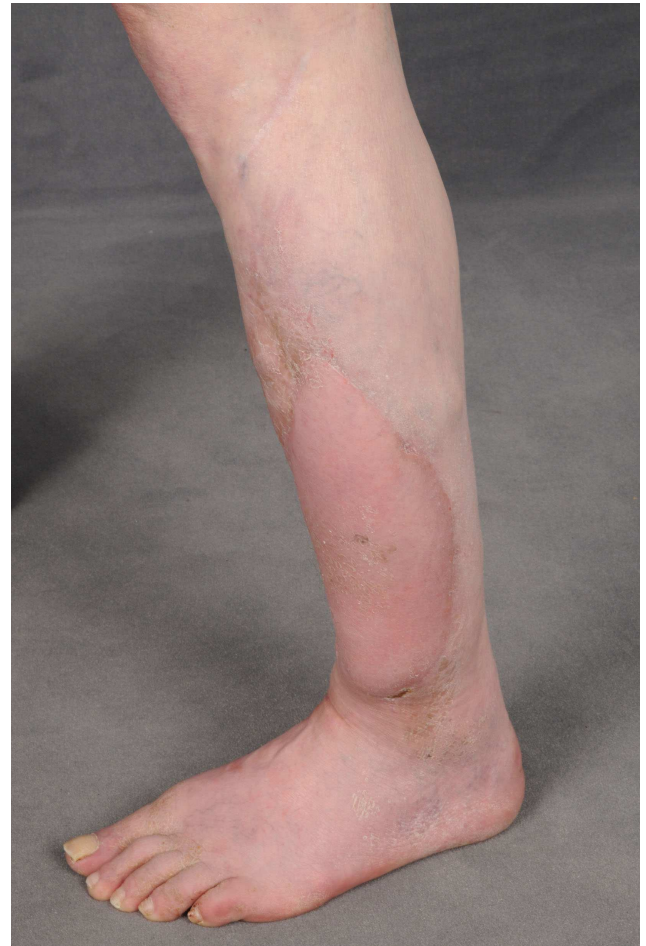

**FIGURE 2 |** Preoperative planning of tumor resection (R0).



**FIGURE 3 |** Elevation of an anteromedial thigh (AMT) flap and dissection of the pedicle.

(17). Nevertheless, other studies demonstrated an increased rate of impaired wound healing after brachytherapy combined with neoadjuvant radiation when compared with external radiation, irrespective of the reconstructive approach (18). The overall higher radiation dose might be an explanation for these findings. No negative influence to microsurgical reconstruction has been described (19). However, it is important to note that the source



**FIGURE 4 |** Postoperative result after complete wound healing.

of radiation should be placed at the maximal distance possible to the anastomosis because local radiation treatment decreases vessel wall strength (20).

## CHEMOTHERAPY

Just as in the case of radiotherapy discussed above, the role of adjuvant or neoadjuvant chemotherapy in the treatment of STS is controversial due to the low response rate and toxic adverse effects. Marginal positive effect to the disease-free surviving was reported in several meta-analyses in the past (21). Nevertheless, for first line therapy including Doxorubicin and Ifosfamide, a response rate of up to 30% is described while no benefit in relapse-free survival or overall survival could be shown (22, 23). Based on these findings, adjuvant chemotherapy should be limited to high-risk patients with extensive, highly malignant STS in the setting of controlled clinical studies (23).

There have been no reports to the authors' knowledge of negative influence of chemotherapy on reconstructive procedures involving local or free flaps. However, it is noted that adjuvant treatment should not start before completion of wound healing because there is a known increased risk of wound complications



associated with chemotherapy (6). Sanniec et al. showed wound complications in 49% of cases of combined sarcoma resection and chemotherapy (24).

Extravasation of cytostatic drugs during peripheral intravenous administration is a potentially severe complication of chemotherapy. The frequency of extravasation is considered to be between 0.6 and 6% (25). The extent of local tissue injury depends on the chemical structure of the applied substance, which is classified as vesicant, irritant, and non-irritant. According to current references, treatment of chemotherapy drug extravasation should be managed in specialized centers (26). Surgical interventions are indicated in cases of extensive necrotic areas or failure of conservative measures. After surgical debridement, reconstructive procedures, such as split-thickness skin grafts or randomized fasciocutaneous flaps, prevent prolonged secondary wound healing. Thus, plastic surgical treatment enables early and complete remission of the lesions and reduces the delay in administration of further chemotherapy (27).

## ISOLATED LIMB PERFUSION

For the treatment of locally advanced STS in the extremities, isolated limb perfusion with TNF-alpha and melphalan (TM-ILP) has proven to be a effective treatment modality with limb salvage rates of ~87% and response rates of 71% (28, 29). Tumor size reduction induced by TM-ILP can render non-resectable tumors to resectable.

Unfortunately, there is limited available data for reconstructive procedures following isolated limb perfusion. Even when

local complications, such as impaired wound healing and lymphocutaneous fistulas are described, small sample size studies demonstrated no increased risk of microsurgical failure or wound complications (30). Functional results after limb-sparing surgery were shown to be satisfactory (31).

## CONCLUSION

Interdisciplinary treatment involving pathologists, radiologists, surgeons, radiation therapists, and medical oncologists is mandatory in cases of STS. Therapy planning and performance should be carried out at referral centers for sarcomas that can provide the necessary multidisciplinary environment. Irradiation represents a mainstay in treatment. The significance of chemotherapy and isolated limb perfusion on the outcomes of reconstructive procedures following STS resection is yet to be elucidated. The chronology of radiation, chemotherapy, limb perfusion, and surgical resection appears to have no influence on the success of reconstructive procedures, such as microsurgical tissue transfers (**Figures 1–4**). Most surgeons prefer postoperative radiation because it may afford decreased risks of wound complications. In cases of neoadjuvant radiation, free flaps may be performed for soft-tissue reconstruction. Several studies showed superior functional outcomes with preoperative, rather than postoperative radiotherapy. Pre- and postoperative irradiation mainly affects plastic surgery procedures in terms of impaired wound healing and fibrosis. Further studies will be necessary to elucidate the effects of chemotherapy and isolated limb perfusion on the outcomes of reconstructive procedures following resection of STSs.

## REFERENCES

- Hohenberger P, Wysocki WM. Neoadjuvant treatment of locally advanced soft tissue sarcoma of the limbs: which treatment to choose? *Oncologist* (2008) **13**:175–86. doi:10.1634/theoncologist.2007-0165
- Enneking WF, Spanier SS, Goodman MA. A system for the surgical staging of musculoskeletal sarcoma. *Clin Orthop Relat Res* (1980) **153**:106–20.
- O'Donnell PW, Griffin AM, Eward WC, Sternheim A, Catton CN, Chung PW, et al. The effect of the setting of a positive surgical margin in soft tissue sarcoma. *Cancer* (2014) **120**:2866–75. doi:10.1002/cncr.28793
- Rosenberg SA, Tepper J, Glatstein E, Costa J, Baker A, Brennan M, et al. The treatment of soft-tissue sarcomas of the extremities: prospective randomized evaluations of (1) limb-sparing surgery plus radiation therapy compared with amputation and (2) the role of adjuvant chemotherapy. *Ann Surg* (1982) **196**:305–15. doi:10.1097/00000658-198209000-00009
- Trovik CS, Bauer HC. Local recurrence of soft tissue sarcoma a risk factor for late metastases. 379 patients followed for 0.5–20 years. *Acta Orthop Scand* (1994) **65**:553–8. doi:10.3109/17453679409000913
- Dagan R, Indelicato DJ, McGee L, Morris CG, Kirwan JM, Knapik J, et al. The significance of a marginal excision after preoperative radiation therapy for soft tissue sarcoma of the extremity. *Cancer* (2012) **118**:3199–207. doi:10.1002/cncr.26489
- O'Sullivan B, Davis AM, Turcotte R, Bell R, Catton C, Chabot P, et al. Preoperative versus postoperative radiotherapy in soft-tissue sarcoma of the limbs: a randomised trial. *Lancet* (2002) **359**:2235–41. doi:10.1016/S0140-6736(02)09292-9
- Nielsen OS, Cummings B, O'Sullivan B, Catton C, Bell RS, Fornasier VL. Preoperative and postoperative irradiation of soft tissue sarcomas: effect of radiation field size. *Int J Radiat Oncol Biol Phys* (1991) **21**:1595–9. doi:10.1016/0360-3016(91)90337-4
- Barwick WJ, Goldberg JA, Scully SP, Harrelson JM. Vascularized tissue transfer for closure of irradiated wounds after soft tissue sarcoma resection. *Ann Surg* (1992) **216**:591–5. doi:10.1097/00000658-199211000-00011
- Cohn AB, Lang PO, Agarwal JP, Peng SL, Alizadeh K, Stenson KM, et al. Free-flap reconstruction in the doubly irradiated patient population. *Plast Reconstr Surg* (2008) **122**:125–32. doi:10.1097/PRS.0b013e3181773d39
- Chao AH, Chang DW, Shuaib SW, Hanasono MM. The effect of neoadjuvant versus adjuvant irradiation on microvascular free flap reconstruction in sarcoma patients. *Plast Reconstr Surg* (2012) **129**:675–82. doi:10.1097/PRS.0b013e3182412a39
- Rosenberg LA, Esther RJ, Erfanian K, Green R, Kim HJ, Sweeting R, et al. Wound complications in preoperatively irradiated soft-tissue sarcomas of the extremities. *Int J Radiat Oncol Biol Phys* (2013) **85**:432–7. doi:10.1016/j.ijrobp.2012.04.037
- Bujko K, Suit HD, Springfield DS, Convery K. Wound healing after preoperative radiation for sarcoma of soft tissues. *Surg Gynecol Obstet* (1993) **176**:124–34.
- Kunisada T, Ngan SY, Powell G, Choong PF. Wound complications following pre-operative radiotherapy for soft tissue sarcoma. *Eur J Surg Oncol* (2002) **28**:75–9. doi:10.1053/ejso.2001.1213
- Kaushal A, Citrin D. The role of radiation therapy in the management of sarcomas. *Surg Clin North Am* (2008) **88**:629–646, viii. doi:10.1016/j.suc.2008.03.005
- Davis AM, O'Sullivan B, Turcotte R, Bell R, Catton C, Chabot P, et al. Late radiation morbidity following randomization to preoperative versus postoperative radiotherapy in extremity soft tissue sarcoma. *Radiother Oncol* (2005) **75**:48–53. doi:10.1016/j.radonc.2004.12.020
- Sharma DN, Deo SV, Rath GK, Shukla NK, Bakhshi S, Gandhi AK, et al. Perioperative high-dose-rate interstitial brachytherapy combined with external beam radiation therapy for soft tissue sarcoma. *Brachytherapy* (2015) **14**:571–7. doi:10.1016/j.brachy.2015.03.002
- Spierer MM, Alektiar KM, Zelefsky MJ, Brennan MF, Corderio PG. Tolerance of tissue transfers to adjuvant radiation therapy in primary soft tissue sarcoma of the extremity. *Int J Radiat Oncol Biol Phys* (2003) **56**:1112–6. doi:10.1016/S0360-3016(03)00200-1
- Papagelopoulos PJ, Mavrogenis AF, Mastorakos DP, Vlastou C, Vrouvas J, Soucacos PN. Free vascularised tissue transfer and brachytherapy for soft-tissue

- sarcomas of the extremities. *Injury* (2008) **39**(Suppl 3):S83–9. doi:10.1016/j.injury.2008.06.005
20. Hinchcliff K, Olson CA, Little CJ, Orbay H, Sahar DE. Irradiated superficial femoral artery rupture after free flap: a case report and review of the literature. *Ann Plast Surg* (2015) **74**(Suppl 1):S15–8. doi:10.1097/SAP.0000000000000432
  21. Pervaiz N, Colterjohn N, Farrokhhyar F, Tozer R, Figueredo A, Ghert M. A systematic meta-analysis of randomized controlled trials of adjuvant chemotherapy for localized resectable soft-tissue sarcoma. *Cancer* (2008) **113**:573–81. doi:10.1002/cncr.23592
  22. Riedel RF. Systemic therapy for advanced soft tissue sarcomas: highlighting novel therapies and treatment approaches. *Cancer* (2012) **118**:1474–85. doi:10.1002/cncr.26415
  23. Woll PJ, Reichardt P, Le Cesne A, Bonvalot S, Azzarelli A, Hoekstra HJ, et al. Adjuvant chemotherapy with doxorubicin, ifosfamide, and lenograstim for resected soft-tissue sarcoma (EORTC 62931): a multicentre randomised controlled trial. *Lancet Oncol* (2012) **13**:1045–54. doi:10.1016/S1470-2045(12)70346-7
  24. Sannicci KJ, Swanson S, Casey WJ III, Schwartz A, Bryant L, Rebecca AM. Predictive factors of wound complications after sarcoma resection requiring plastic surgeon involvement. *Ann Plast Surg* (2013) **71**:283–5. doi:10.1097/SAP.0b013e31827c7973
  25. Jordan K, Grothe W, Schmoll HJ. [Extravasation of chemotherapeutic agents: prevention and therapy]. *Dtsch Med Wochenschr* (2005) **130**:33–7. doi:10.1055/s-2005-837372
  26. Azaïs H, Bresson L, Bassil A, Katdare N, Merlot B, Houpeau JL, et al. Chemotherapy drug extravasation in totally implantable venous access port systems: how effective is early surgical lavage? *J Vasc Access* (2015) **16**:31–7. doi:10.5301/jva.5000316
  27. Pluschnig U, Haslik W, Bayer G, Soleiman A, Bartsch R, Lamm W, et al. Outcome of chemotherapy extravasation in a large patient series using a standardised management protocol. *Support Care Cancer* (2015) **23**:1741–8. doi:10.1007/s00520-014-2535-2
  28. Deroose JP, van Geel AN, Burger JW, Eggermont AM, Verhoef C. Isolated limb perfusion with TNF-alpha and melphalan for distal parts of the limb in soft tissue sarcoma patients. *J Surg Oncol* (2012) **105**:563–9. doi:10.1002/jso.22121
  29. Deroose JP, Grünhagen DJ, van Geel AN, de Wilt JH, Eggermont AM, Verhoef C. Long-term outcome of isolated limb perfusion with tumour necrosis factor-alpha for patients with melanoma in-transit metastases. *Br J Surg* (2011) **98**:1573–80. doi:10.1002/bjs.7621
  30. Sadrian R, Niederbichler AD, Friedman J, Vogt PM, Steinau HU, Reece G, et al. Intraarterial chemotherapy: the effects on free-tissue transfer. *Plast Reconstr Surg* (2002) **109**:1254–8. doi:10.1097/00006534-200204010-00007
  31. Di Filippo F, Giacomini P, Rossi CR, Santinami M, Garinei R, Anzà M, et al. Hyperthermic isolated perfusion with tumor necrosis factor-alpha and doxorubicin for the treatment of limb-threatening soft tissue sarcoma: the experience of the Italian Society of Integrated Locoregional Treatment in Oncology (SITIO). *In Vivo* (2009) **23**:363–7.

**Conflict of Interest Statement:** The authors declare that the research was conducted in the absence of any commercial or financial relationships that could be construed as a potential conflict of interest.

Copyright © 2015 Kapalschinski, Goertz, Harati, Kueckelhaus, Kolbenschlag, Lehnhardt and Hirsch. This is an open-access article distributed under the terms of the Creative Commons Attribution License (CC BY). The use, distribution or reproduction in other forums is permitted, provided the original author(s) or licensor are credited and that the original publication in this journal is cited, in accordance with accepted academic practice. No use, distribution or reproduction is permitted which does not comply with these terms.

# Advantages of publishing in Frontiers



## OPEN ACCESS

Articles are free to read,  
for greatest visibility



## COLLABORATIVE PEER-REVIEW

Designed to be rigorous  
– yet also collaborative,  
fair and constructive



## FAST PUBLICATION

Average 85 days from  
submission to publication  
(across all journals)



## COPYRIGHT TO AUTHORS

No limit to article  
distribution and re-use



## TRANSPARENT

Editors and reviewers  
acknowledged by name  
on published articles



## SUPPORT

By our Swiss-based  
editorial team



## IMPACT METRICS

Advanced metrics  
track your article's impact



## GLOBAL SPREAD

5'100'000+ monthly  
article views  
and downloads



## LOOP RESEARCH NETWORK

Our network  
increases readership  
for your article

## Frontiers

EPFL Innovation Park, Building I • 1015 Lausanne • Switzerland  
Tel +41 21 510 17 00 • Fax +41 21 510 17 01 • [info@frontiersin.org](mailto:info@frontiersin.org)  
[www.frontiersin.org](http://www.frontiersin.org)

## Find us on

